

Evaluation of the Rabbit as a Model for Chagas Disease - II. Histopathologic Studies of the Heart, Digestive Tract and Skeletal Muscle

Arnaldo Moreira da Silva⁺, Luiz Eduardo Ramirez, Marlene Vargas*,
Edmundo Chapadeiro/⁺⁺, Zigman Brener**

Curso de Pós-graduação em Patologia Humana, Faculdade de Medicina do Triângulo Mineiro, 38025-440 Uberaba, MG, Brasil * Departamento de Patologia, Faculdade de Medicina Veterinária de Viçosa, MG, Brasil

** Centro de Pesquisas René Rachou-FIOCRUZ, Belo Horizonte, MG, Brasil

In order to investigate the value of the rabbit as an experimental model for Chagas' disease, seventy one animals were inoculated with different Trypanosoma cruzi strains and routes. The rabbits were submitted to necropsy in acute (earlier than three months of infection), recent chronic (three to six months) and late chronic (later than six months) phases.

Myocarditis, generally focal and endomyocardial, occurred in 94.1%, 66.7% and 70.8% of the infected rabbits respectively in the acute, recent chronic and late chronic phases. The myocardial inflammatory exudate was composed by mononuclear cells, and also polymorphonuclear cells in the acute phase. In most cases of the late chronic phase, the myocarditis was similar to that described in the indeterminate form of human chagasic patients. Initial fibrosis occurred in the three phases but was more severe and frequent in the early chronic. Advanced fibrosis occurred only in the late chronic phase. Tissue parasites occurred only in the acute phase. The digestive tract and skeletal muscles showed mild and occasional lesions.

Our data indicate that experimentally infected chagasic rabbits repeat some lesions similar to that of humans chagasic patients, specially that of the indeterminate form. So, it may be a useful, however not an ideal, model.

Key words: *Trypanosoma cruzi* - Chagas' disease - experimental infection - rabbit - histopathology

Many aspects of Chagas' disease remain poorly understood, in spite of large number of researches in this subject. One example is the pathogenesis of the cardiac lesions in the chronic phase of the disease. So, it is indispensable to select adequate experimental models that can reproduce all or the majority of the pathologic events observed in human cases, as recommended by WHO (1984). According to Brener and Ramirez (1985), other conditions are necessary, such as the development of the lesions in relatively short time, easy manipulation and accessible cost and maintenance.

Regarding to rabbits, there are many controversies about its usefulness as an experimental model to the study of Chagas' disease. Different researchers have obtained discordant results, that were promising for those who utilized strains as Ernestina and Albuquerque of *Trypanosoma cruzi*

(Teixeira et al. 1975, 1983a, b, Figueiredo et al. 1979, Rezende Filho et al. 1979), and discouraging for others who employed strains as Y, CL, MR and 12SF (Andrade & Andrade 1979, Chiari et al. 1980). With the Colombian strain, Figueiredo (1984) and Figueiredo et al. (1985) observed significant lesions, which was not confirmed by Andrade and Andrade (1979).

The aim of this research is to study the histologic lesions of the heart, digestive tract and skeletal muscle of rabbits infected with different strains of *T. cruzi*, by different numbers of parasites and routes, during the acute and chronic phases of the infection.

MATERIALS AND METHODS

Eighty three outbred male 2-4 month old rabbits, weighing from 800 to 1,300 g were utilized. Among them, 71 were infected by intraperitoneal (ip) or conjunctival (conj) routes, with Y, CL or Ernane (Er) strains of *T. cruzi*. and 12, non-infected, were used as controls.

The infective forms were: (a) blood trypomastigotes (BTry) of the three strains, obtained from experimentally infected mice; (b) tissue-culture ("VERO" cells) derived trypto-

⁺Present address: Serviço de Anatomia Patológica, Hospital de Clínicas da Universidade Federal de Uberlândia, Campus Umarama, Av. Pará nº 1720, 38405-382 Uberlândia, MG, Brasil

⁺⁺Corresponding author. Fax: 55-034-312.6640

Received 3 March 1995

Accepted 22 December 1995

mastigotes (TcTry) of the Y strain; (c) metacyclic trypomastigotes (MTry) of the three strains, obtained from *Dipetalogaster maximus*.

Forty eight (48) rabbits were infected by ip route with 10^7 BTry (14 with Y, 16 with CL and 12 with Er) or TcTry (6 with Y) and 23 by conj route with $2 - 4 \times 10^3$ MTry (8 with Y, 7 with CL and 8 with Er).

Seventy six rabbits were sacrificed and seven died spontaneously between 22 days and 24 months post-infection and were submitted to necropsy. Fragments of heart (from the four chambers), digestive tract and skeletal muscle (diaphragm, intercostal and psoas) were obtained for histopathological examination. Routine histological sections were stained by hematoxylin-eosin (H&E) and Gomori or Masson trichrome. Immunohistochemistry reaction with the peroxidase-antiperoxidase method (Taylor 1986) was used in heart sections of 31 rabbits, to amplify the search of amastigote forms.

The histological study of the heart, digestive tract and skeletal muscle samples was systematically done, specially concerning the inflammatory process when present (topography, characteristics of the exudate, fibrosis) and the presence of parasites. Myocarditis, diagnosed in accordance to the Dallas' criteria (Aretz 1987), was evaluated qualitatively (inflammatory exudate, fibrosis), semiquantitatively, topographically (endomysial or perimysial inflammation) and about its extent: focal (F), isolated little injured areas; zonal (Z), many confluent foci; and diffuse (D), large confluent areas. To apprise the evolution of the myocarditis, three aspects were considered: (a) leukocytic infiltration, characterizing active inflammation; (b) fibroblastic proliferation with minimal young collagen deposition, called here "initial fibrosis"; (c) abundant dense collagen deposition, designated "advanced fibrosis". For semiquantitative evaluation, the inflammatory exudate, the initial fibrosis and the advanced fibrosis were characterized as F, Z or D. When F, the number of foci per 100 high power field (HPF) was counted, with a 40x objective. Comparing the infected with the controls animals, it seemed suitable to consider: (a) absence of lesion, less than one focus per 100 HPF (f/100 HPF); (b) very mild focal lesion (VmF), one to two f/100 HPF; (c) mild focal lesion (MF), three to ten f/100 HPF; (d) moderate focal lesion (MoF), 11 to 25 f/100 HPF; (e) severe focal lesion (SF), more than 25 f/100 HPF. Thus, the crescent severity degree were: VmF, MF, MoF, SF, Z and D.

For description and analysis of the results, it was considered three phases according to the time lapse from the infection to the necropsy: (a) acute phase, earlier than three months of infection; (b)

recent chronic phase, three to six months of infection; (c) late chronic phase, later than six months of infection.

The chi-square test was utilized to compare the frequencies of the lesions observed in the diverse groups (p value ≤ 0.05 was considered statistically significant).

RESULTS

Acute phase - In 16 out of 17 animals submitted to necropsy during the acute phase (94.1%), it was observed myocarditis varying from VmF to Z (Table), characterized by myocardial foci of mononuclear infiltrate bound to the sarcolemma of myocardial cells, and occasional neutrophils and eosinophils granulocytes, with endomysial distribution and variable extension (Fig. 1). The exudate was associated with degeneration and destruction of myocardial cells. Nests of *T. cruzi* amastigotes were seen in six rabbits (35.3%): four infected with Y; one with CL and one with Er.

Initial fibrosis (VmF) occurred in the myocardium in only one rabbit, infected with Er. None

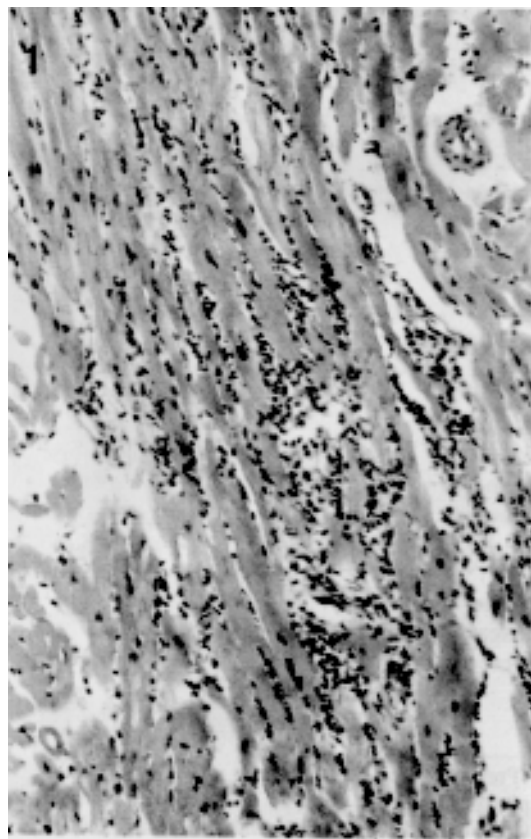


Fig. 1: rabbit myocardium in the acute phase (23 days of infection by Ernane strain): acute multifocal confluent (zonal) myocarditis characterized by endomysial mononuclear exudate, associated to destruction of cardiac fibrocytes. H&E x200.

TABLE
Inflammatory lesions of the heart, digestive tract and skeletal muscles in the different groups of experimentally chagasic and in the control rabbits

Phase	Strain	Total	Heart															DT	SM									
			Inflammatory exudate					Myocarditis					Epi-car ditis															
			Vmf	MF	MoF	SF	Z	D	Total	Vmf	MF	MoF	SF	Z	D	Total	Vmf			MF	MoF	SF	Z	D	Total			
Acute	Y	6	-	3	3	-	-	-	-	-	-	-	-	-	-	-	-	-	-	-	-	-	-	-	4	-	1	
	CL	6	1	5	-	-	-	-	-	-	-	-	-	-	-	-	-	-	-	-	-	-	-	-	-	1	-	1
	Er	5	-	2	1	1	-	-	-	-	-	-	-	-	-	-	-	-	-	-	-	-	-	-	-	3	2	1
	Total	17	1	8	5	1	1	-	-	-	-	-	-	-	-	-	-	-	-	-	-	-	-	-	-	8	2	3
Recent chronic	Y	5	1	1	-	-	1	-	-	-	-	-	-	-	1	-	1	-	-	-	-	-	-	-	-	1	1	-
	Er	1	-	-	-	1	-	-	-	-	-	-	-	-	1	-	1	-	-	-	-	-	-	-	-	-	-	-
	Total	6	1	1	-	2	-	4	-	-	-	-	-	-	2	-	2	-	-	-	-	-	-	-	-	1	1	-
Late chronic	Y	17	1	9	2	-	2	-	14	3	-	1	-	1	-	5	2	2	1	-	2	-	7	3	3	2	3	2
	CL	17	4	10	-	-	-	-	14	-	-	-	-	-	-	-	4	-	-	-	-	-	4	5	3	3	3	
	Er	14	2	4	-	-	-	-	6	-	-	-	-	-	-	-	3	1	-	-	-	-	4	1	3	-	-	
	Total	48	7	23	2	-	2	-	34	3	-	1	-	1	-	5	9	3	1	-	2	-	15	9	9	5	5	
Total	71	9	32	7	1	5	-	54	4	-	1	-	3	-	8	9	3	1	-	2	-	15	18	12	8	8		
Control	12	2	-	-	-	-	-	2	-	-	-	-	-	-	-	-	-	-	-	-	-	-	-	-	1	1	-	

Acute phase: less than 3 months of infection; recent chronic phase: between 3 and 6 months of infection; late chronic phase: later than 6 months of infection; VmfF: very mild focal - 1 to 2 foci in 100 high power fields (f/100 HPF); MF: mild focal - 3 to 10 f/100 HPF; MoF: moderate focal - 11 to 25 f/100 HPF; SF: severe focal - over than 25 f/100 HPF; Z: zonal - confluence of several foci; D: diffuse - confluence of large areas; DT: digestive tract; SM: skeletal muscle; Er: Ermane strain of *T. cruzi*; -: no case.

had advanced fibrosis.

Epicarditis, distinguished by mononuclear infiltrate with or without neutrophils and eosinophils, appeared in eight rabbits (47.1%), four infected with Y, one with CL and three with Er strains. Only one animal showed a focus of mononuclear infiltration in the endocardium .

In the digestive tract it was evidenced myositis, pointed out by mild focal infiltration of mononuclear cells on the muscularis propria, in two animals infected with Er. Signs of ganglionitis of the myoenteric plexus were not observed.

Focal myositis in the skeletal muscle was seen, characterized by little foci of mononuclear infiltrate and destruction of muscle cells, in three rabbits infected with Y, CL and Er strains.

Parasites were seen only in the myocardium and only in the acute phase.

Recent chronic phase - Among the six animals investigated in the recent chronic phase, four (66.7%) showed myocarditis with leukocytic infiltrate qualitatively similar to that seen in the acute phase varying from VmF to Z (Table) In two animals, besides the mononuclear exudate and the extensive myocardial destruction, there was initial fibrosis of Z extension (Fig. 2). None of them presented advanced fibrosis.

Epicarditis, pointed out by focal mononuclear infiltration, occurred in one rabbit (16.7%) inoculated with Y strain. No endocardial lesions were seen.

The digestive tract presented exclusively mild focal myositis involving the esophagus and stomach of one animal infected with Y. In the stomach, the process also reached a small area of the myoenteric plexus (Fig. 3).

The skeletal muscles did not show any histologic alteration.

Late chronic phase - Among 48 animals submitted to necropsy during the late chronic phase, 34 (70.8%) presented myocarditis characterized by mononuclear, mainly endomysial, exudate and degenerative and necrotic phenomena, similar to those observed in the former groups, varying from VmF to Z (Table). Nevertheless in 14 animals (41.2%), the myocardial inflammation acquired a fibrous feature (Fig. 4). The intensity of the cellular infiltration and fibrosis had great variability, as well as the degree of association between these two phenomena. In three others rabbits, one infected with Y and two infected with Er strains, only mild focal fibrosis without infiltrate was observed. The fibrosis was endomysial and perimysial, being of the advanced type in the great majority of cases and varying from VmF to Z (Table). Initial fibrosis, in addition to advanced ones, was present in five animals (10.4%), varying from VmF to Z (Table).

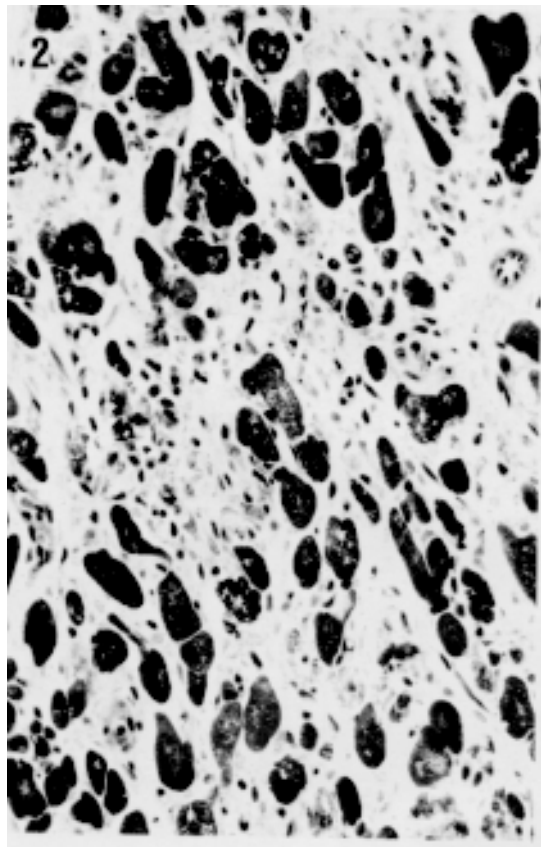


Fig. 2: rabbit myocardium in the recent chronic phase (four months of infection by Y strain): multifocal confluent (zonal) myocarditis with initial fibrosis; proliferation of fusiform cells, probably fibroblasts, with young collagen deposition, replacing the dead myocardial cells. Gomori' trichrome x400.

The most severe case of myocarditis was found in a rabbit that died spontaneously in the 6th month of infection by Y strain. In this case, the myocardium showed intense multifocal, confluent (Z), mononuclear infiltrate, with severe myocytolysis and confluent (Z) foci of fibrosis of the initial and advanced type. Another rabbit, with 12 months of infection by Y strain, also showed significant Z fibrosis of the advanced type, but with less severe inflammatory exudate and no initial fibrosis. It is noteworthy that one rabbit died suddenly due to right ventricle tip rupture and hemopericardium. In that area, the heart showed more severe myocarditis.

Chronic epicarditis occurred in nine animals (18.8%): three were infected with Y, five with CL and one with Er strains. The epicardial exudate was very mild and represented by one or few groups of mononuclear cells. Subepicardiac nervous ganglia were normal.

In the digestive tract, focal myositis, characterized by mononuclear infiltrate in the muscularis

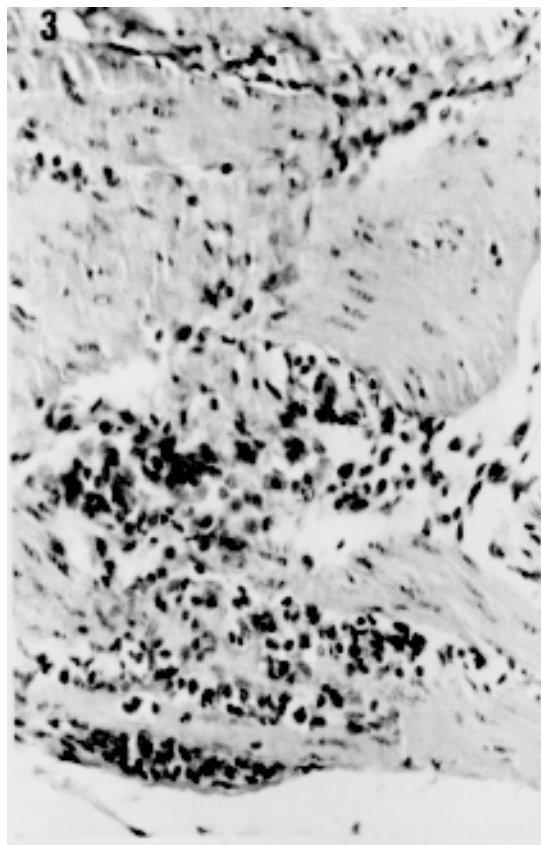


Fig. 3: rabbit gastric muscularis propria in the recent chronic phase (three months of infection by Y strain): focal myositis characterized by mononuclear and neutrophil infiltration. H&E x400.

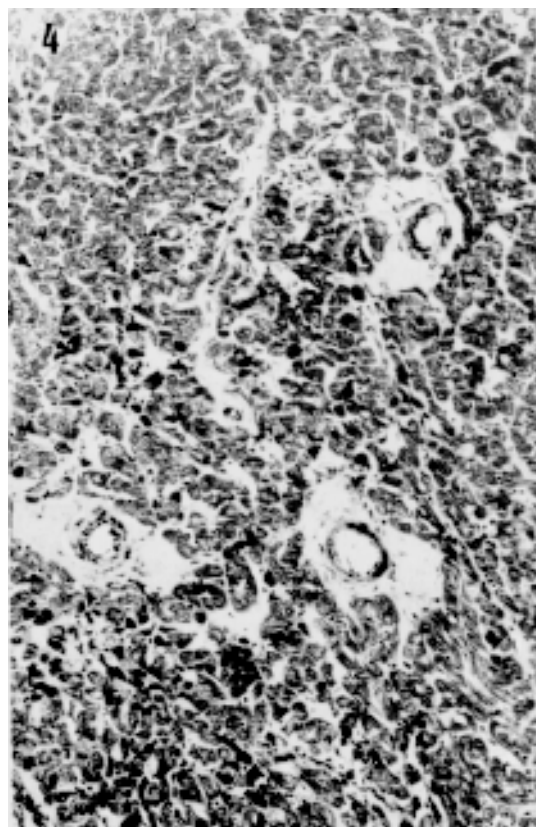


Fig. 4: rabbit myocardium in the late chronic phase (six months of infection by Y strain): multifocal confluent (zonal) myocarditis with perimysial and endomysial fibrosis, with heavy deposition of dense collagen (advanced fibrosis). Gomori' trichrome x200.

propria, was found in the esophagus of five animals, three infected with Y strain and two other with CL strain; in the stomach of three rabbits, one infected with CL strain and two other with Er strain; in the cecum of one animal inoculated with Er strain; and in the colon of one, infected with CL strain. Muscular fibrosis occurred in the esophagus of one animal infected with Y strain and in the cecum of two others, being one infected with CL and the other with Y strains. In the last animal, the fibrosis involved large area of the outer coat of the muscularis propria and the myoenteric plexus. Excepting this case, the intramural nervous system did not present lesions.

Focal skeletal myositis, pointed out by mild mononuclear exudate and injury of the muscular cells, was found in five rabbits, two infected with Y and three with CL strains.

The Table summarizes the microscopic lesions observed in heart, digestive tract and skeletal muscle of all groups in different phases of the infection.

DISCUSSION

Acute phase - The histological lesions observed in heart, digestive tract and skeletal muscle of the acute chagasic rabbits were qualitatively similar to that found in humans (Lopes et al. 1987) and in other experimental models (Andrade & Andrade 1979, Beraldo 1987, Chapadeiro et al. 1988, Bonecini-Almeida et al 1990, Ramirez et al. 1991), although generally milder and scarcer mainly in the digestive tract and in the skeletal muscles.

The acute chagasic myocarditis showed variable severity depending on the strain of the parasite: it was more severe with Er strain infection, mild to moderate in the inoculated with Y strain and milder with CL strain. The intensity of the myocardial inflammation did not present relationship with cardiac parasitism. In this aspect the rabbit model is not similar to the human acute cases submitted to necropsy, which usually present intense tissue parasitism (Lopes et al. 1987).

The scanty tissue parasitism, although present

in rabbits infected by the three strains, was observed only in that inoculated by ip route, that evidenced the highest levels of parasitemia by direct examination (Ramirez 1984, Ramirez & Brener 1987). Nevertheless, tissue parasitism did not show correlation with the parasitemia since animals inoculated with CL strain presented higher peaks of parasitemia than those infected with Y. The more frequent tissue parasitism in the animals inoculated with Y strain would be due to the virulence behavior of this strain (Andrade 1973).

In our material, the acute chagasic myocarditis seemed to be qualitatively similar to that described by others (Andrade & Andrade 1979, Figueiredo et al. 1979, Teixeira et al. 1983a, Figueiredo 1984).

The unique case of initial myocardial fibrosis among the acute chagasic rabbits perhaps should be correlated to the acute chagasic myocarditis because the morphological characteristics of this finding are similar to that observed in the recent chronic phase.

The epicarditis, although mild and found in some control animals, may be, at least in part, due to *T. cruzi*. According to Figueiredo (1984) and our data, it does not seem to occur in the acute chagasic rabbits so severely as in humans (Lopes et al. 1987).

Recent chronic phase - Although researchers who studied previously the chagasic rabbit had considered the chronic phase as a whole, and did not separate events that can occur between three and six months of the infection, we believe such separation to be helpful in order to detect possible lesions interposed between the acute and the late chronic (after six months) phases, and in this way to try to establish the morphogenesis of the pathological process.

In spite of the negativity of tissue parasitism in the animals studied in the recent chronic phase, Ramirez (1984) demonstrated the presence of parasites by the xenodiagnosis and the presence of lytic antibodies, which indicate the infection activity.

The myocarditis was less frequent in this group as compared to the acute phase, albeit the difference was not statistically significant, perhaps due to the low number of animals.

The initial fibrosis presented clear tendency to be more frequent in the recent chronic phase, but the difference in relation to the other phases did not show statistical significance. Being more severe in the recent chronic phase, and in two animals allocated in the late chronic phase but studied with six months of infection (at the boundary between the recent and later chronic phases), it is possible that the initial fibrosis represents reparative phenomenon following the myocardial destruction in the acute phase, in the cases of more

severe myocarditis.

The scarcity of the epicarditis and its similarity with the control lesions does not permit comparisons with the human chagasics. The same occurs with the digestive tract lesions. In skeletal muscle, no lesion was observed in the recent chronic phase.

Late chronic phase - The absence of tissue parasitism in the late chronic phase in our material is coincident with the majority of published observations in rabbits (Teixeira et al. 1975, Andrade & Andrade 1979, Figueiredo et al. 1979, Figueiredo 1984, Figueiredo et al. 1985, Teixeira et al. 1983a, b). Only Gonz ales Cappa et al. (1977) reported tissue parasites in this phase. In this aspect, the infected rabbits would look like the human chronic cases (Lopes et al. 1987), and other animal models (Lopes et al. 1979, Bolomo et al. 1980, Lana 1982, Bonecini-Almeida et al. 1990).

The myocarditis in the late chronic phase was significantly less frequent than in the acute one, but didn't show significant difference with the recent chronic phase. It was significantly more frequent with Y and CL strains infection and more severe in two animals inoculated with Y strain. It is important to stress that the Er strain, that was involved with the more severe acute myocarditis, produced only mild myocardial lesions in the late chronic phase. Such fact seems to indicate that the intensity of the chronic chagasic myocarditis may be at least in part due to the strain behavior with regard to a host, and thus it would not be so dependent on the acute lesions intensity.

The advanced myocardial fibrosis, with endomysial and perimysial localization, just emerged in the late chronic phase, and was a little more frequent and intense (but without statistical significance) in the infected with Y, in comparison to CL and Er inoculated animals. Between the latter, practically there was no difference. Taking in account only the animals that presented myocarditis, the frequency of advanced myocardial fibrosis was similar in the infected with Y and Er strains.

Confronting the literature data, in our experiment we observed a more expressive chronic myocarditis than Andrade and Andrade (1979), but less significant than that achieved by others (Figueiredo et al. 1979, Teixeira et al. 1975, 1983a, b). The divergence with the last ones may be due in part to evaluation criteria, but it seems to originate chiefly from the differences between the rabbits' races, the strains of *T. cruzi* used and their maintenance medium. That researchers utilized New Zealand white or inbred III/J rabbits and mainly the Ernestina strain of *T. cruzi* maintained in fetal rabbit tissue culture. Regarding to fibrosis, our findings in rabbits agree with that of Andrade

(1973) in mice: fibroblastic proliferation (called initial fibrosis in the present investigation) was seen at 90 to 120 days of infection and fibrosis (advanced fibrosis in our designation) was present only after the 6th month.

Although there are no reports on epicarditis in chronic chagasic rabbits, we observed this lesion also in the chronic phase, that was significantly less frequent than in the acute phase.

In our experimental condition, the rabbit did not reproduce the severe digestive tract lesions frequently observed in human chronic chagasic patients as well in the same animal by other investigators (Teixeira et al. 1975, Rezende Filho et al. 1979, Figueiredo 1984). Again, it is probable that the differences between their finds and ours was dependent on the type and/or the source or *T. cruzi* strains and/or the host.

Regarding the skeletal muscles of the chronic chagasic rabbits, our findings agree with those of other investigators (Teixeira et al. 1983a, b, Figueiredo 1984).

It was not detected histopathological differences among rabbits infected by MTry, BTry and TcTry.

In conclusion, in the experimental conditions established in our research, the rabbit model was able to reproduce a chronic focal, endomyxial and perimyxial myocarditis, with fibrous feature, qualitatively similar to that observed in human cases but with low potential to develop the more severe forms of chronic myocarditis, and showed only mild histological lesions in digestive tract and skeletal muscles. In the majority of the animals, the myocarditis was mild and similar to that described in the indeterminate form of the human chagasic patients. Thus, the rabbit did not behave as an ideal model for study of the chagasic infection. Nevertheless, as it reproduced some of the lesions described in the heart of humans naturally infected with *T. cruzi*, mainly in the indeterminate form, this animal may be useful for the study of some aspects of the Chagas' disease.

ACKNOWLEDGMENTS

To Prof. Edison Reis Lopes (Faculdade de Medicina do Triângulo Mineiro) and Prof. Ademir Rocha (Universidade Federal de Uberlândia) for critical revisions and suggestions, and to Prof. Gisele Pianetti (Faculdade de Medicina do Triângulo Mineiro) for collaboration with the English version.

REFERENCES

- Andrade SG 1973. *Caracterização de cepas do Trypanosoma cruzi isoladas no Recôncavo Baiano: contribuição ao estudo da patologia geral da doença de Chagas em nosso meio*. MSc Thesis. Universidade Federal da Bahia, Salvador, 123pp.
- Andrade ZA, Andrade SG 1979. Patologia, p. 199-248. In Z Brener, Z Andrade (eds). *Trypanosoma cruzi e doença de Chagas*. Guanabara Koogan, Rio de Janeiro.
- Aretz HT 1987. Myocarditis: the Dallas criteria. *Human Pathology* 18: 619-624.
- Beraldo PSS 1987. *Sobre a infecção chagásica experimental no rato; estudo eletrocardiográfico seriado e funcional autônomo do coração, correlacionado à histopatologia*. MSc Thesis. Universidade de Brasília, Brasília, 178 pp.
- Bolomo N, Milei J, Cossio PM, Segura EL, Languens RP, Fernandez LM, Arana RM 1980. Experimental Chagas' disease in South American primate (*Cebus sp.*). Buenos Aires, *Medicina* 40: 667-672.
- Bonecini-Almeida M, Galvão-Castro B, Pessoa MHR, Pirmez C, Laranja F 1990. Experimental Chagas' disease in rhesus monkey - I. clinical, parasitological, hematological and anatomo-pathological studies in the acute and indeterminate phase of the disease. *Mem Inst Oswaldo Cruz* 85: 163-171.
- Brener Z, Ramirez LE 1985. Modelo crônico da doença de Chagas experimental, p. 23-28. In JR Cançado, M Chuster (eds). *Cardiopatía chagásica*. Fundação Carlos Chagas, Belo Horizonte.
- Chapadeiro E, Beraldo PSS, Jesus PC, Oliveira Jr WP, Junqueira Jr LF 1988. Lesões cardíacas em ratos Wistar inoculados com diferentes cepas de *Trypanosoma cruzi*. *Rev Soc Bras Med Trop* 21: 95-103.
- Chiari E, Tafuri WL, Bambirra EA, Rezende MM, Ribeiro TO, Castro LP, Salgado JA, Amaral de Padua RA 1980. The rabbit as a laboratory animal for studies on Chagas' disease; research note. *Rev Inst Med Trop São Paulo* 22: 207-208.
- Figueiredo F 1984. *Infecção experimental de coelhos com Trypanosoma cruzi; aspectos de parasitologia, imunologia e patologia*. MSc Thesis. Faculdade de Medicina de Ribeirão Preto da Universidade de São Paulo, Ribeirão Preto, 119 pp.
- Figueiredo F, Macedo V, Teixeira ARL 1979. Experimental model for chronic Chagas' disease, p. 18. In International congress on Chagas' disease, Anais, Rio de Janeiro, Instituto Oswaldo Cruz.
- Figueiredo F, Rossi MA, Ribeiro dos Santos R 1985. Evolução da cardiopatía experimentalmente induzida em coelhos infectados com *Trypanosoma cruzi*. *Rev Soc Bras Med Trop* 18: 133-141.
- González Cappa S, Lazzari J, Segal A, Katzin A, Mistchenko A, Languens RP, Elizari M 1977. Infección experimental del conejo com *Trypanosoma cruzi* - II. Correlación entre el electrocardiograma y la histopatología. Buenos Aires, *Medicina* 37: 508.
- Lana M 1982. *O cão como modelo experimental para o estudo da doença de Chagas*. PhD Thesis. Instituto de Ciências Biológicas da Universidade Federal de Minas Gerais, Belo Horizonte, 207 pp.
- Lopes ER, Chapadeiro E, Tafuri WL, Prata AR 1987. Doença de Chagas, p. 1.047-1.065. In ER Loper, E Chapadeiro, P Raso, WL TAFURI (eds). *Bogliolo Patologia*. 4th ed. Guanabara Koogan, Rio de Janeiro.

- Lopes ER, Pires LL, Chapadeiro E, Tafuri WL, Prata AR 1979. Estudo anatomopatológico das vísceras de cães artificial e naturalmente infectados com o *T. cruzi*. In 15º Congresso da Sociedade Brasileira de Medicina Tropical, Campinas.
- Ramirez LE 1984. *O coelho como modelo experimental no estudo da doença de Chagas crônica*. PhD Thesis. Instituto de Ciências Biológicas da Universidade Federal de Minas Gerais, Belo Horizonte, 186 pp.
- Ramirez LE, Brener Z 1987. Evaluation of the rabbit as a model for Chagas' disease - I. Parasitological studies. *Mem Inst Oswaldo Cruz* 82: 531-536.
- Ramirez LE, Lages-Silva E, Chapadeiro E 1991. Infecção do hamster pelo *Trypanosoma cruzi*. *Rev Soc Bras Med Trop* 24: 119-120.
- Rezende Filho J, Figueiredo F, Teixeira ARL 1979. Megacolon syndrome in rabbits with chronic Chagas' disease. p. 20. In International congress on Chagas' disease, Anais, Rio de Janeiro, Instituto Oswaldo Cruz.
- Taylor CR 1986. Staining protocols and practical procedures, p. 365-367. In CR Taylor. *Immunomicroscopy: a diagnostic tool for the surgical pathologist*. Saunders, Philadelphia.
- Teixeira ARL, Teixeira ML, Santos-Buch CA 1975. The immunology of experimental Chagas' disease - IV. Production of lesions in rabbits similar to those of chronic Chagas' disease in man. *Am J Path* 80: 163-180.
- Teixeira ARL, Figueiredo F, Rezende Filho J, Macedo V 1983a. Chagas' disease; a clinical, parasitological, immunological, and pathological study in rabbits. *Am J Trop Med Hyg* 32: 258-272.
- Teixeira ARL, Junqueira Jr LF, Solórzano E, Zappalá M 1983b. Doença de Chagas experimental em coelhos isogênicos III/J; I. Fisiologia das arritmias e da morte súbita do chagásico. *Rev Assoc Méd Bras* 29: 77-83.
- World Health Organization 1984. Report of the Scientific Working Group on the Development and Evaluation of Animal Model for Chagas' Disease. WHO, Geneva.