







The Using Virtual Computer-Assisted Planning in Orthognathic Surgery: A Systematic Review and Meta-Analysis

Samira Jamali¹, Sobhan Pourarz², Navid Nasrabadi³, Hashem Ahmadizadeh⁴, Mohammad Khorram⁵, Maryam Darvish⁶

¹Department of Endodontics, Stomatological Hospital, College of Stomatology, Xi'an Jiaotong University, Shaanxi, PR China.

²Department of Oral and Maxillofacial Surgery, School of Dentistry, Isfahan University of Medical Sciences, Isfahan, Iran.

³Department of Endodontics, School of Dentistry, Shahid Beheshti University of Medical Sciences, Tehran, Iran.

⁴School of Dentistry, Tehran University of Medical Sciences, Tehran, Iran.

⁵Golpayegan Health Center, Isfahan University of Medical Sciences, Isfahan, Iran.

⁶Department of Endodontics, School of Dentistry, Kerman University of Medical Sciences, Kerman, Iran.

Author to whom correspondence should be addressed: Samira Jamali, Department of Endodontics, Stomatological Hospital, College of Stomatology, Xi'an Jiaotong University, Shaanxi 710004, PR China. Phone: +86 2982655450. E-mail: samira.jamali90@yahoo.com.

Academic Editors: Alessandro Leite Cavalcanti and Wilton Wilney Nascimento Padilha

Received: 07 November 2019 / Accepted: 20 March 2020 / Published: 08 April 2020

How to cite this article: Jamali S, Pourarz S, Nasrabadi N, Ahmadizadeh H, Khorram M, Darvish M. The using virtual computer-assisted planning in orthognathic surgery: a systematic review and meta-analysis. *Pesqui Bras Odontopediatria Clín Integr.* 2020; 20:e5381. <https://doi.org/10.1590/pboci.2020.064>

Abstract

Objective: To use virtual computer-assisted planning in orthognathic surgeries through meta-analysis and systematic review. **Material and Methods:** This search took place between 2010 and 2019. The databases searched in this domain included MEDLINE, PubMed, Cochrane Library, Embase, ISI, and Google scholar. Accordingly, the abstracts of the articles were initially reviewed and the ones that had the most coordination with the study objectives were selected. Then, the full texts of the articles were examined; and finally, five studies were selected. In addition to reviewing the related literature, the results were extracted and entered into the meta-analyzer Stata V.14 to summarize the final results. **Results:** The sample size in this study was at a range from 6 to 28 patients and a total number of 85 patients had participated in the given investigations. As well, CT and CBCT were selected as imaging methods. Clinical imaging and analysis were also employed in computer-assisted planning in all five studies. Subsequently, surgical planning was performed and the virtual splint was designed while the planning time was 225 minutes and 145 minutes in two studies. **Conclusion:** The present results supported computer-assisted planning and the quality of scientific evidence.

Keywords: Orthognathic Surgery; Cone-Beam Computed Tomography; Diagnostic Imaging.

Introduction

As a unique facial surgery, orthognathic surgery can significantly improve the patient's appearance and occlusal function and also affect the patient's sense of self and well-being. In modern orthognathic surgery, successful results depend on a close collaboration between orthodontists and surgeons in all treatment steps, ranging from preoperative planning to occlusion finalization [1].

The stone model surgery has been conventionally used to perform orthognathic surgery that involves mandible into stone models and translation of the desirable clinical movements of the maxilla, which are cut and then repositioned into the class-I occlusion that generate a splint. Despite being significantly time-consuming, the model surgery is a reproducible and precise surgical method of correcting non-cleft patients as well as dentofacial skeleton in the cleft. Virtual surgical planning (VSP) and 3D imaging have also become popular in orthognathic surgery with the emergence of computed VSP, and tomography scanning is thus quickly replacing traditional model surgery in many regions of Iran and across the globe. So, whether or not the feasibility and application of virtual model surgery can obviate the need for conventional model surgery in both academic and private settings should be determined [2,3].

Recent decades have also witnessed the evolution of planning in orthognathic surgery [4]. Moreover, 3D virtual orthognathic planning has been proved as a cost-effective, reliable, and efficient alternative [4]. The widespread industrial applications of CAD/CAM technology have further generated both the desire and the momentum for the translation of 3D images into physical prototype models. Meanwhile, computed tomography (CT) imaging has introduced 3D anatomy of the living humans [5].

Over the past decades, the effect of the CAD/CAM technology, particularly the rapid prototyping (RP) technology, combined with the availability of 3D medical images, i.e., CT, medical image analysis software, and magnetic resonance imaging (MRI) have transformed clinical practices in craniomaxillofacial surgery. Nowadays, these applications range from customized fabricated craniofacial prosthetic implants to occlusal guides in orthognathic surgical procedures [6].

Therefore, the present systematic review and meta-analysis were conducted to evaluate the use of virtual computer-assisted planning in orthognathic surgery.

Material and Methods

The present systematic review followed the preferred reporting items for meta-analyses and systematic reviews as well as reporting guidelines. The study protocol was also developed via evaluating 8 selected studies systematically. In this regard, data extraction forms were developed after obtaining the initial results of the search.

Search Strategy

This search took place between 2010 and 2019. The databases searched for this purpose included Medline, PubMed, Cochrane Library, Embase, ISI, and Google scholar. To this end, the abstracts of the articles were initially reviewed and the ones that had the most coordination with the study objectives were selected. Then, the full-texts of the articles were examined and finally, 5 studies were selected (Figure 1).

Inclusion Criteria

The inclusion criteria were as follows: A sample size of at least 5; All clinical trials larger than case studies; Conventional orthognathic surgeries fulfilled to correct dental and facial development abnormalities;

and Evaluation of accuracy and precision through comparing 3D virtual surgical plans with actual 3D surgical outcomes. Exclusion Criteria: Case reports involving below 5 patients; Surgeries performed using a distraction apparatus; and Surgeries associated with cancer, trauma, and cleft palate.

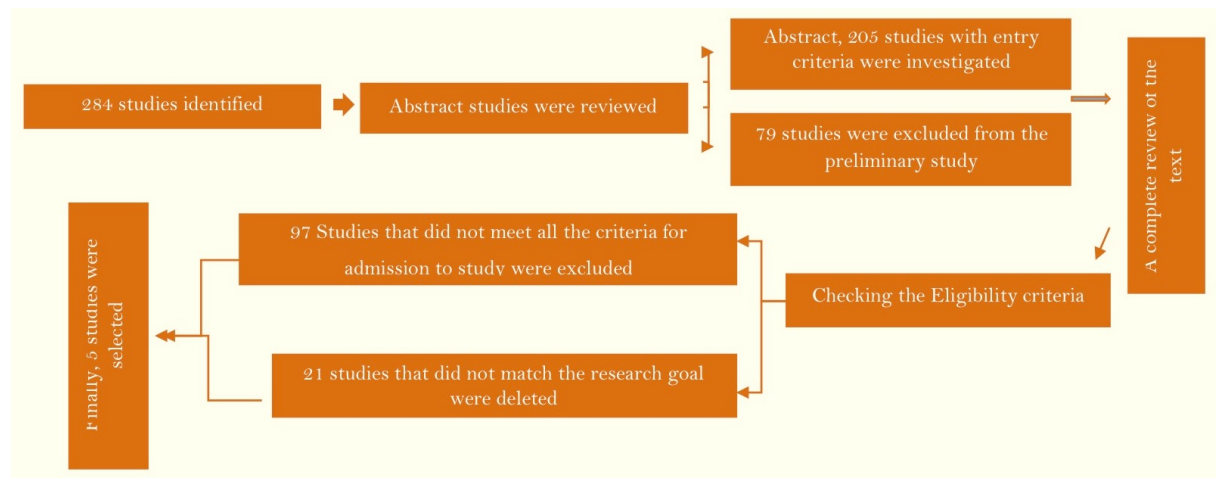


Figure 1. Study attrition diagram.

Data Extraction and Analysis Procedure

Evaluation the risk of bias - RCTs were surveyed utilizing the Cochrane Collaboration tool for evaluating risk of bias and the risk of bias of non-randomized studies was evaluated utilizing the methodological list for non-randomized studies. The subsequent data were extracted from the research included: study, years, number of patients, imaging of dental arches, software used for virtual planning, surgical splint, planning time, conclusions, postoperative period and mean of general, maxilla, mandible and mandibular condyle. Calculate the risk ratio (RR) and 95% confidence interval (CI). Forest plots in meta-analysis assessed using a commercially available software program (Comprehensive Meta-Analysis Stata, V14).

Results

In this study, the sample size was at a range from 6 to 28 patients and a total number of 85 patients had participated in the investigations. The imaging methods were CT and CBCT. Clinical imaging and analysis had also been used in computer-assisted planning in all the 5 studies [7-11]. Likewise, surgical planning had been performed and the virtual splint had been designed while the planning time was 225 minutes and 145 minutes in two studies (Table 1).

Moreover, the systematic review suggested the precision of computer-assisted planning in orthognathic surgery as follows (Table 2): 1. Maxilla: Sagittal<1 mm (1-0.14), Transversal<0.8 mm (0.8-0.04), Vertical: <1.2 mm (1.2-0.23); 2. Mandible: Sagittal<1.1 mm (1.1-0.13), Transversal<0.8 mm (0.8-0.17), Vertical<0.6 mm (0.6-0.33); 3. Chin: Sagittal<1 mm (1-0.3), Transversal<0.8 mm (0.8-0.76), Vertical: <0.6 mm (0.6-0.25); 4. Mandibular condyle: Sagittal<1 mm (0.18 mm), Transversal<0.8 mm (0.07), Vertical: <0.6 mm (0.13 mm)

The surgical splint in all 5 studies was surgical splint and the software used for virtual planning in two studies [7,10] was SimPlant OMS (Materialise, Leuven, Belgium). The postoperative period in two studies had lasted 3 months [7,11], and that was six weeks [8], 3 days [9], 6 months [10] in other investigations. Quality analysis of the studies included was illustrated in Tables 3 and 4 and Figure 2.

Table 1. Computer-aided surgery—articles included in the review.

Author	Number of Patients	Imaging Method	Imaging of Dental Arches	Software Used for Virtual Planning	Surgical Splint	Planning Time	Conclusions
Centenero et al. [7]	16	CT, CBCT	A scan of the plaster model	SimPlant Pro OMS 10.1 (Materialise Dental, Leuven, Belgium)	Occlusal Splint	NA	The Software program used in the study is reliable for 3D planning and for the manufacture of surgical splints using CAD/CAM technology.
Luebbers et al. [8]	15	CBCT	A Scan of bite registration with reference points for image fusion with CT	Amira (Visage Imaging GmbH, Germany)	Occlusal Splint	255 min	The accuracy of the designed intermediate splint met the requirements for bimaxillary surgery under clinical circumstances.
Li et al. [9]	6	CT	CT with bite registration	SurgiCase CMF 5.0 (Materialise, Leuven, Belgium) Unigraphics NX 7.5 (Siemens PLM Software, TX, USA)	Occlusal Splint Bone Splint (Maxilla)	145 min	CAD/CAM templates provide a reliable method for transfer of maxillary surgical planning, which may be a useful alternative to the intermediate splint technique.
Zinser et al. [10]	28	CT, CBCT	A scan of plaster model	SimPlant Pro OMS 10.1 (Materialise Dental, Belgium)	Occlusal Splint Bone Splint	NA	CAD/CAM splints and surgical navigation provide a reliable, innovative, and precise approach for the transfer of virtual orthognathic planning.
Shaheen et al. [11]	20	CT, CBCT	Virtual 3D planning-printing	The software to design the intermediate and final splints (Proplan software - Materialise, Leuven, Belgium). The designed splints were printed in biocompatible material using Objet Connex 350 (Stratasys, Eden Prairie, Minnesota, USA) with slice thickness of 0.03 mm.	Occlusal Splint	NA	19 out of the 20 intermediate digitally 3D printed splints were clinically accepted

CT: Computed Tomography; CBCT: Cone Beam Computed Tomography; NA: No information provided by the authors.

Table 2. Orthognathic surgery accuracy of the studies included.

Study	Postoperative Period	General Mean (SD)	Maxilla Mean (SD)	Mandible Mean (SD)	Chin Mean (SD)	Mandibular Condyle Mean (SD)
Centenero et al. [7]	3 Months	Soft tissue 0.7240.310 (0.053–0.970) ICCa Angles: 0.8670.164 (0.624–0.970) ICCa Lines: 0.6080.368 (0.053–0.947) ICCa Bone tissue 0.7220.246 (0.350–0.964) ICCa Angles: 0.6550.249 (0.350–0.910) ICCa Lines: 0.9220.059 (0.880–0.964)	OcPl: 0.375 (0.178 to 0.739) ICCa (FHP)	MdPl: 0.608 (0.162 to 0.849) ICCa (FHP)	MdPl: 0.608 (0.162 to 0.849) ICCa (FHP)	NA
Luebbbers et al. [8]	6 Weeks	NA	Sagittal: 0.50.22 mm (0 to 0.9) Vertical: 0.570.35 mm (0.2 to 1.4) Transversal: 0.380.35 mm (0 to 1.3)	NA	NA	NA
Li et al. [9]	3 Days	<1mm (0.03–1.7)	<1mm (0.03–1.7)	NA	NA	NA
Zinser et al. [10]	6 Months	NA	Sagittal: <0.14 mm (VS) Sagittal: <0.61 mm (CS) Vertical: <0.23 mm (VS) Vertical: <1.3 mm (CS) Transversal: <0.04 mm (VS) Transversal: <0.43 mm (CS) MxPl: 0.358 (FHP)-0.038 (MFP) (VS) MxPl: 0.638 (FHP) 0.468 (MFP)(CS) OcPl: 0.028 (FHP) 0.038 (MFP) (VS) OcPl: 0.958 (FHP)-0.368 (MFP) (CS) Soft Tissue Sagittal: <1.39 mm (VS) Sagittal: <2.1 mm (CS) Vertical: <2.52 mm (VS) Vertical: <4.3 mm (CS) Transversal: <1.2 mm (VS) Transversal: <2.5 mm (CS)	Sagittal: <0.17 mm (VS) Sagittal: <0.94 mm (CS) Vertical: <0.33 mm (VS) Vertical: <1.8 mm (CS) Transversal: <0.17 mm (VS) Transversal: <0.58 mm (CS) MdPl: 0.588 (FHP) - 0.618 (MFP) (VS) MdPl: 10.258 (FHP) - 1.18 (MFP) (CS) Soft Tissue Sagittal: 0.09 mm (VS) Sagittal: 0.74 mm (CS) Vertical: <0.48 mm (VS) Vertical: 1.5 mm (CS) Transversal: 1.1 mm (VS) Transversal: 1.3 mm (CS)	NA	Sagittal: 0.18 mm (VS) Sagittal: 0.61 mm (CS) Vertical: 0.13 mm (VS) Vertical: 0.5 mm (CS) Transversal: 0.07 mm (VS) Transversal: 0.5 mm (CS) CoL-ZFS: 0.058 (VS) CoL-ZFS: 0.518 (CS)
Shaheen et al. [11]	3 Months	NA	OcPl: 0.275 (0.178 to 0.739) ICCa	NA	NA	NA

NA: No information provided by the authors; ICC: Intra-Class Correlation Coefficient; OcPl: Occlusal Plane; FHP: Frankfort Horizontal Plane; VS: Virtual Splint; CS: Classic Splint; MdPl: Mandibular Plane; CoL: Condylar Line.

Table 3. Quality analysis of the studies included.

Quality Criteria for Studies	Study				
	[7]	[8]	[9]	[10]	[11]
Sample Randomization	No	No	No	No	No
Comparison Between Treatments	No	No	No	Yes	No
Blind Assessment	Yes	Yes	No	No	No
Validation of Measurements	No	Yes	Yes	Yes	No
Statistical Analysis	No	Yes	Yes	Yes	Yes
Defined Inclusion and Exclusion Criteria	Yes	Yes	Yes	Yes	Yes
Report on Follow-Up	Yes	Yes	Yes	Yes	Yes
Risk of Bias Assessment	High	High	High	Medium	High

Risk of bias assessment: High = 0-5 'Yes'; Medium = 5-6 'Yes'; Low = 7 'Yes'.

Table 4. Studies selected for meta-analysis.

Study	95% Confidence Interval		% Weight
	Upper	Lower	
Centenero et al. [7]	10.800	-8.800	22.78
Luebbers et al. [8]	11.800	-7.800	22.78
Li et al. [9]	12.800	-6.800	22.78
Zinser et al. [10]	15.760	-7.760	15.82
Shaheen et al. [11]	16.760	-6.760	15.82

Heterogeneity Chi-squared = 0.33 (d.f. = 4), p = 0.988; I-squared (variation in ES attributable to heterogeneity) = 0.0%; Test of ES=0 ; z= 1.17, p = 0.242.

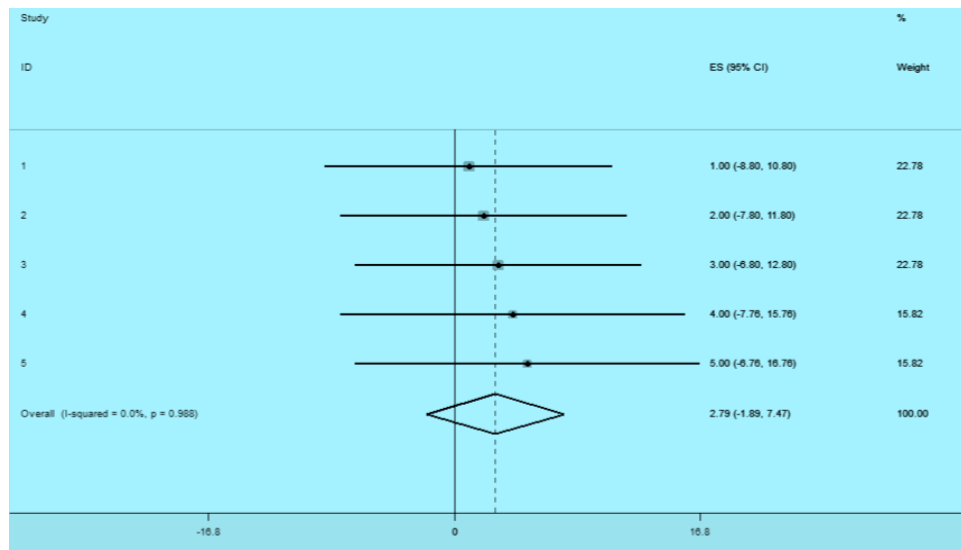


Figure 2. Forest plots showed evaluate virtual computer-assisted planning in orthognathic surgery.

Discussion

This study was performed using 3D planning to investigate the accuracy of SimPlant to Pro OMS 10.1 (Materialize, Leuven, Belgium) in terms of postoperative predictions and manufacture of surgical splints using the CAD/CAM technology. This program could help with diagnoses, as did other 3D virtual imaging systems [12].

In this regard, previous authors used CAD/CAM surgical splints to send 3D treatment plans to the CAD/CAM center and manufacture stereolithographic surgical splints [7]. The study software was comprised of algorithms to obtain the correct occlusion. The same study, as in the preoperative planning step, was also conducted on a group of patients 3 months after surgery, and the second set of DICOM-format images was derived using CBCT or CT, which were transferred to the CAD/CAM center wherein 3D images were

obtained following segmentation, which enabled postoperative measurements to be contrasted with the predicted results acquired from the preoperative data. These authors used 3D planning as a working technique included in clinical practices. The next step in evaluating computerized 3D treatment planning was to use the CAD/CAM technology for manufacturing surgical splints used in orthognathic surgery, which could help in obtaining 3D physical structures from 3D images [13]. Some authors also argued that the given technique did not need traditional model surgery, recording of the CAD/CAM splint, and scanning of dental casts [9].







Furthermore, it has been suggested 3D planning and fabrication of intermediate splints for bimaxillary orthognathic surgery [11]. Other studies also confirmed these results [14,15]. In this regard, the designed intermediate splint was accurate enough to satisfy the requirements of bimaxillary surgery [8]. Moreover, the advantages of using 3D printing methods in orthognathic surgery included a precise translation of treatment plans, patient satisfaction, and optimal functional and aesthetic outcomes [16].

It should be noted that the precision of the maxilla translation was below 1 mm in computer-assisted planning for orthognathic surgery and the rotation was reported below 1.5 mm [17]. The vertical precision of the maxilla was found to be below 1.2 mm in 3D imaging [10]. The splints used also resembled those utilized by other authors [9,10]. The differences between the two interventions could be explained by the fact that surgical splints could not be used in classic planning and that surgeons were guided by their experiences as well as certain chin plate and internal reference points. Classic planning was, therefore, not precise enough in chin surgeries, and computer-assisted planning could yield higher accuracy levels [7].

Conclusion

The software program used in the investigations included in this study was found to be reliable enough for 3D planning as well as manufacturing surgical splints using CAD/CAM technology. These results supported computer-assisted planning and the quality of scientific evidence. Finally, it was recommended to conduct further randomized clinical trials on the present subject.

Authors' Contributions

SJ	 0000-0003-3803-1235	Conceptualization, Methodology, Investigation, Formal Analysis, Writing - Original Draft Preparation and Writing - Review and Editing.
SP	 0000-0002-7900-3671	Writing - Review and Editing.
NN	 0000-0002-6365-6619	Writing - Original Draft Preparation and Writing - Review and Editing.
HA	 0000-0001-7845-2638	Writing - Review and Editing.
MK	 0000-0001-8254-3129	Writing - Review and Editing.
MD	 0000-0002-0622-4895	Formal Analysis and Writing - Original Draft Preparation.

All authors declare that they contributed to critical review of intellectual content and approval of the final version to be published.

Financial Support

None.

Conflict of Interest

The authors declare no conflicts of interest.

References

- [1] Khechoyan DY. Orthognathic surgery: general considerations. *Semin Plast Surg* 2013; 27(3):133-6. <https://doi.org/10.1055/s-0033-1357109>

- [2] Hammoudeh JA, Howell LK, Boutros S, Scott MA, Urata MM. Current status of surgical planning for orthognathic surgery: traditional methods versus 3D surgical planning. *Plast Reconstr Surg Glob Open* 2015; 3(2):e307. <https://doi.org/10.1097/GOX.0000000000000184>
- [3] Lee YC, Sohn HB, Kim SK, Bae OY, Lee JH. A novel method for the management of proximal segment using computer-assisted simulation surgery: correct condyle head positioning and better proximal segment placement. *Maxillofac Plast Reconstr Surg* 2015; 37(1):21. <https://doi.org/10.1186/s40902-015-0023-3>
- [4] Hatamleh M, Turner C, Bhamrah G, Mack G, Osher J. Improved virtual planning for bimaxillary orthognathic surgery. *J Craniofac Surg* 2016; 27(6):e568-73. <https://doi.org/10.1097/SCS.00000000000002877>
- [5] Zhao L, Patel PK, Cohen M. Application of virtual surgical planning with computer assisted design and manufacturing technology to craniomaxillofacial surgery. *Arch Plast Surg* 2012; 39:309-16.
- [6] Eufinger H, Wehmöller M, Harders A, Heuser L. Prefabricated prostheses for the reconstruction of skull defects. *Int J Oral Maxillofac Surg* 1995;24(1):104-10. [https://doi.org/10.1016/S0901-5027\(05\)80870-7](https://doi.org/10.1016/S0901-5027(05)80870-7)
- [7] Aboul-Hosn Centenero S, Hernández-Alfaro F. 3D planning in orthognathic surgery: CAD/CAM surgical splints and prediction of the soft and hard tissues results - our experience in 16 cases. *J Craniomaxillofac Surg* 2012; 40(2):162-8. <https://doi.org/10.1016/j.jcms.2011.03.014>
- [8] Sun Y, Luebbers HT, Agbaje JO, Schepers S, Vrielinck L, Lambrichts I, et al. Accuracy of upper jaw positioning with intermediate splint fabrication after virtual planning in bimaxillary orthognathic surgery. *J Craniofac Surg* 2013; 24(6):1871-6. <https://doi.org/10.1097/SCS.0b013e31829a80d9>
- [9] Li B, Zhang L, Sun H, Yuan J, Shen SGF, Wang X. A novel method of computer-aided orthognathic surgery using individual CAD/CAM templates: a combination of the osteotomy and repositioning guides. *Br J Oral Maxillofac Surg* 2013; 51(8):e239-e44. <https://doi.org/10.1016/j.bjoms.2013.03.007>
- [10] Zinser MJ, Sailer HF, Ritter L, Braumann B, Maegele M, Zöller JE. A paradigm shift in orthognathic surgery? A comparison of navigation, computer-aided designed/computer-aided manufactured splints, and "classic" intermaxillary splints to surgical transfer of virtual orthognathic planning. *J Oral Maxillofac Surg* 2013; 71(12):2151.e1-21. <https://doi.org/10.1016/j.joms.2013.07.007>
- [11] Shaheen E, Coopman R, Jacobs R, Politis C. Optimized 3D virtually planned intermediate splints for bimaxillary orthognathic surgery: a clinical validation study in 20 patients. *J Craniomaxillofac Surg* 2018; 46(9):1441-7. <https://doi.org/10.1016/j.jcms.2018.05.050>
- [12] de Tejada MJBG, Hernández-Alfaro F, Maier D, Pagès CM. Planificación virtual y diseño de férulas CAD/CAM en cirugía ortognática: una nueva era? *Rev Españ Ortod* 2005; 35(4):363-70. [In Spanish].
- [13] Gateno J, Xia JJ, Teichgraber JF, Christensen AM, Lemoine JJ, Liebschner MA, et al. Clinical feasibility of computer-aided surgical simulation (CASS) in the treatment of complex cranio-maxillofacial deformities. *J Oral Maxillofac Surg* 2007; 65(4):728-34. <https://doi.org/10.1016/j.joms.2006.04.001>
- [14] Al-Rimawi A, EzEldeen M, Schneider D, Politis C, Jacobs R. 3D printed temporary veneer restoring autotransplanted teeth in children: design and concept validation ex vivo. *Int J Environ Res Public Health* 2019; 16(3):496. <https://doi.org/10.3390/ijerph16030496>
- [15] Zhou Z, Zhao H, Zhang S, Zheng J, Yang C. Evaluation of accuracy and sensory outcomes of mandibular reconstruction using computer-assisted surgical simulation. *J Craniomaxillofac Surg* 2019; 47(1):6-14. <https://doi.org/10.1016/j.jcms.2018.10.002>
- [16] Lin HH, Lonic D, Lo LJ. 3D printing in orthognathic surgery - a literature review. *J Formos Med Assoc* 2018; 117(7):547-58. <https://doi.org/10.1016/j.jfma.2018.01.008>
- [17] Hsu SS-P, Gateno J, Bell RB, Hirsch DL, Markiewicz MR, Teichgraber JF, et al. Accuracy of a computer-aided surgical simulation protocol for orthognathic surgery: a prospective multicenter study. *J Oral Maxillofac Surg* 2013; 71(1):128-42. <https://doi.org/10.1016/j.joms.2012.03.027>