

## Description and post-operative evaluation of tie-in technique in tibial osteosynthesis in dogs<sup>1</sup>

Luis G.G.G. Dias<sup>2\*</sup>, João G. Padilha Filho<sup>2</sup>, Maria E.B.A.M. Conceição<sup>2</sup>,  
Fernanda G.G. Dias<sup>3</sup> and Virginia T. Barbosa<sup>2</sup>

**ABSTRACT.-** Dias L.G.G.G., Padilha Filho J.G., Conceição M.E.B.A.M., Dias F.G.G. & Barbosa V.T. 2018. **Description and post-operative evaluation of tie-in technique in tibial osteosynthesis in dogs.** *Pesquisa Veterinária Brasileira* 38(7):1376-1381. Setor de Cirurgia Veterinária, Departamento de Clínica e Cirurgia Animal, Faculdade de Ciências Agrárias e Veterinárias, Universidade Estadual Paulista "Julio de Mesquita Filho", Campus de Jaboticabal, Via de Acesso Prof. Paulo Donato Castellane s/n, Jaboticabal, SP 14884-900, Brazil. E-mail: [gustavogosuen@fcav.unesp.br](mailto:gustavogosuen@fcav.unesp.br)

The aim of this study was to describe and analyse the adaptability and functionality of tie-in configuration in tibial osteosynthesis in dogs. Twenty dogs with tibial fracture were included in this study. An orifice was made on the proximal tibial fragment, on the medial side, close to the tibial crest. The drill piece was angled at 45° and projected into the same orifice on the distal sense of the bone. Others orifices made with the aid of a low rotation drill and drill piece with diameter smaller than the chosen implant. After 10 days post-operative, the animals were evaluated. X-ray analysis was performed at the time of clinical examination; immediate post-operative period; and at 30, 60, 90, and 120 days post-surgery. A questionnaire was given to the owners to provide details on the post-operative period. There were no trans-operative complications or suture dehiscence up to the day of suture removal. Partial development of bone callus was observed in 20 dogs within a mean period of 76 days. Three animals showed bone consolidation within 35 days, nine by 60 days, three by 90 days, and 5 by 120 days post-operative. Dynamization was carried out in 9 animals. The surgical access to the tibial medullary canal through the orifice at the proximal medial face, by the tibial tuberosity, enables the insertion of IMP without risks to articular and peri-articular lesions in the knee in dogs.

INDEX TERMS: Post-operative evaluation, tie-in technique, tibial osteosynthesis, dogs, surgery.

**RESUMO.- [Descrição e avaliação pós-operatória de técnica de osteossíntese com tie-in em tibia.]** O objetivo deste trabalho foi descrever e analisar a funcionalidade da configuração tie-in na osteossíntese de tibia em cães. Foram usados 21 cães com fratura de tibia da rotina clínica do hospital veterinário. Somente a primeira cortical (Sis) foi perfurada, em seguida a broca foi inclinada a 45° e projetada no mesmo orifício no sentido distal do osso. foram confeccionados outros orifícios com auxílio de furadeira de baixa rotação

e broca cujo diâmetro era menor que o implante escolhido. Os procedimentos radiográficos foram realizados no momento do atendimento clínico, no período pós-operatório imediato aos 30, 60, 90 e 120 dias pós-cirúrgico. Não houve nenhuma complicação transoperatória, tão pouco deiscência de sutura até o momento da retirada dos pontos de cútis. A formação parcial de calo ósseo foi evidenciada em 20 cães com tempo médio de 76 dias. Três cães obtiveram consolidação óssea em 35 dias, nove aos 60 dias, três aos 90 dias e cinco aos 120 dias de pós-operatório. Dinamizações foram realizadas em nove animais. Após a confirmação radiográfica de consolidação óssea, os implantes dos 20 animais foram totalmente removidos. Concluiu-se que o acesso cirúrgico ao canal medular da tibia canina por meio de orifício na face medial proximal, junto à tuberosidade da tibia, permite a inserção do PIM sem risco de lesões articulares e periarticulares no joelho.

TERMOS DE INDEXAÇÃO: Avaliação pós-operatória, técnica de osteossíntese, tie-in, tibia, cães, cirurgia.

<sup>1</sup> Received on July 24, 2017.

Accepted for publication on August 3, 2017.

<sup>2</sup> Setor de Cirurgia Veterinária, Departamento de Clínica e Cirurgia Animal, Faculdade de Ciências Agrárias e Veterinárias (FCAV), Universidade Estadual Paulista "Julio de Mesquita Filho" (Unesp), Campus de Jaboticabal, Via de Acesso Prof. Paulo Donato Castellane s/n, Jaboticabal, SP 14884-900, Brazil.

\*Corresponding author: [gustavogosuen@fcav.unesp.br](mailto:gustavogosuen@fcav.unesp.br)

<sup>3</sup> Universidade de Franca (Unifran), Av. Armando Salles Oliveira 201, Franca, SP 14404-600, Brazil.

## INTRODUCTION

Tibial fracture is relatively common in small animals and corresponds to 15 to 21% of long bone fractures and 11.7% of appendicular fractures in dogs (Kemper & Diamante 2010, Lacerda et al. 2013).

Several methods and implants aimed at fixing the bone fragments can be used in the osteosynthesis of long bones. These include external mobilization, intramedullary pins (IMP), stainless steel wires (cerclage), external skeletal fixators (ESF), interlocking nails, bone plates, and screws; as well as the combination of more than one technique (Johnson 2008, Piermattei et al. 2009, Popkov et al. 2014).

Fracture stabilization relies on several factors, such as individual particularities of patients, types of fracture, concomitant lesions, surgeon's ability and familiarity with the technique, and costs. Therefore, there is no optimal method of fracture stabilization, so the advantages of each technique must be maximized and disadvantages minimized (Harari 2002).

In small animals, ESF connected to an intramedullary pin (tie-in configuration) has been used in femoral and humeral osteosynthesis. This technique has several advantages and is biomechanically superior to other methods of stabilization, especially in comminute and distal fractures or both (Beck & Simpson 1999, Harari 2002, Basinger & Suber 2004). This technique has also been described in metacarpus, metatarsus (Fitzpatrick et al. 2011), and tibia (McCartney 2007).

To date, there has been only one study that evaluated the tie-in technique in tibial osteosynthesis in dogs, highlighting the novelty of this technique in this bone. Thus, the aim of this study was to describe and analyse the adaptability and functionality of tie-in configuration in tibial osteosynthesis in dogs, through monthly clinical and radiographic evaluations over a period of 120 days.

## MATERIALS AND METHODS

Twenty dogs with tibial fracture, caused by road-traffic accidents and/or falls, were included in this study. The period between the time of fracture and medical assistance, presence or absence of bone exposure, and any previous treatments were recorded.

Animals were positioned on the surgical table in lateral decubitus, with the affected limb side down. Surgical approach of the tibia was by cutaneous incision on the medial aspect and varied in extension according to the need for anatomic reduction, enabling biological osteosynthesis in some cases. An orifice was made on the proximal tibial fragment, on the medial side, close to the tibial crest, using an orthopaedic drill with 90° between the drill piece and the bone. Once the first cortical (Sis) was perforated, the drill piece was angled at 45° and projected into the same orifice on the distal sense of the bone, creating a route to facilitate the normograde introduction of the intramedullary pin (IMP). It is important to note that the diameter of the drill piece used was 1 to 1.5mm larger than the chosen IMP (Fig.1A-C).

The end of the IMP was bent using orthopaedic pliers and that, combined with the angle of the drilled orifice, enabled its introduction into the medullary canal (Fig.1D,E). A pin reamer and mallet aided in IMP insertion through the drilled orifice into the tibial medullary canal, up to fracture line. Pliers were used to

mould the IMP, undoing the angle previously created. The fracture was reduced and the IMP pushed to the limit of the tibial medullary canal and into the distal epiphyseal bone. A second pin of similar length was positioned externally and used to orientate the final position of the IMP inside the tibial medullary canal, preventing it from being too short or too long, or from penetrating the tibial tarsal joint (Fig.1F).

The drilling points for the remaining pins were chosen and orifices made with the aid of a low rotation drill and drill piece with diameter smaller than the chosen implant. The geometric configuration and the number of pins to be used were determined based on the size and weight of the animal, type of fracture, presence or absence of bone fragments, and desired degree of stability.

Once all implants had been inserted (transfixing pins and IMP), these were bent (including IMP) and bound with sterile bone cement (polymethyl methacrylate). IMP was bent at the medial face, parallel to the tibial diaphysis, and connected to the other implants with resin (Fig.2A,B). After stabilization of the bone fragments, tissue suture was performed as routinely.

The surgical wound was covered with gauze containing 1% povidone-iodine. The external apparatus was protected with gauze or hydrophilic cotton and covered with crepe bandage.

The wound was dressed daily and the skin stitches and implants cleaned using gauze soaked in saline solution followed by 1% povidone-iodine. After 10 days post-operative, the wound was dressed every 2 to 3 days, depending on the case, until complete implant removal.

Oral cephalixin (30mg/kg, every 12 hours, for 10 days) (Cefalexina 500mg, Teuto, Anápolis-GO, Brazil) and meloxicam (0.1mg/kg, every 24 hours, for 5 consecutive days) (Maxican 2mg, Ourofino, São Paulo, Brazil) were prescribed.

The dogs were kept in a restricted area; however, they were walked daily on a lead by the owners. A protective Elizabethan collar was used throughout the post-operative period.

After 10 days post-operative, the animals were evaluated according to their general clinical state, presence/absence of discharge at the site of skin suture or implant-skin interface, presence/absence of movement of the fixating apparatus or at the fracture site, and pain at palpation. Possible complications with the external fixator were also evaluated, such as breakage or loosening of implants or acrylic resin.

The moment the operated limb was able to bear weight was provided by the owners at the periodic follow-ups. The degree of weight bearing was classified into 4 categories: excellent (total weight bearing and no claudication), good (mild claudication), satisfactory (weight bearing with moderate claudication), and poor (intermittent claudication with no weight bearing).

X-ray analysis, always in two projections (craniocaudal and mediolateral), was performed at the time of clinical examination; immediate post-operative period; and at 30, 60, 90, and 120 days post-surgery. The fractures were classified according to the location and radiographic aspect, and were considered as consolidated when bone union was evident in both projections in at least three bone corticals.

The tie-in configuration was dynamized according to each case. Dynamization took place in 4 different ways: 1 = disconnection of IMP from the remaining ESF, 2 = removal of fixating implant(s) from the proximal bone fragment, leaving only the IMP connected to the implants at the distal bone fragment, 3 = complete removal

of IMP, ESF remains; and 4 = removal of all ESF implants, only MIP remains.

In some cases, the configuration was dynamized in stages, every 30 days, to coincide with the follow-ups.

A questionnaire was given to the owners to provide details on the post-operative period, behaviour of the animal towards

the ESF, classification of the degree of weight-bearing, behaviour after dynamization and/or removal of ESF, and owner satisfaction. The owners were also asked whether they would authorize the use of the same technique should another of their animals suffer tibial fracture. The answers were obtained through a telephone call within 60 days of complete removal of the tie-in configuration.

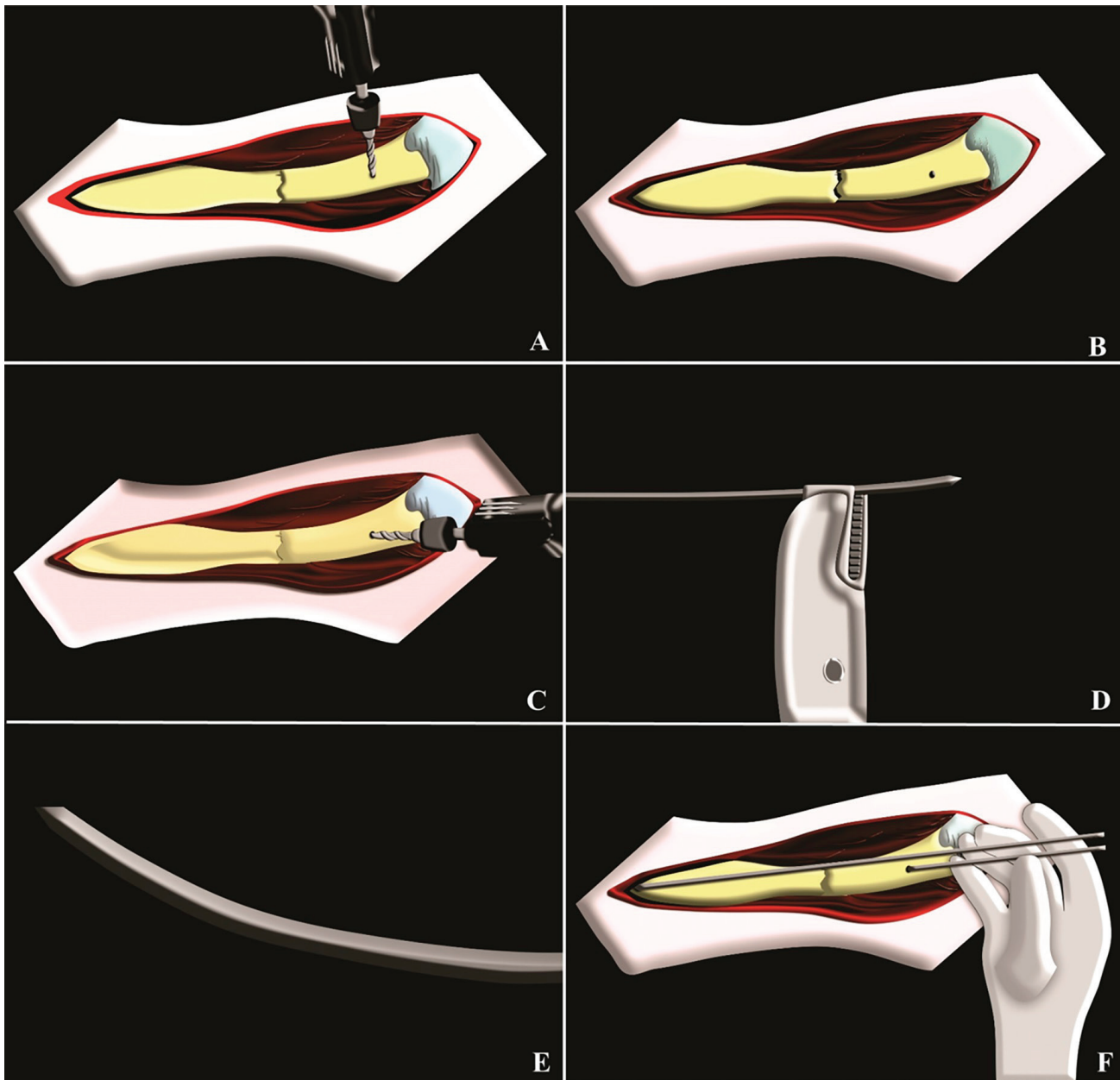


Fig.1. Schematic drawings of the execution of the tie-in osteosynthesis technique in the tibia (left) of a dog. (A) Making of the orifice in the proximal epiphysis by the medial face, close to the tibial crest, with the aid of an orthopaedic drill angled at  $90^\circ$  (drill bit and bone). Only the first cortical (sis) is perforated. (B) Final aspect of the orifice at the proximal epiphysis (only sis cortical). (C) Using a drill bit 1 to 1.5mm wider than the chosen intramedullary pin (IMP), the perforation previously made was enlarged at  $45^\circ$  angle towards the bone medullary canal, in the distal sense, without affecting the opposite cortical (trans). (D) With the aid of orthopaedic pliers, the end of the IMP was bent, facilitating its insertion through the inclined perforation. (E) Detail of the bend end of the IMP, aiding its insertion with a mallet and pin reamer. (F) Final aspect of the insertion of the IMP into the tibial medullary canal. Note the trans-operative measurement of the correct positioning of the IMP by external comparison with an IMP of similar size. It is important to note that the bend was undone in the majority of the cases once the IMP reached the fracture line, in other words, before its introduction into the fractured distal fragment. (Desenhos: Lucas Alvez Ramon)

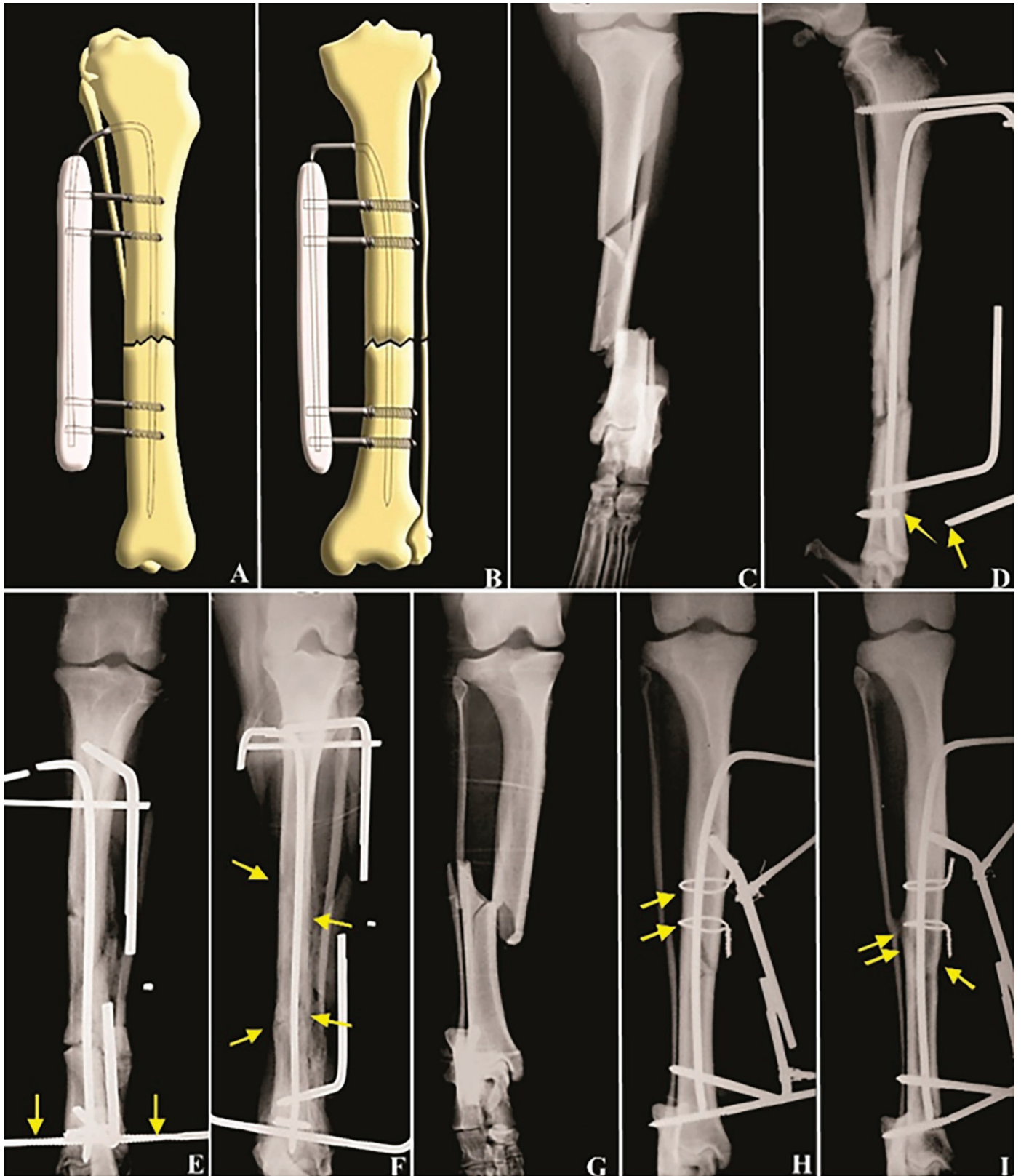


Fig.2. Schematic drawings and radiographic images (mediolateral and craniocaudal projections) of the tie-in osteosynthesis technique in the tibia of a dog. (A) Mediolateral and (B) craniocaudal view of the tie-in with two Schanz pins in each bone fragment. (C-F) = dog 21: (C) pre-operative image of the fracture, (D) break in fixation pin (yellow arrows) at 30 days post-operative (PO), (E) insertion of the pin with central thread close to the fractured implant (yellow arrows), (F) consolidation at 120 days PO (yellow arrows). (G-I) = dog 3: (G) pre-operative image of the fracture, (H) Immediate post-operative with tie-in configuration and two steel cerclages (yellow arrows), (I) bone consolidation at 90 days PO (yellow arrows). (Desenhos: Lucas Alvez Ramon)

## RESULTS

There were no trans-operative complications or suture dehiscence up to the day of suture removal. After 10 days post-operative, only one dog showed intense claudication. When questioned, the owners reported that the request to keep the animal in a confined space was not met. However, radiographic evaluation revealed that there was no failure of the implants and, thus, only rest and movement restrictions were recommended.

In regards to the moment of weight bearing (information obtained through follow-ups and questionnaire), the function of the operated limb was classified as good or excellent in 18 animals, with mean period of 10.8 days for return of limb function, including in dogs with concomitant lesions. The 3 remaining animals were initially classified as satisfactory, but re-classified as good or excellent within 15 days post-surgery.

At 30 days post-surgery, one dog showed instability of the fixating implants from the proximal fragment following trauma. The implant was removed and a Schanz pin inserted to re-stabilize the configuration. Thirty days after this intervention, radiography revealed intense bone absorption at the fracture site, which worsened progressively, leading to complete removal of the fixator. Other stabilization techniques were attempted using autogenous bone graft, although without success, leading to amputation of the limb, as the owner was unable to finance further treatment.

In regard to the degree of owner satisfaction with the technique used, only one owner was very unsatisfied (owner of the dog that had to have the limb amputated), although conscious that he/she had not followed the post-operative recommendations, resulting in bone exposure and lack of bone union. On the other hand, the remaining owners replied to being very satisfied with the results obtained.

When asked whether they would agree to have another dog undergo the same surgical technique (tie-in configuration), the response was exactly as the previous one, being only negative regarding the owner of the amputated dog.

Radiographic evidence was relatively similar in all animals at the immediate post-operative period, with good alignment of the bone axis and correct insertion of IMP and transfixing implants (Fig.2C-I).

Partial development of bone callus was observed in 20 dogs within a mean period of 76 days. Three dogs showed bone consolidation within 35 days, nine by 60 days, three by 90 days, and 5 by 120 days post-operative (Fig.2C-I).

Two dogs incurred trauma following the surgical procedure, at 10 and 30 days, with deformation of IMP axis; however, subsequent x-rays showed bone consolidation without the need for further surgical intervention.

At 45 days post-operative, radiography revealed the presence of bone sequestrum in one of the dogs, with potential associated osteomyelitis as a consequence of the time of fracture exposure. These findings were not clinically apparent, as the dog did not have claudication and there was no fistula tract. Oral cephalixin (30mg/kg, every 12 hours) was prescribed for 40 days. Configuration was adjusted at 60 and 90 days post-operative and bone consolidation observed at 120 days.

Dynamization was carried out in 9 dogs. After radiographic confirmation of bone consolidation, the implants were completely removed from all 20 dogs.

## DISCUSSION

Assuming that the methods of fixation used in osteosynthesis must resist the main mechanical forces at the site of fracture, the tie-in configuration has great biomechanical advantage, as it resists to all these forces even though it requires fewer implants than conventional ESF (Beck & Simpson 1999, Popkov et al. 2014).

Tie-in osteosynthesis is mostly recommended in the treatment of unstable femoral and humeral fractures, with small distal fragments, comminuted, and/or diaphyseal (Beck & Simpson 1999, Rahal et al. 2004, Fitzpatrick et al. 2011). In the present study, all animals had unstable tibial fractures at the rotational or rotational and axial plane and this configuration turned out to be executable and efficient, resulting in bone consolidation in 20 of the 21 dogs treated.

The use of a reduced number of implants results in reduced in muscle damage and discomfort when weight bearing (Johnson 2008), similarly to that observed in the classification of weight bearing in the animals of this study.

The insertion of the intramedullary pin into the tibial medullary canal often leads to peri and intra-articular complications, such as interference of the pin with the cruciate ligaments, menisci, patellar ligament, femoral condyle, patella, and infra-patellar adipose tissue (Piermattei et al. 2009). Due to all these potential complications and the fact that there had to be a connection between the IMP and the ESF, this study opted for extra-articular insertion of the IMP at the medial face of the proximal epiphysis, close to the tibial crest, as preconized by McCartney (2007), eliminating thus the occurrence of articular lesions.

In the present study, there were no complications related to exposed IMP and minimal reaction of adjacent soft tissues, as previously reported by Basinger & Suber (2004) for the extension of the interlocking pin when the tie-in configuration was used. On the other hand, purulent discharge at the site of emergence of the IMP has been reported by Rahal et al. (2004) and Fitzpatrick et al. (2011) in femur and in metacarpus and metatarsus, respectively, of animals treated by this method.

In the present study there was no complication from the use of the polymethyl methacrylate as an external connector of the implants. Furthermore, this material is of low cost and versatile and, when combined with IMP, promotes greater rotational stability (McCartney 2007, Worth 2007). On the other hand, Rahal et al. (2004) observed migration of the IMP when a metallic bar and connection clips were used to join the IMP and the remaining femoral implants (tie-in), due to loosening of the clips.

Three types of implants were used in the configuration; IMP, Schanz pins, and central thread pins, both with positive profile threads. In two animals the Schanz pins were deformed and broken, corroborating with Mercadante et al. (2003), who reported these implants to be the second least resistant point in an ESF configuration. In the present study, there were no complications with central thread pins.

Tie-in configuration was completely removed in 3 animals after clinical and radiographic at 30 days post-operative. These

were young large breed dogs (seven and nine months old), in which bone consolidation occurred early. Similarly, McCartney (2007) reported the removal of the apparatus between six and eight weeks in animals younger than 1 year, and eight to ten weeks in animals over one year old. Popkov et al. (2014) combined Ilizarov ESF and intramedullary pins in dogs aged 1 to 5 years with experimental fractures and closed growth plates and observed that all fractures were completely consolidated by 28 days post-operatively.

Egger et al. (1993) observed that conventional ESF destabilization (dynamization) after four weeks post-operative enabled the formation of periosteal callus in dogs due to an increase in the mechanical force at the site of fracture. The dynamization in the animals in the present study played an essential role in osteosynthesis success, as it was carried out when healing delays were noted in the radiographs. Thus, other forms of bone stabilization probably would not have enabled the correction of these in such a simple manner.

Although the tie-in configuration does not have the consolidation characteristics of a rigid method, such as bone plate (Johnson 2008, Vallefucio et al. 2016), the moderate formation of bone callus observed in the 20 animals from this study suggests stable fixation. The use of IMP and Ilizarov ESF in the osteosynthesis of canine tibia has been associated with good healing by Popkov et al. (2014) who observed early consolidation in animals subjected to this technique in comparison to those subjected only to ESF. These authors suggest that the use of IMP stimulates the formation of granulation tissue, which in turn activates angiogenesis and osteoclast and osteoblast production, leading to bone repair. In the present study, it was observed that tie-in in canine tibia showed excellent stabilization of fractured bone fragments, with early consolidation even though a reduced number of implants was used when compared to conventional ESF or isolated IMP.

One of the disadvantages of bone plates is the need for a surgical procedure to have them removed, as faults related to the implants are often seen in tibia (Vallefucio et al. 2016). On the other hand, in tie-in configuration, all implants are removed after bone consolidation without the need for open surgical intervention or locomotive restriction.

The main complications observed in this study, similarly to those reported by Johnson (2008) and Piermattei et al. (2009) were the presence of bone sequestrum in one animal and lack of bone union in another, which led to the amputation of the later even though other interventions were performed. Other authors have reported complications such as post-operative discharge close to the pin and cutaneous lesions (Fitzpatrick et al. 2011, Popkov et al. 2014), or those related to the implants, leading to loss of stability such as loosening of the implants (Basinger & Suber 2004) and loss of IMP stability (McCartney 2007), all of which were not observed in the present study.

## CONCLUSIONS

The surgical access to the tibial medullary canal through the orifice at the proximal medial face, by the tibial tuberosity, enables the insertion of IMP without risks to articular and peri-articular lesions in the knee in dogs.

Therefore, the connection of IMP to other percutaneous bone stabilization implants (tie-in configuration) can be perfectly adapted to canine tibia, and several types of tibial fractures could be treated by this method of bone fixation.

## REFERENCES

- Basinger R.R. & Suber J.T. 2004. Two techniques for supplementing interlocking nail repair of fractures of the humerus, femur, and tibia: results in 12 dogs and cats. *Vet. Surg.* 33(6):673-680. <<http://dx.doi.org/10.1111/j.1532-950X.2004.04095.x>> <PMid:15659025>
- Beck J.A. & Simpson D.J. 1999. Type 1-2 hybrid external fixator with tied-in intramedullary pin for treating comminuted distal humeral fractures in dog and cat. *Aust. Vet. J.* 77(1):18-20. <<http://dx.doi.org/10.1111/j.1751-0813.1999.tb12417.x>> <PMid:10028386>
- Egger E.L., Gottsauner-Wolf F., Palmer J., Aro H.T. & Chao E.Y. 1993. Effects of axial dynamization on bone healing. *J. Trauma* 34(2):185-192. <<http://dx.doi.org/10.1097/00005373-199302000-00001>> <PMid:8459454>
- Fitzpatrick N., Riordan J.O., Smith T.J., Modlinska J.H., Tucker R. & Yeadon R. 2011. Combined intramedullary and external skeletal fixation of metatarsal and metacarpal fractures in 12 dogs and 19 cats. *Vet. Surg.* 40(8):1015-1022. <PMid:22092182>
- Harari J. 2002. Treatments for feline long bone fractures. *Vet. Clin. N. Am., Small Anim. Pract.* 32(4):927-947. <[http://dx.doi.org/10.1016/S0195-5616\(02\)00025-6](http://dx.doi.org/10.1016/S0195-5616(02)00025-6)> <PMid:12148319>
- Johnson A.L. 2008. Fundamentals of orthopedic surgery and fracture management, p.930-1014. In: Fossum T.W. (Ed), *Small Animal Surgery*. 3rd ed. Elsevier, Rio de Janeiro.
- Kemper B. & Diamante G.A.C. 2010. Retrospective study on fractures in felines attended in the veterinary Hospital at Marília University, São Paulo, Brazil, from 2007 to 2014. *Ciênc. Biol. Saúde* 12(2):23-26.
- Lacerda M.A.S., Baltrão V.A., Lima Filho C.A.A.S., Vieira Filho A.M., Cândido J.M., Monte M.S. & Leite J.E.B. 2013. Estudo retrospectivo sobre fraturas causadas por traumatismo radiodiagnosticadas no setor de radiologia do hospital veterinário da UFRPE no mês de dezembro de 2012. *Anais XIII Jornada de Ensino, Pesquisa e Extensão, Recife, PE*. p.1-3. (Resumo).
- McCartney W.T. 2007. Use of an acrylic external fixator with an intramedullary tie-in pin for the treatment of tibial fractures in 85 dogs. *Vet. Rec.* 161(17):596-597. <<http://dx.doi.org/10.1136/vr.161.17.596>> <PMid:17965373>
- Mercadante M.T., Kojima K., Hungria J.O.S., Hungria Neto J.S., Camargo A.B., Samano H.M., Santos R.S.F., Vatauvuk J., Mello Junior A.G., Bertolani A.D. & Freitas C.E.B. 2003. Mechanical resistance evaluation of three different schanz screws to torsion forces in monolateral external fixation assemblies. *Revta Bras. Ortoped.* 38(3):106-116.
- Piermattei D.L., Flo G. & Decamp C.E. 2009. *Ortopedia e Tratamento de Fraturas de Pequenos Animais*. 4th ed. Manole, Barueri.
- Popkov D.A., Popkov A.V., Kononovich N.A., Barbier D., Ceroni D., Journeau P. & Lascombes P. 2014. Experimental study of progressive tibial lengthening in dogs using the Ilizarov technique: comparison with and without associated intramedullary K-wires. *Orthoped. Traumatol. Surg. Res.* 100(7):809-814. <<http://dx.doi.org/10.1016/j.otsr.2014.06.021>> <PMid:25306304>
- Rahal S.C., Garib M.I., Matsubara F.M., Vulcano L.C. & Louzada M.J.Q. 2004. Immobilization of femoral fractures in cats using intramedullary pin tied-in or not with the external skeletal fixator. *Ciência Rural* 34(6):1841-1847. <<http://dx.doi.org/10.1590/S0103-84782004000600027>>
- Vallefucio R., Le Pommellet H., Savin A., Decambon A., Manassero M., Viateau V., Gauthier O. & Fayolle P. 2016. Complications of appendicular fracture repair in cats and small dogs using locking compression plates. *Vet. Comp. Orthoped. Traumatol.* 29(1):46-52. <<http://dx.doi.org/10.3415/VCOT-14-09-0146>> <PMid:26511152>
- Worth A.J. 2007. Management of fractures of the long bones of eight cats using external skeletal fixation and a tied-in intra-medullary pin with a resin-acrylic bar. *N.Z. Vet. J.* 55(4):191-197. <<http://dx.doi.org/10.1080/00480169.2007.36767>> <PMid:17676085>