




***Listeria innocua* and serotypes of *Listeria monocytogenes* isolated from clinical cases in small ruminants in the northwest of Uruguay¹**

Carolina Matto^{2*} , Ruben E. Giannechini², Víctor Rodríguez²,
Marcos A. Schanzembach², Valeria Braga³, Maria Inés Mota³,
Rodolfo Rivero² and Gustavo Varela³

ABSTRACT.- Matto C., Giannechini R.E., Rodríguez V., Schanzembach M.A., Braga V., Mota M.I., Rivero R. & Varela G. 2023. *Listeria innocua* and serotypes of *Listeria monocytogenes* isolated from clinical cases in small ruminants in the northwest of Uruguay. *Pesquisa Veterinária Brasileira* 43:e07174, 2023. Laboratorio Regional Noroeste DILAVE "Miguel C. Rubino", Ruta 3 Km 369, Paysandú, Uruguay. E-mail: cmatto@mgap.gub.uy

Listeriosis is an infectious disease caused by bacteria of the genus *Listeria*, the neurological form being more common in ruminants. There are many reports of listeriosis in small ruminants in the region that includes Brazil, Argentina and Uruguay. However, these diagnoses were mainly based on histological lesions in the central nervous system (CNS) without the isolation and characterization of the involved *Listeria* strains. The aim of this study was to report sheep and goats listeriosis cases from 2016 to 2021 in northwestern Uruguay. The diagnosis was made according to lesions observed at histopathology, plus *Listeria* isolation in CNS, identifying it at specie and serotype level. Nine animals (n=9) of three outbreaks and five sporadic cases of listeriosis were studied. Sheep was the species with more cases in relation to goats, and adults were the category most affected. Cases occurred in spring and less frequently in winter. All presented neurological clinical signs and the lesions in the CNS were consistent with suppurative meningoencephalitis and micro-abscesses in the brainstem. In eight of nine CNS samples, *Listeria* strains were isolated (seven *L. monocytogenes* and one *L. innocua*). All the *L. monocytogenes* isolates carried the *inlA* gene; serotyping showed that four strains belonged to serotype 1/2b, two isolates belonged to serotype 4b, and one to serotype 1/2a. Considering that listeriosis is a common disease in this region and the fact that isolates are scarcely recovered from small ruminants, it would be important to emphasize the need for *Listeria* isolation to better characterize the strains that affect animals. Not only to improve knowledge about the epidemiology of disease but also with the objective of developing serotype specific vaccines for animal use.

INDEX TERMS: Meningoencephalitis, sheep, goat, *Listeria innocua*, *Listeria monocytogenes*, circling disease, pasture, nervous diseases, South America.

RESUMO.- [*Listeria innocua* e serotipos do *Listeria monocytogenes* isoladas dos casos clínicos em pequenos ruminantes no noroeste do Uruguai.] Listeriose uma doença bacteriana causada pelo gênero *Listeria*, a forma nervosa é a

mais comum em ruminantes. No Brasil, Argentina e Uruguai há vários relatos de listeriose em pequenos ruminantes com diagnóstico baseado na histopatologia do sistema nervoso central (SNC), sem o isolamento e a caracterização do agente. O objetivo deste trabalho foi relatar uma série de casos diagnosticados em ovinos e caprinos no período 2016-2021 no noroeste do Uruguai. O diagnóstico foi feito baseado nas lesões observadas na histopatologia, e caracterização das cepas de *Listeria* recuperadas do SNC quanto à espécie e serotipo. Nove animais (n=9) do três surtos e cinco casos isolados de listeriose foram estudados. Os ovinos foram a

¹ Received on September 13, 2022.

Accepted for publication on September 27, 2022.

² Laboratorio Regional Noroeste DILAVE "Miguel C. Rubino", Ministerio de Ganadería, Agricultura y Pesca (MGAP), Ruta nº 3 Km 369, C.P 60.000, Paysandú, Uruguay. *Corresponding author: cmatto@mgap.gub.uy

³ Instituto de Higiene, Facultad de Medicina, Universidad de la República, Alfredo Navarro 3051, C.P. 11.600, Montevideo, Uruguay.

espécie com o maior número de casos em relação aos caprinos, sendo os animais adultos a categoria mais afetada em ambas espécies. A doença ocorreu principalmente na primavera com alguns casos observados no inverno. Todos os casos apresentavam sinais clínicos nervosos e as lesões no SNC caracterizavam-se por meningoencefalite supurativa com presença de microabscessos no tronco encefálico. Em oito de nove amostras do SNC foram isoladas cepas de *Listeria* (sete *L. monocytogenes* e uma *L. innocua*). Todos os isolados de *L. monocytogenes* continham o gene *inlA*; a sorotipagem apresentou quatro cepas do serotipo 1/2b, duas cepas serotipo 4b e uma cepa 1/2a. Levando em consideração que nesta região a listeriose é uma doença frequente e que existem poucos isolados recuperados de casos clínicos em pequeno ruminantes, torna-se relevante o isolamento deste agente para caracterização das cepas que afetam os animais. Não só para melhorar o conhecimento sobre a epidemiologia da doença, mas também com o objetivo de desenvolver vacinas sorotipo-específicas para uso animal.

TERMOS DE INDEXAÇÃO: meningoencefalite, ovino, caprino, *Listeria innocua*, *Listeria monocytogenes*, torneio, pastagem, doenças nervosas, América do Sul.

INTRODUCTION

Listeriosis is an infectious disease caused by *Listeria monocytogenes* and, less frequently *L. innocua*, *L. ivanovii*, *L. seeligeri* or *L. grayi* (Wilesmith & Gitter 1986, Walker et al. 1994, Bagatella et al. 2022). It has different clinical manifestations in ruminants, but the neurological form is by far the most commonly seen (Oevermann et al. 2010b, Rissi et al. 2010b, Konradt et al. 2017). It is characterized by suppurative meningoencephalitis with brainstem micro-abscesses (Oevermann et al. 2010a). Other clinical manifestations included late-term abortion, neonatal septicemia, and in rare cases, mastitis, gastroenteritis and keratoconjunctivitis/uveitis (Brugère-Picoux 2008, Oevermann et al. 2010b, Fairley et al. 2012).

In South America, including Brazil, Argentina and Uruguay, listeriosis is one of the main neurological diseases of small ruminants (Campero et al. 2002, Guedes et al. 2007, Rissi et al. 2010a, Dutra 2015, Konradt et al. 2017). There are many reports of listeriosis in sheep (Campero et al. 2002, Ribeiro et al. 2006, Rissi et al. 2010a, 2010b, Dutra 2012, 2015, Konradt et al. 2017, Canton et al. 2018, Costa et al. 2018, Ribeiro et al. 2022) as well as in goats (Rissi et al. 2006, Guedes et al. 2007, Headley et al. 2013, Konradt et al. 2017). However, most of these reports based their diagnoses on histopathological lesions, and some of them included immunohistochemistry but did not perform the isolation and characterization of *Listeria*. Therefore, the aim of this study was to describe a case series of listeriosis in small ruminants from 2016 to 2021 in northwestern Uruguay, in which the diagnosis was based on histopathology and bacteriological procedures.

MATERIALS AND METHODS

Case selection. This study included sheep and goat cases received by the Laboratorio Regional Noroeste DILAVE “Miguel C. Rubino” from 2016 to 2021 that met the following conditions: i) presence of neurological signs, ii) availability of the whole brain (or central nervous system, CNS) without

gross lesions and iii) had fresh CNS for bacteriological culture. Those cases of small ruminants with nervous signs in which only formalin-fixed organs were submitted were excluded from this study.

All cases considered had a record that included data on animal species, category, clinical signs, feeding, number of animals affected, dead and at-risk animals.

Pathological evaluation. The brain was sectioned longitudinally in two halves (including cerebral hemispheres, cerebellum and brainstem). For histopathology, different areas of the CNS (frontal, temporal and occipital hemispheres, basal ganglia, thalamus, mesencephalon, cerebellum, pons, medulla oblongata and cervical spinal cord) previously fixed in 10% buffered formalin for 48 hours were routinely embedded in paraffin, sectioned into 5µm-thick sections, and then stained with hematoxylin-eosin (HE).

Bacterial analysis. The other half of the CNS was immersed in 225 ml buffered *Listeria* enrichment broth (BLEB) (Oxoid®) and incubated for 48 hours at 30°C under aerobiosis. At 24 and 48 hours, 100µl of broth was inoculated on modified Oxford agar plates (MOX) (Oxoid®). Plates were incubated under aerobiosis at 35°C, checking for growth at 24 and 48 hours. Small gray to black colonies surrounded by a black halo was transferred to a 5% sheep blood agar plate (SBA-5%) and inoculated in a 1.5ml vial with trypticase soybean broth (TSB) plus glycerol (20%) to preserve them at -80°C (Hitchins et al. 2022).

Suspected isolates of *Listeria* were submitted to the Departamento de Bacteriología y Virología, Instituto de Higiene, Facultad de Medicina, UdelaR for further assays. To determine species identity, Gram staining, catalase and esculin hydrolysis tests, and sucrose, glycerol, xylose, mannitol, glucose and rhamnose fermentation assays were performed (Carlin et al. 2021, Hitchins et al. 2022). Additionally, PCR was performed according to Liu et al. (2007) to detect the *inlA* gene. Another multiplex PCR was performed on all *L. monocytogenes* isolates to group them into serogroups, according to Doumith et al. (2004). On the strains of serogroups IIa, IIb, IIc and IVb, serotyping searching for somatic antigens 1 and 4 were performed using commercially available *Listeria* antisera (BD Difco®).

RESULTS

Epidemiology and clinical data

Table 1 shows the main epidemiological data, *Listeria* species recovered from CNS and serotype of *L. monocytogenes* of the nine animals received (eight sheep and one goat) during the study. In total, 19 animals were affected, and all died. They belonged to six different farms. Three outbreaks included 14 animals from farms D, E and F, while in the other farms (A, B and C), only single cases occurred (n=5). Furthermore, two farms (A and C) had listeriosis cases in different years (farm A in 2016 and 2017, caused by different *Listeria* species; farm C in 2017 and 2018 *L. monocytogenes* in both but different serotypes). There were more cases in sheep (n=18) than in goats (n=1). In sheep, the most affected category was the ewe (16/18, 88.9%), followed by lambs in a much smaller proportion (2/18, 11.1%). In goats, an adult female was affected (Table 1).

Most cases occurred during spring (13/19, 68.4%), and the remaining occurred in winter (6/19, 31.6%). There were no

cases in summer or autumn. Records on feeding showed that in four farms (4/6, 66.6%), the animals only grazed natural or cultivated pastures. Meanwhile, in the other two farms (2/6, 33.3%), animals were fed grain and/or commercial feeds in addition to pasture. None of the cases were previously fed with silage (Table 1).

Like sheep, goats presented with the neurological form of the disease. The clinical signs described were unilateral facial paralysis (drooped ear and upper eyelid, flaccid lip), circling, lateral deviation of the head, depression, hypersalivation, ataxia and recumbency. Clinical signs lasted between two and seven days until death. Morbidity and mortality were 0.56% to 100% (median 0.8%), respectively, while lethality was 100% (Table 1).

Histopathological findings

According to the clinical signs described in all cases, the main lesion was in the brainstem.

At histopathology, in simple identified as one (Table 1), there were in pons and medulla oblongata scarce accumulation of neutrophils and lymphocytes, diffuse gliosis, multiple

perivascular cuffs made of lymphocytes and some histiocytes (Fig.1). These lesions were consistent with a mild suppurative meningoencephalitis. While in the remaining samples (from samples two to nine, Table 1), lesions observed were more severe. At medulla oblongata and pons, there were multifocal to coalescent areas of neuropil aggregates of neutrophils mixed with some lymphocytes and histiocytes (microabscesses) (8/8) (Fig.2), multiple perivascular cuffs made of lymphocytes and histiocytes (8/8), gliosis (Fig.3) and, mild leptomeningeal infiltration by lymphocytes (8/8). In four cases (id samples five, seven, eight and nine), these lesions extend rostrally to the mesencephalon and, in two (cases eight and nine), also affected the thalamus.

Bacterial results

Listeria sp. was recovered in eight out of nine CNS samples. There was no growth in the culture of CNS from case number six. Of these eight isolates, seven belong to *L. monocytogenes* and one to *L. innocua* (Table 1). A case of meningoencephalitis due to *L. innocua* was recently reported (Matto et al. 2022). Whole genome sequencing of this isolate revealed that the

Table 1. Cases of small ruminant listeriosis diagnosed in the northwest of Uruguay from 2016 to 2021. Main epidemiological data, bacterial isolates and *Listeria monocytogenes* serotypes

Number sample	Year	Farm/County	Category	Season	Animals affected	Animals at risk	Feed	Isolation	Serotype
1	2016	A/Paysandú	Lamb	Spring	1	120	Pasture	<i>L. innocua</i>	n/d
2	2017	B/Paysandú	Goat	Winter	1	1	Pasture + sorghum grain	<i>L. monocytogenes</i>	4b
3	2017	C/Paysandú	Ewe	Winter	1	wd	Pasture	<i>L. monocytogenes</i>	1/2a
4	2017	D/Colonia	Ewe	Spring	2	360	Pasture	<i>L. monocytogenes</i>	1/2b
5	2017	A/Paysandú	Ewe	Spring	1	130	Pasture	<i>L. monocytogenes</i>	1/2b
6	2018	E/Paysandú	Ewe	Spring	8	285	Pasture + barley grain + ration	Negative culture	n/d
7	2018	C/Paysandú	Lamb	Spring	1	wd	Pasture	<i>L. monocytogenes</i>	1/2b
8 and 9	2021	F/Soriano	Ewe	Winter	4	600	Pasture	<i>L. monocytogenes</i>	1/2b and 4b

wd = Without data available, n/d = not determined.

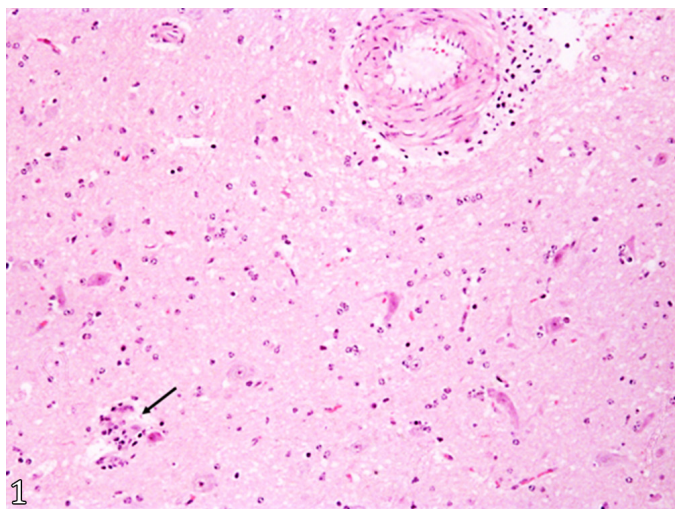


Fig.1. Isolate case of listeriosis due to *Listeria innocua*. Sample no. 1 (lamb). Brain, medulla oblongata. Neuropil infiltration of lymphocytes, diffuse, discrete; diffuse gliosis; accumulation of neutrophils and lymphocytes, focal discrete (arrow); perivascular cuff made of lymphocytes. HE, obj.100x.

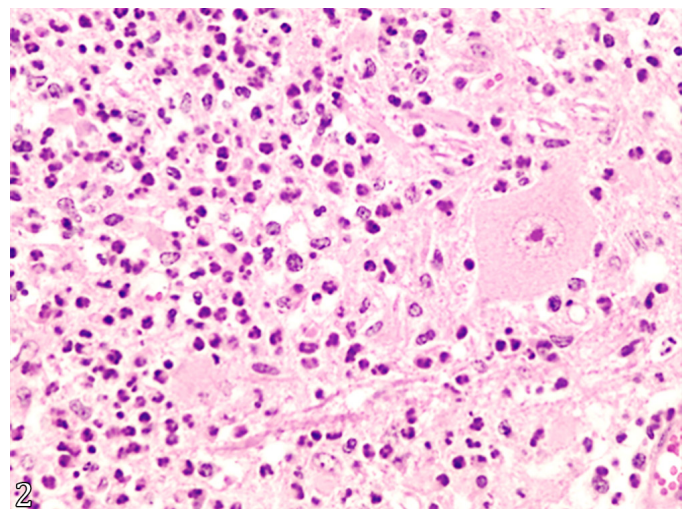


Fig.2. Outbreak of nervous listeriosis on a sheep flock due to *Listeria monocytogenes*. Sample no. 8 (ewe). Brain, medulla oblongata. Diffuse neuropil infiltration by neutrophils mixed with scarce histiocytes. HE, obj.400x.

internalin A gene (*inlA*) was not present. Instead, it carried other accessory virulence genes capable of promoting cell invasion and/or intracellular replication (Matto et al. 2022).

The seven *L. monocytogenes* isolates carried the *inlA* gene, and there was a major presence of serotype 1/2b (4/7, 57%), followed by serotype 4b (2/7, 29%) and serotype 1/2a (1/7, 14%) (Table 1).

DISCUSSION

During this study (2016-2021), the nine animal samples showed histological lesions in the CNS consistent with listeriosis, and in eight of them, *Listeria* strains were recovered. We recorded more cases in sheep than in goats, likely because there are more sheep than goats raised as livestock in Uruguay. Raising goats is rare and is related to the production of milk and its subproducts (Anuario Estadístico Agropecuario 2021). Adults were the most affected categories in both species. The same situation was previously reported by other authors (Campero et al. 2002, Ribeiro et al. 2006, Rissi et al. 2006, Oevermann et al. 2010a, Rissi et al. 2010b). However, other reports from Brazil mentioned that listeriosis occurred in animals under one year old (Guedes et al. 2007, Ribeiro et al. 2022). Therefore, the evidence from different reports suggests that there is no age-related predisposition to listeriosis, as Bagatella et al. (2022) propose.

Similar to many reports from the Northern Hemisphere, the cases of listeriosis occurred mostly in spring and less frequently in winter (Barlow & McGorum 1985, Wilesmith & Gitter 1986, Brugère-Picoux 2008, Dreyer et al. 2015). The predominance of listeriosis during winter and spring could be related to the previous high exposure to the bacteria because the incubation period of the neurological form varies between one and seven weeks (Brugère-Picoux 2008, Oevermann et al. 2010b). Nightingale et al. (2005) and Strawn et al. (2013) found that winter has the highest prevalence of *L. monocytogenes* in the farm environment. However, Rissi et al. (2010b) and Headley

et al. (2013) in southern and southwestern Brazil reported cases in summer. In the same region, Ribeiro et al. (2022) described an outbreak in spring. Such difference could not be attributed to the weather because Uruguay and these regions of Brazil belong to the same Köppen-Geiger climate classification (humid subtropical) (Peel et al. 2007). Therefore, differences in disease seasonality might be explained by other factors, such as the management of animals, the sanitary status, and the type of feed. Characteristics of circulating *Listeria* could also be associated with this variation, as other reports mentioned differences in its capacity to infect animals and survive in the farm environment (Nightingale et al. 2004, Haley et al. 2015).

All cases studied herein exhibited the neurological form of the disease. The predominance of this clinical form agrees with data reported previously by other authors (Barlow & McGorum 1985, Wilesmith & Gitter 1986, Guedes et al. 2007, Oevermann et al. 2010b, Rissi et al. 2010b, Ribeiro et al. 2022). During this study, five single cases and three disease outbreaks occurred, and the morbidity and mortality were 0.8% (median). The fact that few animals per farm were affected has not been clear until now. One reason may be the unequal exposure of animals to *Listeria* spp. due to focal accumulation in the feeds or the farm environments (Walland et al. 2015). Another potential cause would be animal stressors (external and internal) because they weaken the immune system and favor *Listeria* invasion; however, true animal risk factors are not well understood (Brugère-Picoux 2008, Walland et al. 2015, Bagatella et al. 2022). Similarly, Wilesmith & Gitter (1986) and Dreyer et al. (2015) mentioned that there is little evidence that supports the hypothesis of immunosuppression or concomitant diseases when many animals are affected in a flock.

Like in other regional reports (Campero et al. 2002, Guedes et al. 2007, Rissi et al. 2010b, Costa et al. 2018), most of the cases occurred in grazing animals, without data on previous silage intake. In contrast, other authors associate the disease with silage fed (Wilesmith & Gitter 1986, Gudmundsdottir et al. 2004, Ribeiro et al. 2006, 2022, Brugère-Picoux 2008). A previous review of the disease in ruminants by Walland et al. (2015) estimated that up to one-third of cases were unrelated to previous silage intake. Reinforcing this hypothesis, an epidemiological study in a sheep farm where cases of listeriosis occurred found the same strain of *L. monocytogenes* in drinking water, soil, and diseased animals, concluding that water and soil could be the sources of infection (Dreyer et al. 2015). In the same way, other reports in Uruguay have confirmed the presence of *L. monocytogenes* on pastures associated with clinical cases of listeriosis in ruminants (Matto et al. 2017) as well as the fecal shedding of the bacteria by clinically asymptomatic cattle (Matto et al. 2018). Therefore, different feeds consumed by animals and drinking water and/or soil could be sources of contamination. In this case series, it is noteworthy that we recorded cases in different years and with different *Listeria* species or serotypes on farms A and C. This finding might be associated with the ubiquitous condition of this agent (Brugère-Picoux 2008), since its presence was reported in different areas of farms, such as drinking water, feed and/or soil over a prolonged time (Gudmundsdottir et al. 2004, Nightingale et al. 2005, Strawn et al. 2013, Dreyer et al. 2015, Castro et al. 2018). Moreover, in small ruminant farms with previous cases of listeriosis, the prevalence of *L.*

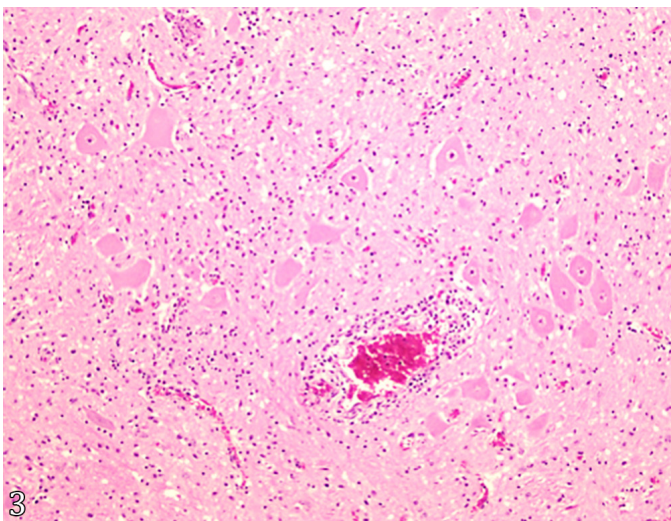


Fig.3. Outbreak of nervous listeriosis on a sheep flock due to *Listeria monocytogenes*. Sample no. 9 (ewe). Brain, medulla oblongata. Large perivascular cuff composed of lymphocytes and some histiocytes. Diffuse neuropil infiltration by lymphocytes. HE, obj.100x.

monocytogenes in the soil, feed and water was statistically superior (Nightingale et al. 2004). Therefore, to better understand the epidemiology of listeriosis in grazing small ruminants, it would be necessary to conduct studies in the farm environments to establish the possible sources of contamination (pasture, silages, soil, beds, drinking water, among others), as has been extensively reported in many scientific papers (Wiedmann et al. 1994, Gudmundsdottir et al. 2004, Nightingale et al. 2004, Dreyer et al. 2015).

The histological lesions caused by *Listeria* in the CNS have been previously described (Barlow & McGorum 1985, Campero et al. 2002, Oevermann et al. 2010a, Rissi et al. 2010b, Konradt et al. 2017). They do not represent a difficulty in the diagnosis of the disease. The kind of inflammatory cells that infiltrates the neuroparenchyma allow us to assess a temporal progression of the encephalitis (Oevermann et al. 2010a). In the nine cases studied, there was a predominance of neutrophilic microabscesses compatible with acute encephalitis. Some authors propose that small ruminants are more susceptible to *Listeria* infection with a clinical course shorter than cattle (Oevermann et al. 2010b, Bagatella et al. 2022). Another interesting finding in this study was that in case number one, CNS lesions due to *L. innocua* were the same as those caused by *L. monocytogenes* but less severe, as reported by Walker et al. (1994) and Rocha et al. (2013).

In the present study, the isolation of *Listeria* from the CNS seems to be more successful (eight positive cultures out of nine samples, 88.8%) than in other reports that diagnose the disease using histopathology and microbiological procedures (Johnson et al. 1995, Campero et al. 2002). A possible explanation may be the changes in techniques for *Listeria* isolation. Previous works used cold enrichment incubation, whereas we used specific selective enrichment media to favor *Listeria* growth (Hitchins et al. 2022). In the CNS of sheep from farm E (case six), we did not recover *Listeria* from culture, despite histopathology showing lesions consistent with listeriosis. This result could be related to a small number or absence of viable bacteria in the CNS at the time of culture (Johnson et al. 1995). Many authors mention that recovery of *Listeria* from fresh organs is difficult for different reasons; for example, the submission of fresh material not properly preserved, the need for appropriate culture media to support the growth of *Listeria*, and the low sensitivity of culture as a diagnostic technique (Johnson et al. 1995, Brugère-Picoux 2008). However, we considered it important to try bacterial isolation because it allows the characterization and comparison of the *Listeria* strains involved. For example, the neurological form of listeriosis could be due to *L. innocua* or different serotypes of *L. monocytogenes*. In the scientific literature, there are few reports of *L. innocua* as a cause of meningoencephalitis in ruminants (Walker et al. 1994, Rocha et al. 2013, Matto et al. 2022), likely because, in most cases, a bacteriological culture is not performed. A comparable situation occurs with sheep abortion, which could be related to *L. monocytogenes* (Wilesmith & Gitter 1986) or *L. ivanovii* (Low et al. 1993, Chand & Sadana 1999). Another fact to consider is that recovering *L. monocytogenes* isolates from clinical cases in ruminants would allow us to study certain characteristics of circulating bacteria, such as serotypes, lineages and/or clonal complexes. This kind of information, complemented with data on isolates recovered from the farm environment,

would enable us to link the clinical cases with the possible source of contamination.

Regarding the *L. monocytogenes* serotypes recovered, all of them are associated with clinical cases in both humans and animals (1/2a, 1/2b and 4b) (Oevermann et al. 2010b). We recorded a major presence of serotype 1/2b. In contrast, Great Britain and Iceland reports mentioned a higher prevalence of serotype 1/2a in the neurological form in small ruminants (Wilesmith & Gitter 1986, Low et al. 1993, Gudmundsdottir et al. 2004). Another interesting result occurred in the farm F outbreak, in which we recovered two strains of *L. monocytogenes*, one of serotype 1/2b and the other of serotype 4b (Table 1). This finding, plus the others mentioned above, could be related to the hypothesis that inside farms, there is a high strain diversity of circulating *Listeria* (Gudmundsdottir et al. 2004, Nightingale et al. 2004, Haley et al. 2015). As mentioned previously, only four regional reports isolated *L. monocytogenes* from clinical cases in small ruminants (Campero et al. 2002, Ribeiro et al. 2006, Konradt et al. 2017, Canton et al. 2018). The first recovered three isolates out of four CNS cultures, and all belonged to serotype 4 (Campero et al. 2002). However, the latter three reports did not serotype the isolates (Ribeiro et al. 2006, Konradt et al. 2017, Canton et al. 2018). On the other hand, Headley et al. (2013) amplified the gene *hly* of *L. monocytogenes* from the brainstem of small ruminants with neurological clinical signs compatible with listeriosis, but no established which serotypes were associated with those cases. Considering that in this region of South America, there are few isolates recovered from clinical cases in small ruminants and that listeriosis is a common disease, it would be important to emphasize the need to isolate *Listeria* to characterize in detail the strains that affect animals. On the other hand, since vaccination is one of the most successful strategies to prevent infectious diseases in animals, the complete characterization of *Listeria* strains involved becomes additionally important for its development and, above all, its evaluation (Calderón-González et al. 2014).

Finally, we want to mention the two main limitations of the present work – at first, the low number of cases studied. We only fully studied nine of 19 animals with nervous signs (47%). Second, as mentioned above, of the nine CNS cultured, we recovered *Listeria* in eight (88.8%). This fact suggests that auxiliary tests such as immunohistochemistry are important in cases where there is no bacterial recovery from culture.

CONCLUSION

In northwest Uruguay, neurolisteriosis was the main form of the disease in small ruminants, affecting mainly adult animals. Cases were more common during spring and winter, occurring as outbreaks or isolated cases. Most of the affected animals were on pasture without fed silage. *Listeria monocytogenes* serotypes 1/2b and 4b were more commonly isolated, and both are associated with human listeriosis. *Listeria innocua* may affect small ruminants less frequently.

Acknowledgements.- Carolina Matto has a Ph.D. scholarship from “Agencia Nacional de Investigación e Innovación” (ANII) Uruguay: POS_NAC_2019_1_157866. The investigation received funding from ANII Uruguay, identified as FSSA_1_2019_1_160057.

Conflict of interest statement.- The authors declare no conflicts of interest.

REFERENCES

- Anuario Estadístico Agropecuario 2021. Ministerio de Ganadería, Agricultura y Pesca, República Oriental del Uruguay. Available at <<https://www.gub.uy/ministerio-ganaderia-agricultura-pesca/comunicacion/publicaciones/anuario-estadistico-agropecuario-2021>> Accessed on Jun. 1, 2022.
- Bagatella S., Tavares-Gomes L. & Oevermann A. 2022. *Listeria monocytogenes* at the interface between ruminants and humans: A comparative pathology and pathogenesis review. *Vet. Pathol.* 59(2):186-210. <<https://dx.doi.org/10.1177/03009858211052659>> <PMid:34856818>
- Barlow M. & McGorum B. 1985. Ovine listerial encephalitis: analysis, hypothesis and synthesis. *Vet. Rec.* 116(9):233-236. <<https://dx.doi.org/10.1136/vr.116.9.233>> <PMid:4002594>
- Brugère-Picoux J. 2008. Ovine listeriosis. *Small Rum. Res.* 76(1/2):12-20. <<https://dx.doi.org/10.1016/j.smallrumres.2007.12.022>>
- Calderón-González R., Frande-Cabanes E., Bronchalo-Vicente L., Lecea-Cuello M.J., Pareja E., Bosch-Martínez A., Fanarraga M.L., Yañez-Díaz S., Carrasco-Marín E. & Álvarez-Domínguez C. 2014. Cellular vaccines in listeriosis: role of the *Listeria* antigen GAPDH. *Front. Cell. Infect. Microbiol.* 21:4-22. <<https://dx.doi.org/10.3389/fcimb.2014.00022>> <PMid:24600592>
- Campero C.M., Odeón A.C., Cipolla A.L., Moore D.P., Poso M.A. & Odriozola E. 2002. Demonstration of *Listeria monocytogenes* by immunohistochemistry in formalin-fixed brain tissues from natural cases of ovine and bovine encephalitis. *J. Vet. Med. B, Infect. Dis. Vet. Public Health* 49(8):379-383. <<https://dx.doi.org/10.1046/j.1439-0450.2002.00586.x>> <PMid:12449246>
- Canton G., Fiorentino A., Manes J., Scioli V., Maldonado J., Moore P. & Morrell E. 2018. Listeriosis neonatal en cordero: reporte de caso, p.19-20. En: Robles C.A. (Ed.), *Enfermedades de Ovinos, Caprinos y Camélidos Sudamericanos*. INTA Ediciones, Buenos Aires. Available at <<https://repositorio.inta.gov.ar/handle/20.500.12123/4835>> Accessed on Jun. 3, 2022.
- Carlin C.R., Liao J., Weller D.L., Gou X., Orsi R. & Wiedmann M. 2021. *Listeria cossartiae* sp. nov., *Listeria farberii* sp. nov., *Listeria immoviles* sp. nov., *Listeria portnoyi* sp. nov., and *Listeria rustica* sp. nov., isolated from agricultural water and natural environments. *Int. J. Syst. Evol. Microbiol.* 71(5):004795. <<https://dx.doi.org/10.1099/ijsem.0.004795>> <PMid:33999788>
- Castro H., Jaakkonen A., Hakkinen M., Korkeala H. & Lindström M. 2018. Occurrence, persistence, and contamination routes of *Listeria monocytogenes* genotypes on three Finnish dairy cattle farms: a longitudinal study. *Appl. Environ. Microbiol.* 84(4):e02000-17. <<https://dx.doi.org/10.1128/AEM.02000-17>> <PMid:29222098>
- Chand P. & Sadana J.R. 1999. Outbreak of *Listeria ivanovii* abortion in sheep in India. *Vet. Rec.* 145(3):83-84. <<https://dx.doi.org/10.1136/vr.145.3.83>> <PMid:10460032>
- Costa R.A., Matto C., Schanzembach M., Rodríguez V., Varela G., Braga V., Vico M.V. & Riet-Correa F. 2018. Romboencefalite por *Listeria monocytogenes* em ovinos criados a pasto. *Pesq. Vet. Bras.* 38(Supl.):113-115.
- Doumith M., Buchrieser C., Glaser P., Jacquet C. & Martin P. 2004. Differentiation of the major *Listeria monocytogenes* serovars by multiplex PCR. *J. Clin. Microbiol.* 42(8):3819-3822. <<https://dx.doi.org/10.1128/JCM.42.8.3819-3822.2004>> <PMid:15297538>
- Dreyer M., Thomann A., Böttcher S., Frey J. & Oevermann A. 2015. Outbreak investigation identifies a single *Listeria monocytogenes* strain in sheep with different clinical manifestations, soil and water. *Vet. Microbiol.* 179(1/2):69-75. <<https://dx.doi.org/10.1016/j.vetmic.2015.01.025>> <PMid:25726302>
- Dutra F. 2012. Boletín nº 14 y 15. Archivo Veterinario del Este, Laboratorio Regional Este de DILAVE "Miguel C Rubino", Ministerio de Ganadería, Agricultura y Pesca (MGAP), Treinta y Tres, Uruguay. Available at <https://www.smvu.com.uy/moduloBiblioteca/23_a52814f9/archivosAdjuntos/ano-2012-p-2.pdf> Accessed on Jun. 1, 2022.
- Dutra F. 2015. Boletín nº 18. Archivo Veterinario del Este, Laboratorio Regional Este de DILAVE "Miguel C Rubino", Ministerio de Ganadería, Agricultura y Pesca (MGAP), Treinta y Tres, Uruguay. Available at <https://www.smvu.com.uy/moduloBiblioteca/23_a52814f9/archivosAdjuntos/ano-2012-p-2.pdf> Accessed on Jun. 1, 2022.
- Fairley R.A., Pesavento P.A. & Clark R.G. 2012. *Listeria monocytogenes* infection of the alimentary tract (enteric listeriosis) of sheep in New Zealand. *J. Comp. Pathol.* 146(4):308-313. <<https://dx.doi.org/10.1016/j.jcpa.2011.08.004>> <PMid:21925677>
- Gudmundsdóttir K.B., Aalbaek B., Sigurdarson S. & Gunnarsson E. 2004. The diversity of *Listeria monocytogenes* strains from 10 Icelandic sheep farms. *J. Appl. Microbiol.* 96(5):913-921. <<https://doi.org/10.1111/j.1365-2672.2004.02183.x>> <PMid:15078506>
- Guedes K.M.R., Riet-Correa F., Dantas A.F.M., Simões S.V.D., Miranda Neto E.G., Nobre V.M.T. & Medeiros R.M.T. 2007. Doenças do sistema nervoso central em caprinos e ovinos no semi-árido. *Pesq. Vet. Bras.* 27(1):29-38. <<https://dx.doi.org/10.1590/S0100-736X2007000100006>>
- Haley B.J., Sonnier J., Schukken Y.H., Karns J.S. & Van Kessel J.A.S. 2015. Diversity of *Listeria monocytogenes* within a U.S. dairy herd, 2004-2010. *Foodborne Pathog. Dis.* 12(10):844-850. <<https://dx.doi.org/10.1089/fpd.2014.1886>> <PMid:26325149>
- Headley S.A., Bodnar L., Fritzen J.T.T., Bronkhorst D.E., Fernandes Alfieri A., Okano W. & Alcindo Alfieri A. 2013. Histopathological and molecular characterization of encephalitic listeriosis in small ruminants from northern Paraná, Brasil. *Braz. J. Microbiol.* 44(3):889-896. <<https://dx.doi.org/10.1590/s1517-83822013000300036>> <PMid:24516457>
- Hitchins A.D., Jinneman K. & Chen Y. 2022. Detection of *Listeria monocytogenes* in foods and environmental samples, and enumeration of *Listeria monocytogenes* in foods. *Bacteriological Analytical Manual*, United States Food and Drug Administration. Available at <<https://www.fda.gov/food/laboratory-methods-food/bam-chapter-10-detection-listeria-monocytogenes-foods-and-environmental-samples-and-enumeration>> Accessed on Jun. 1, 2022.
- Johnson G.C., Fales W.H., Maddox C.W. & Ramos-Vara J.A. 1995. Evaluation of laboratory tests for confirming the diagnosis of encephalitic listeriosis in ruminants. *J. Vet. Diagn. Invest.* 7(2):223-228. <<https://dx.doi.org/10.1177/104063879500700210>> <PMid:7542480>
- Konradt G., Bassuino D.M., Prates K.S., Bianchi M.V., Snel G.G.M., Sonne L., Driemeier D. & Pavarini S.P. 2017. Suppurative infectious diseases of the central nervous system in domestic ruminants. *Pesq. Vet. Bras.* 37(8):820-828. <<https://dx.doi.org/10.1590/S0100-736X2017000800007>>
- Liu D., Lawrence M.L., Austin F.W. & Ainsworth A.J. 2007. A multiplex PCR for species and virulence-specific determination of *Listeria monocytogenes*. *J. Microbiol. Methods* 71(2):133-140. <<https://dx.doi.org/10.1016/j.mimet.2007.08.007>> <PMid:17884210>
- Low J.C., Wright F., McLauchlin J. & Donachie W. 1993. Serotyping and distribution of *Listeria* isolates from cases of ovine listeriosis. *Vet. Rec.* 133(7):165-166. <<https://dx.doi.org/10.1136/vr.133.7.165>> <PMid:8236705>
- Matto C., D'Alessandro B., Mota M.I., Braga V., Buschiazzo A., Giannechini E., Varela G. & Rivero R. 2022. *Listeria innocua* isolated from diseased ruminants harbour minor virulence genes of *L. monocytogenes*. *Vet. Med. Sci.* 8(2):735-740. <<https://dx.doi.org/10.1002/vms3.710>> <PMid:35040277>
- Matto C., Varela G., Braga V., Vico V., Giannechini R.E. & Rivero R. 2018. Detection of *Listeria* spp. in cattle and environment of pasture-based dairy farms. *Pesq. Vet. Bras.* 38(9):1736-1741. <<https://dx.doi.org/10.1590/1678-5150-PVB-5663>>
- Matto C., Varela G., Mota M.I., Giannechini R. & Rivero R. 2017. Rhombencephalitis caused by *Listeria monocytogenes* in a pastured bull. *J. Vet. Diagn. Invest.* 29(2):228-231. <<https://dx.doi.org/10.1177/1040638716689116>> <PMid:28166691>
- Nightingale K.K., Fortes E.D., Ho A.J., Schukken Y.H., Grohn Y.T. & Wiedmann M. 2005. Evaluation of farm management practices as risk factors for clinical listeriosis and fecal shedding of *Listeria monocytogenes* in ruminants. *J.*

- Am. Vet. Med. Assoc. 227(11):1808-1814. <<https://dx.doi.org/10.2460/javma.2005.227.1808>> <PMid:16350271>
- Nightingale K.K., Schukken Y.H., Nightingale C.R., Fortes E.D., Ho A.J., Her Z., Gröhn Y.T., McDonough P.L. & Wiedmann M. 2004. Ecology and transmission of *Listeria monocytogenes* infecting ruminants and in the farm environment. *Appl. Environ. Microbiol.* 70(8):4458-4467. <<https://dx.doi.org/10.1128/AEM.70.8.4458-4467.2004>> <PMid:15294773>
- Oevermann A., Di Palma S., Doherr M.G., Abril C., Zurbriggen A. & Vandeveld M. 2010a. Neuropathogenesis of naturally occurring encephalitis caused by *Listeria monocytogenes* in ruminants. *Brain Pathol.* 20(2):378-390. <<https://dx.doi.org/10.1111/j.1750-3639.2009.00292.x>> <PMid:19476464>
- Oevermann A., Zurbriggen A. & Vandeveld M. 2010b. Rhombencephalitis caused by *Listeria monocytogenes* in humans and ruminants: a zoonosis on the rise? *Interdiscip. Perspect. Infect. Dis.* 2010:632513. <<https://dx.doi.org/10.1155/2010/632513>> <PMid:20204066>
- Peel M.C., Finlayson B.L. & McMahon T.A. 2007. Updated world map of the Köppen-Geiger climate classification. *Hydrol. Earth Syst. Sci.* 11:1633-1644. <<https://dx.doi.org/10.5194/hess-11-1633-2007>>
- Ribeiro L.A.O., Rodrigues N.C., Fallavena L.C.B., Oliveira S.J. & Brito M.A. 2006. Listeriose em rebanho de ovinos leiteiros na região serrana do Rio Grande do Sul: relato de caso. *Arq. Bras. Med. Vet. Zootec.* 58(3):316-319. <<https://dx.doi.org/10.1590/S0102-09352006000300005>>
- Ribeiro L.S., Scheid H.V., Marques L.S., Venancio F.R., Silva E.R., Ladeira S.R.L. & Schild A.L. 2022. Listeriosis outbreak in sheep raised in feedlots in the southern region of Rio Grande do Sul State, Brazil. *Acta Scient. Vet.* 50(Supl.1):738. <<https://dx.doi.org/10.22456/1679-9216.119176>>
- Rissi D.R., Figuera R.A., Irigoyen L.F., Kommers G.D. & Barros C.S.L. 2010a. Doenças neurológicas de ovinos na região central do Rio Grande do Sul. *Pesq. Vet. Bras.* 30(3):222-228. <<https://dx.doi.org/10.1590/S0100-736X2010000300006>>
- Rissi D.R., Kommers G.D., Marcolongo-Pereira C., Schild A.L. & Barros C.S.L. 2010b. Meningoencefalite por *Listeria monocytogenes* em ovinos. *Pesq. Vet. Bras.* 30(1):51-56. <<https://dx.doi.org/10.1590/S0100-736X2010000100008>>
- Rissi D.R., Rech R.R., Barro R.R., Kommers G.D., Langohr I.M., Pierezan F. & Barros C.S.L. 2006. Forma nervosa de listeriose em caprinos. *Pesq. Vet. Bras.* 26(1):14-20. <<https://dx.doi.org/10.1590/S0100-736X2006000100004>>
- Rocha P.R.D., Dalmasso A., Grattarola C., Casalone C., Del Piero F., Bottero M.T. & Capucchio M.T. 2013. Atypical cerebral listeriosis associated with *Listeria innocua* in a beef bull. *Res. Vet. Sci.* 94(1):111-114. <<https://dx.doi.org/10.1016/j.rvsc.2012.07.017>> <PMid:22898534>
- Strawn L.K., Fortes E.D., Bihn E.A., Nightingale K.K., Gröhn Y.T., Worobo R.W., Wiedmann M. & Bergholz P.W. 2013. Landscape and meteorological factors affecting prevalence of three food-borne pathogens in fruit and vegetable farms. *Appl. Environ. Microbiol.* 79(2):588-600. <<https://doi.org/10.1128/AEM.02491-12>> <PMid:23144137>
- Walker J.K., Morgan J.H., McLauchlin J., Grant K.A. & Shallcross J.A. 1994. *Listeria innocua* isolated from a case of ovine meningoencephalitis. *Vet. Microbiol.* 42(2/3):245-253. <[https://dx.doi.org/10.1016/0378-1135\(94\)90023-x](https://dx.doi.org/10.1016/0378-1135(94)90023-x)> <PMid:7533963>
- Walland J., Lauper J., Frey J., Imhof R., Stephan R., Seuberlich T. & Oevermann A. 2015. *Listeria monocytogenes* infection in ruminants: Is there a link to the environment, food and human health? A review. *Schweiz. Arch. Tierheilkd.* 157(6):319-328. <<https://dx.doi.org/10.17236/sat00022>> <PMid:26753347>
- Wiedmann M., Czajka J., Bsat N., Bodis M., Smith M.C., Divers T.J. & Batt C.A. 1994. Diagnosis and epidemiological association of *Listeria monocytogenes* strains in two outbreaks of Listerial encephalitis in small ruminants. *J. Clin. Microbiol.* 32(4):991-996. <<https://dx.doi.org/10.1128/jcm.32.4.991-996.1994>> <PMid:8027356>
- Wilesmith J.W. & Gitter M. 1986. Epidemiology of ovine listeriosis in Great Britain. *Vet. Rec.* 119(19):467-470. <<https://dx.doi.org/10.1136/vr.119.19.467>> <PMid:3788010>