










Fusobacterium necrophorum predominates in the microbiota of mandibular dental abscess in *Blastocerus dichotomus*¹

Ana Carolina Borsanelli^{2*} , Flávia R.F. Athayde³ , Júlia R. Saraiva³ ,
Tamires A. Silva² , Juliana G. Mendes² , Eveline S. Zanetti⁴,
Marcello P. Riggio⁵  and Iveraldo S. Dutra³ 

ABSTRACT. Borsanelli A.C., Athayde F.R.F., Saraiva J.R., Silva T.A., Mendes J.G., Zanetti E.S., Riggio M.P. & Dutra I.S. 2024. *Fusobacterium necrophorum* predominates in the microbiota of mandibular dental abscess in *Blastocerus dichotomus*. *Pesquisa Veterinária Brasileira* 44:e07362, 2024. Departamento de Medicina Veterinária, Escola de Veterinária e Zootecnia, Universidade Federal de Goiás, Rodovia Goiânia-Nova Veneza Km 8, Goiânia, GO 74690-900, Brazil. E-mail: anaborsanelli@ufg.br

Dental abscess in ruminants is an acute polymicrobial infection, usually resulting from periodontal disease or endodontic infection, with consequences for animal health and welfare. The present study aimed to describe the bacterial microbiota of dental abscesses in *Blastocerus dichotomus*. Biological material from mandibular dental abscesses, punctured with a sterile syringe and needle during routine veterinary curative procedures or necropsies, was collected from three *ex-situ* marsh deer. Bacteria were identified using high-throughput sequencing of the 16S ribosomal RNA gene. The three specimens had the presence of facial bulging, and two died because of severe emaciation with a history of progressive weight loss. *Bacteroides* (38.6%), *Fusobacterium* (36.65%), and *Porphyromonas* (7.49%) represented the most abundant genera and *Fusobacterium necrophorum* (35.69%), *Porphyromonas levii* (3.12%) and *Porphyromonas gulae* (1.78%) were among the ten most represented species in the microbiota of mandibular abscess in *Blastocerus dichotomus*. These molecular findings demonstrate a broader diversity of species in the polymicrobial nature of dental abscesses in *B. dichotomus* than was previously reported when culture-dependent methods were used in the diagnosis.

INDEX TERMS: *Fusobacterium necrophorum*, *Blastocerus dichotomus*, orofacial abscess, deer, high-throughput sequencing, microbiome.

RESUMO. [*Fusobacterium necrophorum* predomina na microbiota do abscesso dentário mandibular em *Blastocerus dichotomus*.] O abscesso dentário em ruminantes é uma infecção polimicrobiana aguda, geralmente resultante de doença periodontal ou infecção endodôntica, com consequências para a saúde e bem-estar animal. O presente estudo teve como objetivo descrever a microbiota bacteriana de abscessos dentários em *Blastocerus dichotomus*. Material biológico de

abscessos dentários mandibulares, puncionados com seringa e agulha estéril durante procedimentos curativos veterinários de rotina ou necropsias, foi coletado de três cervos do pantanal criados *ex situ*. As bactérias foram identificadas usando sequenciamento de alto rendimento do gene 16S ribossomal RNA. Os três espécimes apresentavam abaulamento facial e dois faleceram por emagrecimento severo com histórico de emagrecimento progressivo. *Bacteroides* (38,6%), *Fusobacterium*

¹ Received on August 25, 2023.

Accepted for publication on October 26, 2023.

² Departamento de Medicina Veterinária, Escola de Veterinária e Zootecnia, Universidade Federal de Goiás (UFG), Rodovia Goiânia-Nova Veneza Km 8, Goiânia, GO 74690-900, Brazil. *Corresponding author: anaborsanelli@ufg.br; E-mails: tamires_ataides@discente.ufg.br, juliana_mendes@discente.ufg.br

³ Departamento de Produção e Saúde Animal, Faculdade de Medicina Veterinária de Araçatuba, Universidade Estadual Paulista "Júlio de Mesquita Filho" (Unesp), Rua

Clóvis Pestana 793, Bairro Dona Amélia, Araçatuba, SP 16050-680, Brazil. E-mails: iveraldo.dutra@unesp.br, flavia.athayde@gmail.com, julia.rebecca@unesp.br

⁴ Centro de Conservação do Cervo-do-Pantanal (CCCP), Universidade Estadual Paulista "Júlio de Mesquita Filho" (Unesp), Via de Acesso Professor Paulo Donato Castellane s/n, Jaboticabal, SP 14884-900, Brazil. E-mail: eveline.zanetti@tjjoa.com

⁵ Oral Sciences Research Group, Dental School, University of Glasgow, 378 Sauchiehall Street Glasgow, Scotland. E-mail: marcello.riggio@glasgow.ac.uk

(36,65%) e *Porphyromonas* (7,49%) representaram os gêneros mais abundantes e *Fusobacterium necrophorum* (35,69%), *Porphyromonas levii* (3,12%) e *Porphyromonas gulae* (1,78%) estavam entre as dez espécies mais representadas na microbiota do abscesso mandibular em *Blastocerus dichotomus*. Esses achados moleculares demonstram uma diversidade mais ampla de espécies na natureza polimicrobiana dos abscessos dentários em *B. dichotomus*, do que o relatado anteriormente quando métodos dependentes de cultura foram utilizados no diagnóstico.

TERMOS DE INDEXAÇÃO: *Fusobacterium necrophorum*, *Blastocerus dichotomus*, abscesso orofacial, cervídeos, sequenciamento de nova geração, microbioma.

INTRODUCTION

Dental abscess in ruminants is an acute polymicrobial infection caused by opportunistic microorganisms residing in the oral cavity and which may originate from periodontal disease or endodontic infection (Dutra & Borsanelli 2022). Observed with relative frequency in *ex-situ* deer populations classified as vulnerable to extinction (Borsanelli et al. 2022a), dental abscess results in direct and indirect damage to the health and welfare of affected cervids.

The richness and diversity of the dental microbiome of ruminants in health and diseased phenotypes (Borsanelli et al. 2018, 2021, 2022b, 2022c) suggest a robust source of possibilities and risks in orofacial infections. Of this predominantly strict anaerobic microbiota, there are several opportunistic bacteria with invasive capacity, including aerobic or facultative microorganisms detected when using only conventional-bacterial culture (Benito-Peña et al. 2010, Amorim et al. 2011, Rasooli et al. 2018). Indeed, the richness and diversity of the anaerobic microbiota associated with mandibular infections are underestimated when this diagnostic method is used (Arcaute et al. 2021) since some groups of microorganisms, such as spirochetes, cannot be cultivated (Arweiler & Netuschil 2016).

Dental infections have been reported in different species and populations or individuals of deer. The presence of facial bulging compatible with the occurrence of dental abscess has been reported in specimens of *Rangifer tarandus* in Canada (Miller et al. 1975) and in the United States (Doerr & Dieterich 1979, Williams 1980), in specimens from *Dama dama* in Hungary (Miklós et al. 2010), in a specimen of *Hippocamelus bisulcus* in Argentina (Flueck 2018), in specimens of *Odocoileus virginianus* in the United States (Powers & Mead 2019), and clinical records of *Blastocerus dichotomus* in Brazil (Borsanelli et al. 2022a).

Blastocerus dichotomus is classified as vulnerable in the Red List of Endangered Species of the International Union for Conservation of Nature (IUCN) (Duarte et al. 2016). In a previous study, the increase in facial volume with evolution to abscess formation was the main observation described in clinical records of marsh deer that presented some oral affection (Borsanelli et al. 2022a), and this can be an important limiting condition for the survival of cervids.

Within the limits of our knowledge, however, the microbiota associated with the occurrence of dental or periodontal abscesses in deer is unknown. Thus, given the need to promote advances in the conservation of the species and in

the knowledge of the main oral lesions that affect marsh deer, the present study aims to describe the bacterial microbiota identified in dental abscesses in specimens of *Blastocerus dichotomus* bred *ex-situ*, by high-throughput sequencing of the 16S rRNA gene.

MATERIALS AND METHODS

Animal Ethics. “Sistema de Autorização e Informação em Biodiversidade” – SISBIO Protocol no. 87788.

Data availability. Raw sequencing reads were uploaded to the NCBI Sequence Read Archive (SRA) under BioProject PRJNA701760.

Marsh Deer Conservation Center (CCCP). The “Centro de Conservação do Cervo-do-Pantanal” (Marsh Deer Conservation Center – CCCP) is in Promissão/SP and is responsible for maintaining approximately 60% of marsh deer in Brazil, representing one of the largest populations of this species in captivity worldwide (CCCP 2020). Currently, the CCCP population comprises 45 deer born in captivity and descendants of rescued cervids.

Cervid diet. The diet of CCCP deer is based on forage cultivated, pumpkin (*Abobra tenuifolia*), concentrate, and water *ad libitum*, as described by Borsanelli et al. (2022a). The cultivated forage is fertilized two to three times a year, and the native pastures are mowed monthly to prevent and control ticks.

Clinical signs and collection of samples. For the present study, three cervids from the CCCP herd with a history of facial bulging (Fig.1) and periodontal disease were included. The first deer was a male that was five months old at the time of sample collection and had severe facial bulging at the level of the last left maxillary molar. The abscess was drained, the deer received antibiotic treatment, and it never presented any visible periodontal process again after this episode. It is important to highlight that this deer’s mother died because of a serious periodontal disease years later. The second cervid was an adult female that, since the age of five, had presented several episodes of facial bulging associated with sialorrhea, tongue protrusion, purulent nasal secretion, and weight loss. At 11 years of age, the deer began to show progressive weight loss, difficulty grasping and swallowing food, and grass stuck on the left side of the mouth cavity. The cervid ended up dying, and at necropsy, it was possible to observe serious periodontal lesions that included loss of insertion of chewing teeth with root exposure, changes in the conformation of the dental arch, bone destruction, and sublingual abscess. The cause of the deer’s death was septic shock. The third cervid was also an 11-year-old adult female who had a history of facial bulging since it was seven years old. The cervid died after a severe case of liquid and foul-smelling diarrhea. At necropsy, an increase in volume in the mandibular ramus, absence of two incisor teeth, presence of two fractured incisor teeth, fistula after the left mandibular third molar and food stuck in the tooth was observed. The cause of the deer’s death was septic shock due to a purulent agent to be clarified.

Thus, three biological samples from the contents of three mandibular dental abscesses, punctured with a sterile syringe and needle during routine veterinary curative procedures or necropsies, were collected from three *ex-situ* marsh deer cited above. A sedation protocol was used with a combination of xylazine (0.5mg/kg) and azaperone (1mg/kg) or an anesthesia protocol with a combination of xylazine (1mg/kg) and ketamine (7mg/kg) to carry out the veterinary procedures. After collection, samples were stored in 250µL of RNAlater (Sigma-Aldrich, Dorset, UK), transported under refrigeration, and kept at -80°C until further processing.

DNA extraction and 16S rRNA sequencing. DNA extraction from dental samples was performed with the GenElute Mammalian Genomic DNA Miniprep Kit (Sigma, St Louis, United States). PCR amplicon libraries targeting the V4 region of the 16S rRNA gene (515F-806R) were produced using a barcoded primer set adapted for the Illumina HiSeq2000 and MiSeq (Caporaso et al. 2011, 2012). Amplicons were sequenced paired-end on an Illumina MiSeq using customized sequencing primers and procedures (Caporaso et al. 2012) at the Environmental Sample Preparation and Sequencing Facility (ESPSF) at Argonne National Laboratory, Lemont, United States.

Sequencing data analysis. Sequencing data from the V4 region of the 16S gene were processed according to the DADA2 microbiome pipeline with default parameters (Callahan et al. 2016). The identification of bacterial communities was performed by unique amplicon sequence variants (ASVs) among the reads (reads), and the taxonomy was assigned to each ASV by Silva’s taxonomic training (database v138) (Quast et al. 2012). All analysis was performed in the R 4.1.2 environment (R Core Team 2019), with the R DADA2 v.1.22 and DECIPHER v.2.22 packages (Wright et al. 2012, Callahan et al. 2016).

RESULTS

Sequencing of three dental abscess samples generated 80,074 reads. After removing sequencing errors, 95.7% of sequences remained (76,667). After merging and removing the chimeric sequences, 69,303 (86.5%) reads remained, assigned to 109 ASVs (amplicon sequence variants), represented by 69 genera. The ten most abundant genera were *Bacteroides* (38.6%), *Fusobacterium* (36.65%), *Porphyromonas* (7.49%), *Parvimonas* (4.19%), *Filifactor* (1.85%), *Helcococcus* (1.56%), *Peptostreptococcus* (1.18%), *Treponema* (1.15%), *Murdochiella* (1.1%) and *Atopobium* (0.93%) (Fig.2).

The 109 ASVs comprised 20 species and the ten most represented species were *Fusobacterium necrophorum* (35.69%), *Porphyromonas levii* (3.12%), *Porphyromonas gulae* (1.78%), *Helcococcus ovis* (1.5%), *Treponema medium* (1.14%), *Porphyromonas katsikii* (1.1%), *Filifactor villosus* (0.83%), *Bilophila wadsworthia* (0.22%), *Bacteroides heparinolyticus* (0.19%) and *Peptostreptococcus canis* (0.17%). The abundance identified in each sample is described in Figure 3.

DISCUSSION AND CONCLUSION

Oral affections represent one of the main and potential causes of mortality in *Blastocerus dichotomus* in CCCP and premature loss of cervid, as already described in a previous study (Borsanelli et al. 2022a). Affected cervids show gingival recession, clinical attachment loss, tooth loss, deep periodontal pockets, suppuration, gingivitis and dental abscesses. As the condition progresses, the cervids are unable to chew and ruminate properly, lose body condition, and die. Most cervids occasionally examined or even necropsied also showed a high prevalence of excessive tooth wear on the incisor and masticatory teeth.



Fig.1. Increased volume on the right side of the face of an adult *Blastocerus dichotomus* from “Centro de Conservação do Cervo-do-Pantanal” (CCCP), São Paulo, Brazil.

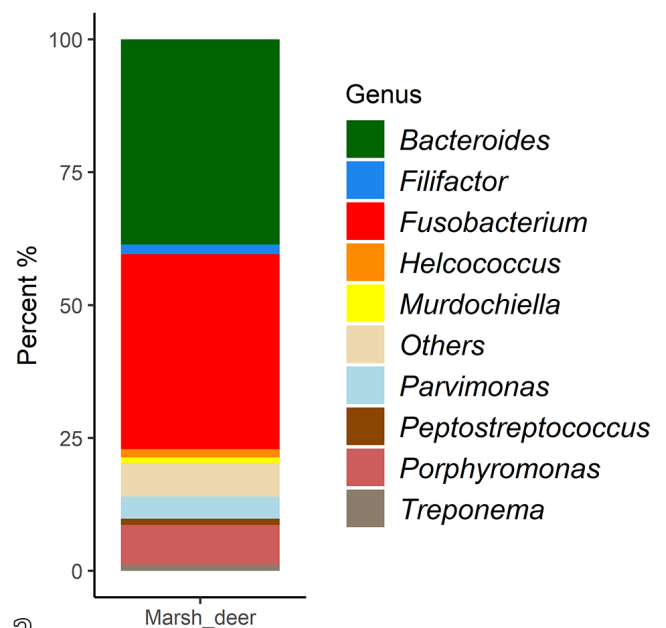


Fig.2. Relative abundance (>1%) of bacterial communities at the genus level, identified in the microbiota of dental abscess in *Blastocerus dichotomus*.

Previous studies reported the occurrence of lesions compatible with dental abscesses in different species of deer in several countries (Miller et al. 1975, Doerr & Dieterich 1979, Williams 1980, Miklós et al. 2010, Flueck 2018, Powers & Mead 2019, Borsanelli et al. 2022a). However, at the moment, few studies have evaluated the microbiota associated with oral affections in deer. Some authors argue that these dental conditions may be caused by a deficiency of minerals such as selenium (Flueck 2015, Flueck & Smith-Flueck 2017). Due to the supposed involvement of minerals in ruminant periodontal disease, Silveira et al. (2023) evaluated the concentrations of several minerals, including selenium, in the liver and bone of sheep affected or not by periodontitis. In contrast, most of the researched minerals were above or within the recommended concentrations in the tissues, and the authors concluded that there was no association between periodontal disease and mineral deficiency.

In the present study, the Gram-negative genera *Bacteroides*, *Fusobacterium* and *Porphyromonas* were the most abundant in the microbiota of deer abscesses. These genera have also been identified in great abundance in the oral microbiota of kangaroos with progressive periodontal disease (Yip et al. 2021) and in domestic ruminants such as cattle, sheep and goats with periodontitis (Borsanelli et al. 2018, 2021, 2022b, 2022c). Some members of *Fusobacterium* genus can connect with different microorganisms, acting as a bridge between early colonizers and the latter periodontopathogens, including anaerobic Gram-negative like *Bacteroides* and *Porphyromonas* (Li et al. 2015).

Fusobacterium necrophorum was the species with the highest abundance in the microbiota of deer with dental abscesses, especially in the microbiota of a young marsh deer. This microorganism has already been identified in different species of deer with mandibular abscess and necrobacillosis (Roeder et al. 1989, Chirino-Trejo et al. 2003), in llamas and alpacas with necrotic infection (Kumar et al. 2013) and in goats

with periodontitis (Suzuki et al. 2006, Campello et al. 2019). The high prevalence of this microorganism and the reduced diversity of other species identified in the young marsh deer may be related to the immaturity of the oral microbiota, as it was a 5-month-old cervid.

Black-pigmented anaerobes belonging to *Porphyromonas* genus represent the most prevalent microorganisms in the microbiota of cattle, sheep, and goats with periodontitis and are associated with the disease in these animals (Borsanelli et al. 2021, 2022b, 2022c). These microorganisms can express potent virulence factors and interfere with the host's innate immune response (Haffajee & Socransky 1994). *Porphyromonas gingivalis* is the most extensively characterized species of the genus, and it is considered an important periodontopathogen in sheep periodontitis (Friskén et al. 1989, Borsanelli et al. 2017). However, in this study, *Porphyromonas gingivalis* was not detected in the microbiota of deer abscesses.

In contrast, in the present study, *Porphyromonas gulae*, *Porphyromonas levii* and *Porphyromonas katsikii* were identified among the most abundant species in the microbiota of deer abscesses. *Porphyromonas gulae* has recognized the importance of periodontitis in humans and dogs (Senhorinho et al. 2011, Lenzo et al. 2016; Silva et al. 2017). So far, this microorganism has not been identified in the microbiota of any domestic ruminant species (Borsanelli et al. 2015, 2017, Campello et al. 2019). *Fusobacterium necrophorum* showed a strong association with *P. gulae* in captive kangaroos that developed periodontitis, and the authors suggested that these microorganisms could be involved in the etiopathogenesis of periodontal diseases in kangaroos (Antiabong et al. 2013).

Porphyromonas katsikii is a recently described species detected in the lung microbiota of goats with pyogranulomatous pneumonia during an outbreak of acute respiratory disease. However, the microorganism was not detected in the gingival sulcus of healthy goats. At the time, this microorganism was not identified in the oral microbiota of the goats as expected (Filioussis et al. 2015). *Porphyromonas levii* has been detected in cases of metritis, necrotic vulvovaginitis and digital dermatitis in cattle (Elad et al. 2004, Santos et al. 2011, Nielsen et al. 2016) and is suspected to have virulence factors capable of delaying the host's immune response, favoring multiplication of the host and other bacteria (Walter & Morck 2022).

Some genera usually associated with pyogenic processes, like *Staphylococcus* (0.15%), *Streptococcus* (0.11%), *Pseudomonas* (0.08%), and *Trueperella* were also identified in the present study. These microorganisms are commonly identified in the mandibular abscesses of animal species when only aerobiosis culture is used (Benito-Peña et al. 2010, Amorim et al. 2011, Rasooli et al. 2018). However, by high-throughput gene sequencing, it was possible to show that the participation of these microorganisms in the composition of the mandibular abscess microbiota is minimal.

In conclusion, the current study explores the polymicrobial nature and the predominance of opportunistic Gram-negative anaerobic microorganisms in the mandibular dental abscess of marsh deer. *Porphyromonas*, *Fusobacterium*, and *Bacteroides* may play key roles in this disease, and species such as *F. necrophorum*, *P. gulae*, *P. levii*, and *P. katsikii* were detected for the first time in the microbiota of cervids. These molecular findings demonstrate a broader diversity of species in the polymicrobial nature of dental abscesses in *B. dichotomus* than was previously reported when culture-dependent methods were used in the diagnosis.

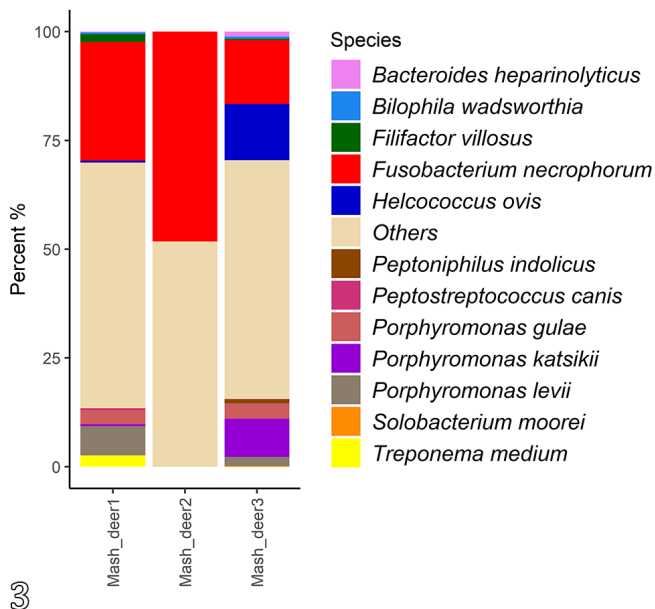


Fig.3. Relative abundance (>1%) of bacterial communities, at the species level, identified in the microbiota of dental abscess in *Blastocercus dichotomus*.

Funding. The authors declare that no funds, grants, or other support were received during the preparation of this manuscript.

Conflict of interest statement. The authors have no relevant financial or non-financial interests to disclose.

REFERENCES

- Amorim R.M., Toma H.S., Vulcano L.C., Ribeiro M.G., Fernandes S., Borges A.S., Chiacchio S.B. & Gonçalves R.C. 2011. Surto de abscesso mandibular por *Pseudomonas aeruginosa* em ovinos. *Pesq. Vet. Bras.* 31(9):747-750. <<https://dx.doi.org/10.1590/S0100-736X2011000900004>>
- Antiabong J.F., Boardman W., Smith I., Brown M.H., Ball A.S. & Goodman A.E. 2013. A molecular survey of a captive wallaby population for periodontopathogens and the co-incidence of *Fusobacterium necrophorum* subspecies *necrophorum* with periodontal diseases. *Vet. Microbiol.* 163(3/4):335-343. <<https://dx.doi.org/10.1016/j.vetmic.2013.01.012>> <PMid:23428381>
- Arcaute M.R., Lacasta D., Bueso J.P., Ferrer L.M., González J.M., Villanueva-Saz S. & Ramos J.J. 2021. Comparative study of bacterial isolates in ovine mandibular osteomyelitis and oral microbiota of healthy sheep. *Appl. Sci.* 11(9):3925. <<https://dx.doi.org/10.3390/app11093925>>
- Arweiler N.B. & Netuschil L. 2016. The oral microbiota. In: Schwartz, A. (Ed.), *Microbiota of the Human Body: implications in health and disease*. Springer, Cham. (advances in experimental medicine and biology 902). <https://dx.doi.org/10.1007/978-3-319-31248-4_4>
- Benito-Peña A., Peris B., Aduriz G., Martínez J. & Corpa J.M. 2010. Purulent nasomaxillary and mandibular osteomyelitis in sheep caused by *Pseudomonas aeruginosa*. *Vet. Rec.* 166(4):115-116. <<https://dx.doi.org/10.1136/vr.b4784>> <PMid:20097891>
- Borsanelli A.C., Athayde F.R.F., Agostinho S.D., Riggio M.P. & Dutra I.S. 2021. Dental biofilm and its ecological interrelationships in ovine periodontitis. *J. Med. Microbiol.* 70(7). <<https://dx.doi.org/10.1099/jmm.0.001396>> <PMid:34313584>
- Borsanelli A.C., Athayde F.R.F., Riggio M.P., Brandt B.W., Rocha F.I., Jesus E.C., Gaetti-Jardim Jr. E., Schweitzer C.M. & Dutra I.S. 2022c. Dysbiosis and predicted function of dental and ruminal microbiome associated with bovine periodontitis. *Front. Microbiol.* 13:936021. <<https://dx.doi.org/10.3389/fmicb.2022.936021>> <PMid:36033883>
- Borsanelli A.C., Athayde F.R.F., Saraiva J.R., Riggio M.P. & Dutra I.S. 2022b. Dysbiosis and predicted functions of the dental biofilm of dairy goats with periodontitis. *Microb. Ecol.* 86:687-698. <<https://dx.doi.org/10.1007/s00248-022-02062-0>> <PMid:35780192>
- Borsanelli A.C., Gaetti-Jardim Jr. E., Schweitzer C.M., Viora L., Busin V., Riggio M.P. & Dutra I.S. 2017. Black-pigmented anaerobic bacteria associated with ovine periodontitis. *Vet. Microbiol.* 203:271-274. <<https://dx.doi.org/10.1016/j.vetmic.2017.03.032>> <PMid:28619155>
- Borsanelli A.C., Gaetti-Jardim Júnior E., Schweitzer C.M., Döbereiner J. & Dutra I.S. 2015. Presence of *Porphyromonas* and *Prevotella* species in the oral microflora of cattle with periodontitis. *Pesq. Vet. Bras.* 35(10):829-834. <<https://dx.doi.org/10.1590/S0100-736X2015001000002>>
- Borsanelli A.C., Lappin D.F., Viora L., Bennett D., Dutra I.S., Brandt B.W. & Riggio M.P. 2018. Microbiomes associated with bovine periodontitis and oral health. *Vet. Microbiol.* 218:1-6. <<https://dx.doi.org/10.1016/j.vetmic.2018.03.016>> <PMid:29685214>
- Borsanelli A.C., Saraiva J.R., Pádua D.B., Athayde F.R.F., Vaccari J., Zanetti E.S. & Dutra I.S. 2022a. Oral affections in an ex-situ population of Marsh deer (*Blastocerus dichotomus*): a retrospective study (1990-2020). *Pesq. Vet. Bras.* 42:e7096. <<https://dx.doi.org/10.1590/1678-5150-PVB-7096>>
- Callahan B.J., McMurdie P.J., Rosen M.J., Han A.W., Johnson A.J.A. & Holmes S.P. 2016. DADA2: High-resolution sample inference from Illumina amplicon data. *Nat. Methods* 13(7):581-583. <<https://dx.doi.org/10.1038/nmeth.3869>> <PMid:27214047>
- Campello P.L., Borsanelli A.C., Agostinho S.D., Schweitzer C.M., Gaetti-Jardim Jr. E., Döbereiner J. & Dutra I.S. 2019. Occurrence of periodontitis and dental wear in dairy goats. *Small Rumin. Res.* 175:133-141. <<https://dx.doi.org/10.1016/j.smallrumres.2019.05.004>>
- Caporaso J.G., Lauber C.L., Walters W.A., Berg-Lyons D., Huntley J., Fierer N., Owens S.M., Betley J., Fraser L., Bauer M., Gormley N., Gilbert J.A., Smith G. & Knight R. 2012. Ultra-high-throughput microbial community analysis on the Illumina HiSeq and MiSeq platforms. *ISME J.* 6(8):1621-1624. <<https://dx.doi.org/10.1038/ismej.2012.8>> <PMid:22402401>
- Caporaso J.G., Lauber C.L., Walters W.A., Berg-Lyons D., Lozupone C.A., Turnbaugh P.J., Fierer N. & Knight R. 2011. Global patterns of 16S rRNA diversity at a depth of millions of sequences per sample. *Proc. Natl. Acad. Sci.* 108(Suppl.1):4516-4522. <<https://dx.doi.org/10.1073/pnas.1000080107>> <PMid:20534432>
- Chirino-Trejo M., Woodbury M.R. & Huang F. 2003. Antibiotic sensitivity and biochemical characterization of *Fusobacterium* spp. and *Arcanobacterium pyogenes* isolated from farmed white-tailed deer (*Odocoileus virginianus*) with necrobacillosis. *J. Zoo Wildl. Med.* 34(3):262-268. <<https://dx.doi.org/10.1638/02-019>> <PMid:14582788>
- Doerr J.G. & Dieterich R.A. 1979. Mandibular lesions in the western arctic caribou herd of Alaska. *J. Wildl. Dis.* 15(2):309-318. <<https://dx.doi.org/10.7589/0090-3558-15.2.309>> <PMid:39180>
- Duarte J.M.B., Varela D., Piovezan U., Beccaceci M.D. & Garcia J.E. 2016. *Blastocerus dichotomus*. The IUCN Red List of Threatened Species, 2016:e.T2828A22160916. <<https://dx.doi.org/10.2305/IUCN.UK.2016-1.RLTS.T2828A22160916.en>>
- Dutra I.S. & Borsanelli A.C. 2022. Doenças periodontais, p.37-118. In: Dutra I.S. & Borsanelli A.C. (Eds), *Saúde Bucal de Ruminantes: atlas para o reconhecimento das doenças periodontais*. 1st ed. Funep, Jaboticabal.
- Elad D., Friedgut O., Alpert N., Stram Y., Lahav D., Tiomkin D., Avramson M., Grinberg K. & Bernstein M. 2004. Bovine necrotic vulvovaginitis associated with *Porphyromonas levii*. *Emerg. Infect. Dis.* 10(3):505-507. <<https://dx.doi.org/10.3201/eid1003.020592>> <PMid:15109423>
- Filioussis G., Petridou E., Karavanis E. & Frey J. 2015. Pyogranulomatous pneumonia in goats caused by an undescribed *Porphyromonas* species, "*Porphyromonas katsikii*". *J. Clin. Microbiol.* 53(3):795-798. <<https://dx.doi.org/10.1128/jcm.02682-14>> <PMid:25540395>
- Flueck W.T. & Smith-Flueck J.A.M. 2017. Troubling disease syndrome in endangered live Patagonian huemul deer (*Hippocamelus bisulcus*) from the Protected Park Shoonem: unusually high prevalence of osteopathology. *BMC Res. Notes* 10:739. <<https://dx.doi.org/10.1186/s13104-017-3052-4>> <PMid:29246255>
- Flueck W.T. 2015. Osteopathology and selenium deficiency co-occurring in a population of endangered Patagonian huemul (*Hippocamelus bisulcus*). *BMC Res. Notes* 8:330. <<https://dx.doi.org/10.1186/s13104-015-1291-9>> <PMid:26233940>
- Flueck W.T. 2018. Elusive cranial lesions severely afflicting young, endangered Patagonian huemul deer. *BMC Res. Notes* 11:638. <<https://dx.doi.org/10.1186/s13104-018-3755-1>> <PMid:30176912>
- Friskin K.W., Laws A.J., Tagg J.R. & Orr M.B. 1989. Environmental influences on the progression of clinical and microbiological parameters of sheep periodontal disease. *Res. Vet. Sci.* 46(2):147-152. <[https://dx.doi.org/10.1016/S0034-5288\(18\)31137-8](https://dx.doi.org/10.1016/S0034-5288(18)31137-8)> <PMid:2784861>
- Haffajee A.D. & Socransky S.S. 1994. Microbiology and immunology of periodontal diseases. *Periodontol.* 2000 5(1):78-111. <<https://dx.doi.org/10.1111/j.1600-0757.1994.tb00020.x>> <PMid:9673164>
- Kumar A., Anderson D., Amachawadi R.G., Nagaraja T.G. & Narayanan S.K. 2013. Characterization of *Fusobacterium necrophorum* isolated from llama and alpaca. *J. Vet. Diagn. Invest.* 25:502-507. <<https://dx.doi.org/10.1177/1040638713491407>> <PMid:23780933>

- Lenzo J.C., O'Brien-Simpson N.M., Orth R.K., Mitchell H.L., Dashper S.G. & Reynolds E.C. 2016. *Porphyromonas gluttony* has virulence and immunological characteristics similar to those of the human periodontal pathogen *Porphyromonas gingivalis*. *Infect. Immun.* 84(9):2575-2585. <<https://dx.doi.org/10.1128/iai.01500-15>> <PMid:27354442>
- Li Y., Guo H., Wang X., Lu Y., Yang C. & Yang P. 2015. Coinfection with *Fusobacterium nucleatum* can enhance the attachment and invasion of *Porphyromonas gingivalis* or *Aggregatibacter actinomycetemcomitans* to human gingival epithelial cells. *Arch. Oral Biol.* 60(9):1387-1393. <<https://dx.doi.org/10.1016/j.archoralbio.2015.06.017>> <PMid:26143497>
- Miklós M., József K., Míra M., Ferenc J. & János G. 2010. Magyarországon elejtett dámszarvas (*Dama dama*) állkapocs- és fogelváltozásainak vizsgálata. *Magyar Allatorvosok Lapja* 132(6):367-370.
- Miller F.L., Cawley A.J., Choquette L.P.E. & Broughton E. 1975. Radiographic examination of mandibular lesions in barren-ground caribou. *J. Wildl. Dis.* 11(4):465-470. <<https://dx.doi.org/10.7589/0090-3558-11.4.465>> <PMid:519>
- Nielsen M.W., Strube M.L., Isbrand A., Al-Medrahi W.D.H.M., Boye M., Jensen T.K. & Klitgaard K. 2016. Potential bacterial core species associated with digital dermatitis in cattle herds identified by molecular profiling of interdigital skin samples. *Vet. Microbiol.* 186:139-149. <<https://dx.doi.org/10.1016/j.vetmic.2016.03.003>> <PMid:27016768>
- Powers P.M. & Mead A.J. 2019. Dental and mandibular anomalies in white-tailed Deer (*Odocoileus virginianus*) from Central Georgia. *Georgia J. Sci.* 77(2):1-11.
- Quast C., Pruesse E., Yilmaz P., Gerken J., Schweer T., Yarza P., Peplies J. & Glockner F.O. 2012. The SILVA ribosomal RNA gene database project: improved data processing and web-based tools. *Nucleic Acids Res.* 41:D590-D596. <<https://dx.doi.org/10.1093/nar/gks1219>> <PMid:23193283>
- R Core Team 2019. R: A language and environment for statistical computing. R Foundation for Statistical Computing, Vienna.
- Rasooli A., Nouri M., Esmailzadeh S., Ghadiri A., Gharibi D., Koupaei M.J. & Moazeni M. 2018. Occurrence of purulent mandibular and maxillary osteomyelitis associated with *Pseudomonas aeruginosa* in a sheep flock in south-west of Iran. *Iran. J. Vet. Res.* 19(2/63):133-136. <PMid:30046326>
- Roeder B.L., Chengappa M.M., Lechtenberg K.F., Nagaraja T.G. & Varg G.A. 1989. *Fusobacterium necrophorum* and *Actinomyces pyogenes* associated facial and mandibular abscesses in blue duiker. *J. Wildl. Dis.* 25(3):370-377. <<https://dx.doi.org/10.7589/0090-3558-25.3.370>> <PMid:2761010>
- Santos T.M.A., Gilbert R.O. & Bicalho R.C. 2011. Metagenomic analysis of the uterine bacterial microbiota in healthy and metric postpartum dairy cows. *J. Dairy Sci.* 94(1):291-302. <<https://dx.doi.org/10.3168/jds.2010-3668>> <PMid:21183039>
- Senhorinho G.N.A., Nakano V., Liu C., Song Y., Finegold S.M. & Avila-Campos M.J. 2011. Detection of *Porphyromonas gluttony* from subgingival biofilms of dogs with and without periodontitis. *Anaerobe* 17(5):257-258. <<https://dx.doi.org/10.1016/j.anaerobe.2011.06.002>> <PMid:21723404>
- Silva A.N., Avila E.D., Nakano V. & Avila-Campos M.J. 2017. Pathogenicity and genetic profile of oral *Porphyromonas* species from canine periodontitis. *Arch. Oral Biol.* 83:20-24. <<https://dx.doi.org/10.1016/j.archoralbio.2017.07.001>> <PMid:28692827>
- Silveira N.S.S., Malafaia P., Brito M.F., Lima D.H.S., Bomjardim H.A., Faial K.C.F., Barbosa C.C., Salvarani F.M. & Barbosa J.D. 2023. Mineral contents in bone and liver of sheep with or without periodontitis. *Arq. Bras. Med. Vet. Zootec.* 75(1):83-88. <<https://dx.doi.org/10.1590/1678-4162-12746>>
- Suzuki S., Mitani A., Koyasu K., Oda S.-I., Yoshinari N., Fukuda M., Hanamura H., Nakagaki H. & Noguchi T. 2006. A model of spontaneous periodontitis in the miniature goat. *J. Periodontol.* 77(5):847-855. <<https://dx.doi.org/10.1902/jop.2006.050203>> <PMid:16671878>
- Walter M.R.V. & Morck D.W. 2022. Chemotaxis, phagocytosis, and oxidative metabolism in bovine macrophages exposed to a novel interdigital phlegmon (foot rot) lesion isolate, *Porphyromonas levii*. *Am. J. Vet. Res.* 63(5):757-762. <<https://dx.doi.org/10.2460/ajvr.2002.63.757>> <PMid:12013480>
- Williams N.L. 1980. Dental abnormalities and mandibular swellings in South Georgia reindeer. *J. Comp. Pathol.* 90(2):315-330. <[https://dx.doi.org/10.1016/0021-9975\(80\)90067-5](https://dx.doi.org/10.1016/0021-9975(80)90067-5)> <PMid:7430454>
- Wright E.S., Yilmaz L.S. & Noguera D.R. 2012. DECIPHER, a search-based approach to chimera identification for 16S rRNA sequences. *Appl. Environ. Microbiol.* 78(3):717-725. <<https://dx.doi.org/10.1128/aem.06516-11>>
- Yip S., Dehcheshmeh M.M., McLelland D.J., Boardman W.S.J., Saputra S., Ebrahimie E., Weyrich L.S., Bird P.S. & Trott D.J. 2021. *Porphyromonas* spp., *Fusobacterium* spp., and *Bacteroides* spp. dominate microbiota in the course of macropod progressive periodontal disease. *Sci. Rep.* 11:17775. <<https://dx.doi.org/10.1038/s41598-021-97057-1>>