

Renal involvement in paroxysmal nocturnal haemoglobinuria: a brief review of the literature

 Ênio Simas Macedo¹

Sérgio Luiz Arruda Parente Filho¹

Juan Daniel Zuñiga Pro²

Victor de Matos Rolim¹

Guilherme de Alencar Salazar Primo¹

Denise Menezes Brunetta³

Herivaldo Ferreira da Silva³

Gdayllon Cavalcante Meneses⁴

Fernando Barroso-Duarte³

Elizabeth De Francesco Daher²

¹. School of Medicine, Federal University of Ceará, Fortaleza, CE, Brasil

². Post-graduation Program in Medical Sciences, Department of Internal Medicine, School of Medicine, Federal University of Ceará, Fortaleza, CE, Brasil

³. Medical Assistant, Haematology and Hemotherapy Center (Hemoce), Fortaleza, CE, Brasil

⁴. Department of Physiology and Pharmacology, School of Medicine, Federal University of Ceará, Fortaleza, CE, Brasil

<http://dx.doi.org/10.1590/1806-9282.64.12.1139>

SUMMARY

INTRODUCTION: *Paroxysmal Nocturnal Haemoglobinuria (PNH) is an acquired genetic disorder characterized by complement-mediated haemolysis, thrombosis and variable cytopenias. Renal involvement may occur and causes significant morbidity to these patients.*

OBJECTIVE: *To review the literature about pathophysiology and provide recommendations on diagnosis and management of renal involvement in PNH.*

METHODS: *Online research in the Medline database with compilation of the most relevant 26 studies found.*

RESULTS: *PNH may present with acute kidney injury caused by massive haemolysis, which is usually very severe. In the chronic setting, PNH may develop insidious decline in renal function caused by tubular deposits of hemosiderin, renal micro-infarcts and interstitial fibrosis. Although hematopoietic stem cell transplantation remains the only curative treatment for PNH, the drug Eculizumab, a humanized anti-C5 monoclonal antibody is capable of improving renal function, among other outcomes, by inhibiting C5 cleavage with the subsequent inhibition of the terminal complement pathway which would ultimately give rise to the assembly of the membrane attack complex.*

CONCLUSION: *There is a lack of information in literature regarding renal involvement in PNH, albeit it is possible to state that the pathophysiological mechanisms of acute and chronic impairment differ. Despite not being a curative therapy, Eculizumab is able to ease kidney lesions in these patients.*

KEYWORDS: *Paroxysmal Nocturnal Haemoglobinuria, Acute Kidney Injury, Chronic Kidney Diseases.*

INTRODUCTION

Paroxysmal nocturnal haemoglobinuria (PNH) is a haematological condition classically characterized by chronic haemolysis and thrombotic events. The incidence of PNH is 1-1.5 cases per million people and the clinical manifestations usually becomes evident between the third and fifth decades of life¹.

The main genetic abnormality in PNH is a somatic mutation of PIG-A gene, which is responsible for the final step of glycosylphosphatidylinositol (GPI) anchor production, required for the attachment of extracellular proteins to the surface of all blood cell lineages, including red blood cells (RBCs). The

DATE OF SUBMISSION: 10-Apr-2018

DATE OF ACCEPTANCE: 22-Apr-2018

CORRESPONDING AUTHOR: Ênio Simas Macedo

Rua Joaquim Nabuco, 643. – Fortaleza – CE – Brasil – 60125-120

Phone / Fax: (+55 85) 3224-0811/ (+55 85) 99982-4049

E-mail: enio_s_macedo@hotmail.com

deficiency of two of those extracellular proteins is specifically relevant in PNH: CD55 and CD59. Both proteins are responsible to prevent complement-mediated RBCs opsonization and lysis.

The renal impairment in PNH is common. However, statistics are not completely reliable, once renal impairment is usually asymptomatic and studies use different definitions of renal involvement. PNH patients may present tubular concentration defects, acute kidney injury (AKI) and chronic kidney disease (CKD)². In a Korean study with 301 patients with PNH, the prevalence of AKI (defined as a recorded history of AKI prior or after the definitive PNH diagnosis) was estimated at 14.6% and of CKD (defined as a GFR <60 mL/min/1.73m² prior or after the definitive PNH diagnosis) at 8.6%³. Most of the kidney impairment in PNH stems from chronic haemolysis, free haemoglobin (Hb) release in the bloodstream, and subsequent Hb renal filtration. Heme-containing pigments, such as Hb, are well established nephrotoxic agents, mainly due to the production of reactive oxygen species (ROS) and intratubular deposition^{2,4,5}. Magnetic resonance imaging (MRI) may evidence cortical renal haemosiderosis caused by chronic haemolysis and haemoglobin filtration⁵. MRI finding is renal cortical signal reduction in T2⁶. In the development of PNH-related CKD, renal thrombotic events apparently play an even more important role than Hb filtration⁵.

The diagnosis of PNH used to be made by Ham test, sucrose haemolysis test and complement lysis assay. Currently, these methods are no longer used. The gold standard diagnostic method in PNH is flow cytometry, which evaluates the presence of CD55 and CD59 and other GPI-linked proteins in red blood cells, granulocytes, and monocytes membranes. This test presents high sensitivity and specificity^{7,8,9}.

The mainstay of treatment is Eculizumab or haematopoietic stem cell transplantation (HSCT). HSCT is the only curative treatment. However, it is associated with high morbidity and mortality, thus it is only reserved to selected patients¹⁰. Eculizumab is a humanized monoclonal antibody directed against C5 that prevents the production of C5a and C5b-9 (membrane attack complex) via alternative complement system activation. C5b-9 complex is the principal culprit of intravascular haemolysis in PNH¹¹. Eculizumab also has a positive impact on renal function. A cohort of PNH patients has shown an improvement or maintenance of renal function in 94.5% of patients

after 36 months of therapy. Headache, nasopharyngitis, back pain, nausea, and increased susceptibility to *Neisseria* infections are among Eculizumab side effects, although it is generally well-tolerated¹².

METHODS

A review of literature was performed in the Medline (PubMed) database, using the following keywords: paroxysmal nocturnal haemoglobinuria; renal involvement; renal injury; Eculizumab; pathogenesis. 26 articles considered by us the most relevant were obtained from the Commission for Improvement of Higher Education Personnel (*Comissão de Aperfeiçoamento de Pessoal de Nível Superior – CAPES*) online source.

RESULTS

Pathogenesis

Paroxysmal nocturnal haemoglobinuria (PNH) is an acquired disease of haematopoietic stem cells (HSC), arising most commonly from a loss-of-function mutation in the PIG-A gene (phosphatidylinositol glycan class A). PIG-A gene encodes a subunit of an enzymatic complex responsible for the assembly of GPI, a molecule that works as anchor to the attachment of extracellular proteins to plasma membrane. In PNH, due to the lack of proper GPI synthesis, GPI-anchored proteins (GPI-AP) are partially or completely absent in the surface of all haematopoietic lineages. Besides PIG-A gene mutation, any other genetic abnormality impairing proper synthesis of GPI-AP may lead to PNH, with many possible genetic mutations reported in literature. Some of the reported alternative mutated genes were PIG-M, PIG-T, PIG-V, PIG-Y, PIG-L, and CD59². All haematopoietic lineages lack GPI-AP, therefore not only red blood cells (RBCs) are involved in the disease, but also leukocytes and platelets.

In healthy individuals, a small percentage of haematopoietic cells (probably colony-forming cells) may carry mutations compatible with PNH and, therefore, their derived cells are GPI-AP deficient. However, these cells are not numerous enough to produce clinical manifestations. In order to achieve an overt PNH phenotype, two other issues should be addressed. First, the cells bearing the genetic abnormalities must be HSC, which have a virtually unlimited self-renewal capacity and endless production of GPI-AP-deficient blood elements. Second, these HSC

must undergo clonal expansion^{2,13,14}, increasing the population of GPI-AP-deficient cells in the peripheral blood. There are mainly two hypothetical mechanisms for clonal expansion in PNH. First, it is believed that the cells bearing the mutations acquire other genetic abnormalities, which provide them a survival advantage. Second, in some cases the mechanism underlying clonal expansion requires the association of PNH and other haematological disorders, such as aplastic anaemia, in which the autoimmune destruction is mainly directed to healthy HSC, possibly because PNH-HSC lack in their membrane the target antigens². Moreover, the development of PNH may also be associated with myelodysplastic syndrome².

Clinical manifestations

The deficiency of CD55 and CD59 is the main source of clinical manifestations in the pathogenesis of PNH. These two proteins are characterized structurally as GPI-AP (thus are absent in PNH HSC-derived blood elements) and functionally as inhibitors of the complement system. Abrogation of these proteins is followed by complement-mediated cell damage. Most of the mechanisms responsible for the clinical features found in PNH are derived from complement-mediated injury (Figures 1 and 2). Frequent manifestations of the disease are haemolytic anaemia (mechanisms of haemolysis and anaemia in PNH are summarized in Figure 1)^{2,13,14,15} and thrombotic events (mechanisms of thrombosis in PNH are summarized in Figure 2)^{2,13, 14, 16}. Some of the com-

mon sites of thrombosis in PNH patients are: hepatic veins (Budd-Chiari syndrome); portal, splanchnic and mesenteric veins; cavernous and sagittal sinuses; dermal veins; deep leg veins (which may progress to pulmonary embolism), and coronary and cerebral arteries. Smooth muscle dystonia may also be present. It stems from the nitric oxide (an important smooth muscle relaxant) scavenging by the free Hb molecules released by lysed red blood cells^{2,13}. Smooth muscle dystonia manifests as abdominal pain, erectile dysfunction, and oesophageal spasms. Other possible clinical manifestations of the disease are fatigue and kidney injury.

Kidney injury

In 1971, Rubin¹⁷ reported the first case of PNH with massive haemolysis causing AKI. Apart from the haemolytic crisis, the patient did not present any other condition that could explain the renal injury. Following Rubin's work, many reports showed the variety of renal lesions that could arise from PNH. The acute setting is commonly severe, frequently requiring dialysis, while chronic injury is insidious and potentially associated with high morbidity. Clark et al.¹⁸ studied the renal function in 21 patients with PNH followed for 20 years. In this study, the authors linked the haemolytic crises with AKI, which tended to recover without providing further renal impairments, and also associated PNH with CKD and tubular reabsorption defects. Post-mortem analyses of subjects in the study suggested renal haemosider-

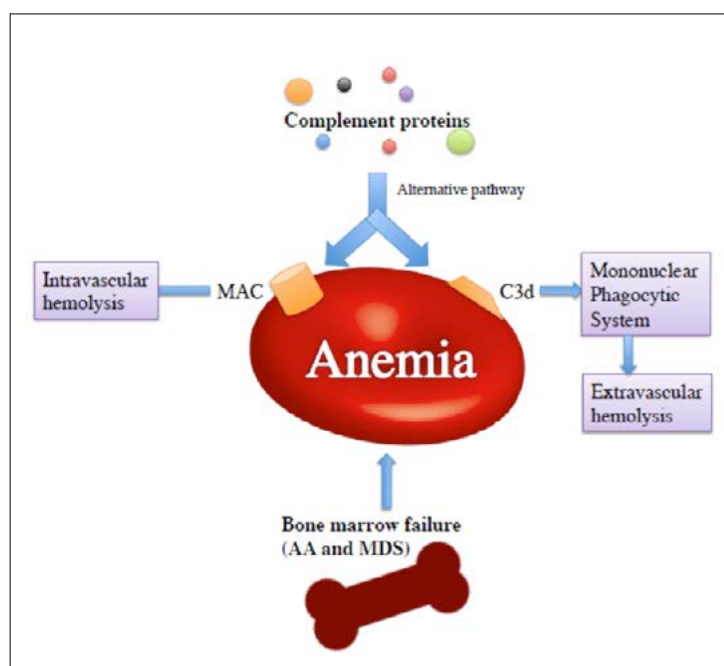


FIGURE 1 - MECHANISMS OF ANAEMIA IN PNH.

Anaemia in PNH may occur due to several factors. First, the alternative pathway activation of the complement system will lead to the formation of MAC, which will produce intravascular haemolysis, a mechanism which is the major pathogenic factor of anaemia in non-treated individuals. Second, red blood cells are marked with C3d produced by the activation of the complement system. Cells marked with this molecule are recognized and cleared from the circulation by macrophages of the mononuclear phagocytic system in a process called extravascular haemolysis, which is the primary culprit of anaemia in Eculizumab-treated individuals. Third, in patients with PNH associated with aplastic anaemia and myelodysplastic syndrome, bone marrow failure contributes to the development of anaemia.

Abbreviations: AA: aplastic anaemia; MAC: membrane attack complex; MDS: myelodysplastic syndrome. Author: Énio Simas Macedo.

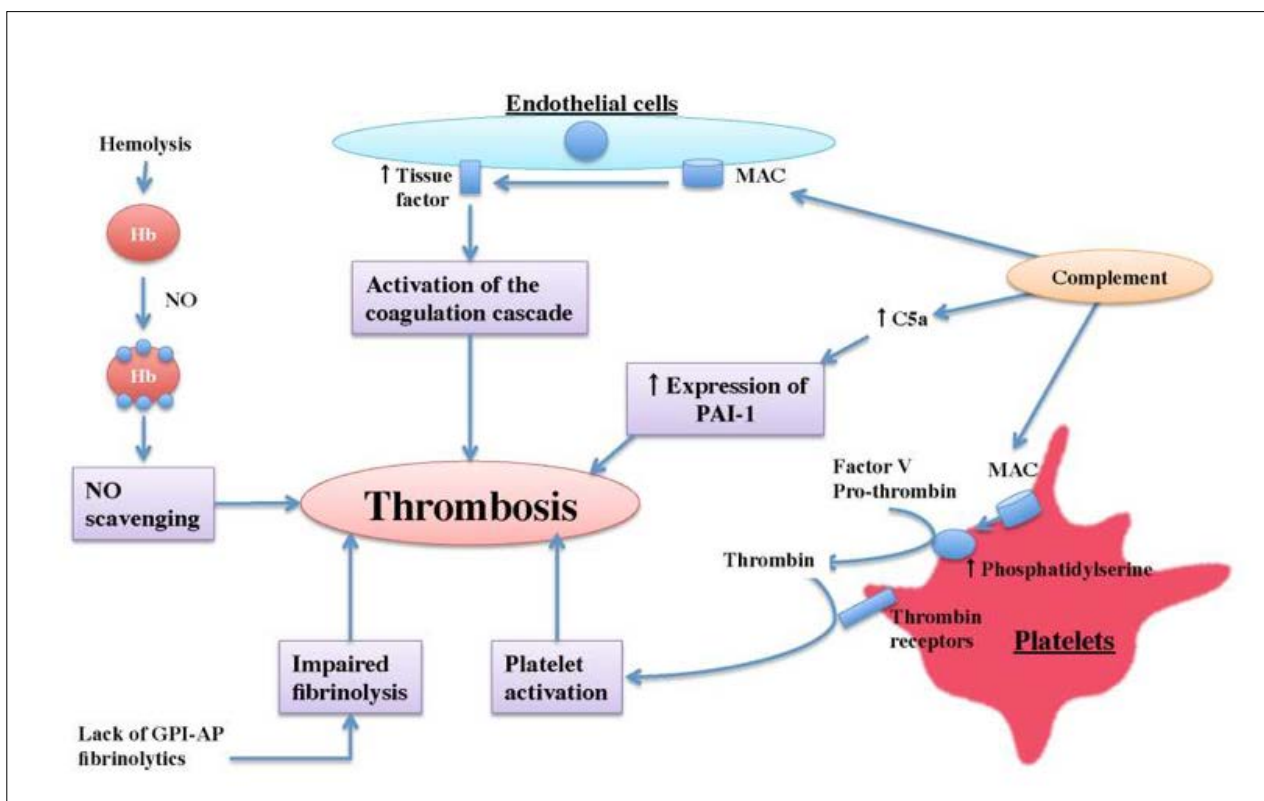


FIGURE 2 - MECHANISMS OF THROMBOSIS IN PNH.

Thrombosis in PNH is multifactorial. Complement activation leads to the formation of MAC in the surface of endothelial cells and platelets. The former cells express tissue factor in response to injury, which then activates the coagulation cascade. Platelets attacked by MAC expose in their surface phosphatidylserine, leading to factor V aggregation, followed by thrombin production. This enzyme interacts with receptors in platelets, provoking the activation of these cells. Complement activation also produces C5a, which upregulates the expression of PAI-1, an inhibitor of the fibrinolytic system. Additionally, lysed red blood cells release free-Hb (which acts as a NO scavenger) and erythrocyte arginase (an enzyme that degrades arginine, the substrate of NO synthesis). Finally, the proper function of the fibrinolytic system requires some GPI-AP, which are lacking in PNH patients.

Abbreviations: GPI-AP: GPI-anchored proteins; Hb: haemoglobin; MAC: membrane attack complex; NO: nitric oxide; PAI-1: plasminogen activator inhibitor 1. Author: Enio Simas Macedo.

osis, interstitial fibrosis, and microvascular infarcts as possible pathophysiological sources of renal impairment.

Renal impairment in PNH may range from tubular concentration defects to dialytic acute kidney injury and chronic kidney disease. PNH patients have a greater than six-fold increased risk of developing CKD². Furthermore, the presence of renal involvement augments mortality after 40 years of follow-up in 3-fold for patients with AKI or 6-fold for patients with CKD³.

The mechanism involved in the development of renal damage in PNH seems to differ in acute and chronic lesions. AKI is commonly associated with episodes of haemolysis exacerbation, which may be related to infections, exercise, stress, and alcohol and drug use. As haemolysis augments, there is an increased amount of free-haemoglobin released in plasma, which is subsequently filtered by renal

glomeruli. Filtered haemoglobin mediates direct toxic tubular injury, especially in the proximal convoluted tubules (PCT), by the production of reactive oxygen species (ROS). A putative mechanism that may exacerbate the PCT damage is the conversion of haemoglobin into methaemoglobin by the acidic pH of distal convoluted tubules (DCTs). Methaemoglobin, in turn, precipitates in the DCTs, leading to urinary stasis, increased PCT haemoglobin absorption and ROS-mediated damage. Moreover, ischemic features in the setting of massive haemolysis are also capable of exacerbating tubular damage. All those mechanisms may cause acute tubular necrosis, followed by AKI⁵.

Mechanisms involved with CKD development are different from those of AKI. In PNH, chronic haemolysis and haemoglobin filtration lead to marked renal tubular haemosiderosis. Haemosiderin deposits are clinically observed in biopsy samples and MRI.

It is generally believed that haemosiderin may lead to interstitial fibrosis, however the exact role of these deposits in CKD development is still controversial. Classical putative mechanisms of PNH-related CKD are micro-infarcts (derived from microvascular thrombotic events) and interstitial fibrosis⁵.

There have also been some reports of PNH and glomerular diseases, such as IgA nephropathy, focal segmental glomerulosclerosis, and membranous nephropathy. However, glomerular involvement in PNH is uncommon^{19,20,21}.

There is little experience on renal transplantation due to PNH-related end-stage CKD. Vanwalleghem et al. reported a case of a 60-year-old PNH patient, who was transfusion dependent. The patient underwent renal transplantation, with an initially significant reduction in haemolysis and no more need for transfusion. However, a new haemolytic crisis occurred within 9 months, and, posteriorly, the cortical haemosiderosis of the transplanted kidney was evidenced by MRI.

Mechanisms of renal injury in PNH were schematically summarized in figure 3.

DIAGNOSIS OF PNH

Flow cytometry is the gold standard for PNH diagnosis since it is capable of evaluating GPI-anchored proteins with high sensitivity and specificity. This technology is widely available in haematology and immunology laboratories that use flow cytometry both in research and in daily clinical practice.

The study of PNH populations is routinely performed on peripheral blood samples. Flow cytometry is performed by targeting a variety of GPI-linked proteins, and CD55 and CD59 are the most important proteins evaluated. However, false-positive diagnosis of PNH occurs if these are used alone due to the presence of rare congenital deficiencies of CD55 and CD59². Ideally, at least two different monoclonal antibodies directed against two different GPI-anchored proteins on at least two different cell lineages should be used to diagnose PNH.

Previous diagnostic methods were erythrocyte-based, and included the Ham test, the sucrose haemolysis test, and the complement lysis assay. These tests have now been abandoned, especially the erythrocyte-based ones, since they can give false

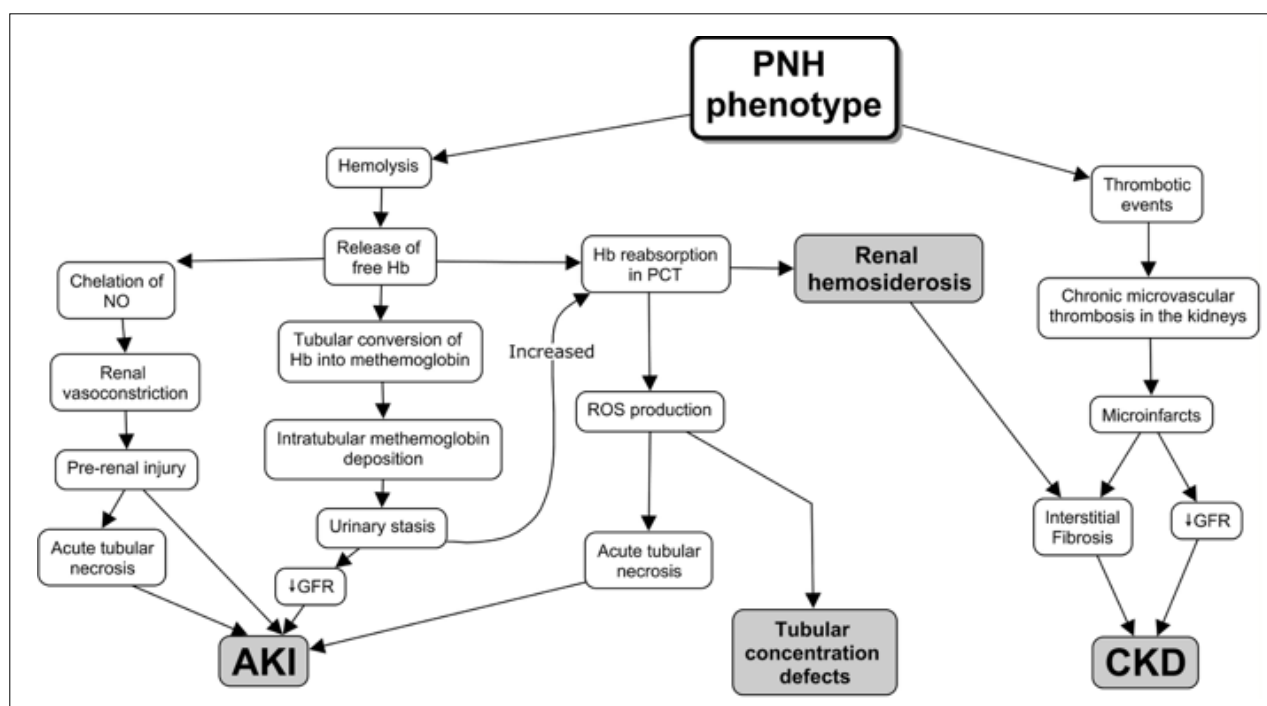


FIGURE 3 - MECHANISMS OF RENAL INJURY IN PNH.

Free haemoglobin release in haemolytic episodes, leading to renal vasoconstriction, methaemoglobin formation, renal haemosiderosis, and PCT toxicity, contribute to the development of AKI and tubular concentration defects, whereas thrombosis of the renal vasculature associated with the deleterious effects of haemosiderosis apparently plays an essential role in CKD development.

Abbreviations: AKI: Acute Kidney Injury; CKD: Chronic Kidney Disease; GFR: Glomerular Filtration Rate; Hb: Haemoglobin; NO: Nitric Oxide; PCT: Proximal Convoluted Tubule; PNH: Paroxysmal Nocturnal Haemoglobinuria; RBCs: Red Blood Cells; ROS: Reactive Oxygen Species. Author: Énio Simas Macedo.

negative results following red blood cell transfusions or haemolysis⁹.

The complement lysis sensitivity test is a more specific type of test, measuring the amount of haemolysis at varying concentrations of complement. This assay showed that PNH cells lysed at lower concentrations than normal cells. This test also led to the recognition that some PNH patients have a population of cells with intermediate complement sensitivity (Type II), normal red blood cells (Type I), and the most abnormal PNH-type red blood cells (Type III)²². However, this test is laborious, difficult to standardize and may miss small populations of abnormal cells⁷.

INDICATIONS FOR THE STUDY OF POPULATIONS OF PNH

The study of PNH is indicated in patients who present one or more of the following manifestations⁸:

- Haemolytic anaemia with negative direct Coombs test.
- Haemoglobinuria.
- Unexplained venous or arterial thrombosis in patients who meet one of the following criteria: young patients, thrombosis in unusual locations (intra-abdominal veins, Budd-Chiari syndrome, brain, dermis, etc.), evidence of haemolysis and/or cytopenia.
- Intermittent dysphagia or abdominal pain of unclear aetiology with evidence of haemolysis.
- Aplastic anaemia (at diagnosis and during annual follow-up).
- Hypoplastic myelodysplastic syndrome.
- Idiopathic and maintained cytopenias of uncertain significance.

PNH classification

The International PNH Interest Group (I-PIG) includes three main categories that cover the spectrum of disease presentation and has proposed a classification scheme for PNH²³:

- Classical PNH, which includes haemolytic and thrombotic patients.
- PNH in the context of other primary disorders, such as aplastic anaemia (AA/PNH) or myelodysplastic syndrome (MDS/PNH).
- Subclinical PNH (scPNH), in which patients have small PNH clones but no clinical or laboratory evidence of haemolysis or thrombosis.

However, although the overall purpose of such

classification scheme is to provide a common international terminology for the disorder, it has resulted in some confusion since varying degrees of bone marrow failure underlie virtually all cases of PNH. Thus, in some cases it may be difficult to distinguish between the three categories.

TREATMENT

The only available options for the treatment of PNH are the C5 inhibitor (Eculizumab) and HSCT. The latter eradicates PNH clone cells and is the only curative therapy, but is associated with a high rate of morbidity and mortality; therefore it is indicated only as frontline therapy for patients with PNH associated with aplastic anaemia. Other controversial indications are PNH in patients presenting with severe complications of the disease despite Eculizumab therapy or for those who do not have access to Eculizumab¹⁰.

Patients who present scPNH do not typically progress to clinical PNH¹⁰. PNH specific therapy is not indicated in the absence of clinical manifestations. The majority of patients presenting MDS/PNH and AA/PNH have relatively small PNH clones, and haemolysis is typically an incidental finding, thus only few patients require Eculizumab treatment and the therapy must focus on the bone marrow failure syndrome¹³.

Eculizumab therapy

The complement-mediated intravascular haemolysis of PNH can be inhibited by blocking the assembly of MAC. Eculizumab is a humanized monoclonal antibody against C5 that inhibits terminal complement activation. The prevention of C5 cleavage blocks the generation of the potent pro-inflammatory and cell lytic molecules, respectively C5a and C5b-9¹¹. Thus, Eculizumab is highly effective in reducing intravascular haemolysis in PNH, but it does not target extravascular haemolysis and bone marrow failure. In a study with 195 patients, treatment with Eculizumab was effective to rapidly decrease lactate dehydrogenase (LDH) levels - a haemolysis marker - which was sustained as long as the patients were under treatment, although a few patients have presented a transient elevation of LDH serum. The same study showed that the percentage of patients presenting thrombotic events decreased from 32.3% to 3.6%¹².

Eculizumab is generally well tolerated. Commonly reported adverse events in clinical trials included headache, nasopharyngitis, back pain, and nausea¹². This therapy increases the risk of *Neisseria* infections, including meningitis and sepsis. Therefore, patients must be vaccinated two weeks prior to the beginning of treatment and should be revaccinated with the tetravalent conjugate vaccine for *N. meningitidis* every 3 years after starting the therapy²⁴. Other common approach for *Neisseria* prevention is the use of continuous prophylactic penicillin.

Impact of Eculizumab in renal function

Eculizumab reduces intravascular haemolysis and haemoglobinuria events in patients presenting CKD. A cohort has shown that after 36 months of Eculizumab therapy, there was an improvement or maintenance of renal function in 94.5% of patients. Improvement in renal function was more commonly seen in patients with baseline CKD Stages 1–2 (67.1% improvement, $P < 0.001$). Overall, 40 (21%) of 195 patients who had renal dysfunction or damage at baseline were no longer classified as such after 18 months of treatment²⁵.

Future perspectives

Inhibitors of the small molecule factor D (compounds ACH-3856 and ACH-4471) significantly re-

duced complement-mediated haemolysis. This promising agents can be taken orally and act by blocking the alternative pathway of complement activation in PNH. Additionally, the compound ACH-4471 significantly decreased C3 fragment deposition on paroxysmal nocturnal haemoglobinuria erythrocytes, indicating a reduced potential relative to Eculizumab for extravascular haemolysis. ACH-4471 has been selected for clinical development in PNH and is currently in phase 1 clinical study²⁶.

CONCLUSION

There is lack of information in the literature concerning renal function in PNH. Nevertheless, we may conclude that acute and chronic renal injury mechanisms differ in the setting of the haemolysis and its repercussions. While acute injury relates with the haemolysis itself, leading to haemoglobinuria and its deleterious effects in patient's kidneys, chronic injury is mainly associated with micro-infarcts and interstitial fibrosis.

Eculizumab therapy has been proven to reduce the occurrence of haemolysis, and consequently, of haemoglobinuria, decreasing AKI incidence. Moreover, the treatment is also related with lower rates of thrombosis, and is capable of maintaining or improving renal function in patients presenting CKD.

RESUMO

INTRODUÇÃO: A hemoglobinúria paroxística noturna (HPN) é uma doença genética adquirida, caracterizada por hemólise mediada pelo sistema complemento, eventos trombóticos e citopenias variáveis. Envolvimento renal pode ocorrer, contribuindo com morbidade significativa nesses pacientes.

OBJETIVO: Realização de revisão de literatura sobre o envolvimento renal na HPN.

MÉTODOS: Pesquisa on-line na base de dados Medline, com compilação e análise dos 26 estudos encontrados de maior relevância.

RESULTADOS: A HPN pode se apresentar com insuficiência renal aguda induzida por hemólise maciça, que geralmente tem apresentação grave. Em quadros crônicos, declínio insidioso da função renal pode ocorrer por depósitos tubulares de hemossiderina, micro-infarctos renais e fibrose intersticial. Apesar de o transplante de células-tronco hematopoiéticas permanecer como a única terapia curativa para a HPN, a droga Eculizumab é capaz de melhorar a função renal, entre outros desfechos, por meio da inibição de C5 e a subsequente ativação da cascata do complemento, que culminaria com a formação do complexo de ataque à membrana.

CONCLUSÃO: Há poucas informações na literatura no que concerne ao envolvimento renal na HPN, apesar de ser possível estabelecer que os mecanismos fisiopatológicos das lesões agudas e crônicas são distintos. Apesar de não ser uma terapia curativa, Eculizumab é capaz de amenizar o comprometimento renal nesses pacientes.

PALAVRAS-CHAVE: Hemoglobinúria paroxística noturna. Lesão renal aguda. Doenças Renais Crônicas.

REFERENCES

- Hill A, DeZern AE, Kinoshita T, Brodsky RA. Paroxysmal nocturnal haemoglobinuria. *Nat Rev Dis Primers* 2017 May 18;3:17028.
- Brodsky RA. Paroxysmal nocturnal haemoglobinuria. *Blood* 2014;124(18):2804-2811.
- Jang JH, Kim JS, Yoon SS, Lee JH, Kim YK, Jo DY, et al. Predictive Factors of Mortality in Population of Patients with Paroxysmal Nocturnal Haemoglobinuria (PNH): Results from a Korean PNH Registry. *J Korean Med Sci* 2016;31(2):214-221.
- Zager RA, Gamelin LM. Pathogenetic mechanisms in experimental haemoglobinuric acute renal failure. *Am J Physiol* 1989;256(3 Pt 2):F446-455.
- Nair RK, Khaira A, Sharma A, Mahajan S, Dinda AK. Spectrum of renal involvement in paroxysmal nocturnal haemoglobinuria: report

- of three cases and a brief review of the literature. *Int Urol Nephrol* 2008;40(2):471-475.
6. Shinde SN, Agarwal MB. Renal low-signal intensity on magnetic resonance imaging in a case of paroxysmal nocturnal haemoglobinuria. *Br J Haematol* 2005;131(5):559.
 7. Hall SE, Rosse WF. The use of monoclonal antibodies and flow cytometry in the diagnosis of paroxysmal nocturnal haemoglobinuria. *Blood* 1996;87(12):5332-5340.
 8. Villegas A., Arrizabalaga B., Bonanad S., Colado E., Gaya A., González A., et al. Grupo de Trabajo de HPN de la Sociedad Española de Hematología y Hemoterapia. Consenso español para el diagnóstico y tratamiento de la haemoglobinuria paroxística nocturna. *Med Clin (Barc)* 2016 Mar 18; 146(6):278.e1-7.
 9. Brodsky RA. How I treat paroxysmal nocturnal haemoglobinuria. *Blood* 2009;113(26):6522-6527.
 10. Parker CJ. Update on the diagnosis and management of paroxysmal nocturnal haemoglobinuria. *Hematology Am Soc Hematol Educ Program* 2016;2016(1):208-216.
 11. Rother RP, Rollins SA, Mojcik CF, Brodsky RA, Bell L. Discovery and development of the complement inhibitor Eculizumab for the treatment of paroxysmal nocturnal haemoglobinuria. *Nat Biotechnol* 2007;25(11):1256-1264.
 12. Hillmen P, Muus P, Röth A, Elebute MO, Risitano AM, Schrezenmeier H, et al. Long-term safety and efficacy of sustained Eculizumab treatment in patients with paroxysmal nocturnal haemoglobinuria. *Br J Haematol* 2013;162(1):62-73.
 13. Pu JJ, Brodsky RA. Paroxysmal nocturnal haemoglobinuria from bench to bedside. *Clin Transl Sci* 2011;4(3):219-224.
 14. DeZern AE, Brodsky RA. Paroxysmal nocturnal haemoglobinuria: a complement-mediated haemolytic anemia. *Hematol Oncol Clin North Am* 2015;29(3):479-494.
 15. Parker C. Eculizumab for paroxysmal nocturnal haemoglobinuria. *Lancet* 2009;373(9665):759-767.
 16. Hill A, Kelly RJ, Hillmen P. Thrombosis in paroxysmal nocturnal haemoglobinuria. *Blood* 2013;121(25):4985-4996; quiz 5105.
 17. Rubin H. Paroxysmal nocturnal haemoglobinuria with renal failure. *JAMA* 1971;215(3):433-436.
 18. Clark DA, Butler SA, Braren V, Hartmann RC, Jenkins DE. The kidneys in paroxysmal nocturnal haemoglobinuria. *Blood* 1981;57(1):83-89.
 19. Kato K, Shibata T, Mukai K, Kitazawa K, Sugisaki T. [Case of paroxysmal nocturnal haemoglobinuria complicated with IgA nephropathy who developed acute renal failure induced by haemolytic crisis]. *Nihon Jinzo Gakkai Shi* 2005;47(5):540-546.
 20. Takahashi K, Yoshimura A, Inoue Y, Takahashi N, Sugeno Y, Morita H, et al. [A case of paroxysmal nocturnal haemoglobinuria combined with focal segmental glomerular sclerosis]. *Nihon Jinzo Gakkai Shi* 2001;43(1):39-43.
 21. Lee GW, Lee JH, Kim SB, Yu ES, Lee JL, Ryu MH, et al. Membranous glomerulopathy as a manifestation of chronic graft-versus-host-disease after non-myeloablative stem cell transplantation in a patient with paroxysmal nocturnal haemoglobinuria. *J Korean Med Sci* 2003;18(6):901-904.
 22. Rosse WF, Hoffman S, Campbell M, Borowitz M, Moore JO, Parker CJ. The erythrocytes in paroxysmal nocturnal haemoglobinuria of intermediate sensitivity to complement lysis. *Br J Haematol* 1991;79(1):99-107.
 23. Parker C, Omine M, Richards S, Nishimura J, Bessler M, Ware R, et al. Diagnosis and management of paroxysmal nocturnal haemoglobinuria. *Blood* 2005;106(12):3699-3709.
 24. Alashkar F, Vance C, Herich-Terhürne D, Preising N, Dührsen U, Röth A. Serologic response to meningococcal vaccination in patients with paroxysmal nocturnal haemoglobinuria (PNH) chronically treated with the terminal complement inhibitor Eculizumab. *Ann Hematol* 2017;96(4):589-596.
 25. Hillmen P, Elebute M, Kelly R, Urbano-Ispizua A, Hill A, Rother RP, et al. Long-term effect of the complement inhibitor Eculizumab on kidney function in patients with paroxysmal nocturnal haemoglobinuria. *Am J Hematol* 2010;85(8):553-559.
 26. Yuan X, Gavrilaki E, Thanassi JA, Yang G, Baines AC, Podos SD, et al. Small-molecule factor D inhibitors selectively block the alternative pathway of complement in paroxysmal nocturnal haemoglobinuria and atypical haemolytic uremic syndrome. *Haematologica* 2017;102(3):466-475.

