

The differential diagnoses include other diseases affecting the trachea, not only those presenting localized involvement—such as primary tracheal neoplasms, injuries of traumatic origin, and some infectious diseases—but also those presenting diffuse involvement—amyloidosis, tracheobronchopathia osteochondroplastica, relapsing polychondritis, laryngotracheobronchial papillomatosis, tracheobronchomegaly, neurofibromatosis, Wegener's granulomatosis, lymphoma, and paracoccidioidomycosis^(5,7–12).

Imaging studies have become increasingly important in the evaluation of chest diseases, as recently noted in the radiology literature of Brazil^(13–19). In the study of the trachea, imaging studies comprise X-rays and, primarily, CT of the chest, which can show irregular, circumferential narrowing of the lumen, with or without mediastinitis. In fibrotic disease, the lumen is smoother and the wall is not thickened. Lymphadenopathy is generally associated with active tuberculosis^(4,6).

Bronchoscopy can reveal inflamed mucosa, submucosal granuloma or polyp, ulceration, hypertrophy, or cicatricial stenosis; histologically, tracheobronchial tuberculosis can be identified the presence of giant cell granuloma and caseous necrosis⁽¹⁾. Although the gold standard for the diagnosis of tracheobronchial tuberculosis is the finding of granulomas in the tracheal/bronchial mucosa, a diagnosis based on imaging findings and sputum positivity is accepted and enables immediate treatment⁽²⁾.

Making a diagnosis of tracheobronchial tuberculosis requires suspicion, and it is necessary to correlate the clinical manifestations with the radiological findings. Early diagnosis and treatment can avert the complications of the disease.

REFERENCES

1. Lee JH, Park SS, Lee DH, et al. Endobronchial tuberculosis. Clinical and bronchoscopic features in 121 cases. *Chest*. 1992;102:990–4.
2. Morrone N, Abe NS. Bronchoscopic findings in patients with pulmonary tuberculosis. *J Bronchol*. 2007;14:15–8.
3. Arora A, Bhalla AS, Jana M, et al. Overview of airway involvement in tuberculosis. *J Med Imaging Radiat Oncol*. 2013;57:576–81.
4. Moon WK, Im JG, Yeon KM, et al. Tuberculosis of the central airways: CT findings of active and fibrotic disease. *AJR Am J Roentgenol*. 1997;169:649–53.
5. Marchiori E, Pozes AS, Souza Jr AS, et al. Alterações difusas da traqueia: aspectos na tomografia computadorizada. *J Bras Pneumol*. 2008;34:47–54.

6. Smati B, Boudaya MS, Ayadi A, et al. Tuberculosis of the trachea. *Ann Thorac Surg*. 2006;82:1900–1.
7. Gasparetto TD, Azevedo FB, Toledo A, et al. Primary tracheal non-Hodgkin lymphoma: case report with an emphasis on computed tomography findings. *J Thorac Imaging* 2010;25:W24–6.
8. Marchiori E, Zanetti G, Mano CM. Tracheobronchial papillomatosis with diffuse cavitory lung lesions. *Pediatr Radiol*. 2010;40:1301–2.
9. Marchiori E, Araujo Neto C, Meirelles GSP, et al. Laryngotracheobronchial papillomatosis: findings on computed tomography scans of the chest. *J Bras Pneumol*. 2008;34:1084–9.
10. Marchiori E, Escuissato DL, Souza Jr AS, et al. Computed tomography findings in patients with tracheal paracoccidioidomycosis. *J Comput Assist Tomogr*. 2008;32:788–91.
11. Azeredo F, Severo A, Zanetti G, et al. Floppy ears and tracheal wall narrowing. *Neth J Med*. 2012;70:417–21.
12. Hochhegger B, Guimarães MD, Marchiori E. Thacheal paraganglioma: differential diagnosis of a contrast-enhanced tracheal mass. *AJR Am J Roentgenol*. 2014;202:w598.
13. Lachi T, Nakayama M. Radiological findings of pulmonary tuberculosis in indigenous patients in Dourados, MS, Brazil. *Radiol Bras*. 2015;48:275–81.
14. Barbosa BC, Marchiori E, Zanetti GMR, et al. Catamenial pneumothorax. *Radiol Bras*. 2015;48:128–9.
15. Francisco FAF, Rodrigues RS, Barreto MM, et al. Can chest high-resolution computed tomography findings diagnose pulmonary alveolar microlithiasis? *Radiol Bras*. 2015;48:205–10.
16. Guimarães MD, Hochhegger B, Koenigk-Santos M, et al. Magnetic resonance imaging of the chest in the evaluation of cancer patients: state of the art. *Radiol Bras*. 2015;48:33–42.
17. Batista MN, Barreto MM, Cavaguti RF, et al. Pulmonary artery sarcoma mimicking chronic pulmonary thromboembolism. *Radiol Bras*. 2015;48:333–4.
18. Guimarães MD. Pulmonary tuberculosis in Brazilian indians: a picture of this context depicted through radiography. *Radiol Bras*. 2015;48(5):v–vi.
19. Silva Junior GM, Zanetti GMR, Barillo JL, et al. Peripheral primitive neuroectodermal tumor of chest wall in young adult. *Radiol Bras*. 2015;48:59–60.

Brainner Campos Barbosa¹, Viviane Brandão Amorim², Luiz Flávio Maia Ribeiro², Edson Marchiori³

1. Hospital Samaritano – Clínica Luiz Felipe Mattoso, Rio de Janeiro, RJ, Brazil. 2. Clínica Felipe Mattoso, Rio de Janeiro, RJ, Brazil. 3. Universidade Federal do Rio de Janeiro (UFRJ), Rio de Janeiro, RJ, Brazil. Mailing address: Dr. Brainner Campos Barbosa. Rua das Laranjeiras, 371, ap. 303, Laranjeiras. Rio de Janeiro, RJ, Brazil, 22240-004. E-mail: brainnerc@gmail.com.

<http://dx.doi.org/10.1590/0100-3984.2015.0200>

Immune reconstitution inflammatory syndrome, with pulmonary and neurological cryptococcosis, in an HIV-negative patient

Dear Editor,

A 26-year-old male presented with complaints of cough and fever for a few days. He reported having followed a weight loss program for the last four months, having lost 20 kg. He reported no comorbidities.

Chest X-ray showed pulmonary consolidation in the left lung. A complete blood count showed leukocytosis and a lymphocyte count at the lower limit of normality. Subsequent X-rays, during antibiotic therapy, showed an increase in the consolidation. Computed tomography of the chest showed left lung consolidation with air bronchogram and a partially rounded hilar opacity, both containing areas of hypointense signals (Figure 1A), raising the hypothesis of an infectious or neoplastic process. Because he developed mental confusion, seizures, and postural instability, the patient was submitted to magnetic resonance imaging (MRI) of the

brain, which showed multiple intraparenchymal cystic lesions (Figure 1B), with no enhancement and minimal edema at the borders.

Pathological examination of a biopsy sample obtained from the pulmonary consolidation revealed fungal infection with characteristics of deep cryptococcal mycosis. Staining with mucicarmine showed a mucin-positive capsule. The serology was negative for HIV, as well as for hepatitis B and C. Treatment was started with fluconazole, alternated with amphotericin B. During hospitalization, the general status of the patient became unstable and he was submitted to tracheostomy, subsequently developing tracheal candidiasis. After clinical improvement, he was discharged to outpatient follow-up, with home therapy and attention to an appropriate diet.

Five weeks after discharge, the patient was readmitted to the hospital with worsening neurological status. Another MRI of the brain showed the development of marked, progressive perilesional vasogenic edema (Figure 1C) and significant enhancement of

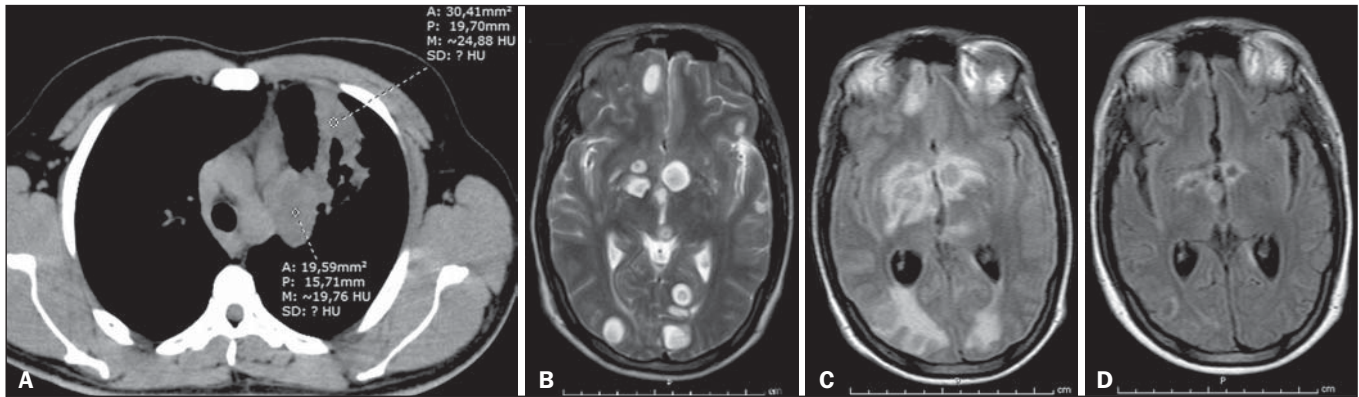


Figure 1. A: Axial computed tomography of the chest showing consolidation with air bronchogram and partially rounded hilar opacity, both presenting areas of low signal intensity, in the upper lobe of the left lung. **B:** Initial MRI of the brain. Scan with T2-weighted turbo spin-echo sequence showing multiple rounded cystic formations of varying dimensions scattered throughout the cerebral and cerebellar parenchyma, as well as in the left thalamus and nucleocapsular regions, having a discrete compressive effect and no signs of significant perilesional edema. **C:** Follow-up MRI of the brain. Scan with fluid-attenuated inversion recovery sequence, performed five weeks after the start of fluconazole therapy and the restoration of adequate nutrition, showing intense perilesional vasogenic edema indicating a reactive inflammatory process that was nearly undetectable at the beginning of treatment, due to immunosuppression. **D:** Follow-up MRI of the brain. Scan with fluid-attenuated inversion recovery-weighted sequence, performed five weeks after the start of corticosteroid therapy, when the patient was still under treatment with fluconazole, showing significant regression of the edema around the brain lesions, as well as a reduction in the size of the lesions.

the lesions by the paramagnetic contrast agent. Examination of the cerebrospinal fluid showed that there was no infection with *Cryptococcus* or any other agents, indicating an effective response to the treatment. The combination of clinical and radiological worsening, despite an effective treatment response, in a patient with evidence of immunosuppression (probably due to nutritional restriction), strongly suggested immune reconstitution inflammatory syndrome (IRIS). The antifungal therapy was maintained, and corticosteroid therapy was started, resulting in significant clinical improvement and regression of the lesions seen on follow-up imaging studies (Figure 1D).

In immunocompromised patients, cryptococcosis is common and is mainly caused by inhalation of *Cryptococcus neoformans* or *Cryptococcus gattii*⁽¹⁻⁴⁾. Many patients with cryptococcosis develop pulmonary colonization, which is often asymptomatic. The symptoms become pronounced when they evolve to meningoencephalitis, presenting high tropism for the leptomeninges⁽¹⁻⁵⁾. The presentations include masses and pulmonary consolidations^(1,3), gelatinous cystic formations in the brain, especially in the thalamus and basal nuclei⁽²⁾. The differential diagnoses include lung cancer with brain metastasis^(3,4). The diagnosis is made by identifying the fungus in sputum samples, bronchoalveolar lavage fluid, cerebrospinal fluid, histological sections, or culture⁽⁴⁾. Fluconazole and amphotericin-B are therapeutic options^(2,4).

Malnutrition is a known cause of immunodeficiency, affecting the mechanisms of adaptive immunity^(5,6). Some patients with acquired immunodeficiency syndrome or immunosuppression develop IRIS, in which the immune system begins to recover, responding to a previously acquired opportunistic infection with an exuberant inflammatory response that paradoxically causes a worsening of the symptoms^(2,7,8). Here, we have described an unusual case suggestive of cryptococcosis-related IRIS in an HIV-

negative patient, probably developing immunosuppression due to nutritional restriction for weight loss.

REFERENCES

1. Fox DL, Müller NL. Pulmonary cryptococcosis in immunocompetent patients: CT findings in 12 patients. *AJR Am J Roentgenol.* 2005;185:622–6.
2. Saigal G, Post MJD, Lolayekar S, et al. Unusual presentation of central nervous system cryptococcal infection in an immunocompetent patient. *AJNR Am J Neuroradiol.* 2005;26:2522–6.
3. McAdams HP, Rosado-de-Christenson ML, Templeton PA, et al. Thoracic mycoses from opportunistic fungi: radiologic-pathologic correlation. *Radiographics.* 1995;15:271–86.
4. Severo CB, Gazzoni AF, Severo LC. Chapter 3 – Pulmonary cryptococcosis. *J Bras Pneumol.* 2009;35:1136–44.
5. Fontana MH, Coutinho MF, Camargo ES, et al. Neurocryptococcosis in childhood. Report of three cases in the first decade of life. *Arq Neuropsiquiatr.* 1987;45:403–11.
6. Chinen J, Shearer WT. Secondary immunodeficiencies, including HIV infection. *J Allergy Clin Immunol.* 2010;125(2 Suppl 2):S195–203.
7. Murdoch DM, Venter WDF, Van Rie A, et al. Immune reconstitution inflammatory syndrome (IRIS): review of common infectious manifestations and treatment options. *AIDS Res Ther.* 2007;4:9.
8. Somerville LK, Henderson AP, Chen SCA, et al. Successful treatment of *Cryptococcus neoformans* immune reconstitution inflammatory syndrome in an immunocompetent host using thalidomide. *Med Mycol Case Rep.* 2014;7:12–4.

Rodolfo Mendes Queiroz¹, Lara Zupelli Lauer¹, Marcus Vinicius Nascimento Valentin¹, Cecília Hissae Miyake¹, Lucas Giansante Abud¹

1. Documenta – Hospital São Francisco, Ribeirão Preto, SP, Brazil. Mailing Address: Dr. Rodolfo Mendes Queiroz. Documenta – Centro Avançado de Diagnóstico por Imagem. Rua Bernardino de Campos, 980, Centro. Ribeirão Preto, SP, Brazil, 14015-130. E-mail: rod_queiroz@hotmail.com.

<http://dx.doi.org/10.1590/0100-3984.2015.0139>

Neurocutaneous melanosis

Dear Editor,

A 12-year-old male patient presented with a delay in neuropsychomotor development that had been diagnosed in the first year of life. Two years prior (at 10 years of age), he had undergone ventricular shunt placement because of hydrocephalus. Six

months prior to the visit reported here, he had experienced episodes of seizures. Physical examination revealed multiple cutaneous nevi (Figure 1A). Cerebrospinal fluid examination showed an elevated level of protein (1359.7 mg/dL; reference range: 15.0–45.0 mg/dL) and revealed the presence of epithelioid cells. Magnetic resonance imaging (MRI) of the brain (Figures 1B, 1C, and 1D) showed extensive, bilateral, asymmetric leptomeningeal thick-