



REVISTA BRASILEIRA DE ANESTESIOLOGIA

Official Publication of the Brazilian Society of Anesthesiology
www.sba.com.br



CLINICAL INFORMATION

Anesthesia for EXIT procedure (ex utero intrapartum treatment) in congenital cervical malformation – a challenge to the anesthesiologist



Elsa Oliveira*, Paula Pereira, Carla Retroz, Emília Mártires

Department of Anesthesiology, Centro Hospitalar e Universitário de Coimbra, Coimbra, Portugal

Received 22 June 2013; accepted 22 July 2013

Available online 9 October 2015

KEYWORDS

EXIT procedure;
Ex-uterus
intrapartum
treatment;
Congenital cervical
malformation;
Anesthesia

Abstract The ex utero intrapartum treatment (EXIT) procedure consists of partial externalization of the fetus from the uterine cavity during delivery, allowing the maintenance of placental circulation. It is indicated in the presence of congenital malformation when difficulty in fetal airway access is anticipated, allowing it to be ensured by direct laryngoscopy, bronchoscopy, tracheostomy, or surgical intervention. Anesthesia for EXIT procedure has several special features, such as the appropriate uterine relaxation, maintenance of maternal blood pressure, fetal airway establishment, and maintenance of postpartum uterine contraction. The anesthesiologist should be prepared for the anesthetic particularities of this procedure in order to contribute to a favorable outcome for the mother and particularly the fetus.

© 2015 Sociedade Brasileira de Anestesiologia. Published by Elsevier Editora Ltda. All rights reserved.

PALAVRAS-CHAVE

Procedimento EXIT;
Tratamento
extraútero
intraparto;
Malformação
congénita cervical;
Anestesia

Anestesia para procedimento EXIT (tratamento extraútero intraparto) em malformação congênita cervical – um desafio para o anestesiolegista

Resumo O procedimento EXIT (tratamento extraútero intraparto) consiste na exteriorização parcial do feto da cavidade uterina durante o parto para permitir a manutenção da circulação fetoplacentária. Está indicado na presença de malformações congênicas em que se antecipa a dificuldade no acesso da via aérea fetal e permite que essa seja assegurada por laringoscopia direta, broncoscopia, traqueostomia ou intervenção cirúrgica. A anestesia para procedimento EXIT apresenta várias particularidades. O relaxamento uterino adequado, a manutenção da pressão arterial materna, o estabelecimento de via aérea fetal e a manutenção da contração

* Corresponding author.

E-mail: elsacsoliveira@gmail.com (E. Oliveira).

<http://dx.doi.org/10.1016/j.bjane.2013.07.020>

0104-0014/© 2015 Sociedade Brasileira de Anestesiologia. Published by Elsevier Editora Ltda. All rights reserved.

uterina pós-parto são alguns exemplos. O anestesiologista deve estar preparado para as particularidades anestésicas desse procedimento, de modo a contribuir para um desfecho favorável para a mãe e particularmente para o feto.

© 2015 Sociedade Brasileira de Anestesiologia. Publicado por Elsevier Editora Ltda. Todos os direitos reservados.

Background and objectives

Recent advances in prenatal diagnosis allow early detection of defects responsible for fetal airway obstruction that benefit from intrapartum treatment.¹

The EXIT procedure (ex utero intrapartum treatment) is indicated in the presence of these situations. It is performed during cesarean section and after partial externalization of the fetus from uterine cavity and consists of the fetoplacental circulation maintenance until the fetal airway is secured.²

It was originally described to reverse the tracheal occlusion performed in utero treatment of severe congenital diaphragmatic hernia. Currently, it is used in situations where the fetus has airway obstruction at the end of gestation. The procedure is usually scheduled after the 35th week of pregnancy and prematurity is not considered a contraindication.³

The anesthetic technique during the EXIT procedure differs from a normal cesarean section and has some peculiarities.

This article describes a case in which the EXIT procedure was performed successfully in fetus with prenatal diagnosis of submandibular cystic lymphangioma and discusses the anesthetic technique applied with a brief literature review.

Case report

A female patient, 35 years old, gravida 1/to 0, with 39 weeks of pregnancy, ASA II due to allergic rhinitis, presenting with fetus with right cervical mass diagnosed by prenatal ultrasound at 31 weeks of pregnancy (Fig. 1).

At 36 weeks, a magnetic resonance imaging (MRI) test was performed and confirmed an expansive lesion in the soft tissues of hemiface and proximal portion of the submandibular region and right cervical with 55 mm × 50 mm × 53 mm,

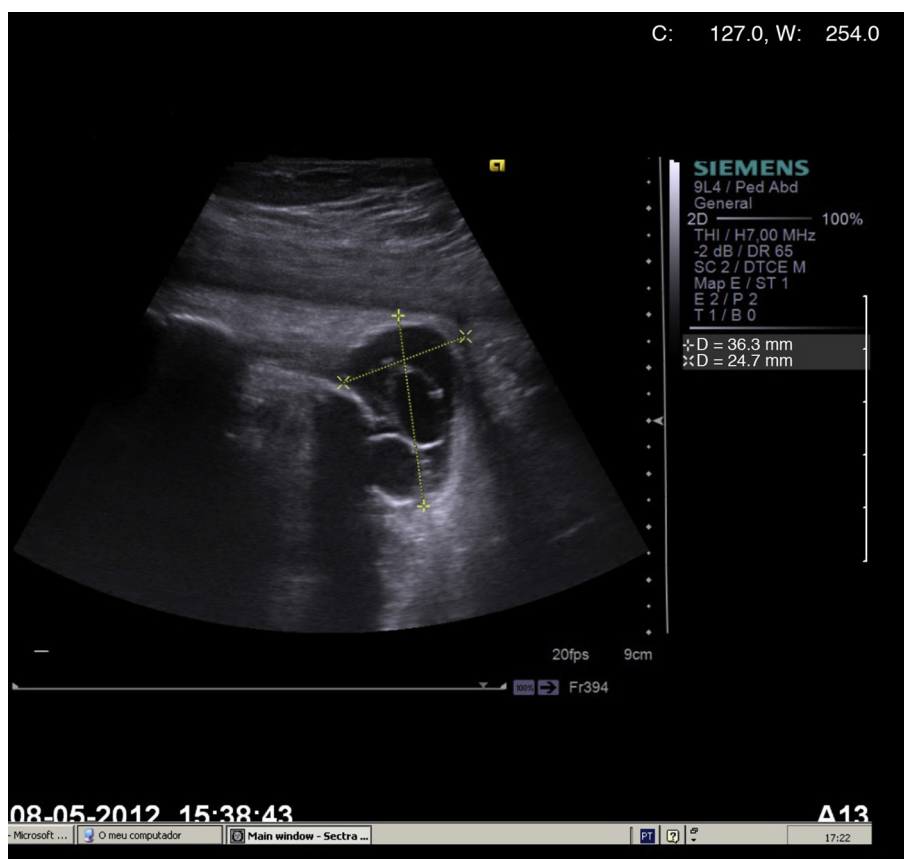


Figure 1 Prenatal ultrasound.

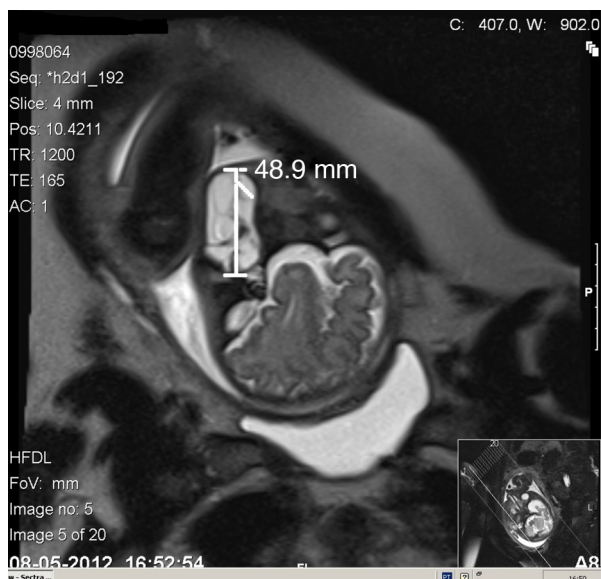


Figure 2 Fetal MRI.

associated with tongue protrusion/macroglossia with a diagnosis compatible with cystic lymphangioma (Fig. 2).

Elective cesarean section was scheduled with EXIT procedure by a multidisciplinary team of neonatologists, pediatric surgeons, obstetricians, anesthesiologists, and nurses.

The chosen anesthetic technique was balanced general anesthesia with epidural catheter placement for postoperative analgesia.

In the operating room, the initial maternal monitoring was performed with pulse oximetry, ECG, and noninvasive blood pressure, and the mother was positioned in the left lateral position for epidural catheter placement. Anesthesia was applied to the skin with 1% lidocaine (2 mL) and the identification of the epidural with air was initiated by the median approach in L3–L4. The epidural space was identified at 5.5 cm of the skin, and the epidural catheter was inserted up to 11 cm. Subsequently, a test dose was administered with 2% lidocaine 2 mL (40 mg) and the catheter was fixed. Afterwards, the pregnant woman was placed in a supine position with the uterus displaced to the left with pad and lateralization of the table.

Before induction of anesthesia, catheterization of radial artery for invasive monitoring of blood pressure and two 18-G peripheral venous accesses were performed.

Afterwards, the remaining monitoring with invasive blood pressure, capnography, anesthetic gas analyzer, and hourly diuresis were performed.

Face mask oxygenation was performed with 100% oxygen for 5 min and midazolam (2 mg) was administered. Rapid sequence induction was initiated with thiopental 300 mg (4 mg/kg), rocuronium 40 mg (0.6 mg/kg), fentanyl 0.05 mg, Sellick maneuver, and tracheal intubation with a 7.5-cuffed tube. General anesthesia was maintained with 2–3% sevoflurane and remifentanyl (0.1–0.5 μ g/kg/min). After induction of anesthesia, midazolam 1 mg, fentanyl 0.1 mg, and rocuronium 10 mg were given. For the maintenance of maternal systolic blood pressure above 100–120 mmHg it was necessary to administer ephedrine 5 mg and hydroxyethyl starch 500 mL.

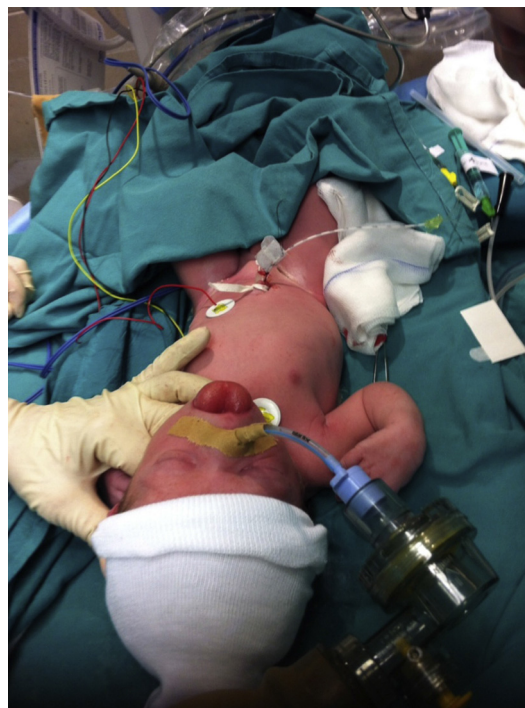

Figure 3 Nasotracheal intubation of the newborn.

The time elapsed between the induction of anesthesia and hysterotomy was 15 min.

After the hysterectomy, the head, trunk, and upper limbs of the fetus were externalized, preserving the uterine volume and fetoplacental circulation. The fetal tracheal intubation was achieved under direct laryngoscopy, with a 3.5 uncuffed tube, 4 min after hysterectomy. The correct positioning of the nasotracheal tube was confirmed, and we proceeded to the clamping and cutting of the umbilical cord (Figs. 3 and 4).

During the procedure, uterine relaxation obtained with 2–3% sevoflurane was satisfactory and there was no need for additional tocolytic drugs.

After cutting the umbilical cord, oxytocin (10 U) was administered at uterine myometrium, sevoflurane was

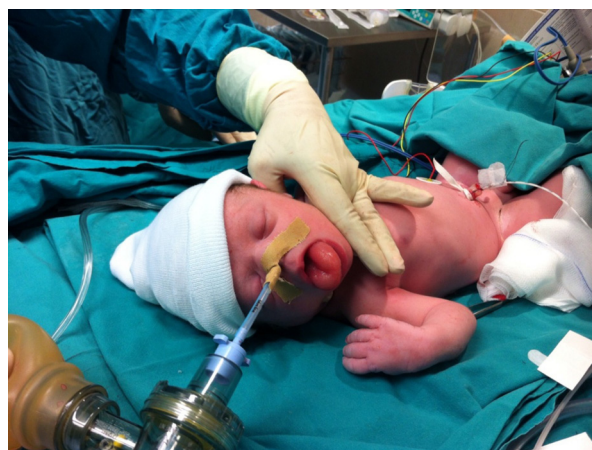

Figure 4 Evidence of macroglossia and right submandibular edema.

reduced to 0.8%, and remifentanyl infusion was discontinued. There was adequate uterine contraction.

Total volume of fluids infused was 1.500 mL of crystalloid and 500 mL of colloids. The estimated bleeding was approximately 800 mL and there was no need for transfusion of blood products. At the end of the procedure, the neuromuscular blockade was reversed with neostigmine 2 mg and atropine 1 mg, and the patient was extubated after full reversal of the blockade.

The newborn was transferred to the pediatric hospital, intubated, mechanically ventilated, and sedated with fentanyl infusion. The newborn transport was uneventful.

Conclusions

Prenatal diagnosis of fetal malformation in the cervical or oral region with obstruction of the upper airway is essential to reduce perinatal morbidity and mortality.^{3,4} It allows the maternal–fetal monitoring during pregnancy and define the best approach to be undertaken during delivery.³

EXIT is indicated in the presence of congenital malformations in which difficulty in fetal airway access is anticipated and allows its patency by direct laryngoscopy or fiberoptic and orotracheal intubation or tracheostomy before fetoplacental separation.^{1,5} It is defined as a procedure performed after partial externalization of the fetus from the uterine cavity, with uterine volume maintenance and fetoplacental circulation, and ensures the fetal oxygenation during airway access.^{6,7}

Anesthesia for this procedure differs from a conventional cesarean-section and general anesthesia is the preferred technique.^{1,2} Deep uterine relaxation, fetoplacental circulation preservation, anesthesia, and fetal immobility are the main goals of this procedure.^{1,2,7,8}

Uterine relaxation is critical to prevent uterine contractions and placental separation.² Several authors have recommended the administration of inhaled anesthetics in concentrations not below 2 MAC, which, in addition to uterine relaxation, are responsible for maternal and fetal deep anesthesia. In the event of poor uterine relaxation, it can be achieved with tocolytic drugs, such as terbutaline, magnesium sulfate, or nitroglycerin. Nitroglycerin has ideal pharmacokinetic characteristics, such as its short half-life and high potency, but it may have adverse effects, such as hypotension.^{2,6} It is used in intravenous bolus of 50–100 μ g or by continuous infusion of 10–20 μ g/kg/min.⁶

Maintenance of the fetoplacental circulation is also important during EXIT, as it provides adequate fetal oxygenation.⁶ Fetal oxygenation may be compromised in the presence of maternal hypotension, which may occur upon administration of tocolytic drugs, such as nitroglycerin. Aggressive fluid resuscitation and administration of vasopressors and inotropic drugs, such as dobutamine, are critical to maintain the maternal hemodynamic stability.^{1,2} Invasive blood pressure monitoring is strongly recommended for adequate control of hemodynamic parameters.^{1,7,8}

Fetal anesthesia and immobility are essential for a safe and effective airway management, which occurs by the transplacental passage of anesthetic drugs administered in the maternal circulation. When ineffective, it can be

assured by intravenous or intramuscular administration of opioids or neuromuscular relaxants drugs directly on the fetus.^{1,8}

In situations where general anesthesia is contraindicated (difficult airway or high risk of malignant hyperthermia), neuraxial anesthesia should be considered.^{1,9} In these circumstances, uterine relaxation should be obtained with tocolytic drugs, as described above.

The main intraoperative and postoperative complication is bleeding, which is usually associated with uterine atony, related to the administration of high doses of tocolytic drugs or procedure duration.^{1,5,8,10}

In our case, the chosen anesthetic technique was the balanced general anesthesia because it is preferable to neuraxial anesthesia in this kind of procedure, and we opted for epidural catheter placement for postoperative analgesia. Uterine relaxation was achieved with the administration of 2–3% sevoflurane, and the additional administration of tocolytic drugs was not required. Systolic blood pressure over 100–120 mmHg, essential for proper placental perfusion, was maintained with ephedrine and hydroxyethyl starch, and there was no need to use inotropic drugs.

The fetal immobility occurred by the transfer of anesthetic agents administered in the maternal circulation through the placenta, and it was not necessary to supplement the fetus anesthesia with opioids or neuromuscular relaxants. In our case, the fetus did not react to the direct laryngoscopy maneuvers, which strongly contributed to the success of tracheal intubation. After securing the fetal airway, we proceeded to the full externalization of the fetus, with umbilical cord clamping and uterine relaxation reversal.

The period of time between hysterectomy and umbilical cord clamping was approximately 5 min, a shorter time in relation to other cases in the literature.⁶ This seems to be a factor of great importance for fetal well-being at the end of the EXIT procedure.^{6,11}

To prevent uterine atony, the high inhalational anesthetic concentrations should be discontinued after clamping the umbilical cord and oxytocin should be administered. In the case, uterine contraction was achieved after reducing the inspired concentration of sevoflurane to 0.8% and after administration of oxytocin (10U) at the uterine myometrium. The estimated bleeding during the procedure was similar to that of a conventional cesarean section.

This intervention success was due not only to the early diagnosis of malformation responsible for the fetal airway obstruction, but fundamentally to the planning of the procedure by a multidisciplinary team of neonatologists, pediatric surgeons, obstetricians, anesthesiologists, and nurses.

Anesthesiologists should be aware and prepared for the anesthetic particularities of this procedure in order to contribute to a favorable outcome for the mother and especially for the fetus.

Conflicts of interest

The authors declare no conflicts of interest.

References

1. De Buck F, Deprest J, Van de Velde M. Anesthesia for fetal surgery. *Curr Opin Anaesthesiol.* 2008;21:293–7.
2. Chang LC, Kuczkowski KM. The ex utero intrapartum treatment procedure: anesthetic considerations. *Arch Gynecol Obstet.* 2008;277:83–5.
3. Nascimento GC, Souza ASR, Lima MMS, et al. Estratégia de conduta intraparto no teratoma cervical congênito. Procedimento Exit (tratamento extraútero intraparto). *Acta Med Port.* 2007;20:221–7.
4. De Backer A, Madern GC, Van de Ven CP, et al. Strategy for management of newborns with cervical teratoma. *J Perinat Med.* 2004;32:500–8.
5. Kuczkowski T, Krzysztow M. Advances in obstetric anesthesia: anesthesia for fetal intrapartum operations on placental support. *J Anesth.* 2007;21:243–51.
6. Helfer DC, Clivatti J, Yamashita AM, et al. Anestesia para tratamento intraparto extraútero (Exit) em fetos com diagnóstico pré-natal de malformações cervical e oral: relato de casos. *Rev Bras Anesthesiol.* 2012;62(3):411–23.
7. Botto HA, Boailchuck ID, Garcia C, et al. Ex utero intrapartum treatment – management of neonatal congenital high airway obstruction syndrome. Case report. *Arch Argent Pediatr.* 2010;108:E92–5.
8. Marwan A, Crombleholme TM. The exit procedure: principles, pitfalls, and progress. *Semin Pediatr Surg.* 2006;15:107–15.
9. George RB, Melnick AH, Rose EC, et al. Case series: combined spinal epidural anesthesia for cesarean delivery and ex utero intrapartum treatment procedure. *Can J Anaesth.* 2007;54:218–22.
10. Kunisaki SM, Fauza DO, Barnewolt CE, et al. Ex utero intrapartum treatment with placement on extracorporeal membrane oxygenation for fetal thoracic masses. *J Pediatr Surg.* 2007;42:420–5.
11. Gaiser RR, Cheek TG, Kurth CD. Anesthetic management of cesarean delivery complicated by ex utero intrapartum treatment of the fetus. *Anesth Analg.* 1997;84:1150–3.