



SCIENTIFIC ARTICLE

Incidence of epidural spread after Chayen's approach to lumbar plexus block: a retrospective study[☆]



Elisabetta Rosanò ^{a,*}, Diego Tavoletti^a, Giulia Luccarelli^a, Elisabetta Cerutti^b, Luca Pecora^b

^a Ospedali Riuniti, Marche Polytechnic University, Department of Emergency, Clinic of Anesthesia and Intensive Care Unit, Ancona, Italy

^b Ospedali Riuniti Ancona, Department of Emergency, Anesthesia and Intensive care of Transplantation and Major Surgery, Ancona, Italy

Received 9 January 2019; accepted 9 March 2020

Available online 17 May 2020

KEYWORDS

Lumbar plexus block;
Psoas compartment
block;
Hip surgery

Abstract

Background and objectives: The lumbar plexus block (LPB) is a key technique for lower limb surgery. All approaches to the LPB involve a number of complications. We hypothesized that Chayen's approach, which involves a more caudal and more lateral needle entry point than the major techniques described in the literature, would be associated with a lower rate of epidural spread.

Method: We reviewed the electronic medical records and chart of all adult patients who underwent orthopedic surgery for Total Hip Arthroplasty (THA) and hip hemiarthroplasty due to osteoarthritis and femoral neck fracture with LPB and Sciatic Nerve Block (SNB) between January 1, 2002, and December 31, 2017, in our institute. The LPB was performed according to Chayen's technique using a mixture of mepivacaine and levobupivacaine (total volume, 25 mL) and a SNB by the parasacral approach. The sensory and motor block was evaluated bilaterally during intraoperative and postoperative period.

Results: A total number of 700 patients with American Society of Anesthesiologists (ASA) physical status I to IV who underwent LPB met the inclusion criteria. The LPB and SNB was successfully performed in all patients. Epidural spread was reported in a single patient (0.14%; $p < 0.05$), accounting for an 8.30% reduction compared with the other approaches described in the literature. No other complications were recorded.

[☆] Internal review board approval. This study was approved by the local Ethical Committee of our institution Comitato Etico Regionale delle Marche, Chairperson Prof. P. Pelaia; Protocol number: 2018/21; Date of approval: 2.2.2018. Written informed consent. The patients gave their written informed consent to the processing of data for this study.

* Corresponding author.

E-mail: rosano.elisabetta@gmail.com (E. Rosanò).

PALAVRAS-CHAVE

Bloqueio do plexo lombar;
Bloco do compartimento do Psoas;
Cirurgia de quadril

Conclusions: This retrospective study indicates that more caudal and more lateral approach to the LPB, such as the Chayen's approach, is characterized by a lower epidural spread than the other approach to the LPB.

© 2020 Sociedade Brasileira de Anestesiologia. Published by Elsevier Editora Ltda. This is an open access article under the CC BY-NC-ND license (<http://creativecommons.org/licenses/by-nc-nd/4.0/>).

Incidência de dispersão peridural após bloqueio do plexo lombar com técnica de Chayen: estudo retrospectivo

Resumo

Justificativa e objetivos: O Bloqueio do Plexo Lombar (BPL) é uma técnica fundamental para a cirurgia de membros inferiores. Todas as abordagens do BPL são associadas a uma série de complicações. Nossa hipótese foi de que a abordagem de Chayen, que envolve um ponto de entrada da agulha mais caudal e mais lateral do que as principais técnicas descritas na literatura, estaria associada a menor incidência de dispersão peridural.

Método: Revisamos os prontuários médicos eletrônicos e em papel de todos os pacientes adultos submetidos à Artroplastia Total do Quadril (ATQ) e hemiartroplastia do quadril devido a osteoartrite ou fratura do colo do fêmur empregando-se BPL associado ao Bloqueio do Nervo Ciático (BNC), entre 1 de Janeiro de 2002 e 31 de Dezembro de 2017 em nossa instituição. Realizamos o BPL usando a técnica de Chayen e uma mistura de mepivacaína e levobupivacaína (volume total de 25 mL) e o BNC pela abordagem parassacral. Testes sensorial e motor bilaterais foram realizados no intra e pós-operatório.

Resultados: Os critérios de inclusão foram obedecidos pelo total de 700 pacientes classe ASA I a IV submetidos ao BPL. Os BPL e BNC foram realizados com sucesso em todos os pacientes. A dispersão peridural foi relatada em um único paciente (0,14%; $p < 0,05$), representando uma redução de 8,30% quando comparada às outras abordagens descritas na literatura. Nenhuma outra complicação foi registrada.

Conclusões: Este estudo retrospectivo indica que a abordagem mais caudal e mais lateral do BPL, como a técnica de Chayen, é caracterizada por menor dispersão peridural do que outras abordagens do BPL.

© 2020 Sociedade Brasileira de Anestesiologia. Publicado por Elsevier Editora Ltda. Este é um artigo Open Access sob uma licença CC BY-NC-ND (<http://creativecommons.org/licenses/by-nc-nd/4.0/>).

Introduction

Orthopedic surgery is the main field of application of lower extremity nerve blocks. The Lumbar Plexus Block (LPB) is a key technique for regional anesthesia. The lumbar plexus lies anterior to the transverse processes of the lumbar vertebrae and is formed by the anterior branches of the first three lumbar nerves (L1, L2, L3), most of the fourth nerve (L4) and, in about 50% of individuals, the subcostal nerve (T12). The nerves originating from the lumbar plexus (ilioinguinal, ileohypogastric, genitofemoral, femoral, obturator, and lateral cutaneous nerve of the thigh), combined with those deriving from the sacral plexus, provide innervation to the whole lower limb.

Various LPB techniques have been devised since Winnie first described an anterior paravascular approach (3 in 1 block) in 1973, and a posterior approach at the level of L4–L5 in 1974.^{1,2} Soon afterwards, Chayen proposed a posterior L4 approach based on loss of resistance.³ In the following three decades, Parkinson described Dekrey's technique (an L3 approach);⁴ Hanna devised an L2–L3 technique;⁵

Capdevila proposed an approach based on a modification of Winnie's landmarks;⁶ and Pandin modified Chayen's technique by introducing a more medial needle insertion point.⁷

Various complications related to LPB are described in literature.

We report the complications of the Chayen approach recorded in patients who underwent Total Hip Arthroplasty (THA) and hip hemiarthroplasty. The primary objective of the study was to assess the incidence of local anesthetic epidural spread; the secondary objective was to evaluate the rate of the other complications related to the LPB and the efficacy of combined LPB and Sciatic Nerve Block (SNB) for THA and hip hemiarthroplasty.

Method

This retrospective study was approved by the local Ethical Committee of our institution (Comitato Etico Regionale delle Marche, Chairperson Prof. P. Pelaia; protocol num-

ber: 2018/21; date of approval: 2.2.2018). Informed consent for anesthesia, surgery and use of medical records for research has been obtained from all the patients.

Data were obtained from our institutional database, which captures total patient information's including surgical, anesthetic and complications details for intra and postoperative period.

Patient, anesthesia and surgical characteristics were retrospectively collected from our internal registry by individuals who normally have access to it.

Included in the chart reviews were American Society of Anesthesiologists (ASA) physical status I to IV patients who had received a combined LPB and SNB for THA and hip hemiarthroplasty due to osteoarthritis or femoral neck fracture from January 1, 2002 to December 31, 2017.

Records were excluded if the patient received LPB combined with spinal or general anesthesia. Furthermore, patients with ASA physical status V or greater or who did not authorize use of their medical records for research were excluded.

Data recorded included demographic variables (age, gender, height, weight, body mass index, ASA physical status), type and duration of surgery, block success, use of intraoperative sedation and analgesia.

Furthermore, the major complications related to LPB – epidural spread, retroperitoneal hematoma, renal puncture, peripheral neuropathy, subarachnoid anesthesia, systemic toxicity and cardiac arrest – were assessed and their rates, compared with those reported using other approaches.

In the preoperative room, intravenous access, pulse oximetry, ECG, and non-invasive blood pressure monitoring were established. Premedication was with intravenous midazolam ($0.06 \text{ mg} \cdot \text{kg}^{-1}$). Patients were placed in the lateral decubitus position with the side to be blocked uppermost and their hips and legs slightly flexed.

All peripheral nerve blocks were performed by an experienced staff anesthesiologist.

The LPB was performed using Chayen's landmarks.³ The spinous process of L4 was identified by the intercrystal (Tuffier's) line, i.e. the line interconnecting the highest points of the iliac crests, and the needle insertion point on the skin was established 3 cm caudal and 5 cm lateral to it. A 22 gauge (120 mm) needle connected to an Electrical Nerve Stimulation (ENS) set was inserted perpendicular to the skin in sterile conditions, initially delivering a current of 0.70 mA (frequency, 2 Hz; pulse width, 0.1 ms). The needle was advanced until it touched the transverse process of L5, then it was pulled slightly back and advanced over the transverse process until contraction of the femoral quadriceps muscle and patella twitch were detected. At this time, the current intensity was reduced to 0.4 mA, maintaining the proper twitch. Continuous aspiration was provided during needle siting to avoid accidental vessel puncture. The Raj test was performed by the injection of 1 mL of local anesthetic mixture, composed of mepivacaine and levobupivacaine. After this injection stopped the twitch, the location was considered adequate, and the remaining 24 mL was injected (total volume, 25 mL).

The patient remained in the same position and the parasacral SNB was performed.⁸

After identifying the posterior superior iliac spine and the ischiatic tuberosity, a line was drawn between these two points and a mark was made on this line at 7 cm inferior to the posterior superior iliac spine. A 22 gauge (120 mm) needle connected to an ENS set was inserted perpendicular to the skin in sterile conditions, initially delivering a current of 0.70 mA (frequency, 2 Hz; pulse width, 0.1 ms). The needle was advanced until motor responses of the posterior tibial (plantar flexion) or peroneal component (extension of the foot) was elicited. At this time, the current intensity was reduced to 0.4 mA, maintaining the proper twitch. A local anesthetic mixture of mepivacaine and levobupivacaine (total volume, 15 mL) was injected. Continuous aspiration and Raj test were also here performed.

The same anesthesiologist who performed the procedure evaluated the effectiveness of the nerve block every 5 minutes, up to 30 minutes after the local anesthetic injection was completed.

Sensory block was performed bilaterally by cold stimulation in the distribution of femoral, obturator, lateral femoral cutaneous and sciatic nerves, as well as for dermatomal levels on the abdomen and thorax to determine the cephalad extent of the block, if any.

The results of these sensory tests on predefined sensory areas of the nerves were recorded as: 3 – normal sensation; 2 – decreased cold sensation; 1 – absent cold sensation, present touch sensation; and 0 – no cold nor touch sensation.

A supplementary dose of local anesthetic (10 mL of 2% lidocaine) was infiltrated into the surgical skin incision if the lateral femoral cutaneous nerve area had sensory test score of 3 or 2.

Motor block was assessed bilaterally according to a modified Bromage scale (0 = no motor block; 1 = inability to flex the hip; 2 = inability to flex the knee and hip; 3 = inability to flex the ankle, knee and hip).⁹

A successful block was defined as all skin areas of the affected lower limb had a sensory test score of 0 or 1 and motor block score was 2 or 3.

Local anesthetic epidural spread was defined when the sensory or motor block score was 1 or more in the contralateral limb, and/or when the loss of sensivity was present in the abdominal or thoracic region, on the same side of the affected lower limb or in the contralateral one.

Statistical analysis

The sample size for the whole study is based on the difference between the epidural spread rate with the Chayen approach (1.36%) and the rates reported with the other approaches (8.44%) (Table 1). In this way, the number of subjects ensuring a power of 95% and an alpha error of 0.05 is 492.

The method used to calculate this sample size is *a priori* the difference between two independent proportions, by the z-test using G-Power software (v. 3.1.9.2., F. Faul, Christian-Albrecht-Universität Kiel, Germany, Copyright© 1992–2014).

The quantitative variables were summarized as mean \pm Standard Deviation. The qualitative variables were expressed as absolute frequencies and percentages.

Table 1 Epidural spread of the local anesthetic recorded in patients who received a lumbar plexus block.

Article	Approach	Method	Local anesthetic volume (mL)	Number of patient (n)	Epidural spread (n)
Parkinson ⁴	Dekrey	ENS	0.5 kg	25	4
Parkinson ⁴	L4/L5	ENS	0.5 kg	23	1
Capdevila ⁶	Capdevila	ENS	0.4 kg	77	0
Pandin ⁷	Chayen	ENS	30	132	2
Biboulet ¹⁰	Dekrey	ENS	0.6 kg	15	4
Farny ¹¹	Winnie	ENS	25–35	45	4
Stevens ¹²	Winnie	ENS	0.4 kg	28	3
De Biasi ¹³	Capdevila	ENS	30	169	3
Mannion ¹⁴	Capdevila	ENS	0.4/kg	30	10
Mannion ¹⁴	Winnie	ENS	0.4 kg	30	12
Jankowski ¹⁵	Winnie	ENS	40	18	0
Souron ¹⁶	Winnie	ENS	25	26	0
Tokat ¹⁷	Chayen	ENS	30	15	0

ENS, Electrical Nerve Stimulation.

Table 2 Patient characteristics.

Group (n = 700)	
Age (years)	64.7 ± 20.1
Weight (kg)	62.4 ± 8.7
Height (m)	1.63 ± 10.5
BMI (kg. m ⁻²)	23.5 ± 3.0
Sex (Male/Female)	284/416
ASA physical status	
I	67
II	292
III	307
IV	34

All values except sex and ASA physical status are expressed as mean ± SD. Sex and ASA physical status are expressed as absolute number.

BMI, Body Mass Index; ASA, American Society of Anesthesiologist.

Results

The patients' characteristics are summarized in [Table 2](#). The records in which it was registered a combined LPB with spinal or general anesthesia were excluded, because of the impossibility to evaluate the sensory and motor block in the affected lower limb or any epidural spread following the LPB. A total of 731 patients met the inclusion criteria. Thirty-one cases were excluded due to lack of documentation. After exclusions, 700 patients undergoing a combined of LPB and SNB for THA and hip hemiarthroplasty were included for analysis ([Fig. 1](#)).

412 patients underwent THA and 288 patients underwent hip hemiarthroplasty. The surgery duration was 61.3 ± 5.8 minutes. All surgeries were performed in lateral decubitus. All patients completed their operations under peripheral nerve block, and no patient required conversion to general anesthesia.

Thirty minutes after the nerve block, sensory block of the femoral, obturator, lateral femoral cutaneous and sci-

atic nerves was successful in, respectively, 100%, 100%, 89% and 100% of patients (sensory test score equal to 0 or 1).

Even the motor block was successful in all patients (motor block score equal to 2 or 3). Therefore, a successful sensory LPB was in 89% of patients. Of the total of patients, 11% had sensory test score of 2 or 3 in lateral femoral cutaneous nerve area. These patients needed local anesthetic infiltration with lidocaine into the surgical skin incision. However, we considered these patients as successful sensory LPB because the two main nerves (femoral and obturator) were blocked and the sensory block failure in the lateral cutaneous femoral nerve area was overcome by local anesthetic infiltration into the surgical skin incision.

Thirty-two patients reported discomfort (due to position in the surgical bed) or anxiety during surgery time and needed light sedation with continuous propofol infusion. There was no need of analgesic drugs.

Epidural spread of the anesthetic was detected in a single patient (0.14%). In this case the upper anesthetic level was T7 and T8 on the ipsilateral to injection side (sensory test score 1) and L2 and L3 on the contralateral side (sensory test score 1). The anesthetized area was homogeneous down to the L4 dermatome bilaterally (sensory test score 0). Motor block score was 3 in the lower limb to be operated and 2 on the contralateral side.

Epidural spread was compared with those reported using the other approaches ([Table 1](#)).

The rate of epidural spread described with the other approaches is 8.44%. Data analysis shows a rate of 0.14% with Chayen approach, resulting in a reduction of 8.30%.

There were no cases of retroperitoneal hematoma, subarachnoid anesthesia, renal puncture, peripheral neuropathy, systemic toxicity due to the local anesthetic, or cardiac arrest related to the anesthetic technique.

Discussion

The LPB is a key peripheral nerve block in lower extremity surgery.

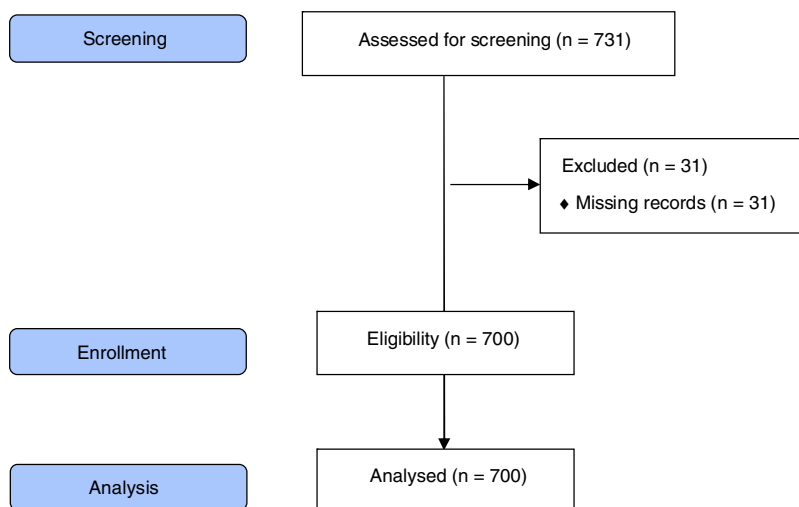


Figure 1 CONSORT flow diagram in this retrospective study.

The posterior LPB has long been considered as the technique providing the most effective blockage of the lumbar plexus,⁴ however, all the approaches to LPB that have been developed in the past few decades involve a number of complications.

In our cohort of 700 patients who underwent in lower extremity surgery with Chayen approach, we found one case of epidural spread (incidence of 0.14%) and no other complications.

Epidural spread of the local anesthetic and bilateral distribution of anesthesia has been reported with all techniques.

A search for studies identified 11 papers that have specifically sought or defined epidural spread, which are listed in [Table 1](#): in a total of 486 patients subjected to various approaches for posterior LPB (excluding the two studies in which the Chayen approach was performed), 41 cases of epidural spread were reported (incidence 8.44%).^{4,6,10–16}

In our study we observed a reduction of 8.30% in the epidural spread incidence.

It is likely that in some of these studies the epidural spread was underestimated. This could suggest that the difference in incidence could be greater.

Capdevila detected no case of contralateral epidural spread with his approach. However, five cases of unilateral epidural anesthesia were recorded. Furthermore, sensory blockade was evaluated one hour and 24 hours after the execution of the nerve block. The contralateral dermatomers evaluation occurred from T8 to L1 and a dilute local anesthetic solution was administered.⁶

Farny reported an 8.9% incidence of epidural anesthesia in patients who underwent Winnie's technique.¹¹ In this study, the epidural spread was evaluated only with motor block.

In contrast to both studies, Mannion reported the highest rate of bilateral spread: 33% with Capdevila's approach and 40% with Winnie's approach.¹⁴

Regarding the Chayen technique, Pandin described a higher incidence of central block (1.52%) compared to our assessment.⁷ It was probably related to the puncture site

(2 cm medial to the original Chayen approach) and a greater local anesthetic volume was administered compared to ours.

Similar to our finding, Tokat detected no case of epidural spread in 15 patients.¹⁷

These data suggest that the type of approach to the lumbar plexus block and the position of the needle tip play an important role in the spread of the local anesthetic toward the neuraxis during application of LPB.

The insertion of the needle in the Chayen's approach is significantly more lateral and distal than any other approach and is associated with a low incidence of neuraxial spread.

Previous contrast dye studies performed during LPB have shown that while injectate remains primarily within the body of the psoas muscle, it may also travel medially toward epidural space through the intervertebral foramina.^{4,5,18}

Bilateral anesthesia after posterior lumbar plexus block may be a result of medial insertion of the needle leading to direct epidural or subarachnoid injection of local anesthetic solution.¹⁴

The nerves are wrapped in dural cuff beyond the intervertebral foramina leading to a risk of intrathecal injection of local anesthetic.¹⁹

In addition, a high injection pressure during LPB is associated with a significant risk of contralateral block extension,²⁰ and a larger volume of local anesthetic could lead to greater risk of epidural spread.^{4,21}

Nerve injury associate with peripheral nerve block is a relatively uncommon complication.^{22,23} In this study, peripheral neuropathy related to anesthetic technique was not detected over the course of the recovery period. Similarly to our data, Auroy reported no peripheral neuropathy in 394 LPB performed, while Barrington found 2 peripheral neuropathies in 691 patients due to surgery and not following the LPB.^{23,24} The reason of our result is that nerve stimulation at 0.4mA allowed us to have the needle at a safe distance from the nerve and avoid nerve trauma caused by the contact with the needle.

Renal puncture, retroperitoneal hematoma, local anesthetic toxicity and cardiac arrest related to the anesthetic technique were not found in our retrospective medi-

cal chart's analysis. In literature, the incidence of these complications was reportedly very low.

Aida reported two cases of subcapsular renal hematoma associated with Dekrey's technique.²⁵ Since the lower pole of the kidney is located near L3, a lower approach is safer.²⁶

Capdevila reported a case of hematoma at the puncture site and three cases of nausea and vomiting with the modified Chayen technique.⁶

Retroperitoneal hematoma has also been described with the L4 approach.^{27,28}

Klein reported psoas hematoma and lumbar plexopathy 4.5 hours after administration of the first postoperative dose of enoxaparin in a patient who received an LPB by Chayen's technique.²⁹

The most severe complications are associated with intravascular injection of the local anesthetic, which may result in cardiotoxicity and, ultimately, cardiac arrest.³⁰ The best way to avoid it is aspiration before the injection.²⁶

Pham-Dang reported a case of acute local anesthetic toxicity with Winnie's posterior approach.³⁰

An interesting result of this study showed that the combined LPB and SNB provided a high successful sensory/motor block and surgical anesthesia for THA and hip hemiarthroplasty.

In our clinical practice, a sensory test score of 1/3 (absent cold sensation, present touch sensation) or less, with a motor block score of 2 (inability to flex the knee and hip) or more, is enough to define a successful nerve block.

In this review of medical records, a successful sensory block in the femoral and obturator nerve areas was achieved in all patients, while in the lateral femoral cutaneous nerve area, it was achieved in 89% of the patients included in the study.

Similar to this result, Capdevila reported a sensory blockade of lateral femoral cutaneous nerve in 85% of patients.⁶ Frequently, the lateral femoral cutaneous nerve runs too laterally to be anesthetized by the LPB.³¹

In patients where a failed sensory block was reported in the lateral femoral cutaneous area, local anesthetic infiltration was performed in the surgical incision site to avoid pain during the incision.

Precise nerve localization using low current intensity nerve stimulation (0.4 mA) was probably the reason of the high success rate of the LPB and SNB. In fact, the distance of the needle tip to the nerve is one of the main determinants of the success in peripheral nerve block.

The highly successful nerve block allowed achieving adequate anesthesia during surgery. In fact no patient required analgesic drugs or conversion to general anesthesia and only 32 patients' required light sedation due to anxiety or discomfort related to the position in the surgical bed.

This is because the effect of combined LPB and SNB could cover all innervated area of the hip and its joint capsule.³² Combined LPB and SNB has been proven as a safe and effective anesthetic method for hip surgery.³³

Our study has three strengths: a large database, a standard LPB and SNB was employed by the anesthesiologists and homogeneous orthopedic practice. However, our results are limited by the retrospective nature of this review: it may contain missing data points, it may not accurately measure the outcomes of interest and the informational content may not be necessarily useful. In our clinical practice we have

a single anesthesiologist in the operating room and he performs the nerve block and evaluates its effectiveness. The ideal would be to use two different anesthesiologists in a prospective study: one anesthesiologist performs the nerve blocks, another one assesses the effectiveness. In addition, the epidural spread was evaluated only with the physical examination. Previous studies evaluated the spread radiologically using other approaches to the LPB.

In conclusion, the present review of the records of 700 LPBs performed by the Chayen technique found a single case of epidural spread of the local anesthetic, probably due to the more caudal and lateral approach.

A number of other factors also play a role in LPB: the patient should be positioned with the side to be blocked uppermost and the leg slightly flexed, correct sedation clearly affects both patient comfort and block accuracy and effectiveness, slow advancement of the needle connected to the ENS, and combination of smaller local anesthetic volume and low pressure at the time of the injection may prevent complications during LPB.

In addition, a combined LPB and SNB could be considered as an effective anesthetic method for THA and hip hemiarthroplasty.

Conflicts of interest

The authors declare no conflicts of interest.

Acknowledgements

The authors declare that they have no financial or personal relationship(s) which may have inappropriately influenced them in writing this paper.

Support was provided solely from institutional and/or departmental sources.

References

1. Winnie AP, Ramamurthy S, Durrani Z. The inguinal paravascular technic of lumbar plexus anesthesia: the "3 in 1 block". *Anesth Analg*. 1973;52:989-96.
2. Winnie AP, Ramamurthy S, Durrani Z, et al. Plexus blocks for lower extremity surgery: new answers to old problems. *Anesthesiology Review*. 1974;1:11-6.
3. Chayen D, Nathan H, Chayen M. The psoas compartment block. *Anesthesiology*. 1976;45:95-9.
4. Parkinson KS, Mueller JB, Little WL, et al. Extent of blockade with various approaches to the lumbar plexus. *Anesth Analg*. 1989;68:243-8.
5. Hanna MH, Peat SJ, D'Costa F. Lumbar plexus block: an anatomical study. *Anaesthesia*. 1993;48:675-8.
6. Capdevila X, Macaire P, Dadure C, et al. Continuous psoas compartment block for postoperative analgesia after total hip arthroplasty: new landmarks, technical guidelines, and clinical evaluation. *Anesth Analg*. 2002;94:1606-13.
7. Pandin PC, Vandesteene A, D'Hollander AA. Lumbar plexus posterior approach: a catheter placement description using electrical nerve stimulation. *Anesth Analg*. 2002;95:1428-31.
8. Bruelle P, Cuvillon P, Ripart J, et al. Sciatic nerve block: Parasacral approach. *Reg Anesth*. 1998;23:78.
9. Kampe S, Kiencke P, Delis A, et al. The continuous epidural infusion of ropivacaine 0.1% with 0.5 microg mL⁻¹ sufentanil.

- tanil provides effective postoperative analgesia after total hip replacement: a pilot study. *Can J Anaesth*. 2003;50:580–5.
10. Biboulet P, Morau D, Aubas P, et al. Postoperative analgesia after total-hip arthroplasty: comparison of intravenous patient-controlled analgesia with morphine and single injection of femoral nerve or psoas compartment block. a prospective, randomized, double-blind study. *Reg Anesth Pain Med*. 2004;29:102–9.
 11. Farny J, Girard M, Drolet P. Posterior approach to the lumbar plexus combined with sciatic nerve block using lidocaine. *Can J Anaesth*. 1994;41:486–91.
 12. Stevens RD, Van Gessel E, Flory N, et al. Lumbar plexus block reduces pain and blood loss associated with total hip arthroplasty. *Anesthesiology*. 2000;93:115–21.
 13. De Biasi P, Lupescu R, Burgun G, et al. Continuous lumbar plexus block: use of radiography to determine catheter tip location. *Reg Anesth Pain Med*. 2003;28:135–9.
 14. Mannion S, O'Callaghan S, Walsh M, et al. In with the new, out with the old? Comparison of two approaches for psoas compartment block. *Anesth Analg*. 2005;101:259–64.
 15. Jankowski CJ, Hebl JR, Stuart MJ, et al. A comparison of psoas compartment block and spinal and general anesthesia for outpatient knee arthroscopy. *Anesth Analg*. 2003;97:1003–9.
 16. Souron V, Delaunay L, Schiffrine P. Intrathecal morphine provides better postoperative analgesia than psoas compartment block after primary hip arthroplasty. *Can J Anaesth*. 2003;50:574–9.
 17. Tokat O, Turker YG, Uckunkaya N, et al. A Clinical Comparison of Psoas Compartment and Inguinal Paravascular Blocks Combined with Sciatic Nerve Block. *J Int Med Res*. 2002;30:161–7.
 18. Mannion S, Barrett J, Kelly D, et al. A description of the spread of injectate after psoas compartment block using magnetic resonance imaging. *Reg Anesth Pain Med*. 2005;30:567–71.
 19. Evans PJ, Lloyd JW, Wood GJ. Accidental intrathecal injection of bupivacaine and dextran. *Anaesthesia*. 1981;36:685–7.
 20. Gadsden JC, Lindenmuth DM, Hadzic A, et al. Lumbar plexus block using high-pressure injection leads to contralateral and epidural spread. *Anesthesiology*. 2008;109:683–8.
 21. Chudinov A, Berkenstadt H, Salai M, et al. Continuous psoas compartment block for anesthesia and perioperative analgesia in patients with hip fractures. *Reg Anesth Pain Med*. 1999;24:563–8.
 22. Brull R, McCartney CJ, Chan VW, et al. Neurological complications after regional anesthesia: contemporary estimates of risk. *Anesth Analg*. 2007;104:965–74.
 23. Barrington MJ, Watts SA, Gledhill SR, et al. Preliminary results of the Australasian Regional Anaesthesia Collaboration: a prospective audit of more than 7000 peripheral nerve and plexus blocks for neurologic and other complications. *Reg Anesth Pain Med*. 2009;34:534–41.
 24. Auroy Y, Benhamou D, Bagues L, et al. Major complications of regional anesthesia in France: the SOS Regional Anesthesia Hotline Service. *Anesthesiology*. 2002;97:1274–80.
 25. Aida S, Takahashi H, Shimoji K. Renal subcapsular hematoma after lumbar plexus block. *Anesthesiology*. 1996;84:452–5.
 26. Capdevila X, Coimbra C, Choquet O. Approaches to the lumbar plexus: success, risks, and outcome. *Reg Anesth Pain Med*. 2005;30:150–62.
 27. Weller RS, Gerancher JC, Crews JC, et al. Extensive retroperitoneal hematoma without neurologic deficit in two patients who underwent lumbar plexus block and were later anticoagulated. *Anesthesiology*. 2003;98:581–5.
 28. Aveline C, Bonnet F. Delayed retroperitoneal haematoma after failed lumbar plexus block. *Br J Anaesth*. 2004;93:589–91.
 29. Klein SM, D'Ercole F, Greengrass RA, et al. Enoxaparin associated with psoas hematoma and lumbar plexopathy after lumbar plexus block. *Anesthesiology*. 1997;87:1576–9.
 30. Pham-Dang C, Beaumont S, Floch H, et al. Acute toxic accident following lumbar plexus block with bupivacaine. *Ann Fr Anesth Reanim*. 2000;19:356–9.
 31. Bendtsen TF, Søballe K, Petersen EM, et al. Ultrasound guided single injection lumbosacral plexus blockade for hip surgery anaesthesia. *Br J Anaesth*. 2013;111.
 32. Birnbaum K, Prescher A, Hessler S, Heller KD. The sensory innervation of the hip joint- an anatomical study. *Surg Radiol Anat*. 1997;19:371–5.
 33. de Visme V, Picart F, Le Jouan R, et al. Combined lumbar and sacral plexus block compared with plain bupivacaine spinal anesthesia for hip fractures in the elderly. *Reg Anesth Pain Med*. 2000;25:158–62.