

CASE REPORTS

General anesthesia for Crisponi syndrome: case report



Chloé Allary ^{a,*}, Marco Caruselli^a, Alexandre Fabre^b, Frédérique Audic^c,
Fabrice Michel^a

^a Aix Marseille University, APHM, La Timone Teaching Hospital, Department of Pediatric Anesthesia and Intensive Care Unit, Marseille, France

^b Aix Marseille University, APHM, La Timone Teaching Hospital, Multidisciplinary Pediatric Department, Marseille, France

^c Aix Marseille University, APHM, La Timone Teaching Hospital, Neuropediatric Department, Marseille, France

Received 14 June 2019; accepted 26 January 2020

Available online 28 April 2020

KEYWORDS

Crisponi syndrome;
Pediatric anesthesia;
Sudden death;
Body temperature
regulation;
Malignant
hyperthermia

PALAVRAS-CHAVE

Síndrome de Crisponi;
Anestesia pediátrica;
Morte súbita;
Regulação da
temperatura
corpórea;
Hipertermia maligna

Abstract Crisponi syndrome is a rare and severe heritable disorder characterised by muscle contractions, trismus, apnea, feeding troubles, and unexplained high fever spikes with multiple organ failure. Here we report perioperative care for endoscopic gastrostomy of a 17 month-old female child with Crisponi syndrome. Temperature in the surgery room was strictly monitored and maintained at 19 °C. The patient was exposed to both inhaled and intravenous anesthetic agents. Surgical and perioperative periods were uneventful. Episodes of fever in Crisponi syndrome arise from CRLF1 mutation, which differs from the physiological pathway underlying malignant hyperthermia.

© 2020 Sociedade Brasileira de Anestesiologia. Published by Elsevier Editora Ltda. This is an open access article under the CC BY-NC-ND license (<http://creativecommons.org/licenses/by-nc-nd/4.0/>).

Anestesia geral para Síndrome de Crisponi: relato de caso

Resumo A Síndrome de Crisponi é uma condição clínica hereditária grave e rara caracterizada por contrações musculares, trismo, apneia, distúrbios na alimentação, picos de febre alta e inexplicável, e falência de múltiplos órgãos. Descrevemos o cuidado perioperatório de paciente pediátrica com 17 meses de idade, portadora da Síndrome de Crisponi, submetida à gastrostomia endoscópica. A temperatura da sala de cirurgia foi cuidadosamente monitorizada e mantida a 19 °C. A paciente foi submetida a agentes anestésicos inalatórios e venosos. O cuidado cirúrgico e perioperatório desenvolveram-se sem incidentes. As crises de febre na Síndrome de Crisponi

* Corresponding author.

E-mail: chloe.allary@ap-hm.fr (C. Allary).

originam-se de mutação no gene CRLF1, o que as diferenciam do mecanismo fisiopatológico da hipertermia maligna.

© 2020 Sociedade Brasileira de Anestesiologia. Publicado por Elsevier Editora Ltda. Este é um artigo Open Access sob a licença de CC BY-NC-ND (<http://creativecommons.org/licenses/by-nc-nd/4.0/>).

Case report

Crisponi syndrome is a severe autosomal recessive disorder first described in 1996 in South Sardinia, Italy.¹ Symptoms at birth comprise facial and skeletal anomalies, onset of high fever episodes with multiple organ failure, and muscle contractions with trismus and inability to swallow. Gastrostomy is often required. There is only one case report that addresses anesthesia management of patients with Crisponi syndrome.² Here we present the details of a 17 month-old female who required general anesthesia for a Percutaneous Endoscopic Gastrostomy (PEG) using the introducer technique (Halyard Introducer Kit for Gastrostomy Feeding Tube).

The extended family experienced several infant deaths, including the patient's older sister, who died at 6 months of age. The patient's parents are first cousins, and both are carriers of the heterozygous CRLF1 mutation c.713dup (p. Asp240Alafs*91). Pregnancy and delivery were uneventful, and the child was born at 36 weeks of gestation. Birth weight was 3100 g, length was 46 cm, and head circumference was 32 cm. The APGAR score was 10/10 at 1 and 5 minutes, but shortly after birth she developed a swallowing disorder with an inability to feed. Diagnosis was confirmed by physical examination: bilateral camptodactyly of index fingers, thumbs in adduction position (Fig. 1), peripheral hypertonia, trismus, and sudden crying spells. Neonatal transthoracic ultrasonography found an ostium secundum atrial septum defect and dilatation of the ascending aorta (+2.3 Z-score) without cardiac dysfunction. She required 15 days of ventilatory support by CPAP and was discharged from the hospital at the age of one month.

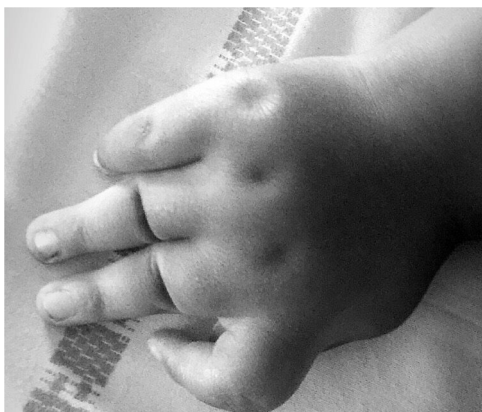


Figure 1 Picture of the child's left hand, showing camptodactyly of index finger and thumb in adduction.

The patient's childhood was marked by a few hospitalizations to general pediatric wards for management of fever spikes. She never succeeded to feed orally and was exclusively dependent on enteral nutrition; thus, gastrostomy was indicated. At the age of 8 months, she was declined for anesthesia. Due to difficulty managing the nasogastric tube at home and to the parents' insistence, anesthesia was approved 9 months later. The parents were clearly informed of the risks of the operation, including death.

Preoperative evaluation showed a smiling, 8.55 kg child who was able to hold her head and sit, but unable to walk. She had a round face without criteria for difficult airway management and without trismus. Venous capital appeared poor. Recent cardiac echography only demonstrated a minimal patent foramen ovale. Her mother reported daily fever spikes up to 39°C secondary to fatigue, external heat, or pain, which were well controlled by paracetamol and cold water baths, or occasional external cooling with ice. She underwent no other medical treatments and had no allergies.

The operating room temperature was maintained at 19°C. Anesthesia was induced by 6% sevoflurane with 100% oxygen and sufentanil (0.1 µg.kg⁻¹), and deepened by propofol (3 mg.kg⁻¹). She was Cormack 2, intubated after one direct laryngoscopy (4.0 cuffed tube). She was perfused with cooled isotonic balanced crystalloid kept at 5 degrees. Tympanic temperature was 37.7°C upon arrival to the surgery room at 11:50 am, 37.2°C after induction, and 36.7°C at extubation at 12:35 pm. She was monitored in the pediatric intensive care unit for 24 hours, where she received four systematic infusions of paracetamol (15 mg.kg⁻¹) and one dose of nalbuphin (0.2 mg.kg⁻¹). Her temperature never exceeded 37.5°C. Nutrition was begun 24 hours following the surgery and was well tolerated. The patient was discharged from the hospital two days after the operation, and the parents were fully satisfied with the care provided to their child.

Discussion

Despite the fact that Crisponi syndrome is a clinically relevant dysmorphic, dysautonomic syndrome from birth, diagnosis can be challenging in non-specialist centres. Diagnostic criteria include facial and skeletal abnormalities sometimes accompanied by micrognathia and torticollis. Neonates present sucking difficulties requiring feeding via nasogastric tube. In response to slight stimulation (e.g. bathing, feeding, changing), painful stimuli, or during crying, they show muscles contractions – including respiratory muscle contractions – with trismus and opisthotonus. Crying

spells can be associated with apnea and cyanosis, and they also experience unexplained episodes of high fever reaching up to 42 °C followed by periods of restlessness, continuous crying, or trismus; generalized seizures are possible. Death secondary to apnea, multiple organ failure, or following fever spikes is common in the first months of life. These episodes tend to decrease in frequency as the child grows, but feeding disorders persist, and paradoxical sweating and severe scoliosis can appear.

Ten years ago, Bonthuis and colleagues listed possible anesthetic complications of Crisponi and related heritable syndromes.³ They underlined a lack of evidence specifically regarding anesthetic risk. Its pathophysiology was only understood later. Crisponi syndrome falls under the umbrella of CNTF receptor-related disorders due to a mutation in the soluble cytokine receptor CRLF1.^{4,5} CRLF1 is involved in the Ciliary Neurotrophic Factor Receptor (CNTRF) pathway, which plays a role in both the development and maintenance of the nervous system and autonomic system function. Crisponi syndrome shares no physiopathology with malignant hyperthermia; however, no improvement was found with the use of muscle relaxants such as dantrolene, and no problems with volatile agents were previously described.^{1,2} We therefore choose sevoflurane for induction and maintenance of anesthesia, which is typically chosen when venous access is difficult. No neuromuscular blocking agents were used in the surgery because they were not required; however, Rafiq and colleagues administered rocuronium (0.5 mg.kg⁻¹) and neostigmine without complication.² No literature on the use of depolarizing neuromuscular blocking agents could be found; their use is suspected to be safe. In summary, no hemodynamic dysfunction, aspiration, or airway management difficulties occurred while managing this anesthesia.

Conclusion

The pathophysiological pathway of Crisponi syndrome differs from that of malignant hyperthermia, and volatile

anesthesia can likely be safely used. Maintaining normal temperature was the goal of the perioperative period. Practitioners should be aware that the younger the patient, the more serious the disease.

Ethical approval

The parents provided written informed consent for publication.

Conflicts of interest

The authors declare no conflicts of interest.

References

1. Crisponi G. Autosomal recessive disorder with muscle contractions resembling neonatal tetanus, characteristic face, camptodactyly, hyperthermia, and sudden death: a new syndrome? *Am J Med Genet.* 1996;62:365–71.
2. Rafiq M, Almasry S, Abdulrahman A, et al. perioperative care of a child with Crisponi syndrome. *Middle East J Anaesthesiol.* 2016;23:563–7.
3. Bonthuis D, Morava E, Booij LHDJ, et al. Stuve Wiedemann syndrome and related syndromes: case report and possible anesthetic complications. *Paediatr Anesth.* 2009;19:212–7.
4. Crisponi L, Crisponi G, Meloni A, et al. Crisponi syndrome is caused by mutations in the CRLF1 gene and is allelic to cold-induced sweating syndrome type 1. *Am J Hum Genet.* 2007;80:971–81.
5. Dagoneau N, Bellais S, Blanchet P, et al. Mutations in cytokine receptor-like factor 1 (CRLF1) account for both Crisponi and cold-induced sweating syndromes. *Am J Hum Genet.* 2007;80:966–70.