

Myocardial infarction and aortic dissection: an important differential diagnosis

Infarto agudo do miocárdio e dissecação aguda de aorta: um importante diagnóstico diferencial

José Fernando Vilela MARTIN, Leticia Goto ANDRADE, Afonso Augusto Carvalho LOUREIRO, Moacir Fernandes de GODOY, Domingo Marcolino BRAILE

RBCCV 44205-712

Abstract

We report on a case of a 54-year-old man suffering from untreated high blood pressure who presented with a hypertensive emergency and target-organ damage. Initially, he was treated for myocardial infarction but later was diagnosed as having a type-A aortic dissection which was successfully operated with adequate control of blood pressure within the first 24 hours. We emphasize the necessity of the differential diagnosis of thoracic pain in the hospital emergency department and the correct treatment of arterial hypertension aiming at a better prognosis over the long term.

Descriptors: Hypertension. Myocardial infarction. Aortic aneurysm, diagnosis, surgery. Aneurysm dissecting, diagnosis, surgery. Diagnosis differential.

Resumo

Relatamos o caso de um paciente de 54 anos, portador de hipertensão arterial sem tratamento, que apresentou quadro de emergência hipertensiva com lesão de órgão-alvo. Inicialmente, tratada como infarto agudo do miocárdio, na evolução foi diagnosticada dissecação de aorta tipo A, abordada cirurgicamente com boa evolução no pós-operatório e controle adequado da pressão arterial nas primeiras 24 horas. Reforçamos a importância do diagnóstico diferencial de dor torácica na emergência hospitalar, visando tratamento correto e controle adequado da hipertensão arterial ao longo do tempo, no sentido de evitar as complicações hipertensivas.

Descritores: Hipertensão. Infarto do miocárdio. Aneurisma aórtico, diagnóstico, cirurgia. Aneurisma dissecante, diagnóstico, cirurgia. Diagnóstico diferencial.

Work performed in the Medical School of São José do Rio Preto – SP
Av Brigadeiro Faria Lima, 5416 CEP: 15090-000

Correspondence address: José Fernando Vilela Martin. Av. Francisco Chagas de Oliveira, 615. São José do Rio Preto, SP CEP: 15091-330.
Fone (Fax): 17-2272409.
E-mail: vilelamartin@uol.com.br

Article received in September, 2004
Article accepted in November, 2004

INTRODUCTION

Acute aortic dissection, caused by arterial hypertension, constitutes a hypertensive emergency. It is characterized by the sudden separation of the media layer of the vessel, leading to the infiltration of a column of blood in the space formed between the intimal and the adventitial layers. This creates a false lumen and the formation of a hematoma [1,2] evolving with high cardiovascular morbidity and mortality.

We present the case of a patient with untreated arterial hypertension which evolved with thoracic pain and an increase in the blood pressure, characterizing a hypertensive emergency. We emphasize the importance of differential diagnosis between myocardial infarction and aortic dissection, two extremely severe situations which require precise diagnoses and the correct therapeutic conduct. The case was initially treated as myocardial infarction and, later, it proved to be type A aortic dissection, which was surgically repaired.

CASE REPORT

A 54-year-old man, with untreated high blood pressure for more than twenty years, was admitted to the hospital emergency department in July 2001 after having an intense burning pain in the precordial and retrosternal regions over a four-day period, which started during rest and irradiated to the neck, upper limbs and dorsum, associated with nausea and cold sweat. The patient reported three similar episodes of precordial pain in the previous year, when anti-hypertensive medicines had been prescribed, which the patient had not taken. An echocardiogram examination made in 2000 showed a dilatation of the ascending aorta and mild aortic valve insufficiency with an ejection fraction equal to 0.71.

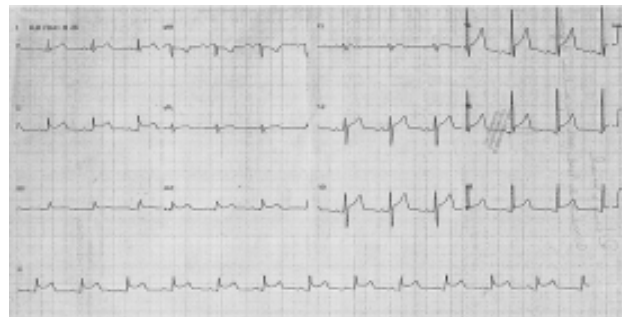
The patient had smoked 20 cigarettes per day during forty years and drank a bottle of Brazilian rum every day for forty years. He said he did not suffer from diabetes, dyslipidemia, myocardial infarction or brain strokes.

He was admitted in hospital in a regular general state – he was hydrated, ruddy, acyanotic, anicteric, eupneic, without fever and conscious. Lung auscultation revealed a global reduction of the vesicular murmur, with rumbles at the pulmonary bases. The heart auscultation was rhythmic and regular with the presence of a regurgitative murmur at the left parasternal edge. The blood pressure was 170 x 110 mmHg and heart rate was 90 bpm. He had pain to the touch in the epigastric region and the peripheral pulses were present and bilaterally symmetrical.

An electrocardiogram examination showed a 2-mm horizontal depression of the ST segment in the inferior wall (Figure 1A) with CPK of 240 IU/L and CKMB of 15 IU/L. The

horizontal depression reduced after sublingual use of nitrates (Figure 1B). He was treated for myocardial infarction of the inferior wall, submitted to fibrinolytic treatment with endovenous streptokinase 1,500,000 IU and maintained on nitrates and endovenous heparin, beta-blockers and angiotensin converting enzyme inhibitor.

A



B

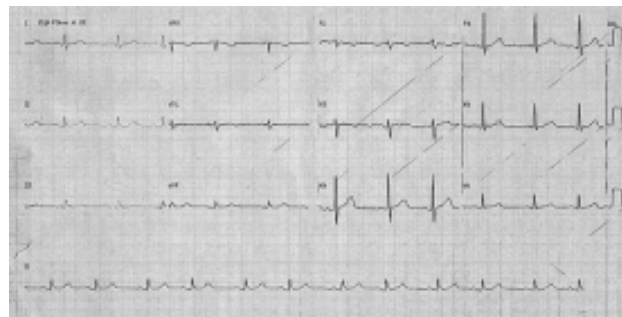


Fig. 1 – A: Electrocardiogram showing horizontal depression of the ST segment in the II, III and aVF (inferior wall) derivations and unspecific alterations of the ST segment in other derivations. B: Electrocardiogram showing improvement of the horizontal depression of the ST segment in the same derivations after the use of sublingual isordil [1B].

An echocardiogram examination performed after the initial intervention showed an acute type A aortic dissection. Catheterism showed the ascending aorta with an angiographically normal image, with a residual double lumen at the origin of the aortic arch and aortic valve insufficiency. The coronary arteries were normal. He was submitted to surgical correction of the dissection and aortic valve replacement using a bovine pericardium prosthesis (Figure 2). Another aortography, which was performed before hospital discharge, showed residual distal dissection below the subclavian artery that was repaired by the implantation of a stent via the femoral artery. A control echocardiogram performed two months after the surgery showed adequate correction of the defect and normal functioning of the biologic prosthesis.

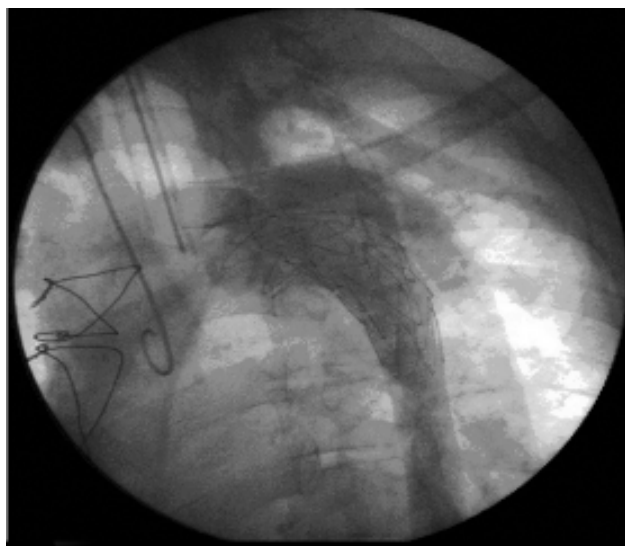


Fig. 2 – Aortography showing the tubular graft in the ascending aorta and the lined stent in the descending thoracic aorta without residual shunts

Recently, in a checkup after three years of follow up, he presented with a 24-hour mean ambulatory blood pressure of 130 x 89 mmHg and is taking 100 mg atenolol, 75 mg captopril, 25 mg hydrochlorotiazide and 200 mg AAS daily.

COMMENTS

Acute aortic dissection (AAD) is a cardiovascular emergency that evolves with high mortality varying from 50% to 68.2% at 48 hours, 70% at one week and 85% at one month [1,3]. The start of the dissection is transversal, located in the ascending aorta in 70% of the cases (immediately above of the aortic valve), in the descending aorta in 20% of the cases (after the aorta arch) and in the transverse aorta in 10%. When it starts, the progression of the dissection can be distal, retrograde or occur in both directions involving varying lengths of the vessel [1-3].

Aortic dissections occur more frequently in men with the proportion between men and women varying from 2:1 to 5:1 [4]. They occur more commonly in individuals between 45 and 70 years old, with a peak of between 50 and 55 years for cases of proximal dissection and between 60 and 70 years old for distal dissections [5].

The most accepted classification of aortic dissections currently used is the Stanford's classification, which includes two types [1,5]: type A (in the ascending aorta involving or not the descending aorta) and type B (involving only the descending aorta).

The main symptoms of dissections are intense thoracic pain followed by sympathetic activity. The start of the pain is almost always sudden and it is characterized as a sharp, cutting or throbbing pain, which is associated with sweating, limited to the thorax or retrosternal region or spreading to the dorsum, abdomen, legs or arms. It is also associated with dyspnea and pulmonary edema [2,5].

The physical examination can reveal asymmetry of peripheral pulses as in 50% of type A dissections alterations occur in one or more pulses but in only 16% in the type B dissections [1,2].

Normally dissections are limited to the aorta, but can involve the iliac, carotid, mesenteric, renal, subclavian or coronary arteries with consequent reductions of blood flow and ischemia of affected regions [4]. Concomitant aortic valve insufficiency evidenced in this case can be from the dilation of the initial portion of the aorta with enlargement of its ring (making coaptation of the cusps difficult), pressure of the cusps below the coaptation line, from the hematoma, collapse of the annular support or prolapse of the delamination of the intima towards the left ventricle during diastole [4].

Some diseases predispose individuals to dissections, including hypertension [2], coarctation of the aorta with stenosis of the bicuspid aortic valve and Marfan's, Turner and Ehler-Danlos syndromes [3]. Patients with valvar prostheses in the aortic position with ectasia of the ascending aorta are also more predisposed to aortic dissections [3].

The current case is a patient with high blood pressure that remained uncontrolled over a long period and evolved as a hypertensive emergency (acute aortic dissection). It must be remembered that an echocardiogram examination performed one year prior to surgery already showed dilatation of the ascending aorta, highlighting the importance of this aspect in an attempt to prevent future complications.

Hypertension is the most common risk factor and exists in 62 to 78% of patients suffering from dissections with proximal dissections being more common than distal dissections (70% versus 35%), as was seen in this case [5-7].

In the initial evaluation with the patient complaining of thoracic pain, the electrocardiogram examination showed an alteration suggestive of acute myocardial infarction (AMI) in the inferior wall (horizontal depression of the ST segment) which is the reason that the patient was submitted to thrombolytic therapy. However, if we carefully assess the ECG (Figure 1A), we can also see non-specific alterations of the ST segment in other derivations, which changed substantially with the sublingual use of isordil (Figure 1B). This apparent inability to identify a specific ischemic area, as well as the absence of necrosis waves on the ECG, the duration of the precordial pain (four days) and the

insignificant enzymatic alterations cast doubts on the hypothesis of Acute Myocardial Infarction. This should highlight the need for a differential diagnosis, with the most important alternative being acute aortic dissection. This possibility was reinforced by other associated risk factors (untreated hypertension, smoking and the previously identified dilation of the aorta), even with the absence of asymmetry of pulses as seen in this case. Thus, with the current use of thrombolytic agents for acute myocardial infarction, the differential diagnosis of aortic dissections is essential [3], to avoid possible iatrogenic cases.

However, dissection and myocardial infarction occur concomitantly in from 1.5 to 7.5% of cases and the involvement of the right coronary artery is more common than the left coronary artery [2,8], a fact that could justify in part, the horizontal depression found in the lower electrocardiographic derivations of this patient. Nevertheless, the ischemic myocardial state can also be explained by reduced coronary artery perfusion, which leads 10 to 15% of patients with aortic dissections to evolving kinetic and electrocardiographic abnormalities of the left ventricular wall, without necessarily developing acute myocardial ischemia, which is confirmed by cardiac catheterization revealing acute type A aortic dissections without coronary artery obstruction, thereby excluding the hypothesis of infarction. The ischemic myocardial alterations found in this case may be due to compression of the coronary artery caused by the expansion of the false lumen, the extension of the dissection process inside the coronary artery or the hypotension or a combination of these conditions [9]. It is interesting to observe that up to 85% of patients with dissections may not receive appropriate medical treatment in the first hours of treatment due to an incorrect diagnosis [3].

The complementary examinations that help to diagnose dissections are transthoracic and transesophageal echocardiograms, computed tomography, magnetic resonance and aortography [1,2]. Cardiac catheterism, in addition to diagnosis, is employed as a therapeutic method (implantation of stents in the thoracic or abdominal aorta via the femoral artery). Recognizing the point at the start of the dissection is of extreme importance in treatment decisions and for surgical conduct [1].

The treatment is initially based on measures such as analgesia and strict control of the hypertension using sodium nitroprusside and beta-blockers [1,2].

The conservative treatment of type A dissections is not advisable because it presents with high mortality due to intrapericardial rupture of the aorta, hemithorax, aortic valve insufficiency, ischemia and necrosis of specific organs [1,6]. Thus, all cases must be considered for emergency surgery, independently of complications.

The surgery is performed with cardiopulmonary bypass associated with deep hypothermia at 26 °C with total circulatory arrest, giving a satisfactory time to inspect the aortic crest and to distally suture the layers of the aorta to a Dacron or bovine pericardium tube. After, the cardiopulmonary bypass is re-established and suturing of the dissected layers is performed using felt or Teflon reinforcement followed by the suturing of the proximal neck re-constituting the tube [1]. The aortic valve is generally preserved, but its substitution may be necessary, as happened in the present case. Due to the involvement of the descending thoracic aorta, the implantation of a stent via the femoral artery was also necessary.

Patients affected by aortic dissections start to suffer generalized diseases of vessels and the good results of the initial therapy must be maintained in survivors, with regular follow ups and strict blood pressure control, as is demonstrated by ambulatory blood pressure monitoring in the first 24 hours, as well as constant observation of the thoracic aorta using non-invasive examinations which allow an evaluation of the evolution of the disease. The presentation of acute thoracic pain in the emergency department makes the differential diagnosis of acute myocardial infarction imperative, in order to achieve a more precise therapeutic conduct.

BIBLIOGRAPHIC REFERENCES

1. Buffolo E, Carvalho ACC. Dissecção aórtica aguda. In: Knobel E, editor. *Conduas no paciente grave*. 2a ed. São Paulo:Atheneu;1998. p. 272-8.
2. Pamplona D, Ferreira JFM. Dissecção de aorta: fisiopatologia, diagnóstico clínico e prognóstico. In: Timerman A, César LAM. *Manual de cardiologia*. Sociedade de Cardiologia do Estado de São Paulo – SOCESP. São Paulo:Atheneu;2000. p.218-21.
3. Mészáros I, Mórocz J, Szlávi J, Schmidt J, Tornóci L, Nagy L et al. Epidemiology and clinicopathology of aortic dissection: a population-based longitudinal study over 27 years. *Chest* 2000;117:1271-8.

4. DeBakey ME, McCollum CH, Crawford ES, Morris GC Jr, Howell J, Noon GP et al. Dissection and dissecting aneurysms of the aorta: twenty-year follow-up of five hundred twenty-seven patients treated surgically. *Surgery* 1982;92:1118-34.
5. Khan IA, Nair CK. Clinical, diagnostic, and management perspectives of aortic dissection. *Chest* 2002;122:311-28.
6. Hagan PG, Nienaber CA, Isselbacher EM, Bruckman D, Karavite DJ, Russman PL et al. The International Registry of Acute Aortic Dissection (IRAD): new insights into an old disease. *JAMA* 2000; 283: 897-903.
7. Spittell PC, Spittell JA Jr, Joyce JW, Tajik AJ, Edwards WD, Schaff HV et al. Clinical features and differential diagnosis of aortic dissection: experience with 236 cases (1980 through 1990). *Mayo Clin Proc* 1993;68:642-51.
8. Rahmatullah SI, Khan IA, Nair VM, Caccavo ND, Vasavada BC, Sacchi TJ. Painless limited dissection of the ascending aorta presenting with aortic valve regurgitation. *Am J Emerg Med* 1999;17:700-1.
9. Eisenberg MJ, Rice SA, Paraschos A, Caputo GR, Schiller NB. The clinical spectrum of patients with aneurysms of the ascending aorta. *Am Heart J* 1993;125:1380-5.