

A novel adjustable pulmonary artery banding system for hypoplastic left heart syndrome

Nova bandagem ajustável das artérias pulmonares na síndrome de hipoplasia de câmaras esquerdas

Renato Samy ASSAD¹, Marina M. ZAMITH², Maria Fernanda SILVA³, Petrônio Generoso THOMAZ⁴, Leonardo Augusto MIANA⁵, Vitor Coimbra GUERRA⁶, Carlos Augusto Cardoso PEDRA⁷, Miguel BARBERO-MARCIAL⁸

RBCCV 44205-867

Abstract

Objective: Hypoplastic left heart syndrome remains a challenge for worldwide surgeons. Initial palliation employing bilateral pulmonary artery banding along with ductal stent implantation and atrial septostomy has been proposed as an alternative approach. However, the surgically placed bands are fixed and may become inadequate after sternum closure or with somatic growth of the patient. We describe the first case in which a neonate with hypoplastic left heart syndrome was initially managed using a mini

banding system that allows for fine percutaneous adjustments of pulmonary blood flow.

Method: Through a mid sternotomy, a 5 day-old neonate underwent bilateral pulmonary artery banding using this new system combined with placement of a main pulmonary artery to innominate artery shunt.

Results: The patient had an uneventful postoperative course. Three percutaneous adjustments of the banding system were necessary to keep the arterial oxygen saturation in the 75%-85% range. On the 48th day of life, she was

1. Professor Livre Docente - Faculdade de Medicina da Universidade de São Paulo, Fellow of Children's Hospital, Boston, EUA, Cardiac Surgen of Hospital Samaritano de São Paulo and Unidade Cirúrgica Infantil do Instituto do Coração HCFMUSP.

2. Master in Cardiology of Universidade Federal de São Paulo (UNIFESP); Coordinator of Curso de Rastreamento Pré-Natal das Malformações Cardíacas da UNIFESP.

3. Pediatric cardiologist of Instituto do Coração da Faculdade de Medicina da Universidade de São Paulo; Pediatric Ecocardiografist of Hospital Samaritano de São Paulo.

4. Cardiovascular Surgeon of Instituto do Coração da Faculdade de Medicina da Universidade de São Paulo; Especialist in Intensive Care; Faculdade de Medicina da Universidade de São Paulo; Cardiac Surgeon of Hospital Samaritano de São Paulo; Cardiac Surgeon of Instituto do Coração de Ipatinga, MG.

5. Cardiovascular Surgeon of Instituto do Coração da Faculdade de Medicina da Universidade de São Paulo; Faculdade de Medicina da Universidade de São Paulo; Cardiac Surgeon of Hospital Samaritano de São Paulo; Cardiac Surgeon of Instituto do Coração de Juiz de Fora, MG.

6. Pediatric cardiologist of Instituto do Coração da Faculdade de Medicina da Universidade de São Paulo. Fellow of Hospital for Sick Children, Toronto, Canadá; Director of Serviço de Ecocardiografia Pediátrica do Instituto do Coração da Faculdade de Medicina da Universidade de São Paulo.

7. Pediatric Cardiologist at Instituto Dante Pazzanese de Cardiologia;

PhD by Faculdade de Medicina da Universidade de São Paulo; Intervencionist cardiologist by The Hospital For Sick Children University of Toronto – Canadá; Chief of Seção Médica de Intervenção em Cardiopatias Congênitas do Instituto Dante Pazzanese de Cardiologia; Assistant physician of Laboratório de Cateterismo do Hospital Samaritano de São Paulo e Hospital do Coração da Associação Sanatório Sírio.

8. Professor Livre Docente and Associate of Faculdade de Medicina da Universidade de São Paulo; Director of Unidade Cirúrgica Infantil do Instituto do Coração da Faculdade de Medicina da Universidade de São Paulo. Cardiac Surgeon of Hospital Samaritano de São Paulo.

Work done at Hospital Samaritano de São Paulo.

Address correspondence:

Renato S. Assad. Instituto do Coração HC – FMUSP. Unidade Cirúrgica Infantil Av. Dr. Enéas de Carvalho Aguiar, 44 - São Paulo, SP – CEP: 05403-000.

Fone/fax: (11) 3069-5089.

E-mail: rsassad@cardiol.br

submitted to stent placement (6 mm) within the atrial septum to treat a restrictive atrial septal defect. The Norwood operation and the bidirectional Glenn shunt were carried out on the 106th day of life. The bands were removed with no distortion of the pulmonary arteries.

Conclusions: The clinical use of this innovative pulmonary artery banding system was feasible, safe and effective. It allowed for customization of the pulmonary blood flow according to the underlying clinical needs, resulting in a more precise balance between the pulmonary and systemic circulations.

Descriptors: Heart defects, congenital. Stents. Palliative care. Hypoplastic left heart syndrome. Pulmonary artery, surgery. Balloon dilatation.

Resumo

Objetivo: A Síndrome de Hipoplasia de Câmaras Esquerdas representa um grande desafio para cirurgiões do mundo inteiro. Atualmente, tem sido proposto procedimento paliativo alternativo, por meio da bandagem bilateral das artérias pulmonares associada à colocação de stent no canal arterial e atrioseptostomia. No entanto, as bandagens utilizadas são fixas, podendo tornar-se inadequadas após o fechamento do esterno ou com o rápido crescimento somático do paciente. Descrevemos a primeira aplicação clínica do novo dispositivo

miniaturizado de bandagem ajustável das artérias pulmonares em neonato portador da síndrome de hipoplasia de câmaras esquerdas, o qual permitiu ajustes percutâneos precisos do fluxo sanguíneo pulmonar.

Método: Através de esternotomia mediana, neonato de 5 dias de vida foi submetido à bandagem pulmonar bilateral, usando este novo dispositivo, combinada com interposição de tubo de PTFE entre o tronco pulmonar e o tronco braquiocefálico.

Resultados: O paciente apresentou boa evolução pós-operatória. Três ajustes percutâneos das bandagens foram necessários para manter a saturação arterial de oxigênio entre 75-85%. No 48^o dia de vida, o paciente foi submetido a atrioseptostomia com colocação de stent (6 mm) para tratamento de comunicação interatrial restritiva. No 106^o dia de vida, realizou-se operação de Norwood associada à anastomose cavopulmonar bilateral. As bandagens foram removidas, sem distorção das artérias pulmonares.

Conclusões: O uso clínico deste sistema inovador de bandagem ajustável das artérias pulmonares mostrou-se factível, seguro e eficaz. Permitiu o ajuste fino do fluxo pulmonar de acordo com as necessidades clínicas, proporcionando um equilíbrio preciso entre as circulações pulmonar e sistêmica.

Descritores: Cardiopatias congênicas. Contenedores. Assistência paliativa. Síndrome do coração esquerdo hipoplásico. Artéria pulmonar, cirurgia. Dilatação com balão.

INTRODUCTION

The traditional surgical approach of newborns with hypoplastic left heart syndrome is complex and continues to have significant mortality compared with other neonatal cardiac operations [1]. Single ventricle palliation with the Norwood operation and a systemic-to-pulmonary shunt aims at redirecting circulatory pathways to protect the pulmonary vasculature from excessive blood flow and optimize systemic organ flows. However, some overloading of the systemic right ventricle still persists after this operation. Also, such major surgical procedures are usually performed in the neonatal period (sometimes in a low-birth weight patient and with unfavorable anatomy), which may result in sub-optimal neurological outcomes in the long-term.

An alternative approach for palliation of hypoplastic left

heart in the neonatal period, first recommended by Gibbs et al. [2], has been stenting the arterial duct in combination with branch pulmonary artery banding and atrial septostomy, as needed [3-5]. At present, most of the technical challenges have been elucidated [6]. Currently, the hybrid stage I palliation is considered the preferred therapeutic approach in high-risk neonates [7,8]. However, fine adjustments of the amount of pulmonary blood flow, which is a critical issue, has proved to be a particularly difficult aspect of the procedure. This can be readily explained when it is recalled that Poiseuille's law predicts that blood flow is related to the fourth power of the radius of the vessel [9,10].

Therefore, a minor alteration in diameter will have a large impact on flow and pressure gradient across the band site. Generally, the bands are surgically adjusted (tighten or loosened), based on pressure measurements and arterial

oxygen saturation monitoring. A systolic pressure in the distal pulmonary artery less than half of the systemic pressure and an arterial oxygen saturation of 75%-85% usually reflect an adequate balance between the pulmonary and systemic blood flow. This may be readily achieved in the operating room, with an open chest and under artificial conditions. However, in the postoperative period, which may be quite unpredictable, the fixed pulmonary bandings do not allow for fine adjustments according to the underlying clinical needs of the patient. Moreover, in order to avoid hypoxemia as the infant rapidly grows up, the balance between the pulmonary and systemic blood flows should be adjusted, which is impossible with fixed bands.

To deal with these problems, we devised a mini banding device that allows fine percutaneous adjustments of the pulmonary blood flow in the postoperative period. It is called ABS, which stands for "Assad Banding System" (Silimed Inc., Rio de Janeiro, Brazil). This innovative percutaneous adjustable pulmonary artery banding system permits fine control of the pulmonary blood flow by accurately increasing or decreasing the cross-sectional diameter of the pulmonary arteries. Therefore, it is adjusted according to the underlying clinical conditions of the patient: hypoxemia is, for instance, managed by loosening the pulmonary artery banding circumference.

The adjustable banding device

Our prototype is entirely made of silicone, a miniaturized and improved device developed in the laboratories of Heart Institute of the Hospital das Clínicas (FMUSP) from previous experimental studies that has resulted in a more delicate banding system for neonatal use (Figure 1) [11-19]. It consists of three parts: a banding ring, connecting tubing, and an inflation reservoir. The banding ring is a C-shaped hydraulic cuff, with an internal diameter of 1 mm to 5 mm and 5-mm width, and a rigid outer layer, reinforced with a Dacron mesh, which stops it from becoming centrifugally deformed. The cuff compresses the lumen of the pulmonary artery when expanded, according to the volume percutaneously injected into the subcutaneously implanted inflation reservoir. The banding ring is potentially able to increase by 500% in size, promoting a wide range of reversible constriction of the banded pulmonary artery. The connecting tubing (70 mm x 2 mm) hermetically connects the banding ring to the inflation reservoir.

In this paper, we report the first clinical application of this new percutaneous adjustable pulmonary artery banding system in a newborn baby with hypoplastic left heart syndrome, who successfully underwent initial palliation. Neo-aortic reconstruction and a bidirectional cavopulmonary connection were successfully performed at 3.5 months of life.

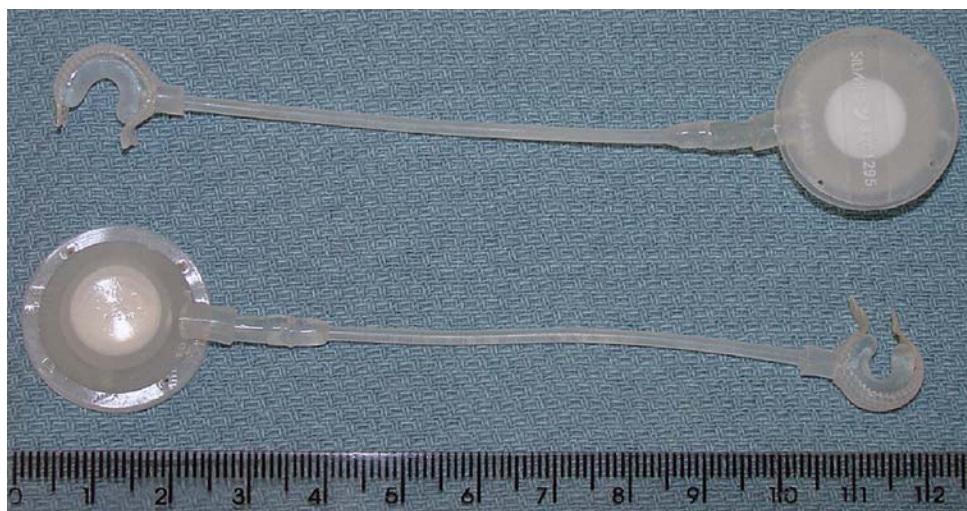

Fig. 1 - The adjustable pulmonary artery banding system is made entirely of silicone. It consists of three parts: banding ring and inflation reservoir and connecting tube (70 mm x 2 mm)

CASE REPORT

This was a full term female newborn, weighing 2.76 kg, with a prenatal diagnosis of hypoplastic left heart syndrome. A postnatal echocardiogram confirmed the intrauterine findings: the aortic and mitral valves were atretic and stenotic, respectively, and the diameter of the ascending aorta was 2.5 mm. There was an unrestrictive atrial septal defect measuring 6 mm. She initiated on a prostaglandin infusion and her systemic saturation was 90-95% in room air with spontaneous breathing. Perinatal management with the new adjustable pulmonary artery banding system had been planned in a tertiary care center (Hospital Samaritano, Sao Paulo, Brazil). After extensive discussions with the parents during gestation, including explanation of the procedure's benefits and risks and the possibility of heart transplantation, the new banding device was used on a compassionate basis after obtaining approval from the local Ethics Committee and written informed consent from parents.

The stage I operation was carried out on the fifth day of life. Through a median sternotomy, the patient underwent bilateral pulmonary artery banding with the new percutaneously adjustable system (Figure 2), associated with a reversed modified Blalock-Taussig shunt (6 mm polytetrafluoroethylene tube) between the main pulmonary artery and proximal innominate artery, without cardiopulmonary bypass (Figure 3).

The strategy of stenting the arterial duct was not applied in this case due to absence of obstructive aortic arch lesion or coarctation. Once the two adjustable banding rings were placed around the pulmonary arteries and the inflation reservoirs left in the infraclavicular subcutaneous tissue, the degree of banding ring constriction was adjusted after sternal closure. Each band was inflated with 0.30 mL saline solution to decrease arterial oxygen saturation to the 75%-80% range, while breathing under a 30% inspired oxygen fraction. The prostaglandin infusion was discontinued following the procedure.

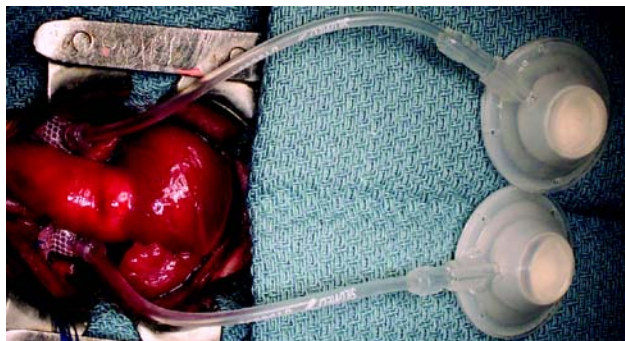


Fig. 2 - Bilateral pulmonary artery banding with the new percutaneously adjustable system (4 mm), implanted through a mid sternotomy. The inflation buttons are to be implanted subcutaneously in the patient's chest wall

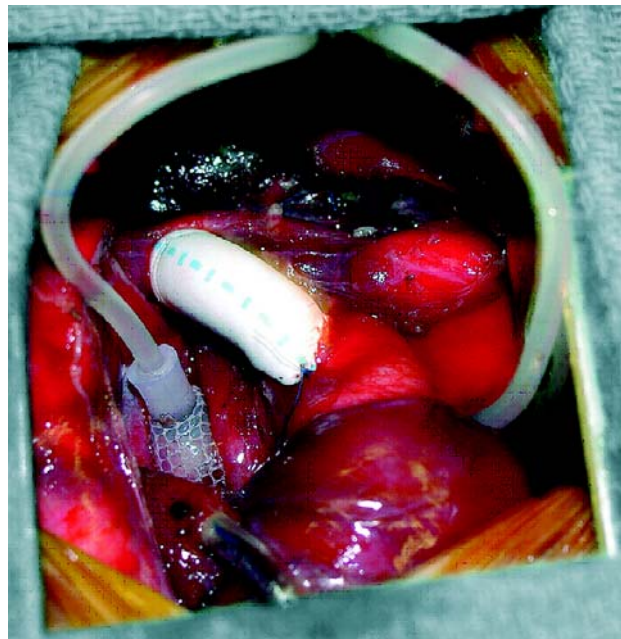


Fig. 3 - Reversed modified Blalock-Taussig shunt (6 mm Goretex tube) between the main pulmonary artery and innominate artery performed through a mid sternotomy

The patient had an uneventful postoperative course, with no need for inotropic medications or bicarbonate. Nitroprusside was used to control systemic hypertension. She was weaned from mechanical ventilation on Postoperative Day 6. She was discharged 21 days after the operation. Three percutaneous adjustments of the banding system were necessary during the hospital stay to keep the arterial oxygen saturation within the 75%-85% range (Figure 4).

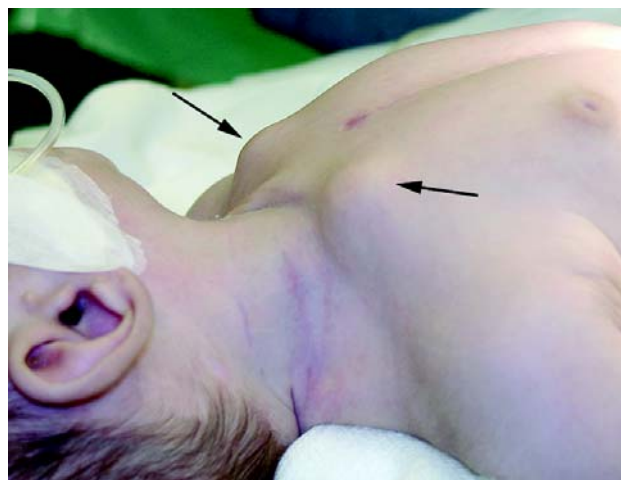


Fig. 4 - Inflating reservoirs positioned in the infraclavicular area, one for each pulmonary artery for independent percutaneous blood flow adjustment

The infant was followed closely with serial echocardiographic assessment every week, which showed progressive obstruction of the atrial septal defect. There was no obstruction within the aortic arch and the main pulmonary artery to the innominate artery shunt was widely patent. There was good qualitative right ventricular function and minimal tricuspid valve regurgitation. Therefore, on the 48th day of life, a 6 x 19 mm, pre-mounted Palmaz Genesis stent (Cordis Co., Miami, FL) was implanted across the atrial septal defect, with clear hemodynamic and arterial oxygen saturation improvement (Figure 5), despite remaining in an off-center position. After that, seven additional percutaneous adjustments (removal of saline solution from the reservoir) of the banding system were necessary, so that in the last adjustment performed on the 91st day of life, only 0.12 mL saline solution was left in each band to maintain the arterial oxygen saturation within the recommended range (Figure 6).

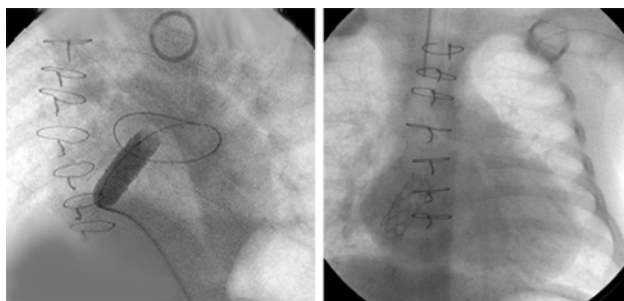

Fig. 5 - Pre-mounted Palmaz Genesis stent (6 x 19 mm) deployed across the atrial septal defect

The patient was electively submitted to the “comprehensive” stage II surgical palliation on the 106th day of life. Progressive obstruction within the interatrial stent had been noted on repeat echocardiograms before surgery. Direct anastomosis of the main pulmonary artery to the transverse aortic arch with no prosthetic materials was performed along with a bidirectional cavopulmonary connection. The anatomy of the pulmonary arteries was well preserved with no distortions. The stent was removed from the interatrial septum and a complete atrial septectomy was carried out. Upon removal, inspection of the stent displayed significant intrastent neoproliferation, leaving a 3-mm orifice that caused the restrictive blood flow through the atrial septal defect (Figure 7). The initial postoperative period was uneventful, with adequate saturation and systemic cardiac output. However, on Postoperative Day 11, she was reoperated to drain a subcutaneous tissue abscess caused by *Pseudomonas aeruginosa*. She remained

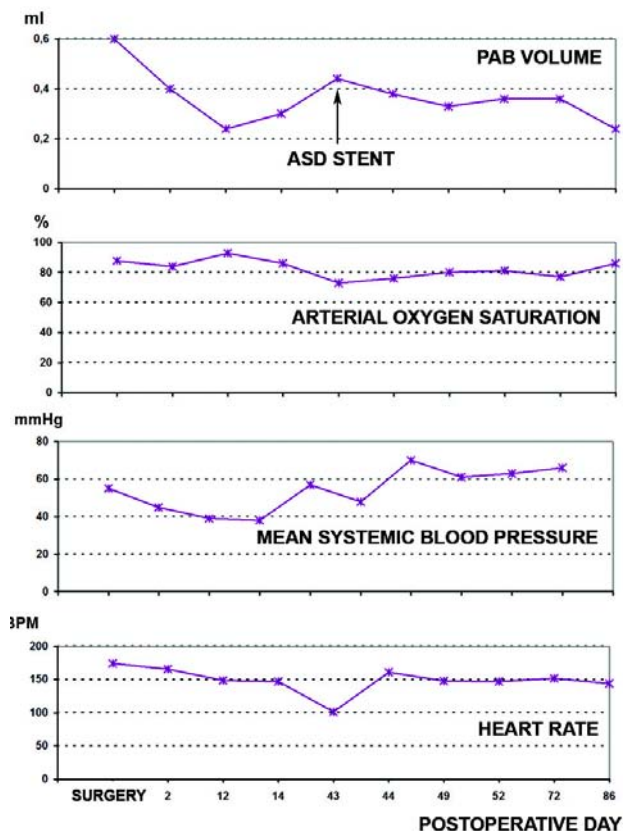


Fig. 6 - Hemodynamics and arterial oxygen saturation during pulmonary artery banding adjustments. PAB VOLUME = total volume injected in both inflating reservoirs; ASD = atrial septal defect

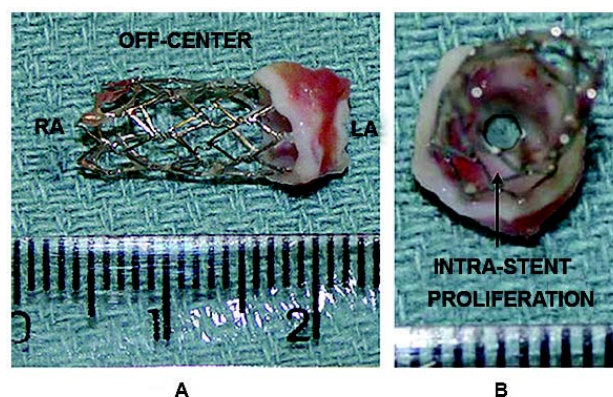


Fig.7 - Stent pré-montado Genesis (6 X 19 mm) mostrando proliferação intra-stent importante, com orifício residual de 3 mm. Painel A: vista lateral, mostrando o posicionamento descentralizado do stent no septo interatrial. AD= lado do átrio direito, AE= lado do átrio esquerdo; Painel B: Vista superior, mostrando a proliferação do tecido intra-stent

on antibiotic therapy for a total of 30 days, with good clinical response. Oral feeding was progressively re-established and she was discharged home on Postoperative Day 50. At present, she is 14 months old, doing well on low doses of vasodilators, with arterial oxygen saturation in the low 80s, normal neurodevelopmental function, with weight and length above the 5th percentile on growth charts, usually expected for infants with complex congenital heart disease [20]. Total cavopulmonary connection (Modified Fontan Surgery) is planned for 2 years time.

DISCUSSION

To the best of our knowledge, this is the first report to demonstrate the feasibility, safety and efficacy of the use of the new percutaneously adjustable pulmonary artery banding system for stage I palliation of hypoplastic left heart syndrome in a neonate.

Prior to applying this new technique in human beings, we extensively evaluated the feasibility and safety of different banding devices in young goats for more than one decade, by assessing the acute right ventricular hypertrophy [10-12,2,3]. The cumulated knowledge of our experimental work was crucial to test our system in a clinical setting, making implantation technically straightforward.

Our new banding system is a biocompatible device, which can easily be placed during an operation with no technical difficulties. It proved to be a very efficient, simple and precise method to percutaneously regulate the pulmonary blood flow over time, resulting in a balanced pulmonary and systemic circulation with adequate saturation as the patient rapidly grew and gained weight. The adjustments could be performed as many times as required, both in the acute stage and in the outpatients' setting, avoiding additional surgical interventions. These fine and reversible adjustments can not be achieved when using traditional surgical banding devices and techniques that are commonly employed for patients with hypoplastic left heart syndrome. The use of this innovative percutaneous adjustable banding system seems to result in a more predictable postoperative course, including in the immediate postoperative period and the inter-stage phase, and a more stable patient, which is highly desirable for the comprehensive phase II operation.

One concern with any pulmonary artery banding technique or device, including the one reported here, is the possibility of causing vessel distortion or stenosis, which may have a deleterious impact on subsequent cavopulmonary operations. Fortunately, the scar tissue surrounding the banding devices was minimal in our patient and did not result in any of these complications. Whether this is related to the material of the banding rings (silicone) is speculative. This issue remains to be clarified with ongoing experience.

On the other hand, the main problem that has emerged in this case was the postoperative infection in the subcutaneous tissue, probably related to the presence of the subcutaneous reservoirs. Although this was a minor complication that was easily managed with antibiotic therapy and drainage of the subcutaneous abscess, it is of paramount importance to keep judiciously sterile techniques when manipulating equipment required to inflate or deflate the reservoirs.

The issue of progressive obstruction through the atrial septal defect, although not related only to the new banding system per se, was another problem in this case, which anticipated the indication of the comprehensive stage II operation. It is well known that even large, unobstructed atrial septal defects in patients with hypoplastic left heart syndrome, such as the one observed initially in the case presented herein, generally become restrictive over time. Stent implantation within the atrial septum has been advocated to treat this complication [6]. The application of this technique in our case proved to be successful for only two months. Significant intra-stent proliferation was observed during the phase II operation. Whether this was related to the type of stent employed, its position (off-center) or final diameter is speculative. Accurate diagnosis of this complication using serial echocardiography is mandatory since deflation of the reservoirs to loosen the pulmonary artery bands could result in pulmonary venous congestion and hypoxemia. It is clear that overall success of this new banding approach is closely related to early establishment of unrestrictive pulmonary blood flow through the atrial septal defect. New catheter technologies must aim at creating a reliable, unrestrictive and durable atrial communication.

We acknowledge that not having stented the duct in order to ensure an unrestrictive systemic blood flow in this case may be highly debatable. However, ductal stent deployment has not been completely free of technical and procedural complications [21]. It may not be necessary in an uncommon and occasional patient with no aortic arch obstructions, such as ours. In our patient, the reversed Blalock Taussig shunt from the main pulmonary artery to the innominate artery worked well to maintain adequate blood flow to the coronary artery, head and neck vessels and lower body arteries after ductal constriction. Indeed, it has a potential to improve coronary flow dynamics [22]. The issue of how to recognize such an uncommon patient using echocardiography remains to be better established with greater experience.

CONCLUSION

In conclusion, the use of our innovative percutaneously adjustable bilateral pulmonary artery banding system allowed fine control of the pulmonary blood flow in a neonate with

hypoplastic left heart syndrome undergoing phase I palliation. This customization of the pulmonary blood flow according to the underlying clinical needs of an infant with rapid somatic growth seems to result in a more precise balance between the pulmonary and systemic circulations during the inter-stage period. Further clinical studies with a larger number of patients and a broader spectrum of the disease are planned in the future.

ACKNOWLEDGEMENTS

We acknowledge the careful assistance of Dr. Tereza Uras, Dr. Kátia Santos, and Maria Fernanda Dib, R.N. and all the professionals from their respective areas, the Neonatal and Pediatric Intensive Care Unit, and the Operating Room in Hospital Samaritano, for providing the great amount of support to the patient and her family.

OBSERVATION

Modified Fontan Surgery (fenestrated intra-atrial tunnel) was done successfully in the 21st month of live.

REFERENCES

1. Ashburn DA, McCrindle BW, Tchervenkov CI, Jacobs ML, Lofland GK, Bove EL, et al. Outcomes after the Norwood operation in neonates with critical aortic stenosis or aortic valve atresia. *J Thorac Cardiovasc Surg.* 2003;125(5):1070-82.
2. Gibbs JL, Wren C, Watterson KG, Hunter S, Hamilton JR. Stenting of the arterial duct combined with banding of the pulmonary arteries and atrial septectomy or septostomy: a new approach to palliation for the hypoplastic left heart syndrome. *Br Heart J.* 1993;69(6):551-5.
3. Boucek MM, Mashburn C, Chan KC. Catheter-based interventional palliation for hypoplastic left heart syndrome. *Semin Thorac Cardiovasc Surg Pediatr Card Surg Annu.* 2005;72-7.
4. Michel-Behnke I, Akintuerk H, Marquardt I, Mueller M, Thul J, Bauer J, et al. Stenting of the ductus arteriosus and banding of the pulmonary arteries: basis for various surgical strategies in newborns with multiple left heart obstructive lesions. *Heart.* 2003;89(6):645-50.
5. Akintuerk H, Michel-Behnke I, Valeske K, Mueller M, Thul J, Bauer J, et al. Stenting of the arterial duct and banding of the pulmonary arteries: basis for combined Norwood stage I and II repair in hypoplastic left heart. *Circulation.* 2002;105(9):1099-103.
6. Galantowicz M, Cheatham JP. Lessons learned from the development of a new hybrid strategy for the management of hypoplastic left heart syndrome. *Pediatr Cardiol.* 2005;26(3):190-9.
7. Lim DS, Peeler BB, Matherne GP, Kron IL, Gutgesell HP. Risk-stratified approach to hybrid transcatheter-surgical palliation of hypoplastic left heart syndrome. *Pediatr Cardiol.* 2006;27(1):91-5.
8. Bacha EA, Daves S, Hardin J, Abdulla RI, Anderson J, Kahana M, et al. Single-ventricle palliation for high-risk neonates: the emergence of an alternative hybrid stage I strategy. *J Thorac Cardiovasc Surg.* 2006;131(1):163-71.
9. Gibbs JL, Uzun O, Blackburn ME, Wren C, Hamilton JR, Watterson KG. Fate of the stented arterial duct. *Circulation.* 1999;99(20):2621-5.
10. Pizarro C, Murdison KA. Off pump palliation for hypoplastic left heart syndrome: surgical approach. *Semin Thorac Cardiovasc Surg Pediatr Card Surg Annu.* 2005:66-71.
11. Assad RS, Cardarelli M, Abduch MCD, Aiello VD, Maizato M, Jatene AD. Bandagem reversível do tronco pulmonar: modelo experimental para o preparo rápido do ventrículo pulmonar. *Rev Bras Cir Cardiovasc.* 1998;13(3):239-48.
12. Assad RS, Cardarelli M, Abduch MC, Aiello VD, Maizato M, Barbero-Marcial M, et al. Reversible pulmonary artery banding with balloon catheter: Assessment of rapid pulmonary ventricular hypertrophy. *J Thorac Cardiovasc Surg.* 2000;120(1):66-72.
13. Dias CA, Assad RS, Caneo LF, Abduch MCD, Aiello VD, Dias AR. Modelo experimental de bandagem ajustável do tronco pulmonar para preparo rápido do ventrículo. *Rev Bras Cir Cardiovasc.* 2000;15(4):328-37.
14. Dias CA, Assad RS, Caneo LF, Abduch MC, Aiello VD, Dias AR, et al. Reversible pulmonary trunk banding. II. An experimental model for rapid pulmonary ventricular hypertrophy. *J Thorac Cardiovasc Surg.* 2002;124(5):999-1006.
15. Caneo LF, Dias CA, Assad RS, Abduch MCD, Aiello VD, Marcial MB, et al. Preparo do ventrículo subpulmonar através de dois modelos ajustáveis de estenose do tronco pulmonar: estudo experimental. *Rev Bras Cir Cardiovasc.* 2001;16(1):35-48.

16. Rabello RR, Assad RS, Krieger JE, Carmona R, Abduch MCD, Oliveira SA. Análise da atividade da enzima conversora da angiotensina na hipertrofia aguda do ventrículo direito em modelo experimental de estenose endovascular ajustável do tronco pulmonar. *Rev Bras Cir Cardiovasc*. 2001;16(4):364-75.
17. Assad RS, Rodriguez MQ, Abduch MCD, Valente AS, Andrade JL, Krieger JE, et al. Bandagem ajustável do tronco pulmonar: comparação de dois métodos de hipertrofia aguda do ventrículo subpulmonar. *Rev Bras Cir Cardiovasc*. 2006;21(4):418-28.
18. Rodriguez M, Assad RS, Valente A, Abduch MCD, Andrade JL, Krieger JE, et al. Reversible pulmonary artery banding V: intermittent x continuous ventricle overload of goats. *Circulation*. 2004;110(17):II-621.
19. Abduch MC, Assad RS, Rodriguez MQ, Valente AS, Andrade JL, Demarchi LMM, et al. Reversible pulmonary trunk banding III: assessment of myocardial adaptive mechanisms - contribution of cell proliferation. *J Thorac Cardiovasc Surg*. 2007; no prelo.
20. Forchielli ML, McColl R, Walker WA, Lo C. Children with congenital heart disease: a nutrition challenge. *Nutr Ver*. 1994;52(10):348-53.
21. Boucek MM, Mashburn C, Kunz E, Chan KC. Ductal anatomy: a determinant of successful stenting in hypoplastic left heart syndrome. *Pediatr Cardiol*. 2005;26(2):200-5.
22. Caldarone CA, Benson LN, Holtby H, Van Arsdell GS. Main pulmonary artery to innominate artery shunt during hybrid palliation of hypoplastic left heart syndrome. *J Thorac Cardiovasc Surg*. 2005;130(4):e1-2.