

Coronary aneurysm after drug-eluting stent implantation

Aneurisma coronário após implante de stent com eluição de fármaco

Paulo Paredes PAULISTA¹, Paulo Henrique Dágola PAULISTA², Marinella Patrícia CENTEMERO³, Fausto FERES⁴

RBCCV 44205-961

Abstract

Drug-eluting stents to counter the disadvantage of stainless steel stents have been associated to late thrombosis on withdrawal of antiplatelet agents. We report a case with another complication: the development of a coronary aneurysm in the stent area, more than three years after index procedure. Late chronic local inflammatory responses may be responsible for the weakening, erosion, and aneurysm formation.

Descriptors: Stents/adverse effects. Coronary aneurysm. Cardiac surgical procedures.

Resumo

A utilização de stents com eluição de fármacos com a finalidade de contornar as desvantagens dos stents não farmacológicos tem sido associada a trombose tardia após a retirada dos agentes antiplaquetários. Relatamos aqui o caso de outra complicação, a formação de aneurisma coronário adjacente ao stent farmacológico, após mais de três anos de implante. As respostas inflamatórias arteriais crônicas locais podem ser as responsáveis pelo enfraquecimento, erosão e formação aneurismática.

Descritores: Contenedores/ efeitos adversos. Aneurisma coronário. Procedimentos cirúrgicos cardíacos.

1. Titular Member of the Brazilian Society of Cardiovascular Surgery, São Paulo, SP, Brazil.
2. Cardiovascular physician surgeon of the Institute Dante Pazzanese of Cardiology.
3. PhD in Cardiology by University of São Paulo – USP, Physician of the Coronary Angioplasty Clinical Session of the Invasive Cardiology Service of the Institute Dante Pazzanese of Cardiology.
4. PhD in Cardiology by the University of São Paulo – USP, Director of the Invasive Cardiology Service of the Institute Dante Pazzanese of Cardiology.

This study was carried out at Institute Dante Pazzanese of Cardiology, São Paulo, Brazil.

Correspondence address:

Paulo Paredes Paulista. Av. Dr. Dante Pazzanese, 500 - 11º andar - São Paulo - SP - Brasil – CEP 04012-180 – Tel: 55-11-5085-6034 – Fax: 55-11-5085-6187.

E-mail: paulistapaulo@ig.com.br

Article received on Oct 30th, 2007

Article approved on Jan 7th, 2008

INTRODUCTION

The use of drug-eluting or adsorption stents (also known as pharmacological stents) in obstructive coronariopathy treatment has been associated to late thrombosis and restenosis. These complications have been related to inflammatory process and they can also be responsible for late development of aneurysms in the site of stent implantation.

We present a case of local aneurysm development after pharmacological stent implantation.

CASE REPORT

Clinical data

A 60-year-old-female patient, Caucasian, 57kg, without family background of coronary artery disease, presenting systemic arterial hypertension; dyslipidemic, smoker and with high levels of stress. Originally from São Paulo, SP, she was admitted to a hospital on April 7th, 2004 with precordial and constrictive pain which had spread to the shoulder and left arm after only moderate physical effort, even though the patient had already been medicated with aspirin, beta blockers and coronary vasodilator.

During the physical examination, the patient was coloring, with low heart rate of 72bpm, arterial blood pressure of 110/70mmHg in superior limbs. Normal heart sounds without significant changes. Normal electrocardiogram and chest radiography with situs solitus, without any report of significant event.

On April 8th, 2004, a cinecoronariography was performed in the patient using the Judkins technique, which showed dominant right coronary artery without significant atherosclerosis and left coronary trunk with good caliber. The descending anterior artery presented stenosis of 50% in the middle third and the circumflex artery presented subocclusive lesion in the distal third and prebifurcation. Preserved left ventricular function and competent mitral valve. Absence of obstacles to the ventricular ejection.

On April 15th, 2004, a 2,50mm x 13mm Cypher stent (Cordis Corp, Miami Lakes, Florida) was implanted in the circumflex artery before the bifurcation and after previous successfully local angioplasty (TIMI III flow, residual lesion less than 30% without thrombi or dissection). The medication was continued after hospital discharge, and included Clopidogrel.

On December 22th, 2004, the patient was sent to the Institution again, due to the reappearance of precordial pain. A rest electrocardiogram (ECG) with normal result and a stress test with positive response were performed. The patient stayed on treatment until March 17th, 2005, when another cinecoronariography was performed, which confirmed the described lesion in the descending anterior

artery in the first examination and lesion of 70% in the proximal third of the right coronary artery. Thus, a transluminal coronary angioplasty was performed in this coronary artery, and another 3.50mm x 18mm Cypher stent was implanted without residual lesion and with TIMI III distal flow, which produced successful results. The circumflex artery that was studied on the occasion presented good results with the previous implantation of the aforementioned Cypher stent. The patient was discharged from hospital on March 18th, and was treated with simvastatin, aspirin, beta blockers and clopidogrel.

The patient developed well until June 2007, when she again presented precordial pain Class II, which led to the need for a new cinecoronariography in order to verify both previous stents and to evaluate the preexisting lesion in the anterior descending artery. The restudy on June 26th showed severe aneurysmal dilatation in the region of the stent, which had been implanted over three years and two

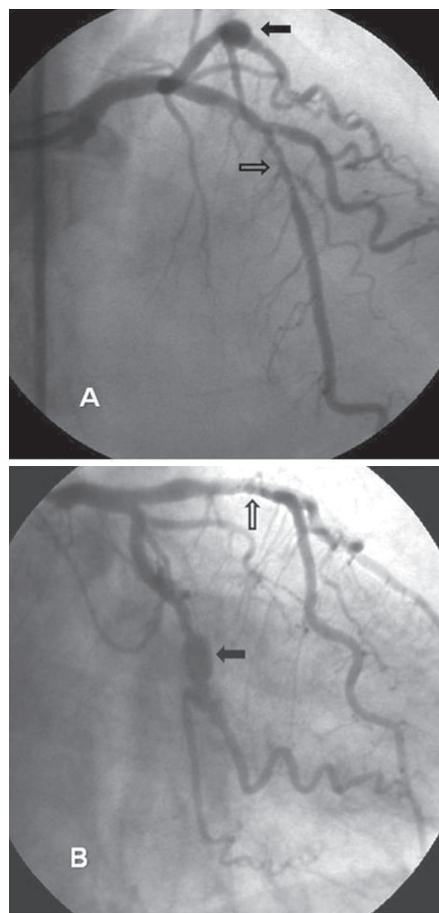


Fig. 1 – Cinecoronariography in two projections, A and B, showing aneurysm after pharmacological stent implantation in circumflex artery (black arrow) and lesion segmented in anterior descending artery (white arrow).

months ago in the circumflex artery associated with moderate stenosis. On that occasion, there was an unsuccessful attempt to perform intracoronary ultrasound. The anterior descending artery was calcified with aggravation of the middle third segmental lesion. The right coronary artery showed stent in its proximal third with preserved aspect. The left ventricular function was normal (Figure 1).

According to these facts, surgical treatment was indicated, and was performed on July 11th, 2007 with assistance of cardiopulmonary bypass. The marginal artery was revascularized with segment of greater saphenous vein in retroaortic position due to stenotic lesion associated to the stent. The aneurysmal formation was located in the left atrioventricular sulcus, in the region of the circumflex artery, and it was not taken into account. During palpation, this aneurysmal formation had firm consistency and nearly 10mm of its larger diameter. In the same procedure, the anterior descending artery was treated with direct end-to-side anastomosis of the previously prepared left internal thoracic artery. The perfusion time was 45 minutes and the simple intermittent anoxia comprised 35 minutes.

The surgery was performed without incident. Evolution in hospital was free of complications and the discharge from hospital occurred on the fifth postoperative day. The patient is currently asymptomatic.

DISCUSSION

The risk of late thrombosis after stents implantation with drug elution has been an increased concern, especially when the antiplatelet therapy is interrupted [1], as Abreu et al. [2] already described in 2005. Recently, another complication has been observed with these stents: the formation of coronary aneurysm at the implant site with unknown incidence, but frequently mentioned in the international literature [3].

The late thrombosis and the formation of aneurysms in the coronary arteries may have the same pathogeny of inflammatory reaction to foreign bodies [4] and to the drugs that coat the stents, since they are not explained by technical factors, such as the use of improper stent sizes or excessive pressure during placement.

The drug elution stents, beyond their metallic frames, are coated by polymers that slowly release drugs at the site, such as sirolimus, inducing a sustained suppression of smooth muscular and neointimal proliferation over a one-year period. Due to the fact that the sirolimus is no longer in the stent after 60 days, the cause of the continuous irritation has been attributed to the polymer, which, because of its long-term staying power, could cause a persistent inflammation, local weakness and aneurysm formation. Such occurrences are less frequent in stents with non-coated metal [5].

The potential use of biodegradable polymers is an expectancy to solve this late and undesirable complication. The late incomplete apposition of the stent filaments can be due to a potential consequence of the coronary aneurysms formation process, verifiable by intracoronary ultrasound, which was not performed in our case [6].

The best option for treatment for this complication caused by the use of pharmacological stents has still not been established. Some aneurysms are spontaneously solved after period of vigilance, but others have indication of use of coils or covered stents, and finally, as in this case, some aneurysms have indication of surgery [6]. The possibility of sudden rupture of the aneurysm with cardiac tamponade is an emergency that has already been described [7].

ACKNOWLEDGMENT

To Dr. Michael Batlouni, for his review of the text.

REFERENCES

1. Bavry AA, Kumbhani DJ, Helton TJ, Borek PP, Mood GR, Bhatt DL. Late thrombosis of drug-eluting stents: a meta-analysis of randomized clinical trials. *Am J Med.* 2006;119(12):1056-61.
2. Abreu L, Meireles GC, Forte AA, Sumita M, Hayashi J, Solano J. Aneurisma de artéria coronária um ano e cinco meses após implante de stent com eluição de sirolimus. *Arq Bras Cardiol.* 2005;85(5):340-2.
3. Bavry AA, Chiu JH, Jefferson BK, Karha J, Bhatt DL, Ellis SG et al. Development of coronary aneurysm after drug-eluting stent implantation. *Ann Intern Med.* 2007;146(3):230-2.
4. Feres F, Costa JR Jr, Abizaid A. Very late thrombosis after drug-eluting stents. *Catheter Cardiovasc Interv.* 2006;68(1):83-8.
5. Luthra S, Tatoulis J, Warren RJ. Drug-eluting stent-induced left anterior descending coronary artery aneurysm: repair by pericardial patch. Where are we headed? *Ann Thorac Surg.* 2007;83(4):1530-2.
6. Al Mutairi M, Al Merri K. Symptomatic large coronary aneurysm associated with Sirolimus - eluting stent implantation. *Kuwait Med J.* 2007;39(2):190-2.
7. Gupta RK, Sapra R, Kaul U. Early aneurysm formation after drug-eluting stent implantation: an unusual life-threatening complication. *J Invasive Cardiol.* 2006;18(4):E140-42.