

# Abordagem paraesternal para refazer um pseudo-aneurisma aórtico

## *Parasternal approach for redo in ascending aorta pseudoaneurysm*

Guillermo Nuncio VACCARINO<sup>1</sup>, Fernando PICCININI<sup>2</sup>, Juan M. VRANCIC<sup>3</sup>, Daniel NAVIA<sup>4</sup>

RBCCV 44205-987

### *Resumo*

Pseudo-aneurisma na parte ascendente da aorta é uma complicação rara após cirurgia da raiz da aorta. A solução cirúrgica é bastante exigente e complexa, especialmente quando chega ao mediastino. Esta parte última se traduz em elevada morbidade e mortalidade. Apresentamos um caso realizado por meio de uma toracotomia direita anterior mínima, que nos permitiu dissecar entre o pseudo-aneurisma e o sítio interno do esterno como um passo inicial, antes de uma segunda esternotomia. Ao usar essa abordagem, minimizamos os riscos de hemorragia e a possibilidade de um rompimento da aorta. Essa técnica tem o potencial para ser aplicável amplamente nessa complicação, após avaliação ulterior.

**Descritores:** Aorta/cirurgia. Aneurisma aórtico/cirurgia. Aneurisma dissecante/cirurgia. Falso aneurisma/cirurgia.

### *Abstract*

Aortic ascending pseudoaneurysm is a rare complication following aortic root surgery. The surgical solution of the complication is rather demanding and complex, especially when reaching the mediastinum. The latter translates into an elevated morbidity and mortality. We present a case performed through a minimal anterior right thoracotomy, which allowed us to dissect between the pseudoaneurysm and the internal site of the sternum as a first step prior to a second sternotomy. By using this approach, we minimized bleeding risks and the possibility of aortic rupture. This technique could have the potential to be generally applicable in this complication after further evaluation.

**Descriptors:** Aorta/surgery. Aortic aneurysm/surgery. Aneurysm, dissecting/surgery. Aneurysm, false/surgery.

1. Cardiovascular surgeon - Instituto Cardiovascular de Buenos Aires, Argentina.
2. MD - Department of Cardiovascular Surgery, Instituto Cardiovascular de Buenos Aires, Ciudad Autónoma de Buenos Aires, Argentina.
3. MD - Department of Cardiovascular Surgery, Instituto Cardiovascular de Buenos Aires, Ciudad Autónoma de Buenos Aires, Argentina.
4. MD, PhD - Chief of Department of Cardiovascular Surgery, Instituto Cardiovascular de Buenos Aires, Ciudad Autónoma de Buenos Aires, Argentina.

Work done at Instituto Cardiovascular de Buenos Aires, Ciudad Autónoma de Buenos Aires, Argentina.

Correspondence address: Guillermo Vaccarino. Department of Cardiovascular Surgery, Instituto Cardiovascular de Buenos Aires, Blanco Encalada 1543, Ciudad Autónoma de Buenos Aires, Argentina. E-mail: gnvaccarino@icba-cardiovascular.com.ar

Artigo recebido em 7 de janeiro de 2008  
Artigo aprovado em 26 de março de 2008

## INTRODUCTION

Ascending aortic pseudoaneurysm is a rare but dreadful complication following cardiac and/or aortic root surgery. On extreme cases, pseudoaneurysm volume and location render re sternotomy unfeasible due to very high bleeding risk [1]. The best approach for this surgical intervention is still to be defined. The most common technique utilized is fem-fem cardiopulmonary derivation, deep hypothermia and cardiac arrest prior to reopening of the thorax [2].

Reinterventions of the ascending aorta by conventional re sternotomy are usually associated with difficulties on manipulation and cannulation of the aorta. We present a case of surgical correction of ascending aortic pseudoaneurysm with a minimal anterior thoracotomy, especially useful to prevent complication associated with the conventional anterior approach. The technique presented can be used only when the sternum is not deeply adherent to the aneurysm.

## CASE REPORT

A 60 year-old hypertensive male with a prior history of severe aortic valve stenosis, underwent aortic valve replacement with a bi-leaflet Medtronic Hall nº 23 in 1994. The patient was in his usual state of health on chronic anticoagulation for his mechanical valve until 2006. During a routine visit, chest X-Ray showed widening of the mediastinum (Figure 1). Transthoracic echocardiogram revealed a dilated ascending aorta with a 9 cm in anterior-posterior diameter, a functioning aortic mechanical valve, with normal systolic left ventricular ejection fraction (Figure 2). Multislice Chest CT confirmed an aortic ascending pseudoaneurysm adjacent to the internal table of the sternum (Figure 3).

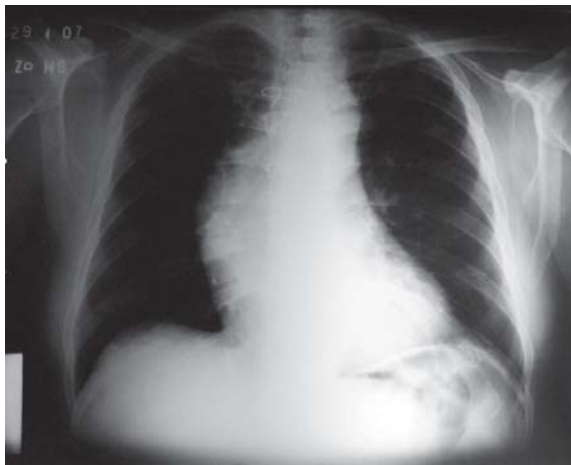


Fig. 1 - Chest X-Ray revealing widening of the mediastinum due to an enlarged ascending aorta

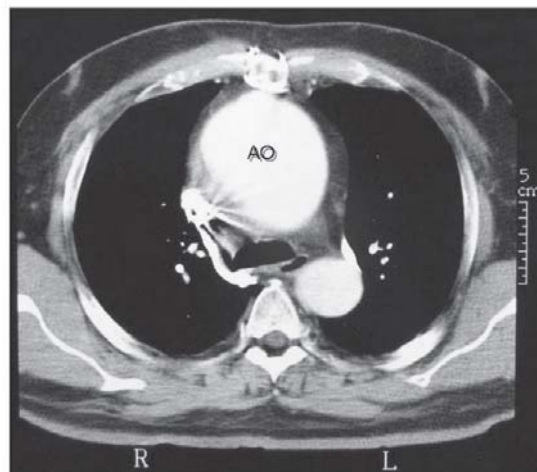


Fig. 2 - Transesophageal echocardiogram showing a severely dilated ascending aorta and a normal mechanical aortic valve

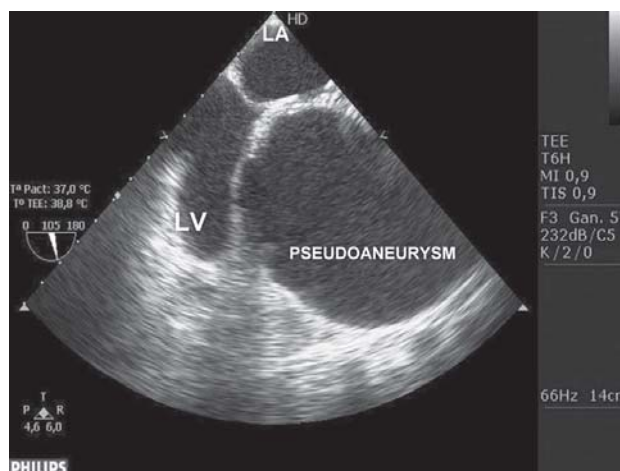


Fig. 3 - Multi-slice chest CT showing an enlarged ascending aorta (8 cm antero-posterior diameter) close contact to the retrosternal region

## Technique

While the patient was placed on dorsal decubitus, peripheral venous line and left radial artery were cannulated. Patient hemodynamic was assessed with a Swan Ganz catheter. After systemic heparinization, cannulation were also performed into the right femoral venous (29F venous return cannula, Medtronic) and into the right axillary artery with interposition a 8 mm Dacron prosthesis. A conventional cardiopulmonary bypass system with roller pumps and membrane oxygenator was used.

First chest incision was a 10 cm long right parasternal thoracotomy at the third intercostal space. Once on the pleural cavity, right pulmonary apex was mobilized to enable

an anterior mediastinal approach. We identified the pseudoaneurysm and its relation to chest wall through the pericardial reflection. This above-mentioned maneuver is rather simple and facilitates a non-traumatic dissection of the pseudoaneurysm with minimal risk of aortic rupture (Figure 4).

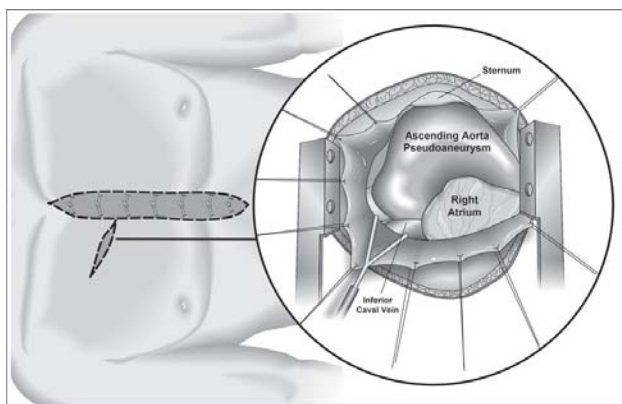


Fig. 4 - Surgery diagram illustrating the surgical approach and location of the pseudoaneurysm close to the sternum. See the location of our surgical wound at the right parasternal area

Following complete dissection of the anterior aspect of the aorta, pseudoaneurysm boundaries could be identified. Then, medium surgical gauze is located posterior to the sternum and an oscillating saw was used to perform a conventional sternotomy without need of cardiopulmonary bypass. After that, we dissected complete the mediastinum, the aorta with the pseudoaneurysm and the supraortic vessels.

We started with the cardiopulmonary bypass axillary artery-femoral vein and cooled down to 25°. Under hypothermic circulatory arrest, we opened and aspirated the pseudoaneurysm, identifying its neck. At that moment, distal hemiarch anastomosis was performed, with a total circulatory arrest time of around 10 minutes. We subsequently started extracorporeal circulation, clamped the proximal 30mm Dacron Haemashield prosthesis and performed proximal aortic supracoronary anastomosis. Total extracorporeal circulation and clamping time were 126 and 48 minutes respectively.

Postoperative outcome was uneventful and patient was discharged on day 7. During follow up, patient remained asymptomatic and late echocardiography studies showed non valvular dysfunction and integrity of the ascending aortic wall. There were no paresthesias or muscular dystrophy associated with the right parasternal approach (Figure 5).

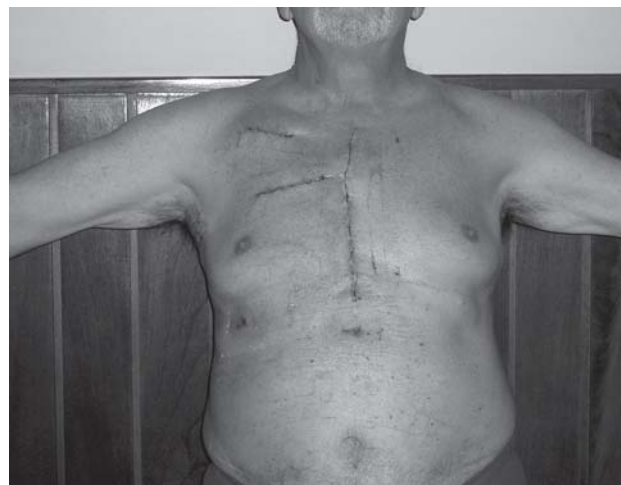

Fig. 5 - Postoperative photograph of the patient's chest prior to discharge, showing both scars from both surgeries: anterior mediastinal and the right parasternal approach

## DISCUSSION

The major issue during the surgical correction of an ascending aortic pseudoaneurysm is the mediastinum approach. During surgery, regaining access to the mediastinum is associated with high mortality risk due to potential rupture of the pseudoaneurysm. This above-mentioned risk is greater when the pseudoaneurysm is on direct contact with the sternum. By the most frequently used anterior approach, mortality rates due to bleeding are between 17 and 20% [3,4].

Mohammadi et al. [4] presented an experience with 28 patients who underwent surgical correction of the pseudoaneurysm with standard technique: extracorporeal circulation with femoral and carotid cannulation, in order to perform antegrade cerebral protection during cardiac arrest and moderate hypothermia. During the opening of the mediastinum, rupture of pseudoaneurysm was encountered in nine cases, with an overall mortality of 17.2%.

D'Attellis et al. [5] used portaccess with cannulation of femoral vessels, aortic endoclamp, cardioplegia and ventricular venting in an attempt to minimized bleeding risk while reentering to the thorax.

During the last ten years, the cardiac surgical team at the Cleveland Clinic Foundation encountered only 60 cases, depicting the paucity of this complication [6]. All patients underwent resternotomy with extracorporeal circulation and cardiac arrest, and only three underwent right thoracotomy to control pseudoaneurysm growth. In their experience, mortality and morbidity was low.

The possibility of controlling mediastinal dissection by a right thoracotomy allows us to perform a resternotomy

without need of extracorporeal circulation and cardiac arrest. We used this technique in two more consecutive patients and we felt helped us to access the thorax in a safer. All three patients had a prior history of aortic valve replacement, and survived the surgery and were discharge home without complications on the thoracic incision site.

The minimal invasive right thoracotomy is a potential alternative technique for access to the mediastinum on a patient with an ascending aortic aneurysm, it does not require extracorporeal circulation and cardiac arrest and so far it has not been associated with severe bleeding or death. The technique presented can be used only when the sternum is not deeply adherent to the aneurysm. Further evolution of this technique is warranted.

#### REFERENCES

1. Katsumata T, Moorjani N, Vaccari G, Westaby S. Mediastinal false aneurysm after thoracic aortic surgery. *Ann Thorac Surg.* 2000;70(2):547-52.
2. Mulder EJ, van Bockel JH, Maas J, van den Akker PJ, Hermans J. Morbidity and mortality of reconstructive surgery of noninfected false aneurysms detected long after aortic prosthetic reconstruction. *Arch Surg.* 1998;133(1):45-9.
3. Apaydin AZ, Posacioglu H, Islamoglu F, Telli A. A practical tool to control bleeding during sternal reentry for pseudoaneurysm of the ascending aorta. *Ann Thorac Surg.* 2003;75(3):1037-8.
4. Mohammadi S, Bonnet N, Leprince P, Kolsi M, Rama A, Pavie A, et al. Reoperation for false aneurysm of the ascending aorta after its prosthetic replacement: surgical strategy. *Ann Thorac Surg.* 2005;79(1):147-52.
5. D'Attellis N, Diemont FF, Julia PL, Cardon C, Fabiani JN. Management of pseudoaneurysm of the ascending aorta performed under circulatory arrest by port-access. *Ann Thorac Surg.* 2001;71(3):1010-1.
6. Atik FA, Navia JL, Svensson LG, Vega PR, Feng J, Brizzio ME, et al. Surgical treatment of pseudoaneurysm of the thoracic aorta. *J Thorac Cardiovasc Surg.* 2006;132(2):379-85.