

Horizontal right axillary minithoracotomy: aesthetic and effective option for atrial and ventricular septal defect repair in infants and toddlers

Minitoracotomia axilar direita horizontal: opção estética e eficaz para correção de comunicação interventricular e interatrial em lactentes e crianças

Luciana da Fonseca da Silva^{1,2}, PhD; José Pedro da Silva², PhD; Aida L R Turquetto²; Sonia Meiken Franchi²; Cybelle M Cascudo²; Rodrigo Moreira Castro²; Walter José Gomes¹, PhD; Christian Schreiber³, PhD

DOI: 10.5935/1678-9741.20140028

RBCCV 44205-1531

Abstract

Introduction: Congenital heart defects treatment shows progressive reduction in morbidity and mortality, however, the scar, resulting from ventricular (VSD) and atrial septal defect (ASD) repair, may cause discomfort. Right axillary minithoracotomy approach, by avoiding the breast growth region, is an option for correction of these defects that may provide better aesthetic results at low cost. Since October 2011, we have been using this technique for repairing VSD and ASD defects as well as associated defects.

Objectives: To evaluate the efficacy of this method in children undergoing correction of VSD and ASD, to compare perioperative clinical outcomes with those repaired by median sternotomy, and to evaluate the aesthetic result.

Methods: Perioperative clinical data of 25 patients submitted to axillary thoracotomy were compared with data from a paired group of 25 patients with similar heart defects repaired by median sternotomy, from October 2011 to August 2012.

Results: Axillary approach was possible even in infants. There was no mortality and the main perioperative variables were similar in both groups, except for lower use of blood products in the axillary group (6/25) vs. control (13/25), with statistical difference ($P=0.04$). The VSD size varied from 7 to 15 mm in axillary group. Cannulation of the aorta and vena cavae was performed through the main incision, whose size ranged from 3 to 5 cm in the axillary group, with excellent aesthetic results.

Conclusion: The axillary thoracotomy was effective, allowing for a heart defect repair similar to the median sternotomy, with more satisfactory aesthetic results and reduced blood transfusion, and it can be safely used in infants.

Descriptors: Heart Septal Defects, Ventricular. Heart Septal Defects, Atrial. Surgical Procedures, Minimally Invasive.

¹Escola Paulista de Medicina da Universidade Federal de São Paulo, (UNIFESP/EPM), São Paulo, SP, Brazil.

²Hospital Beneficência Portuguesa de São Paulo, São Paulo, SP, Brazil.

³Department of Cardiovascular Surgery, German Heart Center Munich at the Technical University Munich, Munich, Germany.

Work carried out at Hospital Beneficência Portuguesa de São Paulo, Escola Paulista de Medicina - UNIFESP, São Paulo SP, Brazil; Department of Cardiovascular Surgery, German Heart Center Munich at the Technical University Munich, Munich Germany.

No financial support.

Correspondence address:

Rua Maestro Cardim, 769, sala 202 – Paraíso - São Paulo, SP, Brazil

Zip code: 01323-001

E-mail: lufonseca@uol.com.br

Article received on April 8th, 2013

Article accepted on July 14th, 2013

Abbreviations, acronyms & symbols	
Ao	Aortic cannula
AoC	Aortic clamp
ASD	Atrial septal defect
CHD	Congenital heart disease
CIA	Comunicação interatrial
CIV	Comunicação interventricular
CL	Cardioplegic line
CPB	Cardiopulmonary bypass
HRAMT	Horizontal right axillary mini thoracotomy
IVC	Inferior vena cava
MS	Median sternotomy
PTFE	Polytetrafluoroethylene
RAT	Right anterolateral thoracotomy
SVC	Superior vena cava
VSD	Approach through the right atriotomy
VSD	Ventricular septal defect

Resumo

Introdução: O tratamento dos defeitos cardíacos apresenta progressiva redução da morbimortalidade, porém, a cicatriz, seqüela aparente do tratamento da comunicação interatrial (CIA) e interventricular (CIV), pode causar incômodo. A abordagem por minitoracotomia axilar é opção para correção destes defeitos, com possível melhor estética e baixo custo, além de evitar a região

INTRODUCTION

The treatment of congenital heart defects has evolved with gradual reduction of morbidity and mortality, but the scar resulting from surgical treatment may be disturbing. The effective repair of ventricular septal defect (VSD) and atrial septal defect (ASD), with less aggressive approach to the patient, is the goal of minimally invasive surgery. The usual approach for correction of simple congenital heart disease (CHD) includes median sternotomy (MS) and right anterolateral thoracotomy (RAT)^[1].

Newer minimally invasive approaches such as ministernotomy^[2], trans-xiphoid approach without MS^[3,4] and posterolateral thoracotomy^[5,6] have been proposed for the treatment of children, attempting to avoid the distortion of breast growth that can be caused by RAT when applied in pre-pubescent girls^[7,8]. The axillary minithoracotomy, originally proposed for thoracic surgery^[9] was used as a vertical infra axillary minithoracotomy, associated with cardiopulmonary bypass (CPB) and ventricular fibrillation for ASD repair without clamping of the aorta^[10].

Subsequently, its use was expanded to approach other heart diseases^[11]. It offers the aesthetic benefit without increasing surgical costs, since it does not require special tools. Schreiber et al.^[12] reported the use of horizontal minithoracotomy in the fourth intercostal space, aortic and bicaval cannulation through

de crescimento da mama. Desde outubro de 2011, empregamos esta técnica para correção de CIA, CIV e defeitos associados.

Objetivo: Avaliar a eficácia do método em crianças submetidas à correção de CIV e CIA, avaliar a evolução clínica perioperatória em comparação à esternotomia mediana e avaliar o resultado estético.

Métodos: Dados clínicos perioperatórios de 25 pacientes submetidos à minitoracotomia axilar foram comparados com dados de grupo de 25 pacientes submetidos à correção de defeitos cardíacos semelhantes por esternotomia mediana, de outubro de 2011 a agosto de 2012.

Resultados: A correção dos defeitos via axilar foi factível inclusive em lactentes. Não houve mortalidade e as principais variáveis perioperatórias foram similares em ambos os grupos, exceto pelo menor uso de hemoderivados no grupo axilar (6/25) x controle (13/25), com diferença estatística ($P=0,04$). A seqüela ventricular nos pacientes do grupo axilar variou de 7 a 15 mm. A canulação da aorta e veias cavas foi realizada através da incisão principal, cujo tamanho variou de 3 a 5 cm no grupo axilar, com resultado estético excelente.

Conclusão: A minitoracotomia axilar foi eficaz, permitiu correção do defeito cardíaco semelhante à esternotomia mediana, com resultado estético mais satisfatório e menor necessidade de transfusão sanguínea, podendo ser utilizada com segurança em lactentes.

Descritores: Comunicação Interventricular. Comunicação Interatrial. Procedimentos Cirúrgicos Minimamente Invasivos.

the same incision for repair of ASD, using heart fibrillation, and no aortic cross-clamping.

They demonstrated this technique to us, which we modified by opening the chest in the third intercostal space, cross-clamping the aorta and applying cardioplegic solution. This strategy has allowed us to repair more complex cases. The horizontal right axillary minithoracotomy (HRAMT) has shown even more superior cosmetic results when compared to conventional incisions by staying hidden under the resting arm, avoiding any interference in the development of breasts, as well as preventing the sectioning of muscles and glands and allowing for the treatment of restrictive VSDs^[12,13].

However, its use in patients under 15 kg was not recommended by some authors, due to the difficulty of direct cannulation of the aorta^[14]. Since October 2011, we have been employing this technique for correction of VSD, ASD and associated defects, extending its use to younger children (5 months), with direct cannulation of the vessels through the same incision in all patients.

Objective

To evaluate the effectiveness of the HRAMT approach in children and infants undergoing VSD and ASD closure, to assess the quality of treatment offered to the HRAMT group, comparing the perioperative data with the group subjected to the usual treatment by MS, including the need for blood transfusion.

To evaluate the aesthetic result of the thoracic incision in HRAMT and satisfaction of parents or guardians.

METHODS

Selection of individuals: This is a retrospective study with comparative analysis of HRAMT patients operated from October 2011 to August 2012 and paired patients operated by MS, for surgical repair of VSD, ASD and associated heart defects under CPB. All first 25 consecutive patients to whom the HRAMT approach was performed were included in the group named HRAMT. In order to balance the prognostic factors, the MS paired case control group patients were selected among the 247 patients undergoing treatment for the same types of heart defects from October 2011 to August 2012 by the same surgical team. For each individual of HRAMT group, a case control individual with the same heart defect, weight (for children assuming values ± 2 kg), age, and sex was selected. The defects covered in each group and their features are presented in the Table 1.

Surgical technique HRAMT Group

The patients were placed under mixed general anesthesia (inhalation plus intravenous) and continuous blood pressure monitoring was established by a left radial artery catheter placement. In addition, a double lumen catheter was placed either in the femoral vein or in the right subclavian vein. Pen marking of anterior and posterior axillary lines was done. The patient was placed in left semi-lateral position at 45° angle, the right arm was suspended at a right angle, in semi-flexion position, and a second line was traced from the scapular lower angle to the xiphoid appendage. The skin incision was performed in the middle portion of this line contained between the anterior and posterior axillary lines. This almost horizontal incision (3 to 5 cm) was done between the anterior and posterior axillary lines (bikini line in girls) and it may be at more cranial level in males (nipple level).

The skin and subcutaneous tissues were retracted toward higher and anterior direction, without muscle section (sparing technique). The third intercostal space was opened and a retractor was placed. The pericardium was opened at 2 cm anterior to the

phrenic nerve. The heart was exposed adequately by opening the pericardium, and placing suitable stay sutures. The thymus gland was preserved. The pericardial incision was extended toward the aorta and a stabilizing 5.0 polypropylene suture was placed in the apex of right atrial appendage, for better aortic exposure. A Cooley-Satinsky clamp was tested for partial aortic clamping at the cannulation site, just in case it became necessary.

After heparin infusion, two standard purse-string 5.0 or 6.0 polypropylene sutures were placed on the ascending aorta, and direct cannulation was performed with straight cannula, of suitable size for the patient's weight. Tapes were passed around the vena cavae. After placing standard purse-string sutures in superior vena cava and in the junction of the inferior vena cava with the right atrium, both vena cavae were cannulated and CPB was initiated.

After mild systemic cooling, the aorta was cross clamped and blood cardioplegic solution was infused in the aortic root. The right atrium was opened longitudinally and some stay sutures were placed at the right atrium edge, which were gently pulled toward the chest opening, exposing the ASD. Usually, tricuspid valve leaflet proximal detachment is required for better subaortic VSD exposure. The subaortic region was explored in all patients and any subaortic membrane was resected when present.

The VSD was closed with either polytetrafluoroethylene (PTFE) patch or autologous pericardial patch using 6.0 polypropylene running suture technique. The tricuspid valve was reattached. Saline solution was injected in the left ventricle to check for residual VSD. In case of ASD, it was closed with either PTFE or autologous pericardial patch, except for one patient in this series who had ASD amenable for direct closure with polypropylene 5.0 sutures.

Mitral valve repair was carried out in one patient, with chordal reduction and annuloplasty with multiple interrupted sutures plicature at different locations of the mitral annulus. In one patient with previous diagnosis of partial anomalous pulmonary vein connection to the superior vena cava associated with ASD, the superior vena cava cannulation was made at a higher level. In this case the right atrial appendage was used to enlarge the superior vena cava, after redirection of pulmonary veins flow to the left atrium with a PTFE patch used to close the ASD.

Table 1. Preoperative characteristics of groups.

	HRAMT (n=25)	MS (n=25)
Female	68%	64%
Age, median (percentile 25%-75%)	2 yr (2 yr - 5 yr)	3 yr (1.5 yr - 6 yr)
Weight, median (percentile 25%-75%)	13.5 kg (10.4 - 21)	13 kg (9.6 - 23.5)
Diagnoses	VSD: 4, VSD and ASD: 1 ASD: 18 ASD and PAPVR: 1 ASD and MR: 1	VSD: 4, VSD and ASD: 1 ASD: 18 ASD and PAPVR: 1 ASD and MR: 1

HRAMT: Horizontal right axillary minithoracotomy; MS: Median sternotomy; y: years-old; VSD: Ventricular septal defect, ASD: Atrial septal defect, PAPVR: Partial anomalous pulmonary veins return, MR: Mitral regurgitation

After deairing the heart, the aortic clamp was removed. CPB was interrupted after heartbeat resumption and the entire blood was reinfused through the aortic cannula. The cannulas were removed and protamine infusion was done. Hemostasis was carefully done and the pericardium edges were partially approximated with interrupted polyester sutures, leaving holes to drain any liquid into the pleural space. One drainage tube was installed in right pleural space. The intercostal space was closed with a single absorbable suture 2.0 approximating the two adjacent ribs. Bupivacain anesthetic was injected in adjacent intercostal spaces, in the anterior and posterior region of the chest incision. The previously spared muscles were approximated with interrupted sutures. Subcutaneous tissue and skin were sutured with absorbable filaments. Figure 1 shows the view of the operative field, with the position of the cannulas in aorta and vena cavae, the clamped aorta, and the VSD exposure through the right atriotomy.

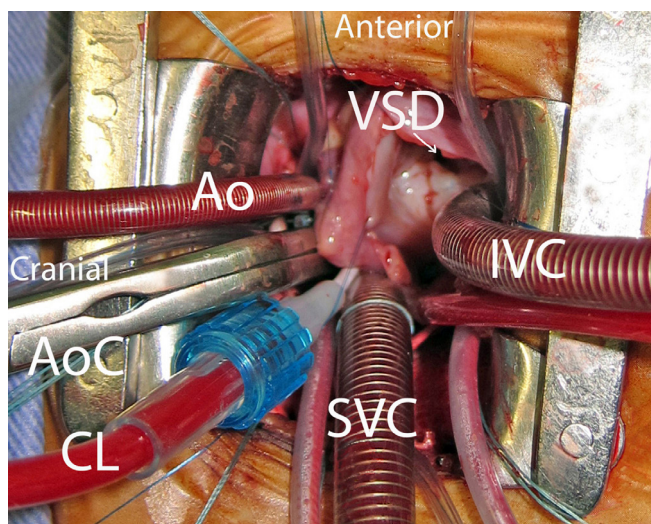


Fig. 1 - Operative surgical field aspect, with cannulas positioned in ascending aorta, superior and inferior vena cava. Aortic clamp and cardioplegic solution catheter positioned through the same incision. VSD approach through the right atriotomy. VSD: Ventricular septal defect, Ao: Aortic cannula, SVC: Superior vena cava cannula, IVC: Inferior vena cava cannula, AoC: Aortic clamp, CL: Cardioplegic line

MS Group

The patients were placed under mixed general anesthesia (inhalation plus intravenous), continuous blood pressure was monitored through a catheter placed in the left radial artery. A double lumen catheter was placed either in the femoral vein or in the right subclavian vein. The patient was placed in supine position with a cushion under the manubrium. A MS longitudinal skin incision was made, usually measuring from 4 to 6 cm in children. The sternum was opened and a retractor was placed. The pericardium was opened in the median line. The

pericardium edges were retracted with sutures. Thymus gland was preserved. Heparin solution was infused and two standard purse-string 5.0 or 6.0 polypropylene sutures were placed on the ascending aorta for cannulation, which was performed with straight cannula suitable for the patient's weight. Snaring tapes were passed around both vena cavae. After placing standard purse-string suture in the superior vena cava and in the junction of the inferior vena cava with the right atrium, bicaval cannulation was performed and CPB was initiated.

The aorta was cross-clamped and cardioplegic solution was infused in aortic root. The right atrium was opened. The atrial septum and the tricuspid valve were exposed by stay sutures placement at the right atriotomy edges, which were gently pulled toward the chest opening. In subaortic VSD cases, the leaflet of tricuspid valve was detached at its basal aspect for better exposure. The subaortic region was explored in all patients and any subaortic membrane was resected when present.

The VSD was closed with either PTFE or autologous pericardial patch of adequate size, using 6.0 polypropylene running suture techniques. After the tricuspid valve reattachment, saline solution was injected in left ventricle to test if VSD was completely closed. The ASD was closed with patch in all patients, when present. Mitral valvoplasty was carried out in one patient.

In one patient with previous diagnosis of partial anomalous pulmonary vein connection to the superior vena cava associated with ASD, the superior vena cava cannulation was made at a higher level. In this case, a PTFE patch was used to close the ASD, and to redirect the right superior pulmonary vein flow to the left atrium, followed by flap rotation of the right atrial appendage to enlarge the superior vena cava. After deairing the heart, the aortic clamp was released. CPB was discontinued after normal heartbeat resumed. All the patient's blood remaining in the membrane oxygenator and pump circuit was slowly reinfused through the aortic cannula. The aortic cannula was removed and protamine is administered. Hemostasis was carefully done and a mediastinal drainage tube was installed. The sternum was closed with steel wires. The subcutaneous tissues and the skin were sutured with absorbable sutures.

The same type of surgical equipment was used in both MS and HRAMT groups.

Control echocardiogram was carried out in all patients at the third or fourth postoperative day. The intraoperative use of red blood cells aimed at keeping the hematocrit above 20% during CPB in both groups was calculated using values from preoperative hematocrit, circulating volume for the patient's weight, and volume added to the CPB machine. The use of packed red blood cells during the postoperative period followed the institutional postoperative intensive care unit routine, based on levels of hematocrit and evaluation of the patient's clinical presentation (heart rate, blood pressure, use of vasoactive drugs, metabolic acidosis). In asymptomatic patients, transfusion was indicated when hemoglobin was less than 8 g/dL.

The aesthetic result of the incision was evaluated by medical staff and the satisfaction of parents or child guardians was verified by phone or e-mail contact, done at six to 16 months after the surgery. The design of the study was approved by the Research Ethics Committee of the institution where the surgeries were carried out and informed consent were signed by parents authorizing the retrospective study of medical records and postoperative aesthetic satisfaction assessment.

Variables analyzed

Operative duration; CPB and aortic clamping times; hematocrit and hemoglobin levels obtained at pre, peri, and post-operative periods; and the use of blood products. Additionally, mechanical ventilation, stay in the intensive care unit (ICU) and total hospital stay as well as mortality, complications, and aesthetics satisfaction were assessed.

Statistical analysis

All variables were analyzed using GraphPad Prism5, version 5.04. Continuous variables were expressed as mean and standard deviation. Categorical variable was expressed as the absolute number and proportion. Student's T-test for paired samples was used to compare continuous variables. The Chi-square test was used to compare categorical variables. A confidence level of < 0.05 was used.

RESULTS

The VSD size did not differ between groups, their diameter measuring 7.8, 11, 11, and 15 mm in the four patients of the axillary incision (HRAMT) group. Cannulation of the aorta and vena cavae was possible in all patients through the

main incision, preventing peripheral artery cannulation and its consequent risk. The correction of heart defects was possible even in infants, HRAMT being applicable in all patients to whom it was been proposed. The quality of treatment assessed by the analysis of variables shown in Table 2, which includes the perioperative data, was similar in both groups, except for the lesser use of blood products in the axillary group (6/25) than in the sternotomy incision group (13/25), with statistically significant difference ($P=0.04$). Six of the HRAMT patients and 11 patients in the MS group received intraoperative blood transfusion and two of the MS group patients received blood transfusion in the ICU. Use of special surgical equipment was not required in any patient. The postoperative surgical results were also similar in both groups; no residual VSD nor ASD was found in any patient. There was no mortality and the surgical complication incidence was similar in both groups, with mild to moderate pericardial effusion occurring in two cases in the HRAMT group and in one patient in MS group, without statistical difference, all three cases being solved with the use of oral anti-inflammatory.

Incision size ranged from 3 to 5 cm (median 4 cm) in the HRAMT group. The size of the incision was not recorded routinely in patient's medical files, which made the statistical comparison between the groups impossible in this retrospective study; however, our team sought to use small incisions even for the MS, usually ranging from 4 to 6 cm in children. The medical staff and the parents were satisfied with the results of HRAMT, considering it an excellent treatment option, due to the location of the incision, which is less exposed and has better aesthetics compared to the MS scar. Figures 2 and 3 show the immediate postoperative appearance of the incision in a patient from the HRAMT group. The incision is hidden under the arm.

Table 2. Perioperative clinical data - groups comparison.

Mean (±SD)	HRAMT (n=25)	MS (n=25)	P
ASD / VSD size (mm)	12.5 (±4.9) / 10.4 (±3.1)	14.8 (±6.5) / 6.2 (±1.1)	0.42 / 0.08
CPB time (min)	49 (±18)	54 (±32)	0.35
Aortic cross clamping time (min)	28 (±11)	34 (±17)	0.14
Preoperative Hematocrit (%)	36.8 (±3.4)	36.7 (±3.2)	0.83
Blood products use (n° of patients/ total)	6 / 25	13 / 25	0.04
Postoperative bleeding (ml)	108.9 (±64)	131.39 (±121.9)	0.25
Postoperative hematocrit (%) Day 1	31.5 (±5.7)	32.5 (±5.6)	0.92
MV time (hours)	6 (±4)	5 (±2)	0.53
ICU stay (days)	2 (±1)	2 (±1)	0.26
Hospital stay (days)	6 (±2)	6 (±2)	0.32

SD: Standard deviation; HRAMT: Horizontal right axillary minithoracotomy; MS: Median sternotomy; ASD/VSD: Atrial septal defect/Ventricular septal defect; CPB cardiopulmonary bypass, MV: Mechanical ventilation, ICU: Intensive care unit

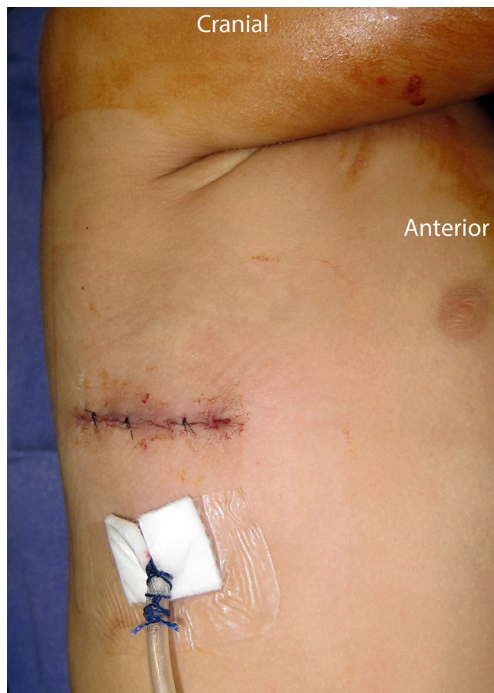

Fig. 2 - Incision aspect at the end of operation

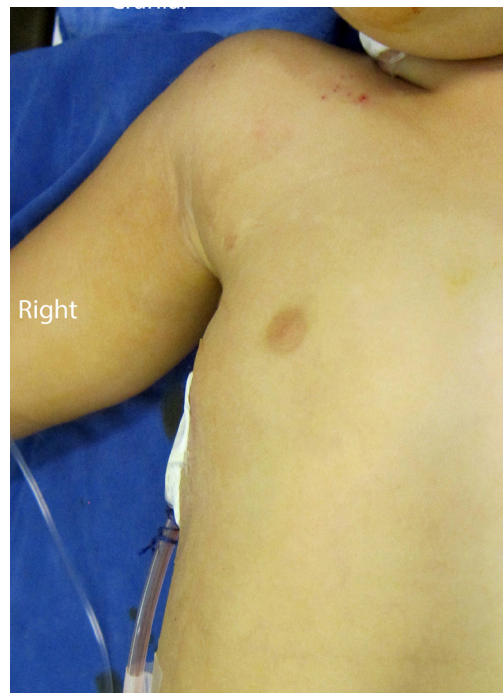

Fig. 3 - Aesthetic aspect of the thorax with hidden incision under the arm

DISCUSSION

The use of minimally invasive thoracic incisions in pediatric patients aims to get better aesthetic results along with the reduction of bleeding and postoperative complications, being employed for treatment of simple, such as the ductus arteriosus, or complex congenital heart defects^[15-17]. The right lateral inframammary thoracotomy is widely used for treating simple congenital heart defects such as ASD. However, this approach carries the risk of compromising breast development and pectoral muscle, especially if performed before complete breast development and inframammary groove definition^[14]. Therefore, it is not a good option for prepubescent girls due to high risk of breast distortion in the long-term follow-up^[7].

The axillary minithoracotomy has the advantage of staying away from the breast growth region and it does not damage the muscles associated with the arm movement. The horizontal axillary approach was reappraised by Schreiber et al.^[12] for ASD closure in children above 15 kg. Later, it was applied by Prêtre et al.^[13] for the treatment of restrictive VSDs, with 3.8 cm incisions in children and cannulation of femoral artery, but causing the prolongation of CPB and aortic cross-clamping time. Prêtre et al.^[13] work was criticized because they used femoral artery cannulation for CPB installation in children, which carries the additional risk, inherent to peripheral vessel cannulation.

The option of subxiphoid incision can be applied in smaller children, but it also requires femoral cannulation and the scar remains in the middle of the chest^[3,4]. In this study, we have expanded the use of HRAMT to younger children, with non-restrictive VSDs, employing exclusively direct cannulation of the aorta and cavae, thereby avoiding the risk of peripheral vascular lesions. This was possible by accessing the heart through the third intercostal space, with traction of the pericardium on multiple points, which allowed greater exposure of the aorta, increasing cannulation safety.

Access through the right atriotomy was used in all patients, with adequate exposure of the heart defect through the small remaining space after installation of all tubes and clamps. No patient required conversion to another type of approach or extension of the skin incision, although the initial skin incision could be extended in female patients, without reaching the breast growth area. There was no increase in CPB time, myocardial ischemia, mechanical ventilation time, ICU stay, nor hospital stay. In the group of patients covered by HRAMT, there was no need for femoral cannulation, avoiding future femoral stenosis and a new scar. In addition, HRAMT does not require any special type of equipment; therefore, it does not add costs to the surgical procedure.

It is worth mentioning that patients' weight in the HRAMT group ranged from 6.7 to 55 kg, and it was possible to perform the surgery in all of them. Actually, in our experience, surgery

was easier in smaller patients, due to shallower chest depth and greater skin and chest elasticity, as has already been observed by Wang et al.^[11], who performed axillary vertical minithoracotomy. The reduction in the blood products transfusion in the HRAMT group of patients can possibly be explained by greater blood loss caused by the sternotomy compared to the minithoracotomy. Preserving the integrity of the sternum bone is also important. There was no difference between the levels of hemoglobin in the pre, intra or postoperative, which reinforces the idea of reduced intraoperative blood loss in the HRAMT group.

The high experience level of the surgeon who performed all stages of surgery in this initial group of patients undergoing HRAMT can also be a contributing factor in the reduction of blood loss in the intra and postoperative periods. This finding calls for further randomized prospective study, although it is difficult to carry out this type of study in groups with varied diseases.

It is important to emphasize that opening the chest in the third intercostal space possibly increases the safety of HRAMT, since it provides good exposure of the ascending aorta, facilitating its cannulation, enabling a well conducted CPB, and giving cardioplegic solution, thereby resulting in effective myocardial protection. Appropriate experience and training should be a pre-requisite for the minimally invasive approach in the treatment of CHD^[18].

The incidence of complications was not higher in the HRAMT group; there was appropriate treatment of all heart defects, without residual communication, emphasizing the safety and effectiveness of this technique. The aesthetic result was considered excellent and parents were very pleased with the location of the incision, considering it more aesthetic than the MS because it stays in a less exposed location. In female, horizontal skin incision was performed at a lower level, compared to previous publications^[12,13] to enable the scar to stay hidden in the bikini line. Furthermore, it allows the extension of the skin incision toward the expected inframammary groove's upcoming location, although, in our experience this was not required in any patient.

Regarding the incision size, it is common in our team to use small incisions, even in the MS approach, but their size were not routinely recorded in patients' medical files, which made it impossible to statistically compare the incision sizes between groups.

Although our study was not randomized and has limitations, comparative study carried out with paired cases minimizes the bias of confounding variables. Possible limitations to the use of this HRAMT technique are the muscular apical VSDs or the presence of patent ductus arteriosus; however, the latter can be closed with transcatheter prosthesis in a hybrid procedure or prior to HRAMT procedure. So far, we have operated on 52 patients using HRAMT approach and we have had 15 cases of VSDs.

Some authors have emphasized that the challenges of surgery are the constant control the blood circulation and effective correction of heart defect, which is an even greater challenge when performed through a 5 cm incision^[19]. However, in our series of cases, it was possible to perform effective surgical treatment of heart disease with adequate blood flow control in all cases, when needed, even with smaller incisions, without great effort, especially in infants. Nonetheless, we would like to reinforce that these good results were achieved by experienced surgeons and trained staff.

CONCLUSION

HRAMT ("bikini line incision") has been effective, allowing the treatment of various heart defects, similar to that achieved by the standard sternotomy surgical approach, with reduced need for blood transfusion in this study. It has provided excellent cosmetic results, and it can be considered a safe alternative, even for infants.

Authors' roles & responsibilities

LFS	Main author
JPS	Coauthor
ALRT	survey data and spreadsheets, coauthor
SMF	Contact with relatives, coauthor
CMC	Survey Data, coauthor
RMC	Coauthor
WJG	Coauthor
CS	Coauthor

REFERENCES

1. Däbritz S, Sachweh J, Walter M, Messmer BJ. Closure of atrial septal defects via limited right anterolateral thoracotomy as a minimal invasive approach in female patients. *Eur J Cardiothorac Surg.* 1999;15(1):18-23.
2. Bichell DP, Geva T, Bacha EA, Mayer JE, Jonas RA, del Nido PJ. Minimal access approach for the repair of atrial septal defect: the initial 135 patients. *Ann Thorac Surg.* 2000;70(1):115-8.
3. Levinson ML, Fonger J. Minimally invasive atrial septal defect closure using the subxyphoid approach. *Heart Surg Forum.* 1998;1(1):49-53.
4. Barbero-Marcial M, Tanamati C, Jatene MB, Atik E, Jatene AD. Transxyphoid approach without median sternotomy for repair of atrial septal defect. *Ann Thorac Surg* 1998;65(3):771-4.
5. Metras D, Kreitmann B. Correction of cardiac defects through a right thoracotomy in children. *J Thorac Cardiovasc Surg.* 1999;117(5):1040-2.

6. Houyel L, Petit J, Planche C, Sousa-Uva M, Roussin R, Belli E, et al. Right postero-lateral thoracotomy for open heart surgery in infants and children. Indications and results. *Arch Mal Coeur Vaiss.* 1999;92(5):641-6.
7. Bleiziffer S, Schreiber C, Burgkart R, Regenfelder F, Kostolny M, Libera P, et al. The influence of right anterolateral thoracotomy in prepubescent female patients on late breast development and on the incidence of scoliosis. *J Thorac Cardiovasc Surg.* 2004;127(5):1474-80.
8. Cherup LL, Siewers RD, Futrell JW. Breast and pectoral muscle maldevelopment after anterolateral and posterolateral thoracotomies in children. *Ann Thorac Surg.* 1986;41(5):492-7.
9. Becker RM, Munro DD. Transaxillary minithoracotomy: the optimal approach for certain pulmonary and mediastinal lesions. *Ann Thorac Surg.* 1976;22(3):254-9.
10. Yang X, Wang D, Wu Q. Repair of atrial septal defect through a minimal right vertical infra-axillary thoracotomy in a beating heart. *Ann Thorac Surg.* 2001;71(6):2053-4.
11. Wang Q, Li Q, Zhang J, Wu Z, Zhou Q, Wang DJ. Ventricular septal defects closure using a minimal right vertical infraaxillary thoracotomy: seven-year experience in 274 patients. *Ann Thorac Surg.* 2010;89(2):552-5.
12. Schreiber C, Bleiziffer S, Lange R. Midaxillary lateral thoracotomy for closure of atrial septal defects in pre-pubescent female children: reappraisal of an "old technique." *Cardiol Young.* 2003;13(6):565-7.
13. Prêtre R, Kadner A, Dave H, Dodge-Khatami A, Bettex D, Berger F. Right axillary incision: a cosmetically superior approach to repair a wide range of congenital cardiac defects. *J Thorac Cardiovasc Surg.* 2005;130(2):277-81.
14. Schreiber C, Bleiziffer S, Kostolny M, Hörer J, Eicken A, Holper K, et al. Minimally invasive midaxillary muscle sparing thoracotomy for atrial septal defect closure in prepubescent patients. *Ann Thorac Surg.* 2005;80(2):673-6.
15. Santos JLV, Braile DM, Ardito RV, Zaiantchick M, Soares MJF, Rade W, et al. Ligation of patent ductus arteriosus: extrapleural technique. *Rev Bras Cir Cardiovasc.* 1992;7(1):14-21.
16. Salerno PR, Jatene MB, Santos MA, Ponce F, Bosísio IJB, Fontes VF, et al. Patent ductus arteriosus (PDA) closure with minithoracotomy: technique and results. *Rev Bras Cir Cardiovasc.* 2000;15(3):234-7.
17. Fonseca L, Silva JP, Franchi SM, Castro RM, Comparato DO, Baumgratz JF. Bidirectional Glenn procedure in the staged treatment of hypoplastic left heart syndrome: early and late results. *Rev Bras Cir Cardiovasc.* 2005;20(1):1-7.
18. Formigari R, Di Donato RM, Mazzera E, Carotti A, Rinelli G, Parisi F, et al. Minimally invasive or interventional repair of atrial septal defects in children: experience in 171 cases and comparison with conventional strategies. *J Am Coll Cardiol.* 2001;37(6):1707-12.
19. Prêtre R. Editorial Comment: The axillary incision to repair congenital heart defects. *Eur J Cardiothorac Surg.* 2013;43(1):141-2.