

Topoguided laser as treatment of ectasia after lasik

Laser topoguiado como tratamento de ectasia pós lasik

Marcio Martins de Melo Alves¹ <https://orcid.org/0000-0003-2900-928X>

Pedro Lukas do Rêgo Aquino² <https://orcid.org/0000-0002-1244-8641>

Henrique Brandt Krause³ <https://orcid.org/0000-0003-1503-3991>

Marina Alves Lucena³ <https://orcid.org/0000-0003-2212-9190>

Ermano de Melo Alves⁴ <https://orcid.org/0000-0001-5184-0905>

ABSTRACT

The laser in situ keratomileusis (LASIK) is the most widely used refractory surgical method in the world with excellent results, but this method is not without risks. Post-LASIK ectasia is a serious complication and is characterized by a progressive increase in curvature and thinning of the cornea, resulting in irregular astigmatism and decreasing visual acuity. Its incidence in the current literature is approximately 0.033%. The main treatment for this complication is the implantation of an intra-stromal ring with crosslinking. In this article, we describe a case of a 45-year-old woman who underwent successive attempts to treat post-LASIK ectasia, with bilateral intra-stromal ring implantation, with no success in the eyes. Excimer laser was used, made through photorefractive keratectomy (PRK) without cross-linking and the patient obtained significant improvement in vision and in quality of life.

Keywords: Ectasia/etiology; Keratomileusis, laser in situ/adverse effects; Refractive surgery; Excimer laser; Topographic PRK

RESUMO

O laser in situ keratomileusis (LASIK) é o método cirúrgico refrativo mais realizado no mundo com excelentes resultados, porém tal método não é isento de riscos. A ectasia pós LASIK é uma complicação grave e se caracteriza por um aumento progressivo da curvatura e afinamento da córnea, resultando em astigmatismo irregular e diminuição da acuidade visual. Sua incidência na literatura atual é de aproximadamente 0,033%. O principal tratamento dessa complicação é o implante de anel intra-estromal com cross-linking. Neste artigo descrevemos um caso de uma mulher de 45 anos submetida a sucessivas tentativas de tratamento de ectasia pós LASIK, com implante de anel intra-estromal bilateral, sem sucesso em um dos olhos. Foi feito o uso do excimer laser topoguiado através do photorefractive keratectomy (PRK) sem o cross-linking, que optamos por não realizar pela estabilidade há anos, pelo risco alto de haze e pela ablação apenas na lamela (que era espessa). A paciente obteve melhoras significativas da visão e da qualidade de vida. Mantemos o acompanhamento a cada seis meses desde então com a tomografia da córnea.

Descritores: Ectasia/etiologia; Ceratomileuse assistida por excimer laser in situ/efeitos adversos; Cirurgia refrativa; Excimer laser; PRK topoguiado

¹Medical School, Pernambuco School of Health, Recife, Brazil

²Medical School, Pernambuco University, Recife, Brazil

³Medical School, UniNassau Univesity Center, Recife, Brazil

⁴Oftalmax Eye Hospital, Recife, Brazil

The authors declare no conflict of interest

Received for publication 3/4/2020 - Accepted for publication 15/9/2020.

INTRODUCTION

The laser in situ keratomileusis (LASIK) is the refractive surgery method most performed in the world, it reports high satisfaction rate and excellent results, but it is not risk free. Post-LASIK ectasia is a serious complication and was first described in 1998 by Seiler et al;⁽¹⁾ it features a progressive increase in corneal thinning curvature, which results in irregular astigmatism and decreased visual acuity.⁽²⁻⁴⁾ High-grade myopia, changes in corneal topography and stromal bed thickness lesser than 250m (micron) are some of the risk factors for the development of this condition.⁽⁵⁻⁶⁾ The introduction of new concepts of risk assessment for ectasia, such as the percent tissue altered (PTA) described by Santhiago in 2015, have reduced the occurrence of this complication.⁽⁷⁾ The first studies have reported 0.66% (8) incidence of the disease, and this is much different from the usual number in the current literature (0.033%).⁽⁹⁾

The refractive error caused by ectasia after LASIK can be solved at first with glasses or contact lenses, however, more invasive therapies should be considered when it progresses. The introduction of intrastromal corneal ring and the use of crosslinking have offered surgeons more possibilities to manage patients in the last few years by avoiding cornea transplant, in many cases.⁽⁹⁻¹¹⁾ The topography-guided excimer laser has been gaining prominence in the medical literature as another form of treatment.⁽¹²⁻¹³⁾

Clinical case

Women, aged 45 years, was subjected to bilateral intrastromal corneal ring implant to treat post-LASIK ectasia, 15 years ago. The patient sought the service with complaint of intense visual impairment in the right eye (RE). Examination reported 20/200 RE visual acuity (VA), which did not improve with refraction. Left eye (LE) reached 20/40 visual acuity with the following correction: plane -3.00x90. The rings were removed from the RE in July 2017 and new segments were implanted with the aid of femtosecond laser LDV Z8, two months later. Cornea OCT was not available at the time for better planning. The assessed patient evolved to significant pain and corneal tunnel infiltrate, which required the two segments to be removed in November 2017. After insisting on a new attempt, a second reimplant was performed. At that moment, it was possible accessing a fundamental tool – images provided by cornea OCT (Avanti Optovue) –, which allowed the accurate measurement of flap thickness to be taken (Figure 1). It was clear that thick flap (measuring between 225 and 296 micron) was the reason for ectasia development, whereas probable

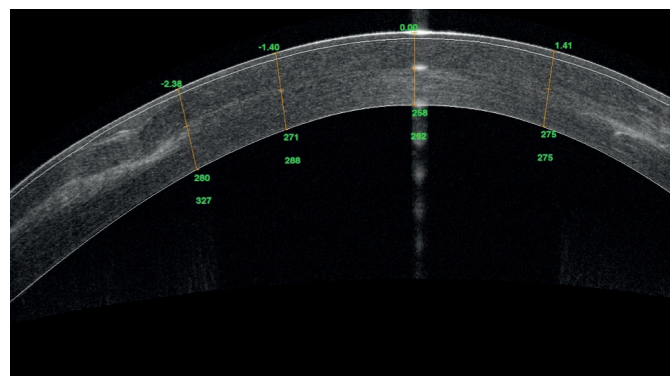


Figure 1: Preoperative Galilei Map

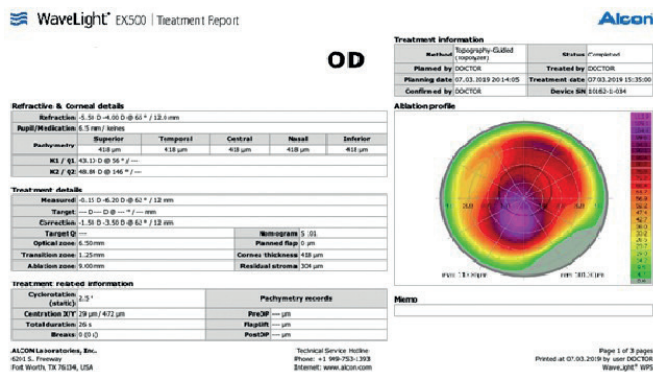


Figure 2: T-CAT, EX500 treatment

planning at that time was 160 micron (maximum). Unfortunately, old exams and the used microkeratome were not available, thus, it was not possible calculating the PTA of the reported case. It was planned to have the corneal tunnel to be under the flap. However, postoperative OCT showed that one of the segments was located between the flap and the residual stroma, without vision improvement and with subsequent extrusion. Cornea transplant was completely dismissed by the patient due to family history of post-transplant visual loss (her father). Option was made to perform a topography-guided photorefractive keratectomy (PRK) with mitomycin as alternative to keratoplasty. Assessed patient refraction was -5.50 -4.0x65 (degrees) with 20/60 corrected VA.

Surgical planning was based on Topolyzer Vario images, which were transported in flash drive to topography-guided excimer EX500 (Alcon Wavelight). The planned treatment (Figure 3) lied on high order correction of aberrations calculated by the software and on partial refraction correction (-1.50-3.50x62), at maximum 113.86 micron ablation, thus within the flap limit. Surgery was performed on March 12, 2019. Mitomycin was administered for one minute with therapeutic contact lens (CL) after photoablation. Videxa (every 6 hours), Acular LS (every 8 hours) and Optive (every 3 hours) were used for 8 days during the postoperative period. The CL was removed after 8 days and Flutinol started to be administered in decreasing scale for 20 days. The assessed patient reported evolution in her visual quality after seven months (September 2019) and presented stable final refraction, RE = -3.00-4.00x70 (20/30) and LE = plane -3.00x90 (20/40). Preoperative and postoperative Galilei images (Figure 4) showed a better topographic pattern, despite significant irregularities. The assessed patient reported improvement in visual quality after the prescription of glasses and returned to her professional activities. She expressed the desire to use gelatinous CL, later on. We kept strict follow-up every six months; all cornea propaedeutic remained stable in the case.

DISCUSSION

The reported case is singular because, after failing of the treatment with intrastromal corneal ring three times, we opted for topography-guided excimer laser in the flap, without performing cross-linking, which would be mandatory by many surgeons. In addition, significant topographic improvement was observed only after a prolonged follow-up period, when there was no evolution expectation by the patient or the doctors.

The first treatment option lied on using intrastromal corneal ring, since it is addressed as a good method in the literature,

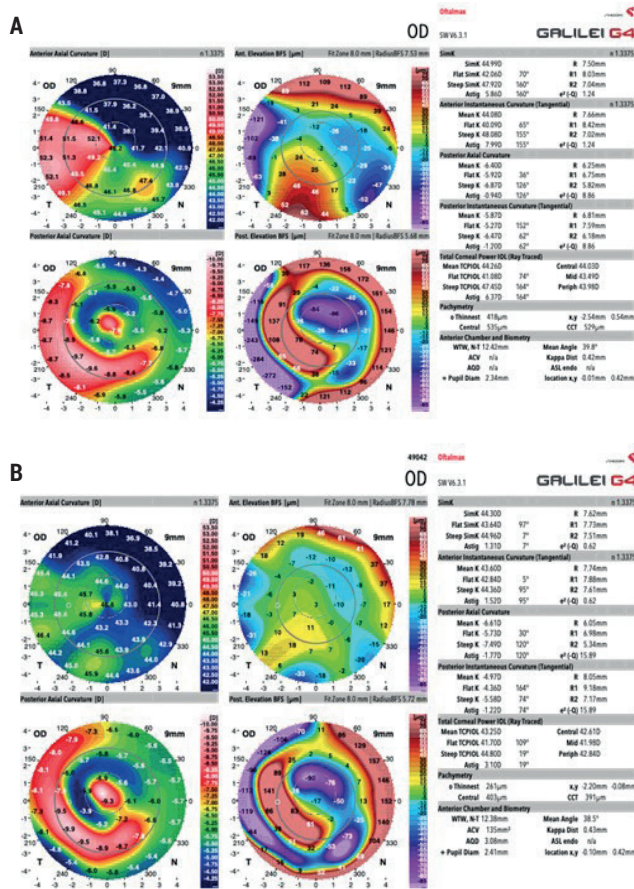


Figure 3: A) Preoperative Galilei Map. B) Postoperative Galilei Map.

given its ability to flatten the central cornea and to allow cornea transplant to be postponed or even avoided.^(12,14) However, there are many complications related to implant rings, such as extrusion (13.8%), asymmetric positioning (5%), migration (5%), conjunctivitis (2.7%), bacterial keratitis (2.7%) and hydrops (2.7%).^(12,14) It is important highlighting that, oftentimes, these complications are benign and reversible after orthosis removal. There was no vision improvement after such a therapeutic measure in the assessed case, even after three attempts. Topography-guided PRK was the chosen option, before the transplant was recommended (that was an unacceptable option for the patient). The patient agreed that, in case of failure, the next step would be the keratoplasty.

The topography-guided PRK aimed at regulating the cornea by smoothing the anterior surface and reducing high-order optical aberrations. Such technology can perform personalized planning based on corneal topography or tomography exams.⁽¹⁵⁾ Most researchers prefer the topography-guided PRK and cross-linking combination, as described by Kanellopoulos in the Athens protocol for keratoconus⁽¹⁶⁾ and in the Crete protocol by Kymionis et al.⁽¹⁷⁾ Cross-linking is a procedure whose riboflavin sensitization with ultraviolet A (UV-A) radiation induces crosslinks formation in the corneal stroma, which changes the corneal biomechanics and increases its tectonic force, as well as stops progressive thinning by increasing curvature and the consequent deterioration of vision.⁽¹⁸⁾ Cross-linking application was considered unnecessary in the assessed case, since there was no further progression of ectasia. It could be argued that a new ablation with excimer laser could worsen the condition; however, it is important recalling

that the place of laser application was the corneal flap, which no longer influences the biomechanical properties of the cornea. In addition, the cross-linking could induce excessive healing (haze) and visual reduction. It was a questionable decision but the case was dramatic and could lead to a transplant. It is known that cross-linking simultaneous to excimer laser can result in unpredictable effects on cornea curvature, in addition to possible changes in transparency. Such an option was left for a latter moment, since ectasia had been stabilized for years (natural cross linking) and residual stroma would not be reached.

Appropriate propaedeutic was fundamental to assess the current case and for therapeutic decision-making. OCT allowed reliably measuring flap thickness, which allowed keeping ablation within the flap limit. Looking back, it was possible carrying out PTK for de-epithelialization and using the epithelium as a "mask". OCT provided epithelial mapping and made it possible programming PTK at the desired thickness, which could further regulate the corneal surface. Unfortunately, this process did not occur, at the time, but it remains a suggestion for future cases.

It is important pointing out improvements in cornea tomography images between 3 and 6 months, together with improvements in visual acuity and reported satisfaction. The authors in the current study did not expected the reported evolution, which encouraged them to write an article in 2019 article⁽¹⁹⁾ about the significant improvement in visual acuity in patients subjected to topography-guided ablation based on the Contoura method (WaveLight EX 500, Alcon) to treatment of myopia and astigmatism in virgin eyes.

The current case report has some limitations because pre- and postoperative documentation could be more detailed and the patient's old clinical data was inaccessible. In addition, the assessed patient did not collaborate in some situations. The most significant aspects of the reported case were emphasized in order to draw attention to the chosen therapeutic option, which is much lesser invasive than cornea transplant, in similar cases, and does not depend on cross-linking.

REFERENCES

- Seiler T, Koufala K, Richter G. Iatrogenic keratectasia after laser in situ keratomileusis. *J Refract Surg.* 1998;14(3):312–7.
- Seiler T, Quurke AW. Iatrogenic keratectasia after LASIK in a case of forme fruste keratoconus. *J Cataract Refract Surg.* 1998;24(7):1007–9.
- Lafond G, Bazin R, Lajoie C. Bilateral severe keratoconus after laser in situ keratomileusis in a patient with forme fruste keratoconus. *J Cataract Refract Surg.* 2001;27(7):1115–8.
- Binder PS. Ectasia after laser in situ keratomileusis. *J Cataract Refract Surg.* 2003;29(12):2419–29.
- Giri P, Azar DT. Risk profiles of ectasia after keratorefractive surgery. *Curr Opin Ophthalmol.* 2017;28(4):337–42.
- Randleman JB, Russell B, Ward MA, Thompson KP, Stulting RD. Risk factors and prognosis for corneal ectasia after LASIK. *Ophthalmology.* 2003;110(2):267–75.
- Santhiago MR, Smadja D, Wilson SE, Krueger RR, Monteiro ML, Randleman JB. Role of percent tissue altered on ectasia after LASIK in eyes with suspicious topography. *J Refract Surg.* 2015;31(4):258–65.
- Pallikaris IG, Kymionis GD, Astyrakakis NI. Corneal ectasia induced by laser in situ keratomileusis. *J Cataract Refract Surg.* 2001;27(11):1796–802.
- Bohac M, Koncarevic M, Pasalic A, Bisevic A, Merlak M, Gabric N, et al. Incidence and clinical characteristics of post LASIK Ectasia: A review of over 30,000 LASIK cases. *Semin Ophthalmol.* 2018;33(7-8):869–77.

10. Tan BU, Purcell TL, Torres LF, Schanzlin DJ. New surgical approaches to the management of keratoconus and post-LASIK ectasia. *Trans Am Ophthalmol Soc.* 2006;104(12):212–20.
11. Rabinowitz YS. Intacs for keratoconus. *Curr Opin Ophthalmol.* 2007;18(4):279–83.
12. Miranda D, Sartori M, Francesconi C, Allemann N, Ferrara P, Campos M. Ferrara intrastromal corneal ring segments for severe keratoconus. *J Refract Surg.* 2003;19(6):645–53.
13. Jankov Ii MR, Jovanovic V, Delevic S, Coskunseven E. Corneal collagen cross-linking outcomes: review. *Open Ophthalmol J.* 2011;5:19–20.
14. Ertan A, Colin J. Intracorneal rings for keratoconus and keratectasia. *J Cataract Refract Surg.* 2007;33(7):1303–14.
15. Shetty R, Shroff R, Deshpande K, Gowda R, Lahane S, Jayadev C. A prospective study to compare visual outcomes between wavefront-optimized and topography-guided ablation profiles in contralateral eyes with myopia. *J Refract Surg.* 2017;33(1):6-10.
16. Kanellopoulos AJ. Comparison of sequential vs same-day simultaneous collagen cross-linking and topography-guided PRK for treatment of keratoconus. *J Refract Surg.* 2009;25(9):S812–8.
17. Kymionis GD, Grentzelos MA, Kankariya VP, Pallikaris IG. Combined transepithelial phototherapeutic keratectomy and corneal collagen crosslinking for ectatic disorders: cretan protocol. *J Cataract Refract Surg.* 2013;39(12):1939.
18. Wollensak G, Spoerl E, Seiler T. Riboflavin/ultraviolet-a-induced collagen crosslinking for the treatment of keratoconus. *Am J Ophthalmol.* 2003;135(5):620–7.
19. Durrie D, Stulting RD, Potvin R, Petznick A. More eyes with 20/10 distance visual acuity at 12 months versus 3 months in a topography-guided excimer laser trial: possible contributing factors. *J Cataract Refract Surg.* 2019;45(5):595–600.

Corresponding author:

Ermano Melo Alves

R. Benfica, 411 - Madalena, Recife – Pernambuco State/Brazil

CEP: 50720-001

E-mail: ermanomelo@uol.com.br