



Original Article

Evaluation of the quality of life after vertebroplasty to treat compressive osteoporotic fractures^{☆,☆☆}



Renato Faria Santos, Julio César Simas Ribeiro, Frederico Barra de Moraes*, André Luiz Passos Cardoso, Wilson Eloy Pimenta Junior, Murilo Tavares Daher

School of Medicine, Universidade Federal de Goiás (UFG), Goiânia, GO, Brazil

ARTICLE INFO

Article history:

Received 12 July 2013

Accepted 29 July 2013

Available online 29 August 2014

Keywords:

Vertebroplasty

Vertebral fractures

Quality of life

ABSTRACT

Objective: with increasing life expectancy around the world, fractures due to osteoporosis have become more common and the expenditure for treating them has also increased. The aim here was to evaluate the improvement in pain and quality of life among patients with compressive osteoporotic vertebral fractures undergoing vertebroplasty.

Methods: eighteen patients with 27 fractured vertebrae underwent vertebroplasty and were evaluated using the Oswestry 2.0 limitations questionnaire before the operation and 24 h and six months after the operation.

Results: there was a 75% improvement in pain and quality of life, going from a mean preoperative Oswestry of 40% to 10% 24 h after the operation and 9% six months after the operation ($p \leq 0.05$).

Conclusion: vertebroplasty is effective in managing compressive osteoporotic vertebral fractures, with improvement in pain and quality of life in the immediate postoperative period and over the medium term.

© 2014 Sociedade Brasileira de Ortopedia e Traumatologia. Published by Elsevier Editora Ltda. All rights reserved.

Avaliação da qualidade de vida após vertebroplastia em fraturas osteoporóticas compressivas

RESUMO

Objetivo: com o aumento da expectativa de vida no mundo, as fraturas por osteoporose se tornaram mais frequentes e aumentaram também os gastos no tratamento. Avaliar a melhoria na dor e na qualidade de vida de pacientes com fraturas vertebrais osteoporóticas compressivas submetidos a vertebroplastia.

Palavras-chave:

Vertebroplastia

Fraturas da coluna vertebral

Qualidade de vida

[☆] Please cite this article as: Santos RF, Ribeiro JCS, de Moraes FB, Cardoso ALP, Pimenta Junior WEP, Daher MT. Avaliação da qualidade de vida após vertebroplastia em fraturas osteoporóticas compressivas. Rev Bras Ortop. 2014;49(5):477-81.

^{☆☆} Work developed in the Department of Orthopedics and Traumatology, Hospital das Clínicas, Universidade Federal de Goiás, Goiânia, GO, Brazil.

* Corresponding author.

E-mail: frederico.barra@yahoo.com.br (F.B. de Moraes).

<http://dx.doi.org/10.1016/j.rboe.2014.08.008>

2255-4971/© 2014 Sociedade Brasileira de Ortopedia e Traumatologia. Published by Elsevier Editora Ltda. All rights reserved.

Métodos: foram submetidos à vertebroplastia 18 pacientes com 27 vértebras fraturadas e avaliados pelo questionário de limitações de Oswestry 2.0 de forma pré-operatória, 24 horas e seis meses no pós-operatório.

Resultados: melhoria de 75% da dor e na qualidade de vida, com Oswestry médio pré-operatório de 40%, em 24 horas de 10% e após seis meses da cirurgia, de 9%. ($p \leq 0,05$).

Conclusão: a vertebroplastia é efetiva no manejo das fraturas vertebrais osteoporóticas por compressão e melhora a dor e a qualidade de vida dos pacientes no pós-operatório imediato e médio prazo.

© 2014 Sociedade Brasileira de Ortopedia e Traumatologia. Publicado por Elsevier Editora Ltda. Todos os direitos reservados.

Introduction

Osteoporosis is defined as a disease characterized by low bone mass and deterioration of the bone tissue microarchitecture, which gives rise to increased fragility and consequently greater risk of developing fractures.¹ Dequeker et al.² conducted radiological studies on Egyptian mummies from approximately 2000 BC and demonstrated occurrences of vertebral fractures related to osteoporosis.

In the United States, US\$ 20 billion/year is spent on 1.3 million fractures attributed to osteoporosis, of which 500,000 are in the spine.³ The treatment for compressive osteoporotic vertebral fractures is generally clinical, with analgesia, early walking, vests and anti-reabsorptive medications for osteoporosis, with the aims of avoiding new fractures and diminishing pain and morbidity-mortality.

At the end of the 1990s, Jensen et al.⁴ and Deramond et al.⁵ indicated vertebroplasty for treating compressive osteoporotic vertebral fractures that had not improved through clinical treatment. This method was originally described by Galibert et al.⁶ in 1987, for treating vertebral tumors.

The objective of our study was to evaluate the improvement in pain and quality of life among patients with compressive osteoporotic vertebral fractures who underwent the technique of vertebroplasty following failure of conservative treatment.

Materials and methods

Eighteen patients with 27 vertebrae affected by compressive osteoporotic vertebral fractures were evaluated between February 2003 and September 2004.

The patients selected for vertebroplasty presented one or more compressive osteoporotic vertebral fractures, with significant pain even after 60 days of clinical treatment consisting of analgesics, non-steroid anti-inflammatory drugs (NSAIDs), opioids, calcitonin, alendronate, calcium, vitamin D and vests and belts for the spine.

Radiography and magnetic resonance imaging (MRI) (with T1/T2/STIR weighted signals) were performed before the operation and radiography and computed tomography (CT) were performed after the operation, on all the patients. MRI showed hypersignal in STIR images, with bone edema in the fractured and painful vertebral body.

All the patients underwent general anesthesia. The routes used for vertebroplasty were posterolateral and

transpedicular, using Jamshid needles and bone cement (polymethylmethacrylate), with 10% barium sulfate for intra-operative viewing by means of fluoroscopy. All the patients were followed up for at least six months after the procedure.

The exclusion criteria were the presence of a compromised medullary canal, infection, coagulation disorders, collapses greater than 90%, fractures of the posterior wall of the vertebra and old fractures that were negative on MRI.

To evaluate the improvement in pain and quality of life, the questionnaire of the Oswestry Disability Index (ODI) (version 2.0) was used during the week preceding the vertebroplasty and 24 h and six months after the procedure.

The statistical test used for comparing the ODI scores was the nonparametric Wilcoxon test, and results were taken to be significant when $p \leq 0.05$.

Results

Two men and 16 women were evaluated, with an age range from 50 to 79 years (mean of 64.5), who underwent vertebroplasty due to compressive osteoporotic vertebral fractures (Figs. 1 and 2).

A total of 27 vertebrae were affected: 18 lumbar (L1 to L4) and nine thoracic (T8 to T12). One patient was affected at four levels, one at three levels, four at two levels and 12 at one level. We observed two complications among the cases operated: one case of collapse of an adjacent level, three weeks after the vertebroplasty; and one case of extravasation of cement from L3, with left-side radicular compression. Decompression via a posterior route was performed, with arthrodesis from L2 to L4 using a pedunculated screw (Figs. 3 and 4).

In relation to pain and quality of life, the mean preoperative ODI score was 40% (± 4) and this changed to 10% (± 5) within the first 24 h, thus showing a 75% improvement of pain ($p \leq 0.05$). When the ODI score was measured six months later, it was observed that the pain-free condition had been maintained over the medium term, with a mean value of 9% (± 5) (Fig. 5).

Discussion

Osteoporosis is a chronic osteometabolic disease with multifactorial causes. It usually has an asymptomatic course, with progressive loss of resistance and bone quality, thereby leading to greater propensity to fractures. Improvement of social conditions, better access to healthcare and better

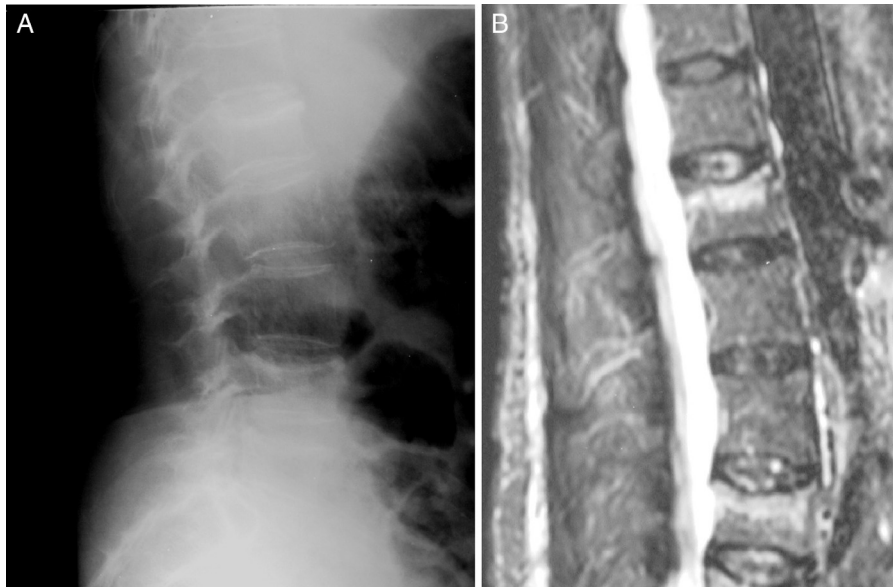


Fig. 1 – Before the operation: (A) lateral radiograph of the spine showing mild compressive fractures of the superior plateau of the L1 and L4 lumbar vertebrae; (B) sagittal MRI slice showing hypersignal in STIR sequence, in L1 and L4.

quality of life have provided increased longevity and consequently it has been observed worldwide that the population is aging. Osteoporosis has been described as the “epidemic of the 21st century”⁷ and is today considered to be a public health problem, although great advances in its prevention, diagnosis and treatment have been achieved since the 1960s.

Patients with compressive osteoporotic vertebral fractures often present complaints of back pain/lumbalgia, which may

be acute or chronic. Such complaints are seen among 85% of the patients with a radiological diagnosis of these fractures.⁸ The deformities due to the fractures are the most frequent cause of pain. The degree of kyphosis can be correlated with the patients’ quality of life (motor, mental and respiratory function), the mortality rate and the risk of new fractures.^{9,10}

This situation leads to sleep disorders, anxiety, depression, diminished social life and increased dependency on

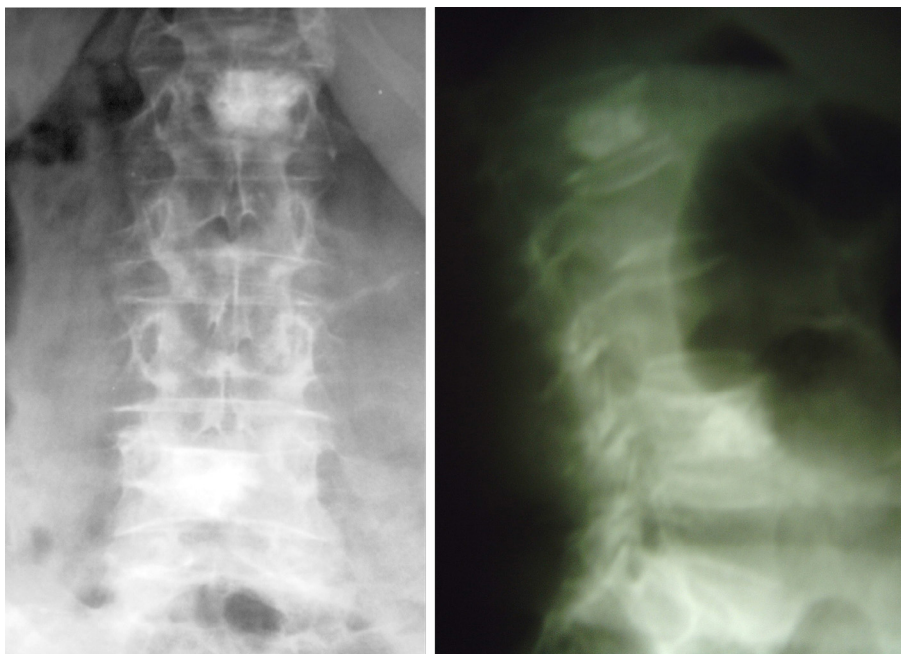


Fig. 2 – After the operation: anteroposterior and lateral radiographs of the lumbar spine showing bone cement in the vertebral bodies, well positioned in L1 and L4.

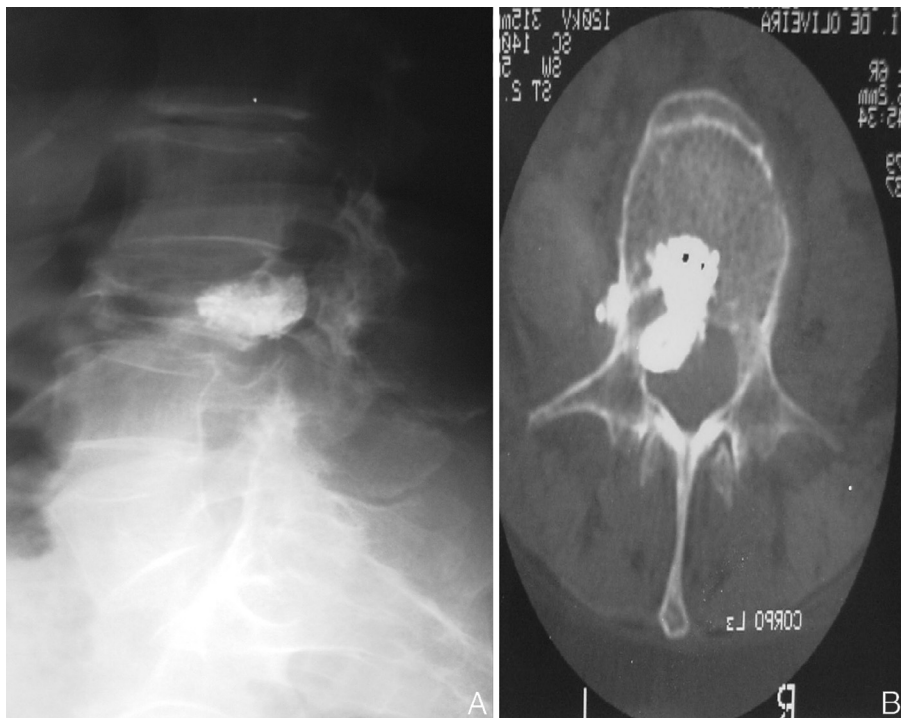


Fig. 3 – Complication: (A) lateral radiograph of the lumbar spine; (B) axial CT bone slice through lumbar vertebra. Both (A) and (B) show extravasation of the vertebroplasty cement to the medullary canal, with left-side radicular compression.

other people.¹⁰ The improvement in pain is significant with vertebroplasty.^{11,12} Gaitanis et al.¹³ observed an improvement in pain on a visual analog scale, from 8.5 before the operation to 2.5 after the operation, and a decrease in the limitations on daily activities assessed through the Oswestry questionnaire from 60% to 28%.

Our results confirm this immediate improvement in pain through vertebroplasty for treating compressive osteoporotic vertebral fractures, with a decrease in the Oswestry index from 40% to 10%. Moreover, this is a safe procedure when performed using the correct technique, with lower morbidity than in decompression surgery and arthrodesis.

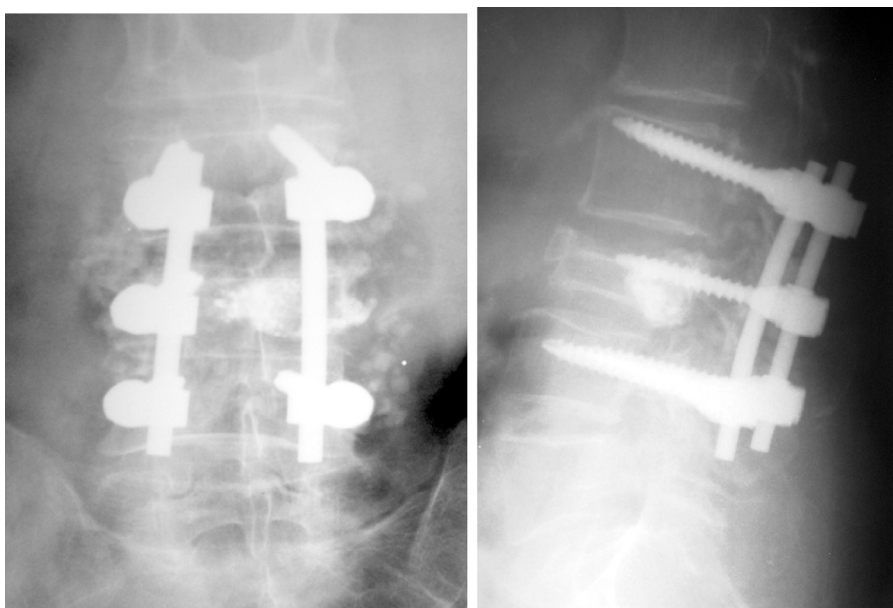


Fig. 4 – Anteroposterior and lateral radiographs of the lumbar spine showing decompression in L3 and posterolateral arthrodesis using pedunculated screws from L2 to L4, as a consequence of extravasation of the cement following vertebroplasty.

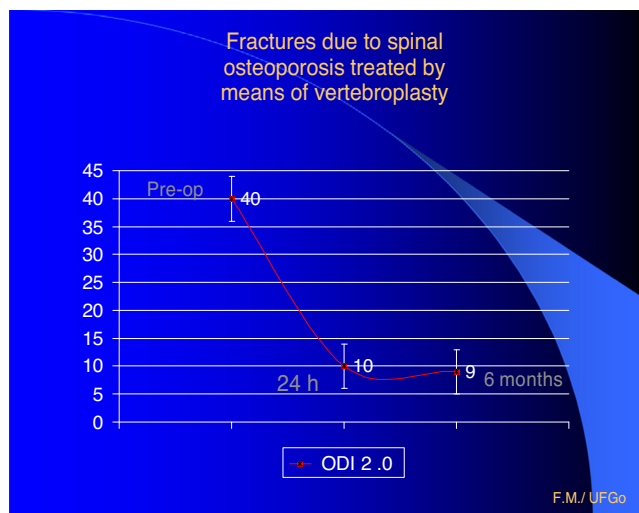


Fig. 5 – Decrease of the ODI score from 40% to 10%, 24 h after vertebroplasty, and its maintenance at 9%, six months after the procedure.

Conclusion

Vertebroplasty is effective in managing compressive osteoporotic vertebral fractures. It improves patients' pain and quality of life immediately after the operation and this is maintained over the medium term.

Conflicts of interest

The authors declare no conflicts of interest.

REFERENCES

1. World Health Organization. Guidelines for Preclinical Evaluation and Clinical Trials in Osteoporosis. In: Technical Report Series, 1998.

2. Dequeker J, Ortner DJ, Stix AI, Cheng XG, Brys P, Boonen S. Hip fracture and osteoporosis in a XIIth Dynasty female skeleton from Lisht, upper Egypt. *J Bone Miner Res.* 1997;12(6): 881-8.
3. Jensen ME, Evans AJ, Mathis JM, Kallmes DF, Cloft HJ, Dion JE. Percutaneous polymethylmethacrylate vertebroplasty in the treatment of osteoporotic vertebral body compression fractures: technical aspects. *Am J Neuroradiol.* 1997;18(10):1897-904.
4. Oliveira LG. Osteoporose: guia para diagnóstico, prevenção e tratamento. Rio de Janeiro: Revinter; 2002.
5. Deramond H, Depriester C, Galibert P, Le Gars D. Percutaneous vertebroplasty with polymethylmethacrylate. Technique, indications, and results. *Radiol Clin North Am.* 1998;36(3):533-46.
6. Galibert P, Deramond H, Rosat P, Le Gars D. Preliminary note on the treatment of vertebral angioma by percutaneous acrylic vertebroplasty. *Neurochirurgie.* 1987;33(2): 166-8.
7. NIH Consensus Development Panel on Osteoporosis Prevention, Diagnosis, and Therapy. Osteoporosis prevention, diagnosis, and therapy. *J Am Med Assoc.* 2001;285(6): 785-95.
8. Lyritis GP, Mayasis B, Tsakalagos N, Lambropoulos A, Gazi S, Karachalios T, et al. The natural history of the osteoporotic vertebral fracture. *Clin Rheumatol.* 1989;8 Suppl 2: 66-9.
9. Kado DM, Browner WS, Palermo L, Nevitt MC, Genant HK, Cummings SR. Vertebral fractures and mortality in older women: a prospective study. Study of Osteoporotic Fractures Research Group. *Arch Intern Med.* 1999;159(11):1215-20.
10. Lyles KW, Gold DT, Shipp KM, Pieper CF, Martinez S, Mulhausen PL. Association of osteoporotic vertebral compression fractures with impaired functional status. *Am J Med.* 1993;94(6):595-601.
11. Gangi A, Kastler BA, Dietemann JL. Percutaneous vertebroplasty guided by a combination of CT and fluoroscopy. *Am J Neuroradiol.* 1994;15(1):83-6.
12. Oliveira FM, Rodrigues AG, Bastos JOC Jr, Yamazato C, Kusabara R. Resultados clínicos da vertebroplastia em pacientes com fratura da coluna vertebral por osteoporose. *Coluna.* 2007;6(1):28-33.
13. Gaitanis IN, Hadjipavlou AG, Katonis PG, Tzermiadianos MN, Pasku DS, Patwardhan AG. Balloon kyphoplasty for the treatment of pathological vertebral compressive fractures. *Eur Spine J.* 2005;14(3):250-60.