


Comparative Analysis of the Effect of Two Therapeutic Ultrasound Protocols for Regeneration of a Critical Bone Defect*

Análise comparativa do efeito de dois protocolos de ultrassom terapêutico para regeneração de defeito ósseo crítico

Ana Flávia Calmon Daltro¹  Isabela Cerqueira Barreto² Renata dos Santos Almeida¹
Iorrana Índira dos Anjos Ribeiro¹ Aryon de Almeida Barbosa Junior³ Fabiana Paim Rosa⁴

¹Tissue Bioengineering and Biomaterials Laboratory, Universidade Federal da Bahia (UFBA), Salvador, BA, Brazil

²Department of Biofunction, Tissue Bioengineering and Biomaterials Laboratory, Universidade Federal da Bahia (UFBA), Salvador, BA, Brazil

³Tissue Bioengineering and Biomaterials Laboratory, Instituto de Patologia Geral e Cutânea (IPAC), Salvador, BA, Brazil

⁴Department of Biointeraction, Tissue Bioengineering and Biomaterials Laboratory, Universidade Federal da Bahia (UFBA), Salvador, BA, Brazil

Address for correspondence Ana Flávia Calmon Daltro, Instituto de Ciências da Saúde, Universidade Federal da Bahia (ICS-UFBA), Av. Reitor Miguel Calmon s/n, Vale do Canela, Salvador, Bahia 40.110-100, Brasil (e-mail: flavia_afcd@hotmail.com).

Rev Bras Ortop 2020;55(3):278–283.

Abstract

Objective To compare the effect of two therapeutic ultrasound protocols, with different times of exposure in the regeneration of critical bone defect.

Methods Forty-five male rats were distributed among three experimental groups: therapeutic ultrasound group 5 minutes (TUG 5); therapeutic ultrasound group 10 minutes (TUG 10); and control group (CG). In all groups, a critical bone defect of 8.5 mm diameter was made in the calvaria region. The protocol was initiated on the 1st postoperative day in TUGs 5 and 10, with therapeutic ultrasound at the frequency of 1.0 MHz, pulsed mode, five times a week, at periods of 15, 30, and 60 days.

Results Among the experimental groups, the highest volume of neoformation of osteoid matrix took place in the TUG 10 group followed by TUG 5, when compared with the CG group, in which the neoformation was restricted to the border region. The use of ultrasound promoted an increase in the thickness of the conjunctive matrix, proliferation of capillaries, alignment of the collagen fibers, reduction of edema and inflammatory process, being more significant in the 10-minutes time period.

Conclusion Therapeutic ultrasound stimulated the repair of a critical bone defect, and the longer exposure time promoted greater osteogenic stimulation.

Keywords

- ▶ bone and bones
- ▶ bone regeneration
- ▶ ultrasound
- ▶ ultrasound therapy

* Study conducted at Universidade Federal da Bahia (UFBA), Salvador, BA, Brazil.

Resumo

Objetivo Comparar o efeito de dois protocolos de ultrassom terapêutico com diferentes tempos de exposição para regeneração de defeito ósseo crítico.

Métodos Foram utilizados 45 ratos, machos, distribuídos em três grupos: grupo ultrassom terapêutico 5 minutos (GUS 5); grupo ultrassom terapêutico 10 minutos (GUS 10); e grupo controle (GC). Em todos os grupos, confeccionou-se um defeito ósseo crítico, com 8,5 mm de diâmetro, na região da calvária. O protocolo foi iniciado no 1º dia do pós-operatório, no GUS 5 e no GUS 10, com ultrassom terapêutico na frequência de 1,0 MHz, modo pulsado, 5 vezes por semana, nos períodos de 15, 30, e 60 dias.

Resultados Dentre os grupos experimentais, houve maior neoformação de matriz osteoide no GUS 10, seguido do GUS 5 quando comparados ao GC, no qual a neoformação foi restrita à região de borda. O uso do ultrassom promoveu aumento na espessura da matriz conjuntiva, proliferação de capilares, alinhamento das fibras colágenas, redução do edema e do processo inflamatório, tendo sido mais significativo no tempo de 10 minutos.

Conclusão O ultrassom terapêutico estimulou o reparo do defeito ósseo crítico, e o maior tempo de exposição promoveu maior estímulo osteogênico.

Palavras-chave

- ▶ osso e ossos
- ▶ regeneração óssea
- ▶ ultrassom
- ▶ terapia por ultrassom

Introduction

Bone tissue is characterized by its strength and hardness properties resulting from the combination of its organic and inorganic components. Despite these properties, this tissue can undergo extensive lesions, called critical bone defects, which compromise the structural integrity and physiology of bone repair.^{1,2}

Critical bone defects are caused by clinical conditions such as trauma and surgical procedures involving bone resection, which compromise the physiological process of bone regeneration, resulting in repair with formation of fibrous connective tissue.^{3,4} This tissue compromises the structure, function, and aesthetics,⁵ and it can lead to reduced quality of life of the individual, impacting the performance of their activities of daily life and work, with possible psychological and economic consequences. In this context, the physiotherapist, included in the multidisciplinary team, participates in the rehabilitation of individuals with this clinical condition.

During the rehabilitation process, therapeutic resources that emit vibrating mechanical waves may be employed to assist, repair, and stimulate osteogenesis.⁶ Among these resources, therapeutic ultrasound is included, and it has been used in clinical physical therapy practice for many years,⁷ consisting in an equipment that emits high-frequency waves of acoustic pressure, which, when interacting with biological tissues, promote micromechanical alterations. These changes generate biochemical events capable of accelerating fracture healing, stimulate repair of injured tissues such as bone and muscle tissue, inhibit inflammatory responses, and participate in the pain modulation process.⁷⁻¹⁰

The tissue response and efficacy of this therapy are closely related to the selected parameters before starting treatment. Thus, it is of fundamental importance to properly choose the frequency, intensity, current emission mode, application time and coupling medium indicated for each lesion.^{7,8}

The literature provides a variety of parameters, especially regarding the time of exposure to the ultrasonic wave, employed in the healing process of bone fractures.

Albertin¹¹ made a bone defect of 2.0 cm in rabbit radius and stimulated the region with ultrasonic wave for 5, 10, 20, and 40 minutes over a period of 15 days, noting that the longer times promoted greater stimulation to bone consolidation when compared with the time of 5 minutes. However, Pereira and others,² after inducing rat tibial fracture and stimulating the region with ultrasound for 10 minutes over a 13-day period, found that the protocol used did not promote a statistically significant difference between the group in which the therapy was performed and the control group, despite the increase of alkaline phosphatase and the diameter of the newly formed bone tissue.

Azuma et al¹² performed femoral fractures in rats and analyzed the effect of ultrasound for 20 minutes daily, at 8 and 24 days, concluding that ultrasound accelerated healing regardless of the treatment period, with improved torsional strength and increased new bone formation.

Given the diversity of protocols involved in bone injury rehabilitation, this study aims to compare the effect of two therapeutic ultrasound protocols with different exposure times for critical bone defect regeneration.

Materials and Methods

This experiment was approved by the Animal Use Ethics Committee, under protocol number 101/2016, and is in accordance with the precepts of the law n° 11,794, from October 08, 2008, and of the decree n° 6,899, July 15, 2009, and with the rules issued by the National Council for the Control of Animal Experimentation (CONCEA, in the Portuguese acronym).

The surgical procedures were performed in the central bioterium (animal facility) of our university, where the animals were allocated during the experiment.

Forty-five rats (*Rattus norvegicus*) of the *Wistar albinus* lineage were used. They were young adults, male, and weighed 350 to 400 grams.

The surgical technique was preceded in all animals by general anesthesia and sedation with intramuscular injection of ketamine hydrochloride (100 mg/kg) and xylazine hydrochloride (40 mg/kg), respectively, followed by trichotomy and asepsis in the calvaria region. Soon after, each animal was placed in prone position to perform the surgical procedure.

The methodology of the surgical procedure was similar to the work performed by Almeida et al.,⁴ Miguel et al.,¹³ Câmara-Pereira et al.,¹⁴ Ribeiro et al.,¹⁵ and Daltro et al.¹⁶ to produce an 8.5-mm diameter critical bone defect in the calvaria region (► **Figure 1**).

After making the critical bone defect, the animals were divided into 3 groups, with biological points of 15, 30, and 60 days, to compose the following categories: therapeutic ultrasound group 5 minutes (**TUG 5**), with application of mechanical waves emitted by the therapeutic ultrasound for 5 minutes on bone defect filled with blood clot; therapeutic ultrasound group 10 minutes (**TUG 10**), with application of mechanical waves emitted by the therapeutic ultrasound for 10 minutes on bone defect filled with blood clot; control group (**CG**), without application of mechanical waves emitted by therapeutic ultrasound. For the acquisition of macroscopic images, a Nikon D 3100 digital camera (Nikon Corp., Minatom, Tokyo, Japan) was used.

Therapeutic Ultrasound Application Protocol

Protocols were started on the 1st postoperative day. All animals in TUG 5 and TUG 10 were anesthetized and sedated to allow the implementation of the therapeutics, followed, when necessary, by trichotomy in the calvaria region. Subsequently, each animal was individually positioned, in prone position, on the procedure table, and water-soluble gel was applied to the calvaria region and the upper part of the water bag (► **Figure 2**).

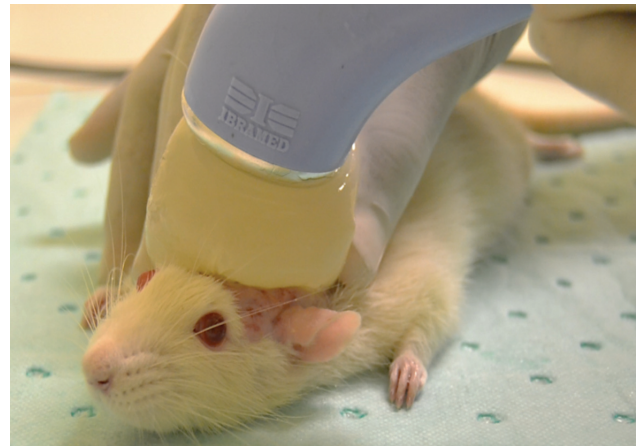

Fig. 2 Use of therapeutic ultrasound. Source: Author elaboration.

A low-intensity therapeutic ultrasound equipment was used, Sonopulse III model (Ibramed, Amparo, SP, Brazil), which had been previously calibrated by the manufacturer, with a 1 MHz frequency, pulsed mode, 0.2 W/cm² intensity, 50% duty cycle, pulse repetition frequency of 16 Hz and a 7 cm² effective radiating area (ERA) size. During the therapeutic ultrasound application, slow, circular and continuous movements with the transducer were performed for 5 or 10 minutes, depending on the experimental group. The protocol was performed 5 times a week, with a 48-hour break, at 15, 30, and 60-day biological points, which are equivalent, respectively, to 11, 22, and 44 ultrasound applications.

The protocols were established after adaptation of those used by Albertin,¹¹ Barreto,¹⁷ and Skau et al.,¹⁸ and a pilot test was conducted, as it was not found, in the available literature, a report of a therapeutic ultrasound therapy protocol with national equipment for regeneration of critical bone defect. After the therapeutic protocols were conducted, the animals were kept in a warm place to recover from anesthetic narcosis and then placed in individual cages.

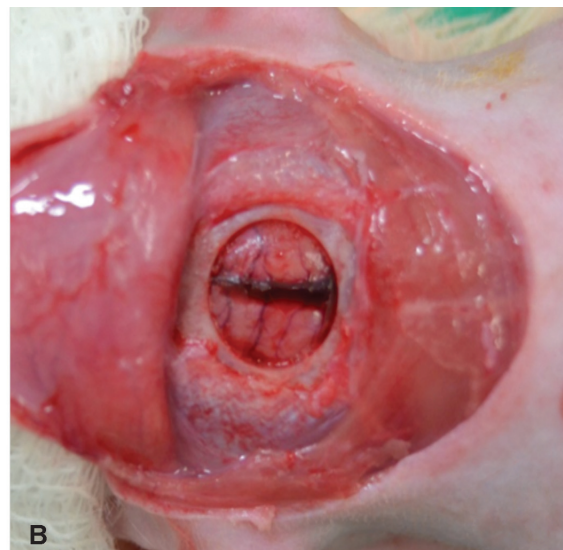
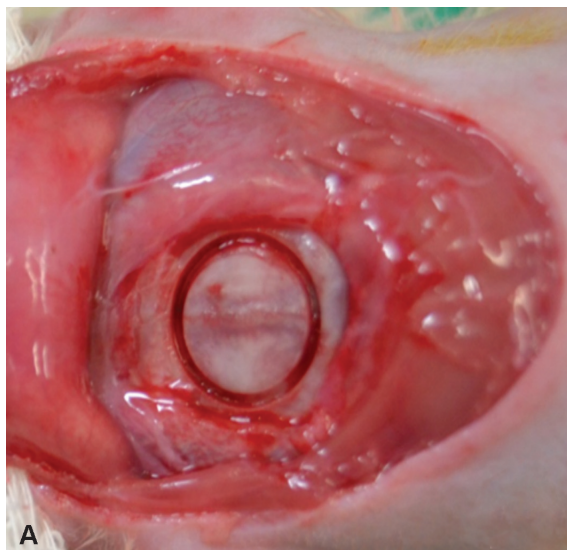


Fig. 1 Stage of the surgical procedure. Removal of subcutaneous tissue, muscles, and the marking of defect (A); bone fragment removal (B). Source: Author elaboration.

After the biological points of 15, 30, and 60 days, the animals were euthanized, the calvarias were removed and fixed in 10% buffered formalin and kept in plastic collectors for 72 hours. Then, the samples were cleaved at the lateral and inferior regions, followed by division into 2 portions, with approximately $\frac{2}{3}$ anterior and $\frac{1}{3}$ posterior.

The anterior portion was decalcified in a 7% ethylenediamine tetraacetic acid (EDTA) solution, for 7 days, with acid exchange every 24 hours. The calvaria were processed, embedded in paraffin, and serially cut into a microtome of 5.0 μ m. Routine hematoxylin and eosin (H&E) staining technique was used; to identify collagen proteins, we used picosirius red (PSR), and to identify the bone matrix, the Masson-Goldner trichrome kit was used. In the histological analysis, the Leica DM6 B digital vertical microscope (Leica Camera AG, Wetzlar, Germany) and the LAS V4.12 software (Leica Microsystems GmbH, Wetzlar, Germany) were used.

Results

Therapeutic Ultrasound Group 5

At 15 days, there was nonspecific reactive osteoid matrix formation (**►Figure 3A**), which increased at 30 days (**►Figure 3B**) and stabilized at 60 days (**►Figure 3C**), although restricted to bone edge regions, without restoration of the original bone volume. Active osteoblasts were present at all biological points. The extent of the defect was filled by loose connective tissue matrix, which was thinner in the central region of the defect at 15 days, and evolved for continuous thickening after 30 days; however, at 60 days, it was reduced (**►Figure 3C**). In all biological points, the presence of collagen

fibers was observed, which, at 30 days, presented in parallel (**►Figure 3B**) and diffuse proliferation of capillaries. At 15 days, the edema was moderate, and there was diffuse mononuclear inflammatory infiltrate, which decreased at 30 days and became inconspicuous at 60 days.

Therapeutic Ultrasound Group 10

At 15 days, the osteoid matrix neof ormation was restricted to the bone border (**►Figure 4A**), and it evolved, from 30 days on (**►Figure 4B**), to formation in centripetal direction (**►Figure 4C**), without restoration of the original bone volume. The osteoblasts remained present and active at all biological points, and the defect area was filled with loose connective tissue, which presented thickness increase in its whole extension. At all biological points, collagen fibers were organized in parallel (**►Figure 4B**), blood vessels proliferated, with angiogenesis stabilization at 60 days. Edema and mononuclear inflammatory infiltrate were reduced and became absent at 60 days.

Control Group

Reactive osteoid matrix neof ormation was restricted to the bone edge at all biological points (**►Figures 5 A, B and C**), without restoration of the original bone volume. Only at 15 days, there were active osteoblasts. Defect filling at all biological points occurred with loose connective tissue, which was thin at 15 days and even thinner at 60 days (**►Figure 5C**), with a thickness smaller than the bone edge. Few capillaries were found, and, at 30 and 60 days, stabilization of angiogenesis, mild edema and diffuse mononuclear inflammatory infiltrate that later became absent.

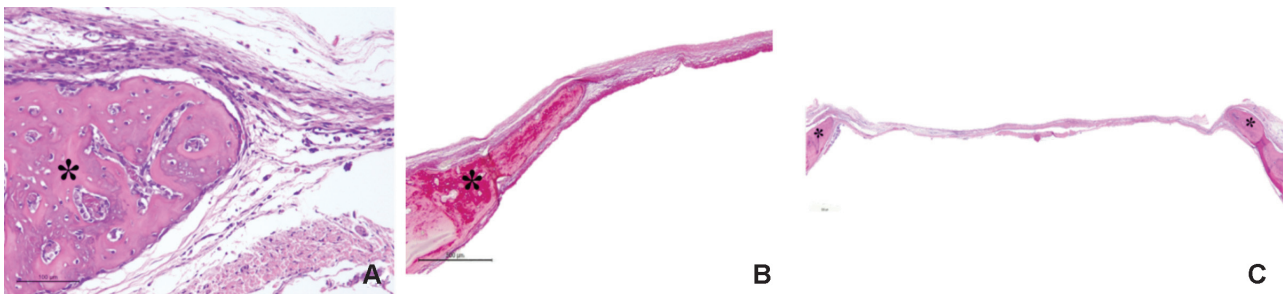


Fig. 3 Therapeutic ultrasound group 5 - Photomicrograph of critical bone defect with presence of osteoid matrix neof ormation (*). (A) At 15 days, presence of active osteoblasts and several capillary spaces (hematoxylin and eosin - H&E). (B) Alignment of collagen fibers at 30 days (picrosirius red). (C) Reduction of loose connective tissue thickening at 60 days (H&E). Fonte: Author elaboration.

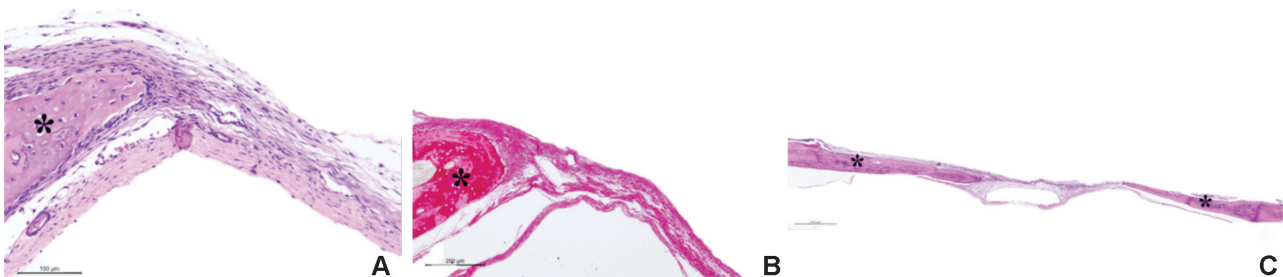


Fig. 4 Therapeutic ultrasound group 10 - Photomicrograph of critical bone defect with presence of osteoid matrix neof ormation (*). (A) Presence of active osteoblasts and various capillary spaces at 15 days (hematoxylin and eosin H&E). (B) 30 days parallel collagen fiber organization (picrosirius red). (C) Neof ormation of osteoid matrix in centripetal direction at 60 days (H&E). Fonte: Author elaboration.

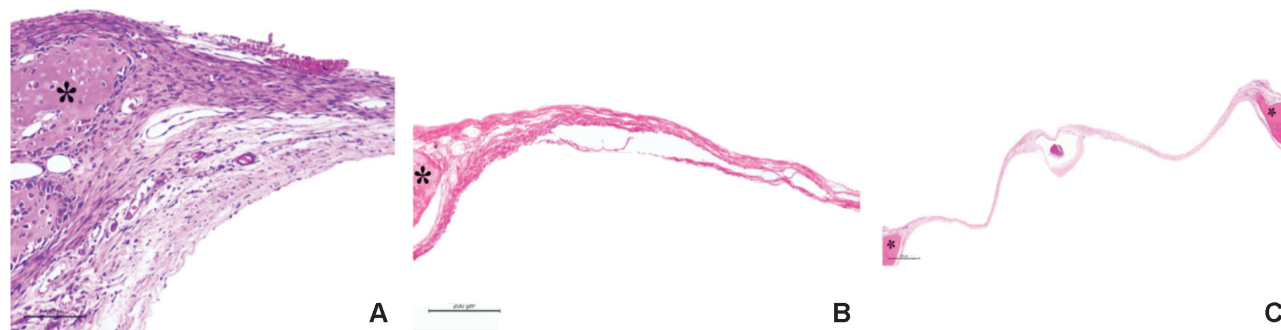


Fig. 5 Control group - Photomicrograph of critical bone defect with presence of osteoid matrix neof ormation (*). (A) Active osteoblasts and few capillary spaces at 15 days (hematoxylin and eosin – H&E). (B) Defect filling with thin loose connective tissue at 30 days (picosirius red). (C) Osteoid matrix neof ormation restricted to bone borders at 60 days (H&E). Fonte: Author elaboration.

Discussion

The absence of standardization of therapeutic ultrasound protocols to assist tissue regeneration may compromise the desired therapeutic outcome. Thus, it is necessary that the parameters to be used in the rehabilitation must be carefully chosen and unified.⁸ Among the various parameters is the time variable, poorly studied in the available scientific articles; thus, the need to define the treatment time to be used in each lesion is imperative.⁸ Therefore, the experiment aimed to compare the effect of two protocols of different therapeutic ultrasound treatment times on critical bone defect regeneration.

Early ultrasound wave therapy increased tissue repair, as the effect of ultrasound is mainly related to the time interval between the beginning of the lesion and the beginning of treatment. Thus, the earlier the therapy is started, the faster is the tissue recovery.^{2,19-21}

In the present study, the results obtained in the initial phase of the repair showed that the 5 and 10 minutes time were not sufficient to stimulate the increase of neof ormation in the critical bone defect.¹⁰ The evolution presented in the other biological points of TUG 5 may have been motivated by the prolongation of bone tissue stimulation, which is capable of promoting remodeling regions,¹⁰ as it was considered sufficient time to promote bone healing.¹⁸ However, some authors^{11,22,23} state that the ideal time to promote osteogenic stimulation and tissue organization starts after 10 minutes, suggesting that ultrasound has a dose-dependent effect considering the stimulation time.

The increase found in late TUG 10 biological points may have occurred as a result of the prolongation of stimulation in the mechanotransduction pathway, which enhances osteogenic stimulation and generates an increase in bone neof ormation rate.²⁴ However, in the CG, the neof ormation limitation was maintained²⁴ due to the absence of additional stimulus.

The cellular pattern found in the experimental groups in which ultrasound therapy was performed demonstrated that ultrasonic waves are capable of inducing and promoting the activation and differentiation of mesenchymal and osteoprogenitor cells.^{19,24} Although this mechanism of osteogenesis induction is not elucidated through this therapeutic resource,²⁴ ultrasound is known to stimulate mesenchymal cells to differentiate into osteoblasts, which, in turn, have their

cellular activity stimulated. In addition, ultrasound accelerates osteoblast differentiation and promotes increased bone mineralization.^{25,26}

The repair tissue that filled the defect in TUG 5 and TUG 10 was stimulated by ultrasonic waves that, in addition to promoting mesenchymal cell synthesis, stimulate collagen and fibroblasts, especially when used in the initial repair phase,^{10,19,20,24} as we proceeded in this experiment. After 2 minutes of ultrasonic wave emission, fibroblast growth is stimulated,²⁷ and collagen fiber alignment happens after 3 minutes.⁸

In this study, ultrasound showed promise in stimulating angiogenesis both at 5 and 10 minutes of therapy, when vascularization takes place from the initial repair phase,¹⁰ and became evident in the late phase, which favors the bone repair process.²⁵

There are two hypotheses to justify the angiogenesis promoted by ultrasound: the stimulus to increase interleukin-8 (IL-8) secretion and the production of vascular endothelial growth factor (VEGF). Ultrasonic waves are supposed to regulate IL-8 secretion by osteoblasts, as it is a cytokine responsible for inducing endothelial cell proliferation and migration, which leads to angiogenesis. The second hypothesis suggests that ultrasound stimulates the production of VEGF also by osteoblasts, a fundamental factor for angiogenesis, which acts in the regulation of mitosis and recruitment of endothelial cells.²⁸

The ultrasonic waves promoted the reduction of the inflammatory process after the times of 5 and 10 minutes of therapy, as they favored the acceleration of the inflammatory phase, resulting from the increase and release of mononuclear cells, as well as the histamine release, which promotes a rapid resolution of the inflammatory process.^{20,29} Due to this mechanism, ultrasound is able to eliminate the inflammatory process from the early stage of repair.²³

Despite having osteogenic effect and allowing its use in situations in which repair is critical, the therapeutic ultrasound did not show efficacy regarding the restoration of the original bone tissue volume and morphology in any of the protocols. Thus, in order to enhance the effects of ultrasonic waves, it is suggested a possible association of this therapeutic resource with a tridimensional scaffold, which will serve as a structural and mechanical support, enhance cell growth, and induce cell differentiation.^{16,30}

Conclusion

Therapeutic ultrasound stimulated the repair of the critical bone defect, and longer exposure promoted greater osteogenic stimulation.

Conflict of Interests

The authors have no conflict of interests to declare.

Acknowledgments

The authors would like to thank Coordenação de Aperfeiçoamento de Pessoal de Nível Superior (CAPES) for the support given to this work.

References

- Andia DC, Cerri PS, Spolidorio LC. Tecido ósseo: aspectos morfológicos e histofisiológicos. *Rev Odontol UNESP* 2006;35(02):191–198
- Pereira AJ, Amorim M, Catelani F, et al. The influence of low-intensity physiotherapeutic ultrasound on the initial stage of bone healing in rats: an experimental and simulation study. *J Ther Ultrasound* 2016;4(24):1–8
- Logeart-Avramoglou D, Anagnostou F, Bizios R, Petite H. Engineering bone: challenges and obstacles. *J Cell Mol Med* 2005;9(01):72–84
- Almeida RS, Ribeiro II, Silva MH, Rocha DN, Miguel FB, Rosa FP. Avaliação da fase inicial do reparo ósseo após a implantação de biomateriais. *Rev Ciênc Méd Biol* 2014;13(03):331–336
- Colnot C. Skeletal cell fate decisions within periosteum and bone marrow during bone regeneration. *J Bone Miner Res* 2009;24(02):274–282
- Lirani APR, Lazaretti-Castro M. Evidências da ação de agentes físicos sobre o metabolismo do tecido ósseo e seus potenciais usos clínicos. *Arq Bras Endocrinol Metabol* 2005;49(06):891–896
- Király M, Varga Z, Szanyó F, Kiss R, Hodosi K, Bender T. Effects of underwater ultrasound therapy on pain, inflammation, hand function and quality of life in patients with rheumatoid arthritis - a randomized controlled trial. *Braz J Phys Ther* 2017;21(03):199–205
- Farcic TS, Lima RM, Machado AF, et al. Aplicação do ultrassom terapêutico no reparo tecidual do sistema musculoesquelético. *Arq Bras Ciênc Saúde*. 2013;37(03):149–153
- Apolinario JC, Coleho WM, Louzada MJ. Análise da influência do ultrassom de baixa intensidade na região de reparo ósseo em ratos sob ausência de carga. *Fisioter Pesqui* 2011;18(03):257–259
- Fávaro-Pípi E, Feitosa SM, Ribeiro DA, et al. Comparative study of the effects of low-intensity pulsed ultrasound and low-level laser therapy on bone defects in tibias of rats. *Lasers Med Sci* 2010;25(05):727–732
- Albertin LM. Efeito do ultra-som sobre o reparo de falha óssea experimental: avaliação quantitativa e morfológica do parâmetro tempo de estimulação. *Rev Bras Fisioter*. 2004;8(01):1–6
- Azuma Y, Ito M, Harada Y, Takagi H, Ohta T, Jingushi S. Low-intensity pulsed ultrasound accelerates rat femoral fracture healing by acting on the various cellular reactions in the fracture callus. *J Bone Miner Res* 2001;16(04):671–680
- Miguel FB, Barbosa Júnior AdeA, de Paula FL, Barreto IC, Goissis G, Rosa FP. Regeneration of critical bone defects with anionic collagen matrix as scaffolds. *J Mater Sci Mater Med* 2013;24(11):2567–2575
- Câmara-Pereira ES, Rolim AEH, Reale R, et al. Analysis of bone repair tissue after implantation of biomaterials and application of vibratory waves. *Mater Sci Forum* 2014;775–776:9–12
- Ribeiro II, Almeida RS, Rocha DN, Silva MH, Miguel FB, Rosa FP. Biocerâmicas e polímero para a regeneração de defeitos ósseos críticos. *Rev Ciênc Méd Biol* 2014;13(03):2298–2302
- Daltro AF, Barreto IC, Rosa FP. Análise do efeito da plataforma vibratória na regeneração de defeito ósseo crítico. *Rev Ciênc Méd Biol* 2016;15(03):323–329
- Barreto AA. Efeito do ultrassom terapêutico sobre o crescimento ósseo das epífises, distal do fêmur e proximal da tibia em *rattus norvegicus*. [tese]. Botucatu: Faculdade de Medicina de Botucatu, Universidade Estadual Júlio de Mesquita Filho; 2009
- Skau JR, Rodrigues B, Rosa FO, Araujo RC, Fontinele RG, Souza RR. Histomorphometrical analysis on the effects of two therapeutic ultrasound intensities on fracture healing in aged rats. *Fisioter Mov* 2014;27(02):173–179
- Acar AH, Yolcu Ü, Altındiş S, Gül M, Alan H, Malkoç S. Bone regeneration by low-level laser therapy and low-intensity pulsed ultrasound therapy in the rabbit calvarium. *Arch Oral Biol* 2016;61(01):60–65
- Silva JM, Carvalho JP, Moura-Junior MJ, et al. Estudo da ação do ultrassom terapêutico em modelo experimental de tendinite em ratos Wistar. *Com Sci Saude* 2010;9(04):625–632
- Pereira AJ, Teixeira RC, Oliveira AJ, Pontes RW, Barros RS, Negrão JN. Efeito do ultrassom terapêutico de baixa intensidade em fratura induzida em tibia de ratos. *Acta Ortop Bras* 2013;21(01):18–22
- Silveira DS, Pippi NL, Costa FS, et al. O ultra-som terapêutico de 1MHz, na dose de 0,5 Wcm², sobre o tecido ósseo de cães avaliado por densitometria óptica em imagens radiográficas. *Cienc Rural* 2008;38(08):2225–2231
- Oliveira P, Sperandio E, Fernandes KR, Pastor FAC, Nonaka KO, Renno ACM. Comparação dos efeitos do laser de baixa potência e do ultrassom de baixa intensidade no processo de reparo ósseo em tibia de rato. *Rev Bras Fisioter* 2011;15(03):200–205
- Jung YJ, Kim R, Ham HJ, et al. Focused low-intensity pulsed ultrasound enhances bone regeneration in rat calvarial bone defect through enhancement of cell proliferation. *Ultrasound Med Biol* 2015;41(04):999–1007
- Zhu H, Cai X, Lin T, Shi Z, Yan S. Low-intensity pulsed ultrasound enhances bone repair in a rabbit model of steroid-associated osteonecrosis. *Clin Orthop Relat Res* 2015;473(05):1830–1839
- Macione J, Long D, Nesbitt S, et al. Stimulation of osteoblast differentiation with guided ultrasound waves. *J Ther Ultrasound* 2015;3(12):12
- Oliveira PD, Oliveira DA, Martinago CC, Frederico RC, Soares CP, Oliveira RF. Efeito da terapia ultrassônica de baixa intensidade em cultura celular de fibroblastos. *Fisioter Pesqui* 2015;22(02):112–118
- Padilla F, Puts R, Vico L, Raum K. Stimulation of bone repair with ultrasound: a review of the possible mechanic effects. *Ultrasonics* 2014;54(05):1125–1145
- Pereira T, Ferreira BS, Alves WS, Filho AL. Ação do ultrassom terapêutico e laser de baixa intensidade na regeneração nervosa em *rattus norvegicus*. *Con Sci Saude*. 2014;13(01):22–30
- Akilal N, Lemaire F, Bercu NB, et al. Cowries derived aragonite as raw biomaterials for bone regenerative medicine. *Mater Sci Eng C* 2019;94(01):894–900