



# Prevalence of Absence of Function of the Flexor Digitorum Superficialis Muscle Tendons in the Fourth and Fifth Fingers of the Hand in the Brazilian Population\*

## *Prevalência de ausência de função dos tendões do músculo flexor superficial do quarto e quinto dedos da mão na população brasileira*

Bruno Macêdo Oliveira<sup>1</sup> Carlos Henrique Fernandes<sup>1</sup> Luis Renato Nakachima<sup>1</sup>  
 João Baptista Gomes dos Santos<sup>1</sup> Celso Kiyoshi Hirakawa<sup>1</sup> Flavio Faloppa<sup>1</sup>

<sup>1</sup>Orthopedics and Traumatology Department, Universidade Federal de São Paulo, São Paulo, SP, Brazil

Address for correspondence Bruno Macêdo Oliveira, MD, Departamento de Ortopedia e Traumatologia, Universidade Federal de São Paulo, Rua Borges Lagoa, 786, São Paulo, SP, Brazil (e-mail: brunomacedooliveira@gmail.com).

Rev Bras Ortop 2020;55(4):448–454.

### Abstract

**Objectives** To evaluate the prevalence of absence of flexor digitorum superficialis muscle tendons function of the fourth and fifth fingers of the hand in the Brazilian population

**Methods** Prospective study performed at the orthopedics and traumatology department of a university hospital. The study was conducted from October 2017 to April 2018. The sample consisted of volunteers with no history of upper limb trauma, surgery or any other condition. This study included both male and female individuals over 18 years old. The flexor digitorum superficialis muscle tendons of the fourth and fifth fingers were evaluated through clinical tests by three independent examiners. The data were analyzed using GraphPad Prism 5.0 (GraphPad Software, San Diego, CA, USA).

**Results** A total of 2,016 hands from 1,008 volunteers were analyzed. The prevalence of absence of flexor digitorum superficialis muscle tendon function of the fourth finger was 0.56% at the right hand and 0.99% at the left hand. At the right hand, this prevalence was higher in females compared to males ( $p = 0.0328$ ). No difference between genders was noted in the left hand ( $p = 0.7562$ ). The prevalence of absence of flexor digitorum superficialis muscle tendon function of the fifth finger was 34.53% in the right hand and 30.06% in the left hand. This prevalence was higher in females compared to males, both at the right hand ( $p = 0.0001$ ) and the left hand ( $p = 0.0003$ ).

**Conclusion** Even though there are studies performed separately in different ethnic groups, there were no data in the literature regarding the prevalence of absence of flexor digitorum superficialis muscle tendons function of the fourth and fifth fingers of the hand in a multiethnic population such as the Brazilian one.

### Keywords

- ▶ fingers
- ▶ hand congenital deformities
- ▶ tendons
- ▶ nervous compression syndromes
- ▶ prospective studies

\* Work developed at the hand and upper limb surgery group, at the orthopedics and traumatology department of Universidade Federal de São Paulo, São Paulo, SP, Brazil.

## Resumo

**Objetivos** Avaliar a prevalência da ausência de função dos tendões do músculo flexor superficial do quarto e quinto dedos em uma população brasileira.

**Métodos** Estudo prospectivo foi realizado no departamento de ortopedia e traumatologia de um hospital universitário. O estudo foi desenvolvido no período de outubro de 2017 a abril 2018. A amostra foi formada por voluntários sem histórico de trauma, cirurgia ou qualquer afecção dos membros superiores. Foram incluídos neste estudo indivíduos de ambos os gêneros com idade igual ou superior a 18 anos. A avaliação da função do tendão do músculo flexor superficial do quarto e quinto dedos foi realizada por meio de testes clínicos por três examinadores independentes. Para análise dos dados foi utilizado o programa *GraphPad Prism 5.0* (GraphPad Software, San Diego, CA, EUA).

**Resultados** Foram analisados 1.008 voluntários totalizando 2.016 mãos. A prevalência da ausência de função do tendão do músculo flexor superficial do quarto dedo foi de 0,56% na mão direita e 0,99% na mão esquerda. Em relação ao gênero, foi verificado na mão direita uma maior prevalência da ausência de função do flexor superficial do quarto dedo no gênero feminino quando comparado ao masculino ( $p = 0,0328$ ). Na mão esquerda não foi observada diferença entre os gêneros ( $p = 0,7562$ ). A ausência de função do músculo flexor superficial no quinto dedo foi de 34,53% na mão direita e de 30,06% na mão esquerda. Quando analisamos o quinto dedo em relação aos gêneros, foi verificado que a prevalência da ausência de função do músculo flexor superficial foi mais frequente no gênero feminino que no masculino, tanto na mão direita ( $p = 0,0001$ ) como na mão esquerda ( $p = 0,0003$ ).

**Conclusão** Apesar de haver estudos realizados separadamente em diversas etnias, não havia na literatura dados referentes à prevalência da ausência de função do músculo flexor superficial do quarto e quinto dedos da mão em uma população miscigenada como a brasileira.

## Palavras-chave

- ▶ dedos
- ▶ deformidades congênitas da mão
- ▶ tendões
- ▶ síndromes de compressão nervosa
- ▶ estudos prospectivos

## Introduction

The flexor digitorum superficialis (FDS) muscle is the largest forearm muscle and the only forearm muscle at the intermediate layer.<sup>1</sup> The FDS muscle has two origins, a humeral-ulnar and a radial origin. It has four independent tendons running to the long fingers after crossing the carpal tunnel.<sup>2,3</sup>

The system consisting of the FDS muscle and its tendons flexes multiple joints, such as the wrist, intercarpal, carpo-metacarpal, metacarpophalangeal, and proximal interphalangeal joints.<sup>3-5</sup>

The literature describes duplicate and accessory muscles, as well as abnormal muscles at the upper limbs. The prevalence of anatomical variations in the FDS muscle and its tendons varies in different populations.<sup>5-9</sup>

The FDS is one of the muscles with the higher number of anatomical variations in the human musculoskeletal system. Its functional alterations may be due to morphology, origin, attachment and possible interconnections. In the general population, the absence of an exclusive FDS tendon function for the fifth finger is the most common variation.<sup>3,4</sup>

The absence of FDS tendon function has not attracted orthopedic attention because it does not affect hand strength

and dexterity in daily activities.<sup>1,3</sup> However, it may lead to misdiagnosis during the clinical examination to assess superficial flexor tendon injuries of the fourth and fifth fingers after trauma.<sup>5</sup> The surgeon must be aware of these variations to better interpret physical examination findings and indicate surgical repair procedures.<sup>10-12</sup>

The literature reports that the prevalence of absence of fifth finger FDS function ranges from 0% in the Indian population to 30.77% in the British population.<sup>3-5</sup> Such variations may be justified by ethnic, geographical, and methodological differences. To date, the prevalence of absence of function of FDS tendons of the fourth and fifth finger in Brazil has not been reported. In this context, the present study aimed to evaluate the prevalence of absence of function of the FDS tendons of the fourth and fifth finger in a multiethnic Brazilian population.

## Materials and Methods

This is a prospective, cross-sectional and observational study conducted at the department of orthopedics and traumatology of a university hospital. The study was conducted from October 2017 to April 2018. The sample consisted of patients' caregivers, who then became volunteer subjects. These individuals

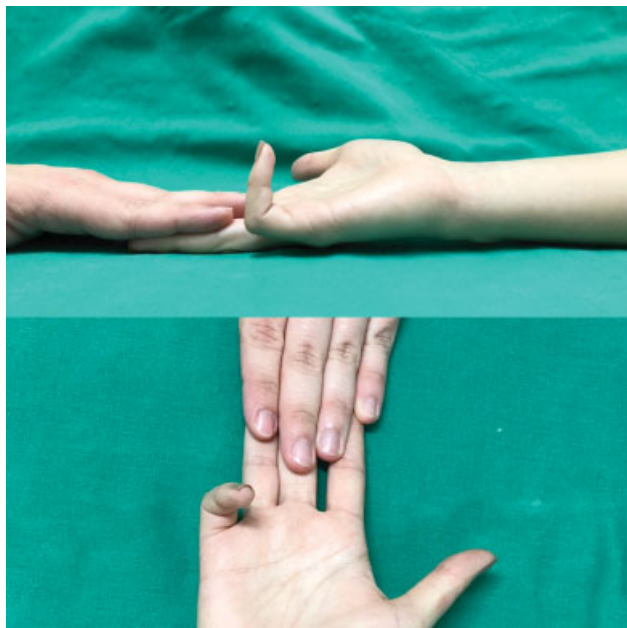
had no history of upper limb trauma, surgery or any condition. Subjects were both male and female over 18 years old.

The project approved by Plataforma Brasil and the ethics committee under number 2481991, according to the Brazilian Health Council Resolution 466/96 recommendations for research on human beings. The researcher in charge invited volunteers to participate in this study and then explained the procedures to them. An informed consent form (ICF) was provided and signed by the subjects who complied with the research terms.

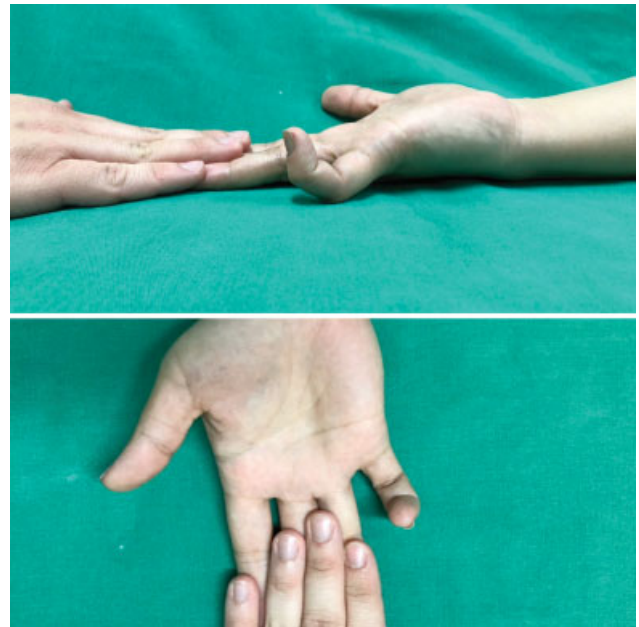
The identification of the superficial flexor function of each finger was performed by two clinical tests performed on both hands by three different examiners. Each examiner performed the tests described below separately and on different volunteers. Therefore, one same examiner did not evaluate all volunteers, decreasing the risk of information bias.

For the fifth finger, all fingers were in extension, except for the fifth finger. The wrist was kept in complete supination and neutral extension. The volunteer was asked to flex the fifth finger. The presence of FDS function was established by flexion of the proximal interphalangeal (PIP) joint without flexion of the distal interphalangeal (DIP) joint (► **Figure 1**). The absence of FDS function was established when the PIP joint was not flexed or when it happened only along DIP joint flexion (► **Figure 2**). The test was also considered negative when the fifth finger PIP flexion occurred only in conjunction with fourth finger PIP flexion. Thus, there was no individual FDS function for the fifth finger.

For the fourth finger, all fingers were in extension, except for the fourth finger. The wrist was kept in complete supination and neutral extension. The volunteer was asked to flex the fourth finger. PIP joint flexion without DIP joint flexion indicated the presence of the FDS function (► **Figure 3**). If PIP joint flexion did not occur or PIP joint flexion occurred only



**Fig. 1** Clinical test to assess the presence of flexor digitorum superficialis muscle tendon function for the fifth finger. Isolated proximal interphalangeal joint flexion confirms its function.

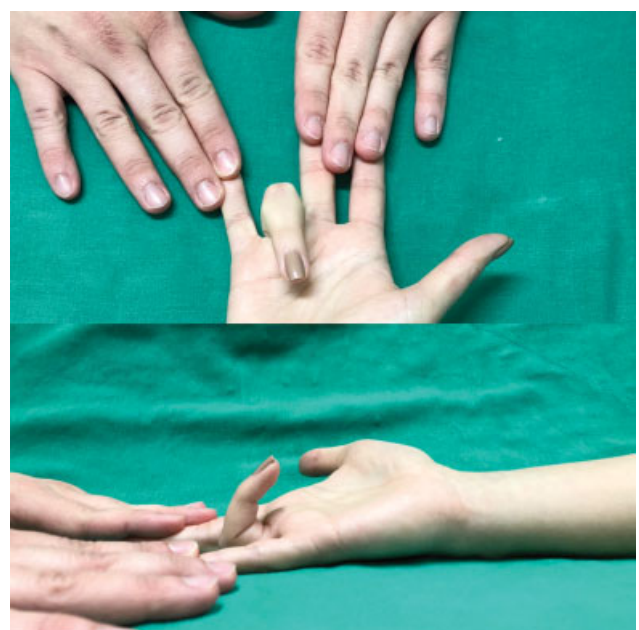


**Fig. 2** Clinical test to assess the presence of flexor digitorum superficialis muscle tendon function for the fifth finger with negative result.

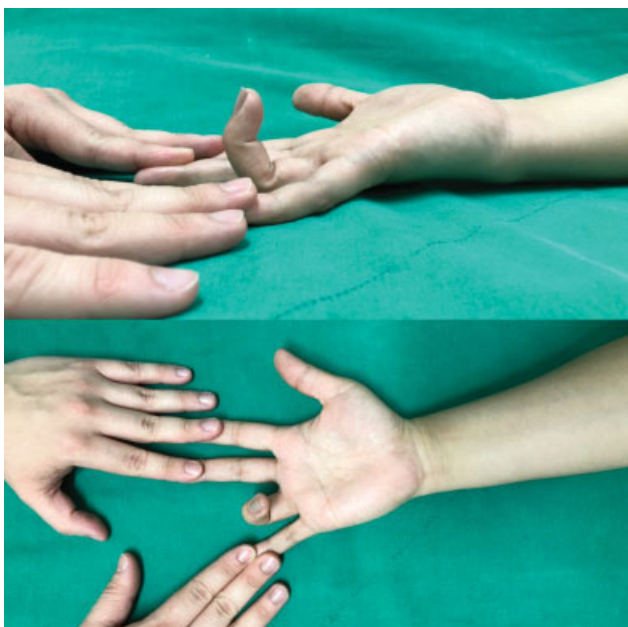in conjunction with DIP joint flexion, FDS function was considered absent (► **Figure 4**).

### Statistical Analysis

All collected data were organized in Excel software (Microsoft Corp., Redmond, WA, USA). Descriptive analysis was expressed in frequency and proportion. The chi-square test or Fisher exact test was used to analyze the homogeneity between proportions. Data analysis was performed at GraphPad Prism 5.0 (GraphPad Software, San Diego, CA, USA), adopting a 5% significance level.



**Fig. 3** Clinical test to assess the presence of flexor digitorum superficialis muscle tendon function for the fourth finger.



**Fig. 4** Clinical test to assess the presence of flexor digitorum superficialis muscle tendon function for the fourth finger with negative result.

## Results

This study evaluated the prevalence of absence of FDS muscle tendon function in the fourth and fifth fingers in 1,008 individuals, totaling 2,016 hands. Subjects included 531 (52.67%) males and 477 (47.33%) females (► **Figure 5**). Age ranged from 18 to 70 years-old, with a mean value of 38.42 years-old.

The prevalence of absence of FDS muscle tendon function in the fourth finger was 6 (0.56%) cases in the right hand and 10 (0.99%) in the left hand (► **Figure 6**). This difference was not significant. Absence of FDS muscle tendon function was more common in females than in males ( $p = 0.0328$ ). In the left hand, there were no differences between genders ( $p = 0.7562$ ). Absolute numbers are shown in ► **Table 1**.

The prevalence of absence of FDS muscle tendon function in the fifth finger was significantly higher in the right hand (34.53%) compared to the left hand (30.06%) ( $p = 0.0361$ ) (► **Figure 7**). This absence was more common in females than in males. In the right hand, it was observed in 37.10% of female subjects versus 23.72% of male subjects ( $p = 0.0001$ ). In the left hand, FDS function was absent in 40.26% of female subjects versus 29.38% of male subjects ( $p = 0.0003$ ). Absolute numbers are shown in ► **Table 2**.

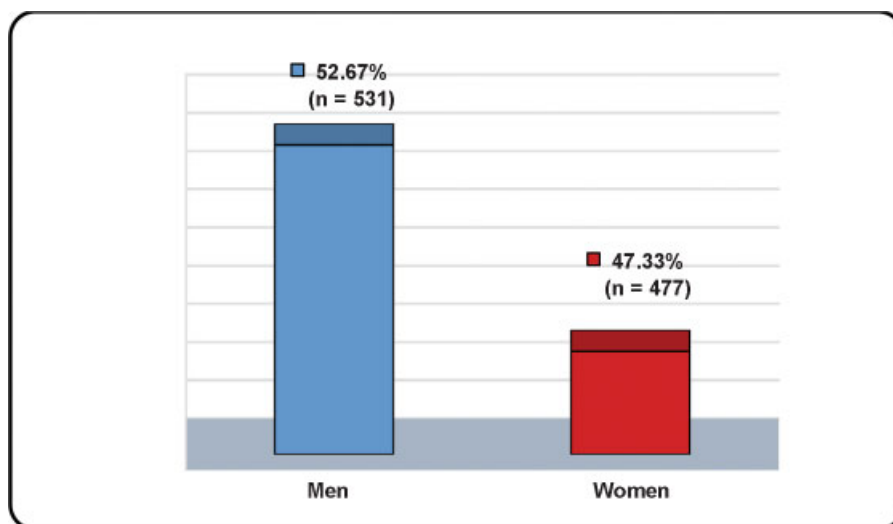
## Discussion

Studies to elucidate the prevalence of absence of FDS muscle tendon function in the fourth and fifth fingers have been conducted in different geographic regions of the world. However, there are few data in multiethnic populations, such as the Brazilian population.

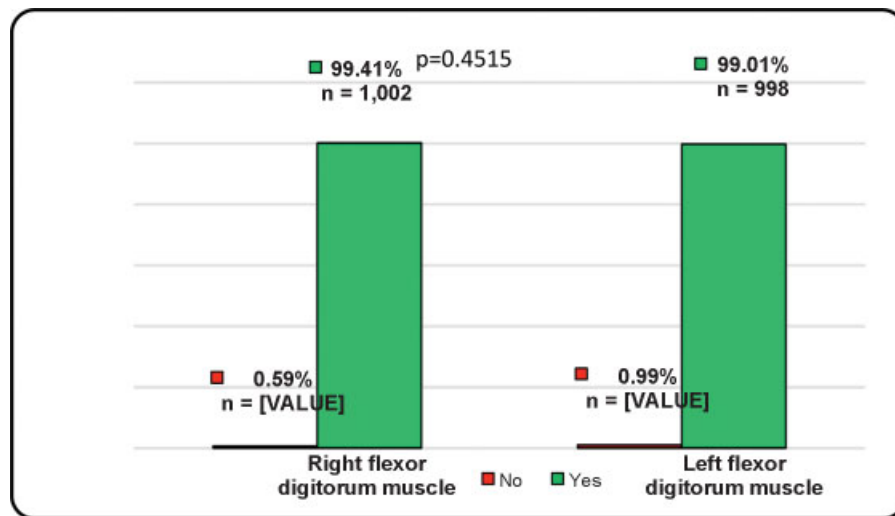
The mean age of our sample was 38 years old. This finding is similar to other studies, which reported an average age of 40 and 41 years-old.<sup>13,14</sup> We observed a higher mean age than Kigera and Katusiime,<sup>15</sup> who studied a population with an average age of 25 years old, and Raouf et al.<sup>16</sup> who reported a mean age of 23 years old.

Differences observed between studies may be justified mainly due to their population groups. In studies analyzing the general population, age was higher compared to our findings. In contrast, other studies have looked at specific groups, such as students, which probably resulted in a younger population. The prevalence of absence of FDS muscle tendon function in the fifth finger can affect an active population, leading to economic impacts and compromising the career of specific, highly specialized individuals, such as musicians.<sup>13-16</sup>

Our results are consistent with those of other studies, which reported that the absence of FDS muscle tendon function in the fifth finger is more frequent in females than in males. However, other studies showed that the prevalence of absence of FDS muscle tendon function in the fourth and fifth finger was similar in both genders. In



**Fig. 5** Gender distribution of the subjects.

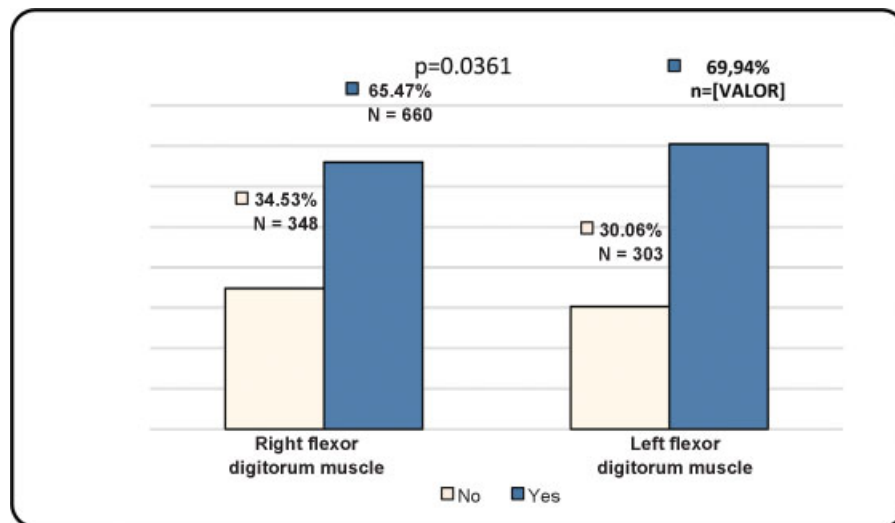


**Fig. 6** General prevalence of presence of flexor digitorum superficialis muscle tendon function for the fourth finger according to side.

**Table 1** Prevalence of the absence of flexor digitorum superficialis muscle tendon function of the fourth finger according to gender

Gender	FDS – Right side			FDS – Left side		
	Present Function % (n)	Absent Function % (n)	p	Present Function % (n)	Absent Function % (n)	p
Male	100% (n = 471)	0% (n = 0)	0.0328	98.88% (n = 525)	1.12% (n = 6)	0.7562
Female	98.88% (n = 531)	1.12% (n = 6)		99.17% (n = 473)	0.83% (n = 4)	

Abbreviation: FDS, flexor digitorum muscle.



**Fig. 7** Prevalence of the absence of flexor digitorum superficialis muscle tendon function for the fifth finger.

addition, the prevalence of absence of FDS muscle tendon function in both hands of female subjects was higher in our work than in the study from Bowman et al. who reported a prevalence of 18.6% in the female population.<sup>9-15</sup>

After evaluating our results and reviewing the literature, it seems that there is a genetic relationship in ethnicity-based prevalence. We observed a high prevalence of absence of FDS muscle tendon function for the fifth finger, consistent to previous reports. These findings are probably due to the miscegenation of the Brazil population. In Africa,

the overall prevalence of absence of FDS function was low, reaching 2.5%.<sup>15</sup> The prevalence of absence of FDS muscle tendon function in the fifth finger in eastern countries was lower, such as 1.3% in Egypt,<sup>16</sup> and 4.3% in Iran.<sup>17</sup> Among the Turkish population, the prevalence is 18.5%. In China, this prevalence was 6.4%.<sup>18</sup> In the USA, prevalence ranged from 16 to 21%. In England, the prevalence of absence of FDS muscle tendon function in the fifth finger in the general population ranged from 13.7 to 25%,<sup>19</sup> and, in musicians, it was 3.3%.

**Table 2** Prevalence of the absence of flexor digitorum superficialis muscle tendon function of the fifth finger according to gender

Gender	FDS – Right side			FDS – Left side		
	Present Function % (n)	Absent Function % (n)	p	Present Function % (n)	Absent Function % (n)	p
Male	76.28% (n = 405)	23.72% (n = 126)	0.0001	70.62% (n = 375)	29.38% (n = 156)	0.0003
Female	62.90% (n = 300)	37.10% (n = 177)		59.74% (n = 285)	40.26% (n = 192)	

Abbreviation: FDS, flexor digitorum muscle.

Another difference between studies includes the sample number addressed in each one, which ranges from 50 people in the 1989 US pioneer study to 800 people in the African study. Thus, it is questionable whether the reported data reflect the actual prevalence of absence of FDS muscle tendon function in the fifth finger.

The present study was the first to report the prevalence of absence of FDS muscle tendon function in the fourth and fifth fingers in the Brazilian population. Obviously, other differences justify the high prevalence found beyond the sample number. Previous researches<sup>13–18</sup> evaluated relatively uniform populations from a racial perspective. The miscegenation found in Brazil and the presence of the native population may be factors that increase the prevalence of absence of FDS muscle tendon function in the fourth and fifth fingers seen in this study. None of the work done in other populations had the presence of the Brazilian native population nor its genetic interactions with other ethnicities.

A recent meta-analysis studied the prevalence of absence of FDS muscle tendon function in the fifth finger in different articles and suggested that there is an evolutionary tendency produced by natural adaptation to generate fifth finger independence. This factor will probably reduce the prevalence of absence of this muscle function.

Patients often visit the emergency department with acute hand and forearm injuries. Standard care of these patients includes thorough examination of neurological and vascular functions. However, it has been shown that the superficial flexor tendon of the fifth finger may be functionally absent, and the simple clinical evaluation of its presence must be included in routine care,<sup>20–22</sup> especially in the Brazilian population, in which we found a high prevalence of absence of this muscle function. Thus, identifying the prevalence of absence of FDS function may be useful for hand surgeons as part of the criteria for surgical repair of tendon disorders.

## Conclusion

Although there are studies performed separately in different ethnic groups, there were no data in the literature regarding the prevalence of the absence of FDS muscle tendon function in the fourth and fifth fingers in a multiethnic population, such as the Brazilian population. Injuries to these tendons must be correctly assessed as they affect workers, and sequelae arising from misdiagnosis can result in serious economic impacts. The decision to explore and repair must be based on adequate physical examination and knowledge

of the high prevalence of absence of function of these tendons, especially of the FDS in the fifth finger, as evidenced in the present study.

## Conflict of Interests

The authors declare that there is no conflict of interests.

## References

- Caetano EB, Sabongi Neto JJ, Ribas LAA, Milanello EV. Accessory muscle of the flexor digitorum superficialis and its clinical implications. *Rev Bras Ortop* 2017;52(06):731–734
- Bernardes A, Melo C, Pinheiro S. A combined variation of Palmaris longus and Flexor digitorum superficialis: Case report and review of literature. *Morphologie* 2016;100(331):245–249
- Yamine K, Erić M. Agénésie, déficit fonctionnel, et variations anatomiques les plus courantes du flexor digitorum superficialis de l'auriculaire: une méta-analyse. *Hand Surg Rehabil* 2018;37(02):77–85
- Gupta A, Kumar V. Bilateral Absence of Flexor Digitorum Superficialis (FDS) Tendon of the Little Finger: Clinical Significance. *J Clin Diagn Res* 2014;8(02):135–136
- Tejaswi HL, Shilpashree YD. Clinical assessment of agenesis of palmaris longus and flexor digitorum superficialis in Indian population. *Int J Rec Trends Sci Technol* 2014;10(03):492–494
- Yılmaz A, Bozer C, Uluçam E, Taşkınalp O. An anomaly of flexor muscles of the fifth (little) finger of the hand: an anatomical case report. *Clinics (São Paulo)* 2009;64(11):1133–1135
- Ndibazza J, Lule S, Nampijja M, et al. A description of congenital anomalies among infants in Entebbe, Uganda. *Birth Defects Res A Clin Mol Teratol* 2011;91(09):857–861
- Elliot D, Khandwala AR, Kulkarni M. Anomalies of the flexor digitorum superficialis muscle. *J Hand Surg Br* 1999;24(05):570–574
- Bowman P, Johnson L, Chiapetta A, Mitchell A, Belusko E. The clinical impact of the presence or absence of the fifth finger flexor digitorum superficialis on grip strength. *J Hand Ther* 2003;16(03):245–248
- Guler F, Kose O, Turan A, Baz AB, Akalın S. The prevalence of functional absence of flexor digitorum superficialis to the little finger: a study in a Turkish population. *J Plast Surg Hand Surg* 2013;47(03):224–227
- Tan JS, Oh L, Louis DS. Variations of the flexor digitorum superficialis as determined by an expanded clinical examination. *J Hand Surg Am* 2009;34(05):900–906
- Yesilada AK, Tatlıdede HS, Çakmak E, Kiyak MV, Kılınc L. Anomalous large unique muscle belly of flexor digitorum superficialis and the absence of palmaris longus in the forearm. *J Plast Reconstr Aesthet Surg* 2013;66(01):137–139
- Godwin Y, Wheble GA, Feig C. Assessment of the presence of independent flexor digitorum superficialis function in the small fingers of professional string players: is this an example of natural selection? *J Hand Surg Eur Vol* 2014;39(01):93–100
- Puhaindran ME, Sebastin SJ, Lim AY, Xu WX, Chen YM. Absence of flexor digitorum superficialis tendon in the little finger is not associated with decreased grip strength. *J Hand Surg Eur Vol* 2008;33(02):205–207

- 15 Kigera JW, Katusiime A. Prevalence of agenesis of flexor digitorum superficialis of the fifth digit in East Africa through clinical examination. *SA Orthop J* 2011;10(04):75–77
- 16 Raouf HA, Kader GA, Jaradat A, Dharap A, Fadel R, Salem AH. Frequency of palmaris longus absence and its association with other anatomical variations in the Egyptian population. *Clin Anat* 2013;26(05):572–577
- 17 Enhesari A, Saied A, Mohammadpoor L, Ayatollahi Mousavi A, Arabnejhad F. Presence or absence of palmaris longus and fifth superficial flexor digitorum; is there any effect on median nerve surface area in wrist sonography. *Iran J Radiol* 2014;11(04): e14441
- 18 Sebastin SJ, Lim AY. Clinical assessment of absence of the palmaris longus and its association with other anatomical anomalies– a Chinese population study. *Ann Acad Med Singapore* 2006;35(04): 249–253
- 19 Townley WA, Swan MC, Dunn RL. Congenital absence of flexor digitorum superficialis: implications for assessment of little finger lacerations. *J Hand Surg Eur Vol* 2010;35(05):417–418
- 20 Wilcox DC, Buschbacher R, Bergeron J. Incidence of the inability to flex the proximal interphalangeal joint in normal subjects. *Arch Phys Med Rehabil* 1998;79(11):1405–1407
- 21 Austin GJ, Leslie BM, Ruby LK. Variations of the flexor digitorum superficialis of the small finger. *J Hand Surg Am* 1989;14(2 Pt 1):262–267
- 22 Baker DS, Gaul JS Jr, Williams VK, Graves M. The little finger superficialis—clinical investigation of its anatomic and functional shortcomings. *J Hand Surg Am* 1981;6(04):374–378