

# Biomechanical Study of Different Femoral Fixation Devices in the Reconstruction of the Medial Patellofemoral Ligament in Porcine Knees\*

## *Estudo biomecânico de diferentes dispositivos de fixação femoral na reconstrução do ligamento patelofemoral medial em joelhos de suínos*

Lothar Schmechel Dobke<sup>1</sup> João Artur Bonadiman<sup>1</sup> Osmar Valadão Lopes Jr.<sup>1</sup>  
 Paulo Renato Saggin<sup>1</sup> Charles Leonardo Israel<sup>3,4</sup> Leandro de Freitas Spinelli<sup>2,3,4,5</sup>

<sup>1</sup> Knee Surgery Service, Instituto de Ortopedia e Traumatologia (IOT), Hospital São Vicente de Paulo (HSVP), Universidade Federal da Fronteira Sul (UFFS), Passo Fundo, RS, Brazil

<sup>2</sup> Orthopedics and Traumatology Service, Santa Casa de Misericórdia de Porto Alegre, RS, Universidade de Passo Fundo, RS, Brazil

<sup>3</sup> Department of Mechanical Engineering, Universidade de Passo Fundo, Passo Fundo, RS, Brazil

<sup>4</sup> Graduate Program in Design and Manufacturing Processes, Universidade de Passo Fundo, Passo Fundo, RS, Brazil

<sup>5</sup> Department of Surgical Clinic, Universidade Federal de Ciências da Saúde de Porto Alegre, Porto Alegre, RS, Brazil

Address for correspondence Osmar Valadão Lopes Jr., MD, MSc, Rua Uruguai, 2050, Passo Fundo, RS, 99010-112, Brazil (e-mail: osmarlopesjr@gmail.com; pesquisa2@hsvp.com.br).

Rev Bras Ortop 2020;55(6):771–777.

### Abstract

**Objective** To evaluate different femoral fixation devices for medial patellofemoral ligament reconstruction and compare their effectiveness regarding fixation strength up to failure in porcine knees.

**Methods** Thirty porcine knees were used, divided into three groups of 10 knees. The removed grafts were dissected from the extensor tendons of porcine feet. In each group, the graft was fixed to the femur with an interference screw, an anchor, or adductor tenodesis. The three methods were subjected to biomechanical tests using a universal Tensile testing machine at a speed of 20 mm/minute.

**Results** The highest average linear resistance under lateral traction occurred in group 1, “screw fixation” ( $185.45 \pm 41.22$  N), followed by group 2, “anchor fixation” ( $152.97 \pm 49,43$  N); the lower average was observed in group 3, “tenodesis fixation” ( $76.69 \pm 18.90$  N). According to the fixed error margin (5%), there was a significant difference between groups ( $p < 0.001$ ); in addition, multiple comparison tests (between group pairs) also showed significant differences. Variability was small, since the variance coefficient was lower than 33.3%.

### Keywords

- ▶ biomechanical phenomena
- ▶ joint ligaments
- ▶ animal models
- ▶ patellofemoral joint
- ▶ suture technique
- ▶ orthopedic fixation devices

\* Work performed at Hospital São Vicente de Paulo (HSVP-RS), Instituto de Ortopedia e Traumatologia de Passo Fundo (IOT-RS) and Laboratory of Bioengineering, Biomechanics and Biomaterials at the Universidade de Passo Fundo (UPF).



## Resumo

### Palavras-chave

- ▶ fenômenos biomecânicos
- ▶ ligamentos articulares
- ▶ modelos animais
- ▶ articulação patelofemoral
- ▶ técnicas de sutura
- ▶ dispositivos de fixação ortopédica

**Conclusion** Interference screws in bone tunnels and mountable anchors fixation with high resistance wire are strong enough for femoral fixation in porcine medial patellofemoral ligament reconstruction. Adductor tenodesis, however, was deemed fragile for such purpose.

**Objetivo** Avaliar diferentes dispositivos de fixação femoral na reconstrução do ligamento patelofemoral medial para comparar sua eficácia quanto à força de fixação até a falha em joelhos suínos.

**Métodos** Foram ensaiados 30 joelhos de suínos subdivididos em 3 grupos de 10 joelhos. Os enxertos retirados foram dissecados de tendões extensores das patas dos suínos. Cada grupo teve o enxerto fixado ao fêmur com parafuso de interferência, âncora, ou tenodese no tendão adutor. Os 3 métodos foram submetidos à testes biomecânicos utilizando uma máquina universal de ensaio de tração com uma velocidade de 20 mm/min.

**Resultados** Verificamos que a média mais elevada da resistência linear sob tração lateral ( $185,45 \pm 41,22$  N) ocorreu no grupo 1: “fixação por parafuso,” seguido do grupo 2: “fixação por âncora” ( $152,97 \pm 49,43$  N), e a média foi menor no grupo 3: “fixação por tenodese” ( $76,69 \pm 18,90$  N). Para a margem de erro fixada (5%), comprovou-se a diferença significativa entre os grupos ( $p < 0,001$ ) e também através dos testes de comparações múltiplas (entre os pares de grupos) verificou-se a ocorrência de diferenças significativas. A variabilidade expressada por meio do coeficiente de variação mostrou-se reduzida, já que a referida medida foi inferior a 33,3%.

**Conclusão** O uso de parafusos de interferência no túnel ósseo de joelhos porcinos é suficientemente forte para fixação femoral na reconstrução do ligamento patelofemoral medial, assim como a fixação com âncoras montáveis com fio de alta resistência. Entretanto, a tenodese no tendão adutor mostrou-se frágil para essa finalidade.

## Introduction

The anatomy and biomechanical properties of the medial patellofemoral ligament (MPFL) are described in several studies.<sup>1-8</sup> The MPFL is located in the second of the three layers of the medial region, together with the medial collateral ligament. It runs transversally from the patella to the femur. At the femur, it attaches itself posteriorly and proximally to the medial and distal epicondyle and anteriorly to the adductor tubercle. Its average length ranges from 53 to 55 mm, and its width varies from 3 to 30 mm.<sup>4</sup> Since MPFL is one of the main medial stabilizers of the patella, its injuries (most often at the femoral attachment site) are associated with patellar dislocations.<sup>1-3</sup> It is frequently reconstructed in patients with recurrent instability, with good outcomes in clinical studies.<sup>1,3,5,7</sup> The MPFL is the main limiting factor for patellar lateral displacement, direction in which most dislocations occur, contributing with 60% of the restraining force during lateralization in 20° flexed knee.<sup>4</sup> The MPFL reconstruction was first described by Gomes et al.<sup>1</sup> and it is performed to restore patellar stability with favorable results.<sup>1,3,5,7</sup>

The reconstruction of the MPFL is often performed alone when bone morphology is normal. In cases with trochlear dysplasia and/or high patella, the MPFL can play an even greater role in biomechanical restriction compared to cases with normal trochlear fossa and patellar height.<sup>6</sup>

Many surgical techniques have been developed for the treatment of patellar instability, including free graft fixation in bone canals, free graft fixation with anchors, and free graft suture to the periosteum.<sup>7</sup> Today, there is no gold standard option for femoral fixation; the technique most frequently used is the tunnel with interference screw, followed by anchors with suture.<sup>9</sup>

Fixation by tenodesis is indicated for MPFL reconstruction in immature skeletons and to avoid transtendinous suture.<sup>10</sup> The technique of graft adductor magnus tenodesis performed in young people has the advantage of not causing any damage to the femoral open growth plate, preventing its premature closure, which may cause angular deformity.<sup>11</sup>

Anchors allow the direct insertion of implants (with no drilling, threading or pre-drilling) with a self-inclusion tip as well as perfecting and tensioning individual sutures.<sup>12</sup> Good functional scores at the Kujala scale were demonstrated in patients submitted to femoral fixation with titanium anchors. Since only one titanium anchor is applied to the femur, this procedure is relatively cost-effective; in addition, the use of many implants for graft stabilization increases the risk of local pain and inflammation.<sup>11</sup>

The prominent fixation material in the medial part of the medial femoral condyle is known to cause local irritation and potentially restrict movement. Even in the absence of prominent material, a medial femoral condyle tunnel can be the

source of refractory pain.<sup>7-9</sup> Pain and stiffness can also be related to an underlying lesion to the joint surfaces of the patellofemoral compartment or to the poor tunnel positioning.<sup>6-9</sup>

It is worth noting that any synthesis material on the patellar edge or the medial femoral condyle may become prominent following surgical swelling resolution. Patients may be less able to tolerate discomfort in such areas, requiring material removal.<sup>9</sup>

The present work aims to test and measure the biomechanical properties of three different methods of graft fixation in the medial femoral condyle during MPFL reconstruction in porcine knees—interference screws, titanium anchors with sutures, and adductor tenodesis—to evaluate the linear resistance under lateral traction at the same patellar inclination until failure at the graft femoral site.

## Materials and Methods

An experimental study was carried out with 30 fresh pigs knees aged 8 to 9 months and with approximately 110 kg of live weight. The tests were performed at room temperature and the samples were kept in saline solution for 300 minutes to maintain adequate hydration of parts before testing.

Porcine knee joints were chosen because they are anatomically similar and have comparable femoral bone density to human knee joints. Porcine knees are used as a comparative model for femur fixation,<sup>13</sup> and previous studies reported their similar biomechanical properties.<sup>14-17</sup>

The knees were dissected evenly. After skin and subcutaneous removal, patellar and quadriceps tenotomy, in addition to all extensor tendons, was performed, except in group 3, and the graft was fixed through an adductor tenodesis. All peripheral structures were sectioned and removed. Only the femur used for MPFL fixation biomechanical tests remained.

Thirty femurs were divided into 3 groups of 10, according to the fixation types to be tested. The reconstruction of the MPFL was performed with grafts dissected from porcine feet extensor tendons. The medial femoral condyle lengths in the sagittal plane were measured for sample standardization.

Considering native MPFL size variations,<sup>18</sup> we used grafts with a thickness of 4 mm and length of 126 mm (30 mm for femoral fixation, 40 mm for fixation to the traction equipment, and 56 mm of free tendon) for the screw and tenodesis groups, and tendons 4-mm thick and 192-mm long for the anchor group (0 mm for femoral fixation, two 56 mm free arms, and two 40 mm arms for fixation to the traction equipment). All grafts were measured with a mechanical caliper.

In group 1, fixation was performed with a 7 × 25 mm titanium interference screw, and a 1.5-mm Kirschner wire was used to find the best point for the femoral tunnel. It was placed at the anatomical site for MPFL attachment, 10 mm proximally and 2 mm posteriorly to the medial femoral epicondyle, or 4 mm distally and 2 mm anteriorly to the femoral adductor tubercle.<sup>6,17</sup>

A 7-mm cannulated drill was passed over the wire up to 30 mm in depth to accommodate the free ends of the tendon and preventing the 25 mm screw of going beyond the free

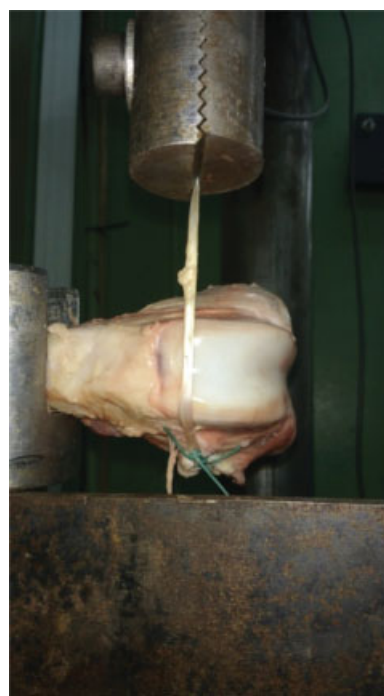end of the tendon in the tunnel to ensure better fixation.<sup>19</sup> Using a 2-mm Beath pin, the ends of the tendon were passed through the femoral tunnel, with the stems coming out through the lateral condyle. Applying traction to the stem, the graft was fixed with a 7 × 25-mm titanium interference screw and, as in the preconized technique, the screw head was buried subcortically.<sup>6</sup>

In group 2, fixation was performed with 5-mm titanium anchors in the femur, at the same point described for the previous group; the graft was folded into two arms of equal length, 96 mm, and fixed to the anchor with Ethibond 5.0 (Ethicon Inc., Somerville, NJ, USA) in the center of the fold over the tendon with two knots using the Pauchet technique.<sup>20</sup> The traction exerted during testing will be at a 90° angle, optimizing the force against the anchor pull.<sup>21</sup>

In group 3, adductor magnus tenodesis was performed; Ethibond 5.0 was used through 4 transfixations at the proximal region of the graft and 1 Pauchet knot<sup>20</sup> after each transfixation, totaling 4 knots (→ **Figure 1**).

## Biomechanical Testing

Biomechanical tests were performed for different types of graft fixation using a universal tensile testing machine at a speed of 20 mm/minute. These tests predict the vulnerability of a special fixation to failure during postoperative rehabilitation and provide an environment for direct comparison of different fixation techniques and devices. The force parameters were recorded using a Spider data acquisition system with 8 channels. The data processing software used was Catman Easy 3.1. Both manufactured by HBM Headquarters Germany / Darmstadt. The femurs were connected to the base of the machine by a tuning fork and kept parallel to the



**Fig. 1** Anterior view of a left porcine femur with a perpendicular graft under traction on the universal traction testing machine. Authors, 2017.

**Table 1** Strength in each fixation group

Group	Mean (N)	Standard deviation (N)	Variation coefficient (%)
1 Screw	185.45 <sup>(A)</sup>	41.22	22.23
2 Anchor	152.97 <sup>(B)</sup>	49.43	32.31
3 Tenodesis	76.69 <sup>(C)</sup>	18.90	24.64
<b>P-value</b>	<b>p<sup>a</sup> &lt; 0.001*</b>		

(\*) Statistically significant difference at 5%.

<sup>a</sup>Kruskal-Wallis test comparisons.

Distinct superscript letters indicate significant difference between corresponding groups.

ground, with the medial epicondyle facing downwards; the bones were fixed by their diaphysis through a screw anchored to the two ends of the tuning fork. A clip was used to fix the free graft extremity to the traction machine. The graft was maintained in the femoral fixation region at a 90° angle in relation to the axis of the machine (► **Figure 1**), keeping the traction visually in a straight line with the patellar lateral displacement vector.

The parameters evaluated were the following: force at the maximum resistance limit for different ligament fixation types, expressed in Newtons, and failure modes. Sample failure was defined by a sudden drop in graph curve (N) during the test. The test was then stopped, and the graph was analyzed.

### Statistical Analysis

Numerical variables were expressed as means, standard deviations, and coefficients of variation, whereas the categorical variable was expressed as absolute frequencies.

The sample size was determined by using the comparison methods of two mean values (Student t-test) from previous studies data.<sup>13,17</sup>

The Kruskal-Wallis test was used to compare the maximum traction force between the groups. Data normality and variances equality hypotheses were verified using the Shapiro-

Wilk and Levene tests; size comparisons were used due to the rejection of variance equality between the groups.<sup>22</sup>

The margin of error for statistical tests was 5.0%. Data were entered into an Excel spreadsheet, and statistical calculations were performed with SPSS version 23 (IMB Corp., Armonk, NY, USA).

This study was approved by the Animal Ethics Committee (CEUA, in the Portuguese acronym) of the institution.

### Results

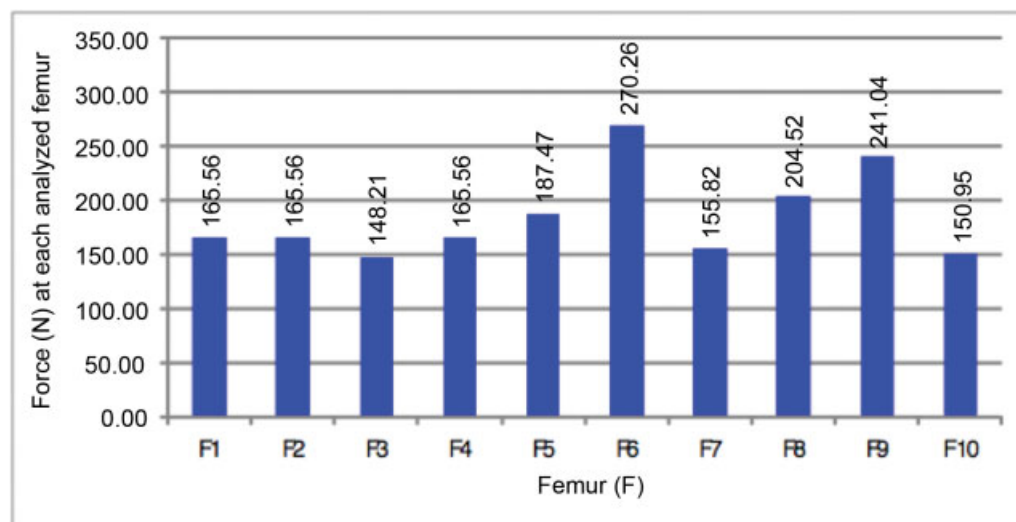
The highest average linear resistance under lateral traction occurred in group 1 (screw fixation; 185.45 ± 41.22 N), followed by group 2 (anchor fixation; 152.97 ± 49, 43 N); the lower average was observed in group 3 (tenodesis fixation; 76.69 ± 18.90 N) (► **Table 1**). According to the fixed error margin (5%), there was a statistically significant difference between the groups ( $p < 0.001$ ); in addition, multiple comparison tests (between group pairs) also showed significant differences. Variability, expressed by the variance coefficient, was small, lower than 33.3%. ► **Figures 2, 3 and 4** show the maximum force to failure in each sample per group

The femoral condyle widths on the sagittal axis were homogenous in each group. There was little variability between parts. Variation coefficients were up to 4.48%, as shown in ► **Table 2**.

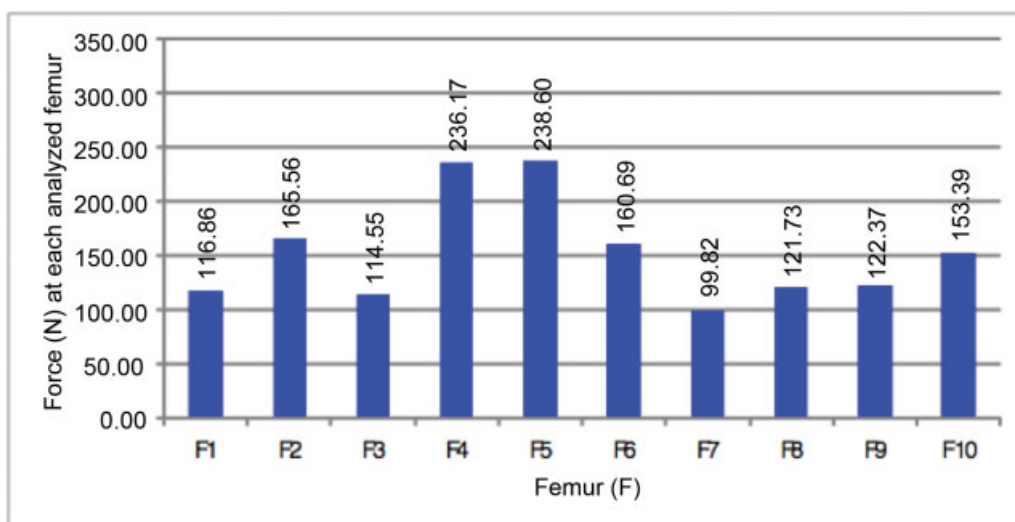
Regarding the causes of failure in each technique, group 1 (screw fixation) presented 6 loosening of the graft due to its sliding in the tunnel, and 4 failures resulting from graft rupture; in group 2 (anchor fixation), 8 failures were due to anchor suture rupture, and 2 due to graft rupture; finally, in group 3 (tenodesis fixation), all 10 failures resulted from graft rupture (► **Table 3**).

### Discussion

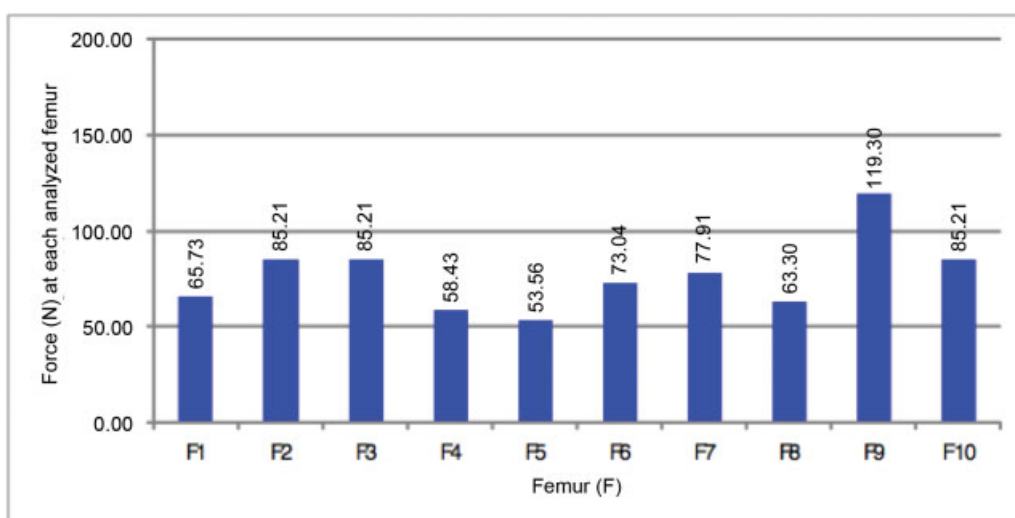
The present study aims to compare biomechanical linear resistance from three fixation methods previously described.



**Fig. 2** Maximum femoral traction force in group 1: Screw fixation. Authors, 2017.



**Fig. 3** Maximum femoral traction force in group 2: Anchor fixation. Authors, 2017.



**Fig. 4** Maximum femoral traction force in group 3: Tenodesis fixation. Authors, 2017.

**Table 2** Medial femoral condyle sagittal axis width in each group

Group	Mean (mm)	Standard deviation (mm)	Variation coefficient (%)
1 Screw	69.00	3.09	4.48
2 Anchor	68.90	2.77	4.02
3 Tenodesis	68.40	1.78	2.60

Fixation with interference screws in a bone tunnel (group 1) resulted in the greatest tensile strength load ( $185.45 \pm 41.22$  N) for medial patellofemoral ligament reconstruction, consistent with the native ligament strength in humans ( $145 \pm 68$  N) reported by Criscenti et al.<sup>2</sup> The anchor fixation group (group 2) also showed an average strength ( $152.97 \pm 49.43$  N) until failure close to findings from the aforementioned study; however, this was not observed in the adductor tenodesis group (group 3) ( $76.69 \pm 18.90$  N).

**Table 3** Failure types in each fixation method

Failure type	Screw	Anchor	Tenodesis
	N	N	N
Graft sliding into femoral tunnel	6	–	–
Graft rupture	4	2	10
Anchor wire rupture	–	8	–
<b>TOTAL</b>	<b>10</b>	<b>10</b>	<b>10</b>

(N) = Number of samples.

Our results are consistent with the published data: fixation with anchors or interference screws results in good postoperative outcomes.<sup>3,5,7,8</sup>

The modes of failure (► **Table 3**) resulting from maximum strength until fixation failure in each group were different depending on the fixation method; as such, a given type of failure prevailed in each group.



Our study showed that group 1 presented greater traction force compared to the other groups (► **Figure 2**), and its main type (60%) of failure was tendon sliding into the tunnel.

In the same group 1, graft rupture occurred in 40% of the samples. The simple placement of an interference screw is known to compromise the biomechanical properties of the graft.<sup>23</sup> This effect can be attenuated by avoiding the use of excessively large screws.

In group 2, 8 samples (80%) presented failure due to anchor suture (Ethibond 5.0) rupture; moreover, traction force variation was reasonably low, as evidenced by the variation coefficient (32.31%). We assume that the type of anchor wire, in addition to the anchor/wire interface, can directly influence the total force supported by the fixture. This finding is corroborated by a work showing that an anchorage using Ethibond 2.0 (Ethicon) is more fragile than one using Ethibond 5.0.<sup>24</sup> Knowing that wires with much higher resistance than Ethibond 5.0 are available, this technique proved to be quite strong to keep the patella on its trochlear track. Barber et al concluded that some more recent suture anchors showed significant improvements in load to failure values when compared to braided polyester sutures. Therefore, suture material influences failure modes.<sup>23,25</sup>

Another factor that apparently contributed to the anchor not being pulled out was the graft traction angle, of approximately 90° (► **Figure 1**), avoiding more acute angles (< 90°) that facilitate anchor pullout.<sup>21</sup>

Group 3 showed lower tensile strength (► **Figure 4**), and all failures resulted from graft rupture after suture (Ethibond 5.0) transfixation for biotenesis. Thus, it seems that the use of a transient suture may weaken the graft, increasing its vulnerability. Although some studies showed a certain advantage in not transfixing the graft,<sup>26</sup> further research on this subject are required.

Direct comparisons between human specimens are complicated, since factors such as donor age and bone density differences are difficult to control. Therefore, we chose to use porcine bones, which allowed us to control these factors. Since this study involved zero-time biomechanical testing in immediate postoperative conditions, no histological comparison was possible. Therefore, there are potential differences between in vitro and in vivo results, including because of the contribution of the other static and dynamic stabilizers at the patellofemoral joint. In addition, there was no measurement of graft slippage to reduce error or intra/interobserver reliability tests.<sup>11,27</sup>

## Conclusion

The use of bone tunnel interference screws in porcine knees is strong enough for femoral fixation in medial patellofemoral ligament reconstruction, as well as the fixation with mountable anchors and high resistance wire. Adductor tenodesis was deemed fragile for this purpose.

### Conflict of Interests

The authors have no conflict of interests to declare.

## References

- Gomez JL, Marczyk LR, Cesar PC, Jungblut CF. Reconstrução do ligamento patelofemoral medial: sua indicação na luxação da patela. *Rev Bras Ortop* 2003;38(1/2):56–66
- Criscenti G, De Maria C, Sebastiani E, et al. Material and structural tensile properties of the human medial patello-femoral ligament. *J Mech Behav Biomed Mater* 2016;54:141–148
- Arendt EA, Moeller A, Agel J. Clinical outcomes of medial patellofemoral ligament repair in recurrent (chronic) lateral patella dislocations. *Knee Surg Sports Traumatol Arthrosc* 2011;19(11):1909–1914
- Amis AA, Firer P, Mountney J, Senavongse W, Thomas NP. Anatomy and biomechanics of the medial patellofemoral ligament. *Knee* 2003;10(03):215–220
- Fithian DC, Gupta N. Patellar instability: principles of soft tissue repair and reconstruction. *Tech Knee Surg* 2006;5:19–26
- Scott WN. *Insall & Scott cirurgia do joelho*. 5° ed. Rio de Janeiro: Elsevier; 2015
- Placella G, Pace V, Foster P. Reconstruction of the medial patellofemoral ligament reconstruction for patients with recurrent patellar dislocation: review of surgical techniques and tips to achieve successful reconstruction. *Ann Transl Med* 2016;4(24):540
- Shah JN, Howard JS, Flanigan DC, Brophy RH, Carey JL, Lattermann C. A systematic review of complications and failures associated with medial patellofemoral ligament reconstruction for recurrent patellar dislocation. *Am J Sports Med* 2012;40(08):1916–1923
- Burrus MT, Werner BC, Conte EJ, Diduch DR. Troubleshooting the Femoral Attachment During Medial Patellofemoral Ligament Reconstruction: Location, Location. *Orthop J Sports Med* 2015;3(01):2325967115569198
- Yercan HS, Erkan S, Okcu G, Ozalp RT. A novel technique for reconstruction of the medial patellofemoral ligament in skeletally immature patients. *Arch Orthop Trauma Surg* 2011;131(08):1059–1065
- Witoński D, Kęska R, Synder M, Sibiński M. An isolated medial patellofemoral ligament reconstruction with patellar tendon autograft. *BioMed Res Int* 2013;2013:637678
- Yang DL, Cheon SH, Oh CW, Kyung HS. A comparison of the fixation strengths provided by different intraosseous tendon lengths during anterior cruciate ligament reconstruction: a biomechanical study in a porcine tibial model. *Clin Orthop Surg* 2014;6(02):173–179
- Ayzenberg M, Arango D, Gershkovich GE, Samuel PS, Saing M. Pullout strength of a novel hybrid fixation technique (Tape Locking Screw™) in soft-tissue ACL reconstruction: A biomechanical study in human and porcine bone. *Orthop Traumatol Surg Res* 2017;103(04):591–595
- Lee YS, Han SH, Kim JH. A biomechanical comparison of tibial back side fixation between suspensory and expansion mechanisms in trans-tibial posterior cruciate ligament reconstruction. *Knee* 2012;19(01):55–59
- Herbert M, Heletta S, Raschke MJ, et al. Accidental perforation of the lateral femoral cortex in ACL reconstruction: an investigation of mechanical properties of different fixation techniques. *Arthroscopy* 2012;28(03):382–389
- Posner M, Owens B, Johnson P, et al. Comparison of Pull-out Strength for Different Bone Block Length in a Porcine Anterior Cruciate Ligament Model. *Orthop J Sports Med* 2014;2(05):2325967114532762
- Shen HC, Chang JH, Lee CH, et al. Biomechanical comparison of Cross-pin and Endobutton-CL femoral fixation of a flexor tendon graft for anterior cruciate ligament reconstruction—a porcine femur-graft-tibia complex study. *J Surg Res* 2010;161(02):282–287
- Placella G, Tei M, Sebastiani E, et al. Anatomy of the Medial Patello-Femoral Ligament: a systematic review of the last 20 years literature. *Musculoskelet Surg* 2015;99(02):93–103
- Stalder M, Farshad M, Snedeker JG, Meyer DC. Interference screws should be shorter than the hamstring tendon graft in the bone

- tunnel for best fixation. *Knee Surg Sports Traumatol Arthrosc* 2013; 21(03):584–588
- 20 Cirino LM. Manual de técnica cirúrgia para a graduação. São Paulo: Sarvier; 2006
- 21 Sano H, Takahashi A, Chiba D, Hatta T, Yamamoto N, Itoi E. Stress distribution inside bone after suture anchor insertion: simulation using a three-dimensional finite element method. *Knee Surg Sports Traumatol Arthrosc* 2013;21(08):1777–1782
- 22 Altman DG. *Practical Statistics for Medical Research*. London: CRC Press; 1991
- 23 Barber FA, Herbert MA, Richards DP. Sutures and suture anchors: update 2003. *Arthroscopy* 2003;19(09):985–990
- 24 Rupp S, Georg T, Gauss C, Kohn D, Seil R. Fatigue testing of suture anchors. *Am J Sports Med* 2002;30(02):239–247
- 25 LaPrade RF, Gilbert TJ, Bollom TS, Wentorf F, Chaljub G. The magnetic resonance imaging appearance of individual structures of the posterolateral knee. A prospective study of normal knees and knees with surgically verified grade III injuries. *Am J Sports Med* 2000;28(02):191–199
- 26 Su WR, Chu CH, Lin CL, Lin CJ, Jou IM, Chang CW. The modified finger-trap suture technique: a biomechanical comparison of a novel suture technique for graft fixation. *Arthroscopy* 2012;28(05):702–710
- 27 Kim MK, Na SI, Lee JM, Park JY. Comparison of bioabsorbable suture anchor fixation on the tibial side for anterior cruciate ligament reconstruction using free soft tissue graft: experimental laboratory study on porcine bone. *Yonsei Med J* 2014;55(03):760–765