

# Update on Cervical Hernia Treatment: Conservative Management and Indications of Different Surgical Techniques

## *Atualização no tratamento da hérnia discal cervical: Manejo conservador e indicações de diferentes técnicas cirúrgicas*

Luis Eduardo Carelli Teixeira da Silva<sup>1,2</sup>  Luiz Eduardo Pereira Costa Assis de Almeida<sup>2</sup>

<sup>1</sup>Instituto Nacional de Traumatologia e Ortopedia (INTO), Rio de Janeiro, RJ, Brazil

<sup>2</sup>Instituto da Coluna Vertebral do Rio de Janeiro (INCOL), Rio de Janeiro, RJ, Brazil

Address for correspondence Luis Eduardo Carelli Teixeira da Silva, MD, Instituto Nacional de Traumatologia e Ortopedia (INTO), Rua Desembargador João Claudino de Oliveira e Cruz, 50, Apt 1804, Barra da Tijuca, Rio de Janeiro, RJ, 22793-071, Brazil (e-mail: luiscarelli@uol.com.br).

Rev Bras Ortop 2021;56(1):18–23.

### Summary

#### Keywords

- ▶ cervical vertebrae
- ▶ intervertebral disc displacement/diagnosis
- ▶ intervertebral disc displacement/therapy
- ▶ intervertebral disc displacement/surgery

### Resumo

#### Palavras-chave

- ▶ vértebras cervicais
- ▶ deslocamento do disco intervertebral/diagnóstico
- ▶ deslocamento do disco intervertebral/terapia
- ▶ deslocamento do disco intervertebral/cirurgia

Cervical and root pain due to herniated disc is one a common cause of a visit to an orthopedic surgeon. It is important to know how to diagnose, treat and initially. What are the best options to treat a herniated disc nowadays? The present article reviews the literature and updates on the clinical and surgical treatment of cervical disc herniation.

A dor cervical e radicular devido à hérnia de disco é uma causa comum de uma visita a um cirurgião ortopédico. É importante saber diagnosticar, tratar e inicialmente. Quais são as melhores opções para tratar a hérnia de disco hoje em dia? Este artigo faz uma revisão da literatura e atualização sobre o tratamento clínico e cirúrgico da herniação do disco cervical.

received  
June 1, 2020  
accepted  
September 16, 2020

DOI <https://doi.org/10.1055/s-0041-1724007>.  
ISSN 0102-3616.

© 2021. Sociedade Brasileira de Ortopedia e Traumatologia. All rights reserved.

This is an open access article published by Thieme under the terms of the Creative Commons Attribution-NonDerivative-NonCommercial-License, permitting copying and reproduction so long as the original work is given appropriate credit. Contents may not be used for commercial purposes, or adapted, remixed, transformed or built upon. (<https://creativecommons.org/licenses/by-nc-nd/4.0/>)

Thieme Revinter Publicações Ltda., Rua do Matoso 170, Rio de Janeiro, RJ, CEP 20270-135, Brazil

## Introduction

Cervical disc disease may have different forms of presentation, such as cervicalgia, radiculopathy, and myelopathy, and this differentiation by the orthopedist is important to guide the treatment.

Cervicalgia, or cervical pain, is the most prevalent symptom of cervical disc syndrome, presenting a lifetime prevalence of 48.5 to 66.7%, depending on the study analyzed.<sup>1,2</sup>

Cervical radiculopathy may be of compressive or inflammatory etiology, due to cytokines released due to disc herniation and rupture of the fibrous annuity.<sup>3</sup> It may present as brachialgia, sensory alteration, motor alteration, scapular pain, and headache.<sup>4</sup>

Myelopathy caused by disc herniation with anterior compression of the medulla may present with gait and sphincter alterations as well as with signs of first motor neuron involvement.

The pathophysiological process that encompasses cervical disc disease begins in the third decade of life, with disc vascularization reduction and increased sclerosis of the terminal plates, thus facilitating disc wear and decreasing the formation of proteoglycans. Once this process is started, there is a change in the load absorption by the disc, promoting fissures in the annulus and, finally, disc herniation or collapse.<sup>5,6</sup>

It is important to emphasize that physical examination provides us with valuable information in the etiological investigation and location of the disease in the cervical spine.

We should always characterize cervical pain, if it has associated muscle contracture, if pain worsens with cervical extension or flexion, and pain's duration.

Root pain usually follows a pattern of distribution on the examination (► **Table 1**), which should be investigated step by step and may present worsening during the Spurling test and improvement in shoulder abduction.

Looking for findings of myelopathy is essential since it can often take time to present symptoms, and the outcome can be catastrophic. We should always evaluate reflexes, gait, muscular trophism, and Hoffman signal presence.

The complementary tests available for diagnostic confirmation and understanding of the cervical disease in question are: anteroposterior, profile, flexion and extension profile radiographies; computed tomography; and magnetic resonance imaging (MRI).

Provocative discography, which has been used in the past, is less and less indicated due to its limited accuracy, with high

false-positive rates that can reach up to 50%, and with the possibility of early degeneration at control levels.<sup>7</sup>

Recently, with a better understanding of cervical and global sagittal alignment in the promotion of cervical diseases, as well as in surgical planning and its correlation with the clinical outcome, cervical and panoramic spine radiographs became important tools, requiring radiological measurements in addition to cervical lordosis, such as: the vertical sagittal axis (VSA) of the cervical spine, T1 inclination and neck tilt, which are parameters similar to those described for spinopelvic alignment<sup>8,9</sup> (► **Figure 1**).

## Treatment

There are several treatment options for cervical disc herniation, including drug treatment; non-interventional treatment, which includes physiotherapy, acupuncture, immobilization, and traction; interventional treatment of pain, which includes neural and facet blocks; and surgical treatment, which is indicated in cases of non-treatable radiculopathy or myelopathy<sup>7</sup> (**Chart 1**).

Making an analogy with conservative drug treatment for lumbosciatalgia, the best options are common analgesics, such as paracetamol and dipyron associated or not with opioids, and targeted use of nonsteroidal antiinflammatory drugs (NSAIDs). The use of oral corticosteroids should be avoided, since it has not been shown to have benefits in the control of root pain.<sup>10</sup>

In the present day, controlled skeletal traction and strengthening exercises continue to be one of the best methods for pain relief in short and medium term, being more efficient than stretching. Skeletal traction can be performed in ventroflexion or slight cervical extension, initially with 4 to 7 kg and with possible load increment. No serious complications were seen with the use of traction.<sup>11-13</sup>

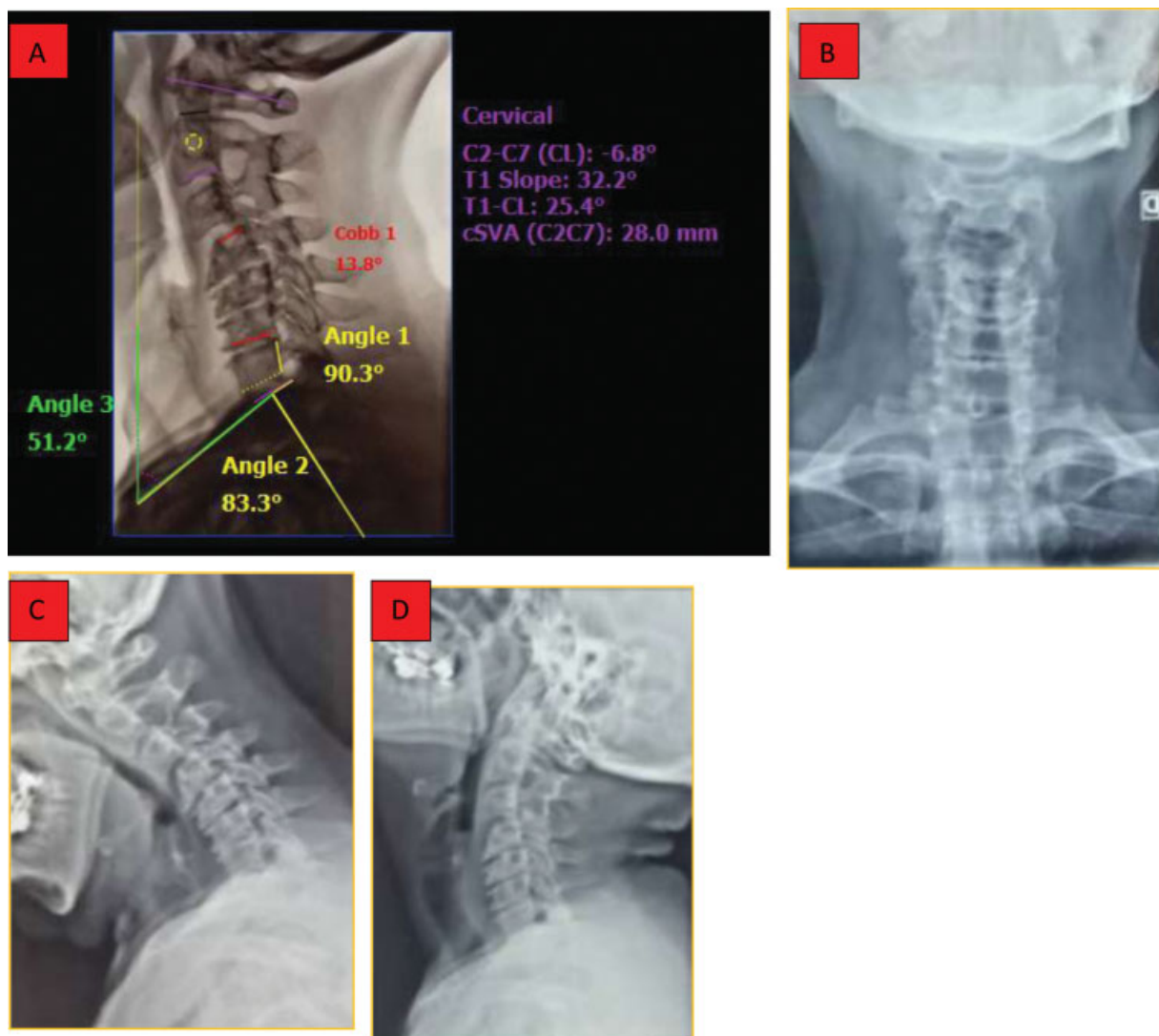
## Interventional Treatment

In cases refractory to conservative treatment, therapeutic blocks can be performed to control root and axial pain. Basically, three types of blockage are used: selective foraminal block, translaminar epidural block, and facet blocks.

Fluoroscopy-guided selective foraminal block has good effectiveness in the treatment of root pain, with successful pain relief rates of around 81% for brachialgia and 66% for cervicalgia, and can thus avoid surgeries. Occurrences of severe complications are little reported, so these can be considered safe procedures.

**Table 1** Distribution of the vicarious-brachial root dysfunction

| Root | Pain localization          | Motor dysfunction                                 | Sensory dysfunction            | Reflection  |
|------|----------------------------|---|--------------------------------|-------------|
| C5   | Shoulder and arm           | Deltoid, supraspinatus, infraspinatus and biceps. | Proximal and lateral shoulder  | Bicipital   |
| C6   | Radial part of the forearm | Wrist biceps and extensors                        | Radial part of the forearm     | Styloradial |
| C7   | Dorsal part of the forearm | Fist triceps and flexors                          | Index finger and middle finger | Tricipital  |
| C8   | Ulnar part of the forearm  | Hand intrinsics                                   | Ring and ulnar hand edge       | —           |



**Fig. 1** Radiographic parameters of cervical sagittal alignment. (A) Profile radiography with measurements of sagittal alignment of the cervical spine; (B) Radiography in anteroposterior incidence; (C) Radiography in profile with cervical flexion; (D) Radiography in profile with cervical extension; (E) Computed tomography of the cervical spine; (F-G) Magnetic resonance imaging of the cervical spine.

**Box 1** Cervical disc hernia treatment options

| Conservative treatment | Interventionist treatment     | Surgical treatment                    |
|------------------------|-------------------------------|---------------------------------------|
| • Drug therapy         | • Foraminal block             | • Posterior discectomy + foraminotomy |
| • Physical therapy     | • Translaminar epidural block | • Anterior discectomy + arthrodesis   |
| • Traction             |                               | • Cervical disc arthroplasty          |
| • Strengthening        |                               |                                       |

On the other hand, interlaminar epidural cervical block, according to the literature, presents a moderate success rate for root pain relief, and, with some reports of quadriparesis or cervical spinal cord injury, it is not considered for routine use.<sup>14-18</sup>

**Surgical Treatment**

Surgical treatment of cervical disc herniation is indicated in cases of failure of conservative treatment or when signs and

symptoms of myeloradicular compression are identified, that may cause excruciating, recurrent or major or compressive neurological deficit.

The main objective to be achieved, regardless of the surgical technique to be used, is the decompression of neural structures.

It should be emphasized that the current evidence does not support the surgical treatment of axial pain without root symptoms, either by arthrodesis or cervical disc arthroplasty, because they present unsatisfactory clinical results in the

subaxial region. Therefore, surgical treatment should be reserved for cases of spinal or root compressive syndromes.

Among the surgical treatment options available, the surgeon can choose from the following techniques: posterior discectomy associated with foraminotomy, open or minimally invasive; previous cervical approaches to decompression associated or not with cervical arthrodesis; or the use of cervical disc arthroplasties.

## Posterior Discectomy

Posterior discectomy, abandoned in the past due to neurological complications and tissue aggression in open surgeries, is regaining ground in selected cases of posterolateral or foraminal herniations that present with radiculopathy, using minimally invasive methods with tubular or endoscopic reformers.

Posterior foraminal decompression, described by Scoville in 1944, has been improved; however, the basic precepts of partial preservation of articular facets to avoid instability, in addition to contraindications for its use in central disc hernias and posterior longitudinal ligament calcification, should be respected.

Thus, the use of endoscopic scans for this purpose has been shown to be effective, with a reduction of 87 to 97% of root pain.<sup>19-23</sup>

Current evidence suggests that the risks of minimally invasive surgery may not outweigh its benefits, and that the routine use of these techniques require more detailed studies with a better level of evidence. However, with adequate training and careful selection of patients, the new technologies have proven safe and promising.<sup>24</sup>

## Anterior Cervical Discectomy and Arthrodesis

In 1958, Cloward described the first anterior discectomy and cervical arthrodesis with iliac crest structural graft, and, respecting the appropriate evolutions in the technique, this is still widely recognized as the gold standard for the surgical treatment of cervical disc herniation (► **Figure 2**).

Currently, titanium or polyetheretherketone (PEEK) spacers (cages) and plates are used, with the aim of ensuring greater stability, restoring cervical lordosis, decreasing subsidence rates and increasing osteointegration.<sup>25</sup>

Recent randomized studies, systematic reviews and meta-analysis, comparing the use of stand-alone cages and surgeries using cages and plates, demonstrated advantages in the adjunct use of plates and screws, such as: greater immediate biomechanical stability, higher arthrodesis rates, cervical lordosis and cervicgia improvement, and lower subsidence rates. However, non-statistically significant complications may occur more frequently when using plates and screws, such as dysphagia and failure of synthesis material.

Despite the improvement of cervical pain in studies with the use of plaque, functional results are similar in both groups.<sup>27</sup>

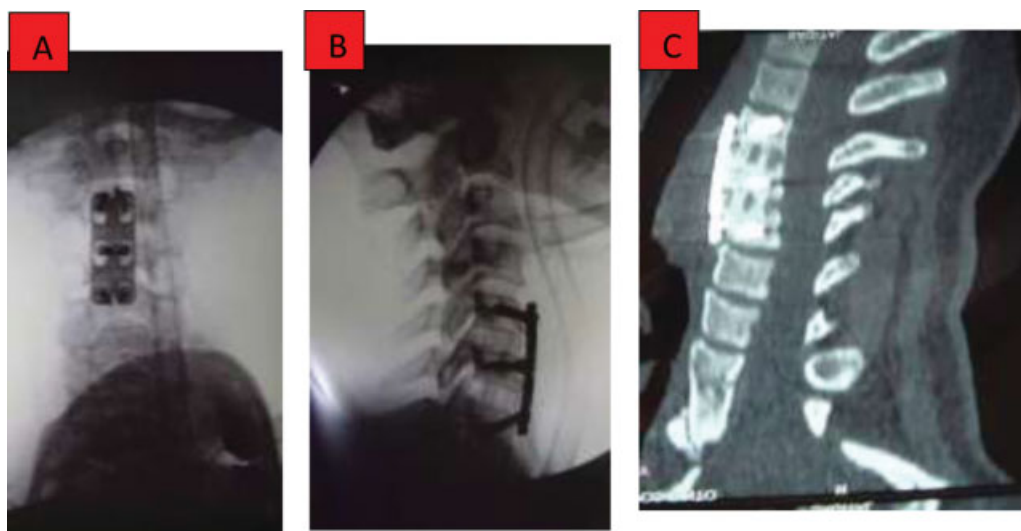
In order to reduce tissue aggression, dysphagia, and adjacent level syndrome, blocked cages were developed using anchors or screws.

In the current literature, studies demonstrate that the use of blocked cages, compared to that of plate, present shorter surgical time, decreased blood loss and lower incidence of dysphagia in the late postoperative period, as well as less adjacent level ossification. However, the evaluation of clinical, functional, radiological, and subsidence rates were similar in both techniques.<sup>28,29</sup>

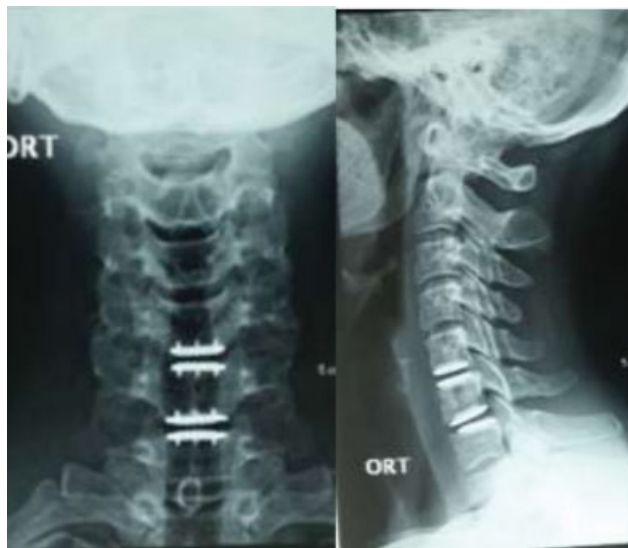In patients with misalignment of the cervical sagittal plane and cervicobrachialgia, the maintenance or improvement of cervical alignment, especially cervical lordosis, T1 slope, and cervical lordosis discrepancy with T1 slope (CL-TS), showed good correlation with clinical and functional results, with arthrodesis being the most indicated in these cases.<sup>30</sup>

## Arthroplasty

In order to preserve cervical mobility at the operated level, prevent adjacent level syndrome and improve clinical results, cervical intervertebral disc arthroplasty has been used in recent years (► **Figure 3**).



**Fig. 2** Anterior cervical arthrodesis with plate and cage in polyetheretherketone. (A) Intraoperative imaging in anteroposterior incidence; (B) Intraoperative profile image; (C) Computed tomography showing consolidation.



**Fig. 3** Cervical disc arthroplasty. (A) Radiography in anteroposterior incidence; (B) Profile radiography.

Numerous models of prostheses, whether constrict, non-constrict and semi-constrict; made of metal-metal or polyurethane nuclei, all of them maintain the same indications of anterior cervical arthrodesis, presenting the following contraindications: surgery at three or more levels, cervical instability, osteopenia, active infection, and kyphotic deformity.<sup>31</sup>

Some studies demonstrate the superiority of the prosthesis, indicating the decrease in the rate of reoperation at the operated level, decrease in the incidence of syndrome of the adjacent level, and maintenance of the arch of motion of the cervical spine among the advantages, despite the appearance of relevant heterotopic ossification, which occurs in around 23% of the cases, without compromising the best clinical and functional results when compared to the anterior cervical arthrodesis.<sup>33</sup>

However, other randomized studies question the effectiveness of arthroplasty when compared to anterior cervical discectomy associated or not with intersomatic fusion, with similar functional results between techniques, showing no superiority of one over the other.<sup>33</sup>

## Final Considerations

Patients with cervical disc herniation may present with a myriad of radiological findings that may have clinical correlation or not. In the failure of conservative treatment, image-guided blocks can be used for the treatment of radiculopathy, and if surgical intervention is required, we must carry out a correct planning, based on the presence of discopathy, myelopathy, cervical alignment, and the presence or not of instability.

After a careful evaluation of the clinical picture, the choice of surgical procedure should be based on available hospital resources, surgeon's experience, and literature with the best level of evidence; thus, it will be possible to indicate the best

surgical technique: discectomy/posterior foraminotomy, anterior arthrodesis, or arthroplasty.

## Conflict of Interests

The authors declare that there is no conflict of interests.

## References

- Côté P, Cassidy JD, Carroll L. The Saskatchewan Health and Back Pain Survey. The prevalence of neck pain and related disability in Saskatchewan adults. *Spine* 1998;23(15):1689–1698
- Fejer R, Ko Kyvik, J Hartvigsen. The prevalence of neck pain in the world population: a systematic critical review of the literature. *Eur Spine J* 2006;15(06):834–848
- Kang JD, Georgescu HI, L McIntyre-Larkin, Stefanovic-Racic M, Evans CH. Herniated cervical intervertebral discs spontaneously produce matrix metalloproteinases, nitric oxide, interleukin-6, and prostaglandin E2. *Spine* 1995;20(22):2373–2378
- Hoy DG, Protani M, De R, Buchbinder R. The epidemiology of neck pain. *Best Pract Res Clin Rheumatol* 2010;24(06):783–792
- Clark CR, Benzel EC, Eds. *The cervical spine*. Philadelphia: Lippincott Williams & Wilkins; 2005
- Taylor TK, Melrose J, Burkhardt D, et al. Spinal biomechanics and aging are major determinants of the proteoglycan metabolism of intervertebral disc cells. *Spine* 2000;25(23):3014–3020
- Manchikanti L, Abdi S, Atluri S, et al. An update of comprehensive evidence-based guidelines for interventional techniques in chronic spinal pain. Part II: guidance and recommendations. *Pain Physician* 2013;16(2, Suppl):S49–S283
- Pratali RR, Hennemann SA, Amaral R, et al. Standardized terminology of vertebral deformity from adult to Portuguese brazil. *Column/Columna* 2015;14(04):281–285
- Ames CP, Blondel B, Scheer JK, et al. Cervical radiographical alignment: comprehensive assessment techniques and potential importance in cervical myelopathy. *Spine* 2013;38(22, Suppl 1): S149–S160
- Goldberg H, Firtch W, Tyburski M, et al. Oral steroids for acute radiculopathy due to a herniated lumbar disk: a randomized clinical trial. *JAMA* 2015;313(19):1915–1923
- Im Moustafa, Diab AA. Multimodal treatment program comparing 2 different traction approaches for patients with discogenic cervical radiculopathy: a randomized controlled trial. *J Chiropr Med* 2014;13(03):157–167
- Yang JD, Tam KW, Huang TW, Huang SW, Liou TH, Chen HC. Intermittent Cervical Traction for Treating Neck Pain: A Meta-analysis of Randomized Controlled Trials. *Spine* 2017;42(13): 959–965
- J Ylinen, Takala EP, Nykänen M, et al. Active neck muscle training in the treatment of chronic neck pain in women: a randomized randomized controlled trial. *JAMA* 2003;289(19):2509–2516
- Ma DJ, Gilula LA, Riew KD. Complications of fluoroscopically guided extraforaminal cervical nerve blocks. An analysis of 1036 injections. *J Bone Joint Surg Am* 2005;87(05):1025–1030
- Abbasi A, Malhotra G, Malanga G, Elovic EP, Kahn S. Complications of interlaminar cervical epidural steroid injections: a review of the literature. *Spine* 2007;32(19):2144–2151
- Bose B. Quadriplegia following cervical epidural steroid injections: case report and review of the literature. *Spine J* 2005;5(05): 558–563
- Hodges SD, Castleberg RL, Miller T, Ward R, Thornburg C. Cervical epidural steroid injection with intrinsic spinal cord damage. Two case reports. *Spine* 1998;23(19):2137–2142, discussion 2141–2142
- Ludwig MA, Burns SP. Spinal cord infarction following cervical transforaminal epidural injection: a case report. *Spine* 2005;30(10):E266–E268

- 19 Wb Scoville. Recent developments in the diagnosis and treatment of cervical ruptured intervertebral discs. *Proc Am Fed Clin Res* 1945;2:23
- 20 Song Z, Zhang Z, Hao J, et al. Microsurgery or open cervical foraminotomy for cervical radiculopathy? A systematic review. *Int Orthop* 2016;40(06):1335–1343
- 21 O'Toole JE, Sheikh H, Eichholz KM, Fessler RG, Perez-Cruet MJ. Posterior cervical endoscopic foraminotomy and discectomy. *Neurosurg Clin N Am* 2006;17(04):411–422
- 22 Gala VC, Je O'Toole, JM Voyadzis, Fessler RG. Posterior minimally invasive approaches for the cervical spine. *Orthop Clin North Am* 2007;38(03):339–349, abstract v
- 23 Zdeblick TA, Zou D, Warden KE, McCabe R, Kunz D, Vanderby R. Cervical stability after foraminotomy. Biomechanical in vitro analysis. *J Bone Joint Surg Am* 1992;74(01):22–27
- 24 Evaniew N, Khan M, Drew B, Kwok D, Bhandari M, Ghert M. Minimally invasive versus open surgery for cervical and lumbar discectomy: a systematic review and meta-analysis. *CMAJ Open* 2014;2(04):E295–E305
- 25 Rb Cloward. The previous approach for removal of ruptured cervical disks. *J Neurosurg* 1958;15(06):602–617
- 26 Song KJ, Taghavi CE, Lee KB, Song JH, Eun JP. The efficacy of plate construct augmentation versus cage alone in anterior cervical fusion. *Spine* 2009;34(26):2886–2892
- 27 Oliver JD, Goncalves S, Kerezoudis P, et al. Comparison of Outcomes for Previous Cervical Discectomy and Fusion With and Without Previous Plate Fixation: A Systematic Review and Meta-Analysis. *Spine* 2018;43(07):E413–E422
- 28 Nambiar M, Phan K, Je Cunningham, Yang Y, Turner PL, Mobbs R. Locking stand-alone cages versus previous plate constructs in single-level fusion for degenerative cervical disease: a systematic review and meta-analysis. *Eur Spine J* 2017;26(09):2258–2266
- 29 Nemoto O, Kitada A, Naitou S, Tachibana A, Ito Y, Fujikawa A. Stand-alone anchored cage versus cage with plating for single-level anterior cervical discectomy and fusion: a prospective, randomized, controlled study with a 2-year follow-up. *Eur J Orthop Surg Traumatol* 2015;25(Suppl 1):S127–S134
- 30 Iyer S, Nemani VM, Nguyen J, et al. Impact of Cervical Sagittal Alignment Parameters on Neck Disability. *Spine* 2016;41(05):371–377
- 31 Koreckij TD, Gandhi SD, Park DK. Cervical Disk Arthroplasty. *J Am Acad Orthop Surg* 2019;27(03):e96–e104
- 32 Hisey MS, Bae HW, Davis RJ, et al. Prospective, Randomized Comparison of Cervical Total Disk Replacement Versus Previous Cervical Fusion: Results at 48 Months Follow-up. *J Spinal Disord Tech* 2015;28(04):E237–E243
- 33 Vleggeert-Lankamp CLA, Janssen TMH, van Zwet E, et al. The NECK trial: Effectiveness of anterior cervical discectomy with or without interbody fusion and arthroplasty in the treatment of cervical disc herniation; a double-blinded randomized controlled trial. *Spine J* 2019;19(06):965–975