

A Prospective Observational Study on Outcomes of Single Stage Posterior Decompression and Fixation for Dorsolumbar Spine Tuberculosis

Estudo observacional prospectivo sobre os desfechos da descompressão posterior e fixação em estágio único na tuberculose da coluna dorsolumbar

Hari J. Menon¹ Aditya V. Tripathi¹  Nrutik M. Patel¹ Chandan Narang¹

¹Department of Orthopaedics, Civil Hospital of Surat, Surat, Gujarat, India

Address for correspondence Aditya V. Tripathi, MS, Department of Orthopaedics, Civil Hospital Surat, Ring Road, Opp Stem Cell Hospital, Khatodra Wadi, Majura Gate, Surat, Gujarat 395001, India (e-mail: ad007t@gmail.com).

Rev Bras Ortop 2023;58(3):404–409.

Abstract

Objective To study the results of only posterior decompression and instrumentation in dorsal and dorsolumbar spine tuberculosis.

Methods The patients ($n=30$) who were included in this study had dorsal or dorsolumbar spine tuberculosis, with or without neurological deficit, and with or without deformity. All 30 patients were managed by only posterior approach decompression and instrumentation. We studied cases for correction and maintenance of deformity at dorsal and dorsolumbar spine, functional outcome by the Oswestry disability index (ODI) and visual analogue scale (VAS) scores, as well as neurological outcome by the Frankel grade.

Results In the current series, 30 patients were operated with single stage posterior decompression and instrumentation, and showed significant improvement in neurological status and functional outcomes, which were accessed by the ODI score, VAS score, and Frankel grade.

Conclusion The posterior (extracavitary) approach provides optimum access to the lateral and anterior aspects of the spinal cord for good decompression. It facilitates early mobilization and avoids problems of prolonged recumbency, provides better functional outcome, and significantly better sagittal plane kyphosis correction.

Keywords

- ▶ Koch's spine
- ▶ posterior approach
- ▶ Pott's spine
- ▶ spondylodiscitis

Work developed in the Department of Orthopaedics, Civil Hospital of Surat, Surat, Gujarat, India

received
February 3, 2022
accepted
April 28, 2022

DOI <https://doi.org/10.1055/s-0042-1750833>.
ISSN 0102-3616.

© 2023. Sociedade Brasileira de Ortopedia e Traumatologia. All rights reserved.

This is an open access article published by Thieme under the terms of the Creative Commons Attribution-NonDerivative-NonCommercial-License, permitting copying and reproduction so long as the original work is given appropriate credit. Contents may not be used for commercial purposes, or adapted, remixed, transformed or built upon. (<https://creativecommons.org/licenses/by-nc-nd/4.0/>)

Thieme Revinter Publicações Ltda., Rua do Matoso 170, Rio de Janeiro, RJ, CEP 20270-135, Brazil

Resumo

Objetivo Estudar os desfechos da descompressão posterior isolada e instrumentação na tuberculose da coluna dorsal e dorsolombar.

Métodos Os pacientes ($n=30$) incluídos no estudo apresentavam tuberculose na coluna dorsal ou dorsolombar acompanhada ou não por déficit neurológico e/ou deformidade. Todos os 30 pacientes foram tratados apenas por descompressão posterior e instrumentação. Estudamos a correção e manutenção da deformidade na coluna dorsal e dorsolombar, o desfecho funcional segundo o índice de deficiência de Oswestry (ODI, do inglês Oswestry disability index) e a escala visual analógica (EVA), e o desfecho neurológico de acordo com a classificação de Frankel.

Resultados A atual série de 30 pacientes submetidos à descompressão posterior e instrumentação em estágio único apresentou melhora significativa no estado neurológico e desfecho funcional segundo ODI, EVA e classificação de Frankel.

Conclusão A abordagem posterior (extracavitária) permite o acesso ideal aos aspectos laterais e anteriores da medula espinhal para uma boa descompressão. Facilita a mobilização precoce, evita problemas associados ao decúbito prolongado, proporciona melhor desfecho funcional e corrige a cifose no plano sagital de maneira significativamente melhor.

Palavras-chave

- ▶ coluna de Koch
- ▶ abordagem posterior
- ▶ coluna de Pott
- ▶ espondilodiscite

Introduction

In India, tuberculosis is a significant infectious cause of death affecting the pulmonary system, but extrapulmonary involvement is also frequently encountered. Skeletal system involvement accounts for 1 to 3% of the cases. The most frequent kind of skeletal tuberculosis (50%) is spinal tuberculosis.¹

From the pre-antitubercular era to the post-antitubercular era, treatment for tuberculosis of the spine has progressed. Antitubercular medicines, decompression surgeries, and a mid-path regimen are good treatment options.¹

Due to anatomical and biomechanical differences, the natural history of tuberculosis in the dorsal and lumbar areas may differ from that of other spine regions. Tuberculosis of the dorsal and lumbar regions destroys the anterior (paradiscal and central) column of the spine, resulting in kyphosis, instability, and late-onset paralysis.²

Tuberculosis-related kyphosis is an unstable condition that tends to worsen until the entire body fuses anteriorly. The surgical treatment is recommended for failed conservative management, instability, and progressive neurological deficit.

Anterior vertebral bodies and paradiscal spaces are the most typically afflicted. The anterior approach has long been considered the gold standard, as it provides direct access to affected vertebral bodies for debridement and abscess drainage, as well as extensive decompression and defect restoration.^{3,4}

Morbidity and problems linked with anterior surgery due to thoracotomy or retroperitoneal exploration are especially common in the thoracic and lumbar regions. Because of the accompanying osteoporosis of vertebrae associated with illness, the anterior fixation is structurally weak, preventing a sufficient and stable fixation.^{5,6}

The use of a combined anterior debridement and posterior instrumentation helps to overcome the anterior approach's instability issues.^{7,8} It does, however, necessitate two procedures (single or staged) with added morbidity, and it is only recommended for patients with severe deformity.

Extrapleural approaches (posterior) can be used to reach the anterior and lateral column via posterior or posterolateral decompression. The posterior approach provides excellent exposure for spinal cord decompression, allows posterior instrumentation above and below the level of involvement, has less morbid surgery, allows for earlier mobilization, better sagittal-plan deformity correction, and is a more widespread approach.^{3,9}

The aim of this prospective study is to analyze the clinical and functional outcomes in term of pain and neurology, in the single stage posterior approach for tuberculosis of dorsolumbar spine among patients operated at our institution.

Materials and Method

This study was conducted at the New Civil Hospital, Surat, India; we studied 30 patients with tuberculosis of dorsal and lumbar spine. All patients were treated with the single stage posterior approach for decompression, fixation, and correction of deformity, as well as fusion for tuberculosis of dorsolumbar spine, from February 2018 to May 2020.

Inclusion Criteria

Age group of 18 to 60 years.

Tuberculosis of dorsal and lumbar spine with instability. Patients with tuberculosis of dorsolumbar spine with neurological signs which are neither improving nor worsening within 4 weeks of adequate conservative treatment.

Progressive neurological deficit even on adequate treatment or recurrence of neurological signs after improvement.

Rapid onset or late onset paraplegia.

Exclusion Criteria

Multi segmental tuberculosis of the spine.

Age under 18 and age over 60 years.

Tubercular spine with other comorbidities of the spine.

Patient responding to conservative management.

Methods

All patients were selected according to above criteria, preoperative diagnosis was based on magnetic resonance imaging (MRI) of the affected spine, and preoperative abscess aspiration, with sample analysis based on the cartridge-based nucleic acid amplification test (CBNAAT) and computed tomography (CT) guided biopsy. Preoperatively, 14 patients were diagnosed with tubercular infection by CBNAAT performed on ultrasound guided aspiration, and 4 patients by CT guided biopsy. All patients were treated with single stage posterior decompression and fixation. As per sensitivity reports, antithrombotic therapy (ATT) continued postoperatively for 9 to 12 months.

Operative Technique

Under general anesthesia, in prone position via midline incision, the subperiosteal dissection was done two levels above and below the affected vertebrae. After adequate exposure, a pedicle screw was inserted in unaffected vertebrae. A shaft with one side temporarily contorted (according to the deformity) was applied to maintain spinal stability during decompression (posterior and posterolateral) and debridement. Paravertebral and epidural abscess were drained and thorough debridement was done until fresh, bleeding bone was seen. The same procedure was repeated over other side. Harvested samples were sent for biopsy and culture for confirmation. Anterior column reconstruction was done using the minced spinolaminous process mixed with streptomycin powder (1 g). A cage was inserted when the defect was too large. The bilaterally placed contorted shafts and the construct were compressed, thereby achieving deformity correction (►Fig. 1–case 1).

The patients are followed up at 3 months, 6 months, and 1 year by the visual analogue pain scale (VAS) and the functional outcome was evaluated by using the postoperative Frankel grading, angle of kyphosis, Oswestry disability index (ODI), and blood investigations at 6 months. During follow-up, the duration of ATT was decided based on the clinical improvement and radiological evidence of disease regression (resolution of abscess and inflammation on follow up MRI, along with evidence of fusion).

Results

The dorsolumbar spine is most commonly affected (46.7%).

The mean surgical time was 3 hours and 20 minutes (range 2h20min – 4h10min).

The average blood loss was 800 ml (400–1500 mL).

The mean preoperative VAS was 7.9 (range 7–10) which improved to 2.1 (range 1–4) on the postoperative period, then to 1.1 on 6 months, and 0.9 on the 1-year follow-up.

The mean preoperative kyphosis in the dorsal and dorso-lumbar spine was 27.9 degrees, which was corrected to a mean of 9.5 degrees in the final follow up MRI images, implying better correction and maintenance of kyphosis.

Before surgery, 1 patient was classified with a Frankel grade A, 3 were classified as Grade B, 6 patients were classified grade C, 16 patients were classified as D, and 4 were classified as E (►Table 1). After surgery, at the 1-year follow up, 6 patients were with grade C improved to D grade. Out of 16 patients with grade D, 12 improved to grade E and 2 remained the same; only 1 patient with grade A improved to grade C. All 3 patients with grade B improved to grade C (►Table 2).

Before surgery, the ODI score of 4 patients was within the range of 0 to 20% (minimal disability); 16 patients were in the 20 to 40% range (moderate disability); 6 patients were in the 40 to 60% range (severe disability); and 4 patients were in the 60 to 80% range (crippled) (►Table 3). There was an improvement in the ODI score noted during follow-up assessment, which suggests functional improvement.

Histopathological examination of intraoperative samples of 30 patients suggestive of rifampicin-sensitive tuberculosis and ATT was started (none of the patients were diagnosed with multidrug-resistant tuberculosis). Duration of ATT was decided based on clinical signs of improvement, laboratory investigations, and radiological evidence of disease regression during follow-up.

Complications

There were 3 patients who developed a superficial wound infection, 2 of which were treated with conservative measures and antibiotics for a longer period of time, and 1 patient was taken for debridement.

On the 6th month of follow-up, 1 patient developed loosening of 2 distal screws which was not progressed on the 12th month of follow-up.

On the 9th month of follow-up, 1 of the patients' MRI scans showed signs of delayed fusion, which on 12th month of follow-up showed satisfactory signs of healing.

Discussion

The dorsal region exhibited the highest rate of neurological impairment (30%). The majority of the patients with tuberculosis in the lumbar region had no neurological impairments. This may be due to them having a narrow spinal canal in the dorsal part of the spine and a relatively wide spinal canal space in the lumbar area.

The goals of surgery for tuberculosis of the dorsal and lumbar spine include appropriate decompression, adequate debridement, correction of deformity, and the prevention of kyphosis progression.

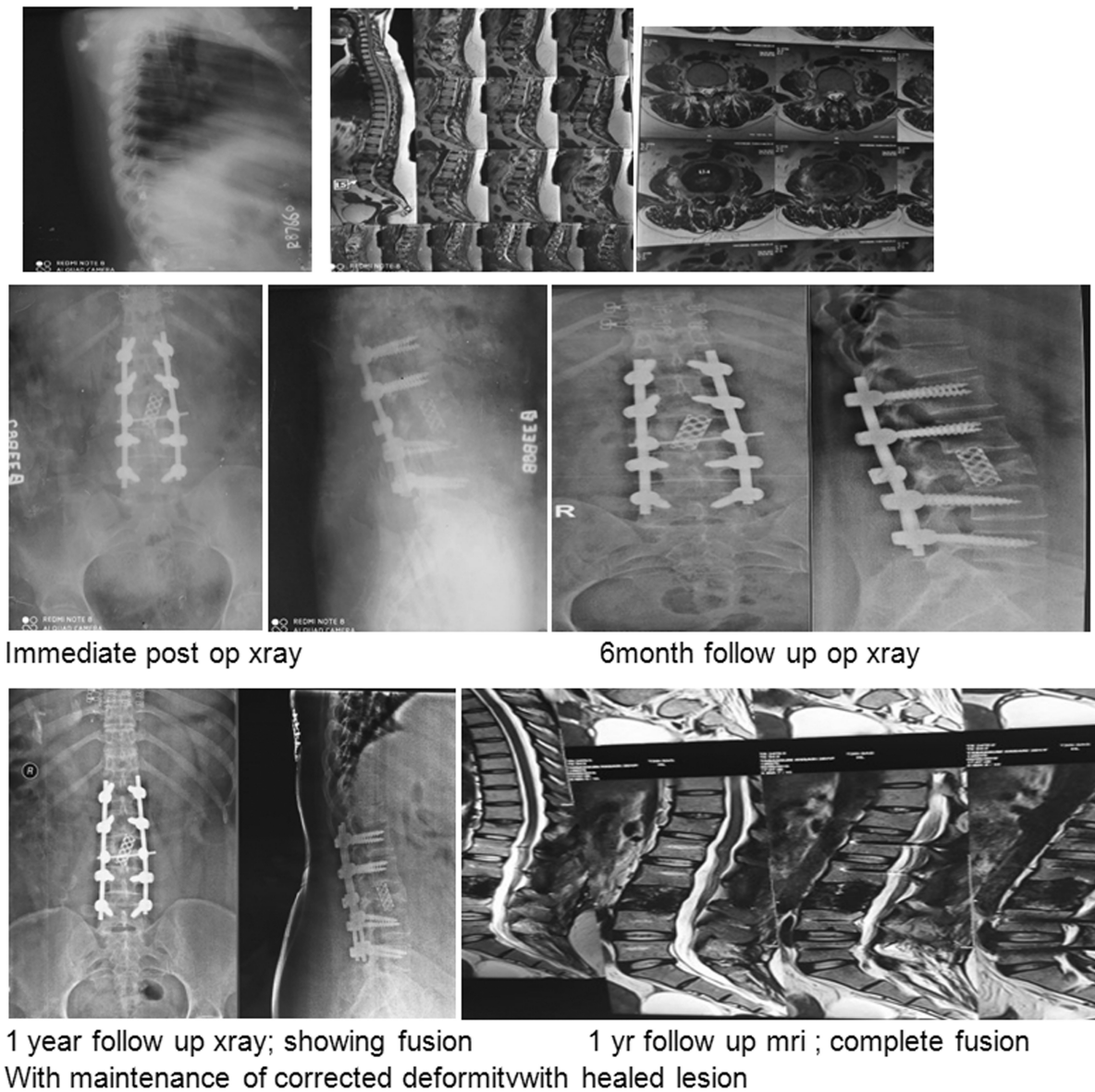


Fig. 1 Case: 28 year female with L2-L3 spondylodiscitis, MRI showing pre- and paravertebral abscess.

The anterior technique is the gold standard for debridement and decompression in spinal tuberculosis. The capacity to directly access the disease for decompression, greater correction of deformity, and ability to place a graft under the compressive load for fusion are the three advantages of the classic anterior technique. However, anterior approach has disadvantages in terms of morbidity and mortality linked with the transpleural and retroperitoneal approaches, such as atelectasis, chest infection, pneumothorax, postoperative ileus, and retrograde ejaculations. In the anterior technique,

the structural bone graft does not provide immediate stability, and graft-related complications are more common when the graft crosses more than two disc spaces.¹⁰

Moon et al. discovered that anterior arthrodesis was unsuccessful in preventing the progression of kyphosis or correcting previous abnormality.¹¹

A stable anterior graft provided structural support in only 41% of the patients, according to Rajasekaran and Soundarapandian,¹² while graft failure with residual kyphosis occurred in 59%. As a result, we came to the conclusion that

Table 1 Preoperative Frankel grade presentation

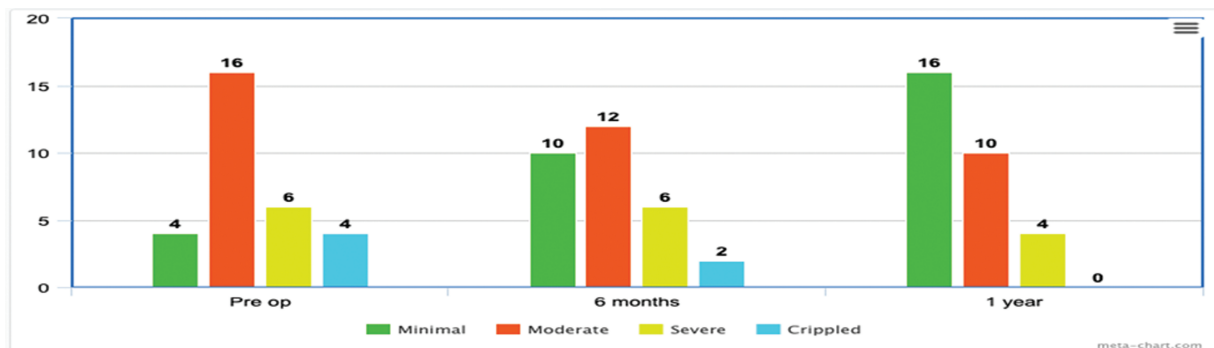
	Frankel grade – preoperative				
	A	B	C	D	E
Number of patients	1	3	6	16	4

Table 2 Postoperative Frankel grade presentation

	Frankel grade – postoperative				
	A	B	C	D	E
Number of patients	0	0	4	10	16

Table 3 Oswestry deficiency index (ODI) score presentation on respective follow-ups

	ODI score at the 6th month follow-up			
	0–20%	20–40%	40–60%	60–80%
Number of patients	10	12	6	2
	ODI score at the 1-year follow-up			
	0–20%	20–40%	40–60%	60–80%
Number of patients	16	10	4	0

**Fig. 2** Graphical representation of ODI score of respective follow-ups.

depending solely on the anterior strut bone graft to prevent vertebral collapse was not enough.¹²

The use of posterior instrumentation has been shown to be very beneficial in reducing graft-related complications and kyphosis development. Because the disease pathology is anterior, the fundamental advantage of posterior instrumentation is that it can give adequate fixation using posterior unaffected vertebrae.¹³

In one or two steps, posterior instrumentation with anterior decompression and fusion can be performed. Although this surgery is more extensive, it has a higher morbidity when conducted in one stage. There is a danger of graft slippage and neurological deterioration while waiting for the second stage of stabilization. When the posterior fixation is done initially, it will simply be in situ stabilization followed by second stage decompression, resulting in minor kyphosis correction.¹⁴

As reported by Jain et al.,² a posterior approach utilizing solely the extrapleural technique is a successful choice. The extrapleural method allows for decompression of the spinal cord under direct vision, and is complemented by a stable posterior fixation that can be extended above and below if necessary. Due to stable posterior instrumentation, early mobilization is possible, avoiding the risks of prolonged recumbency.⁸

In a retrospective analysis of 70 patients with thoracic and lumbar tuberculosis, Garg and Somvanshi³ compared the clinical, radiological, and functional outcomes of anterior versus posterior debridement and fixation. They found that while the anterior approach is equally good for debridement and stabilization, posterior instrumentation is better for kyphosis correction, and is associated with lesser morbidity and problems.

Shah et al.,¹⁵ in case series of 50 patients with tuberculosis of the dorsal and lumbar spines, used posterior instrumen-

tation to reduce and stabilize the unstable kyphotic zone. The practical consequence was much better in the posteriorly fixed group of patients, with an average Seybold and Bayley score of 14.66 (good).

Zeng et al.¹⁶ used single stage, posterior transpedicular debridement, interbody fusion, and posterior fixation followed by chemotherapy for single-segment thoracic spinal tuberculosis with neurological impairments, which were sufficient.

Islam et al.¹⁷ did an observational, follow-up study of 21 patients and concluded that the posterior approach is a minimum surgical intervention that encourages neurological recovery.

Patidar et al.¹⁸ published a prospective study of 20 patients, which suggested that single stage posterior approach is safe and effective for management of dorsolumbar spine tuberculosis.

In our research, posterior stabilization and reconstruction of the spine by posterior and posterolateral fusion, as well as fusion with cage in certain cases, helped to correct the deformity and prevent its progression.

Conclusion

The posterior technique (extracavitary approach) allows for reasonable access to the lateral and anterior spaces of the cord, allowing for equally effective cord decompression. It's a less morbid method that avoids the complications of thoracotomy and laparotomy.

It allows for early mobilization and eliminates the issues associated with extended recumbency; which results in a better functional outcome as well as a considerable improvement in the sagittal plane's deformity correction.

The posterior approach is chosen due to its familiarity, simplicity, and lower rate of complications.

Financial Support

There was no financial support from public, commercial, or non-profit sources.

Conflict of Interests

The authors have no conflict of interests to declare.

References

- 1 Tuli SM. Tuberculosis of the skeletal system. 6th ed. New Delhi: Jaypee Brothers Medical Pub.; 2020
- 2 Jain AK, Dhammi IK, Prashad B, Sinha S, Mishra P. Simultaneous anterior decompression and posterior instrumentation of the tuberculous spine using an anterolateral extrapleural approach. *J Bone Joint Surg Br* 2008;90(11):1477–1481
- 3 Garg RK, Somvanshi DS. Spinal tuberculosis: a review. *J Spinal Cord Med* 2011;34(05):440–454
- 4 Hee HT, Majd ME, Holt RT, Pienkowski D. Better treatment of vertebral osteomyelitis using posterior stabilization and titanium mesh cages. *J Spinal Disord Tech* 2002;15(02):149–156, discussion 156
- 5 Goel MK. Treatment of Pott's paraplegia by operation. *J Bone Joint Surg Br* 1967;49(04):674–681
- 6 Seddon HJ. Pott's paraplegia: prognosis and treatment. *Br J Surg* 1934;22(88):769–799
- 7 Donaldson JR, Marshall CE. Pott's disease (Experience with 560 operated cases). *Indian J Surg* 1965;27:765–773
- 8 Lee TC, Lu K, Yang LC, Huang HY, Liang CL. Transpedicular instrumentation as an adjunct in the treatment of thoracolumbar and lumbar spine tuberculosis with early stage bone destruction. *J Neurosurg* 1999;91(2, Suppl):163–169
- 9 Standring S. Gray's anatomy. The anatomical basis of clinical practice. 39th ed. Philadelphia: Churchill Livingstone; 2004
- 10 Hodgson AR, Stock FE. Anterior spinal fusion for the treatment of tuberculosis of spine. *J Bone Joint Surg* 1960;42(02):295–310
- 11 Moon MS. Tuberculosis of the spine. Controversies and a new challenge. *Spine* 1997;22(15):1791–1797
- 12 Rajasekaran S, Soundarapandian S. Progression of kyphosis in tuberculosis of the spine treated by anterior arthrodesis. *J Bone Joint Surg Am* 1989;71(09):1314–1323
- 13 Sundararaj GD, Behera S, Ravi V, Venkatesh K, Cherian VM, Lee V. Role of posterior stabilisation in the management of tuberculosis of the dorsal and lumbar spine. *J Bone Joint Surg Br* 2003;85(01):100–106
- 14 A controlled trial of débridement and ambulatory treatment in the management of tuberculosis of the spine in patients on standard chemotherapy. A study in Bulawayo, Rhodesia. *J Trop Med Hyg* 1974;77(04):72–92
- 15 Shah M, Suthar K, Zala R. To study the outcomes of posterior decompression and fixation of tuberculosis of dorsolumbar spine. *Int J Orthop Sci* 2017;3(03):691–695
- 16 Zeng H, Zhang P, Shen X, et al. One-stage posterior-only approach in surgical treatment of single-segment thoracic spinal tuberculosis with neurological deficits in adults: a retrospective study of 34 cases. *BMC Musculoskelet Disord* 2015;16:186
- 17 Islam MF, Akon MSI, Alom MI, Islam MZU, Hossain MY, Hossain MI. Evaluation of Outcome of Decompression and Transpedicular Screw Fixation in the Management of TB of the Thoracolumbar Spine. *Med Today (Karachi)* 2020;32(02):104–111 cited 2022 Apr. 26 [Internet] from <https://www.banglajol.info/index.php/medtoday/article/view/48823>
- 18 Patidar AB, Mehta RP, Sharma SK, Vyas GB, Singh V, Ramchandra O. Single-stage posterior-only debridement and transpedicular screw fixation for dorsolumbar tuberculosis: A prospective study of twenty cases. *J Orthop Allied Sci* 2017;5:74. Doi: 10.4103/joas.joas_11_17