

# Deep Vein Thrombosis after a Supracondylar Fracture of the Humerus in a Child – A Rare Complication\*

## *Trombose venosa profunda após uma fratura supracondilar do úmero em uma criança – Uma complicação rara*

Ana Moreira Ferrão<sup>1</sup>  Pedro Fernandes<sup>2</sup> Patrícia Wircker<sup>3</sup> Joana Catarino<sup>4</sup> Joana Arcângelo<sup>5</sup>  
Joana Ovídio<sup>5</sup>

<sup>1</sup> Resident, Orthopedics and Traumatology Service, Hospital de Curry Cabral, Centro Hospitalar Universitário de Lisboa Central, Portugal

<sup>2</sup> Resident, Orthopedics and Traumatology Service, Centro Hospitalar de Lisboa Ocidental, Portugal

<sup>3</sup> Resident, Orthopedics and Traumatology Service, Hospital de Cascais, Portugal

<sup>4</sup> Resident, Vascular Surgery Service, Hospital de Santa Marta, Centro Hospitalar Universitário de Lisboa Central, Portugal

<sup>5</sup> Orthopedic Surgeon, Children's Orthopedics Service, Hospital de Dona Estefânia, Centro Hospitalar Universitário de Lisboa Central, Portugal

**Address for correspondence** Ana Moreira Ferrão, Orthopedics and Traumatology Service, Centro Hospitalar Universitário de Lisboa Central, Rua da Beneficência, 8, 1050-099, Lisboa, Portugal (e-mail: anamoreiraferrao@gmail.com).

Rev Bras Ortop 2023;58(4):e672–e675.

### Abstract

Deep vein thrombosis in the upper extremities is uncommon, especially in the pediatric population and in the trauma setting. The diagnosis is challenging, due to its rarity, requiring a high degree of suspicion.

### Keywords

- ▶ deep vein thrombosis
- ▶ humeral fractures
- ▶ thrombosis
- ▶ venous thromboembolism
- ▶ child

We describe a rare case of humeral vein thrombosis after a displaced supracondylar fracture of the humerus in a 7-year-old girl. The risk factors for thromboembolism and sequelae are also discussed.

The early detection and treatment are mandatory to prevent poor outcomes, such as fatal thromboembolism.

\* Work developed at the Orthopedics and Traumatology Service at Centro Hospitalar Universitário of Lisboa Central, Portugal.

received  
June 2, 2020  
accepted  
September 16, 2020

DOI <https://doi.org/10.1055/s-0040-1722580>.  
ISSN 0102-3616.

© 2021. Sociedade Brasileira de Ortopedia e Traumatologia. All rights reserved.

This is an open access article published by Thieme under the terms of the Creative Commons Attribution-NonDerivative-NonCommercial-License, permitting copying and reproduction so long as the original work is given appropriate credit. Contents may not be used for commercial purposes, or adapted, remixed, transformed or built upon. (<https://creativecommons.org/licenses/by-nc-nd/4.0/>)

Thieme Revinter Publicações Ltda., Rua do Matoso 170, Rio de Janeiro, RJ, CEP 20270-135, Brazil

**Resumo****Palavras-chave**

- ▶ trombose venosa profunda
- ▶ fraturas do úmero
- ▶ trombose
- ▶ tromboembolia venosa
- ▶ criança

Trombose venosa profunda nas extremidades superiores é incomum, especialmente na população pediátrica e no ambiente do trauma. O diagnóstico é desafiador, devido a sua raridade, exigindo alto grau de suspeita.

Descrevemos um caso raro de trombose venosa úmera após uma fratura supracondilar deslocada do úmero em uma menina de 7 anos. Os fatores de risco para tromboembolismo e sequelas também são discutidos.

A detecção e o tratamento precoces são obrigatórios para evitar desfechos ruins, como tromboembolismo fatal.

**Introduction**

Humeral supracondylar fractures represent one third of all pediatric limb fractures in children under 7 years old, and are a cause of significant morbidity in the pediatric population.<sup>1,2</sup>

The complications most frequently encountered in this setting include neurovascular injuries, compartment syndrome, malunion, and functional impairment.<sup>1,2</sup>

Nerve and vascular injuries can be iatrogenic, or they may occur after a traumatic event. Vascular compromise can be caused by vessel rupture, kinking, compression, spasm, or intimal lesion, and the incidence increases according to the degree of fracture dislocation.<sup>3</sup>

The overall incidence of vascular complications associated with supracondylar fractures ranges from 3,2 to 14,3%, but may be as high as 20% in Gartland type III fractures.<sup>3,4</sup> Upon inspection, ecchymosis in the antecubital fossa with skin and brachialis tethering are warning signs of neurovascular damage.<sup>4</sup> Although the incidence and management of arterial injuries in supracondylar fractures is well established in the literature, little has been said about vein compromise.

Venous thromboembolism (VTE) in children is rare, ranging from 0.01% to 0.2% of pediatric hospitalizations; higher rates are observed in specific groups, including those with central venous catheters (CVC), malignancies, obesity and those submitted to major surgeries.<sup>5,6</sup>

In pediatric trauma patients, the risk of developing VTE is uncertain. The severity of the injury, increasing age, anemia, external fixation, obesity, length of hospital stay, postoperative complications, spinal cord injury and the presence of a CVC are well known risk factors in this population.<sup>6-8</sup> Some anatomical locations are also more prone to thrombotic events, that is, trauma to the head, the spine or major vessels, as well as pelvic and lower limb fractures.<sup>8</sup>

We report a case of humeral vein thrombosis after a supracondylar fracture in a child, given its rarity and difficult diagnosis, considering its potential complications.

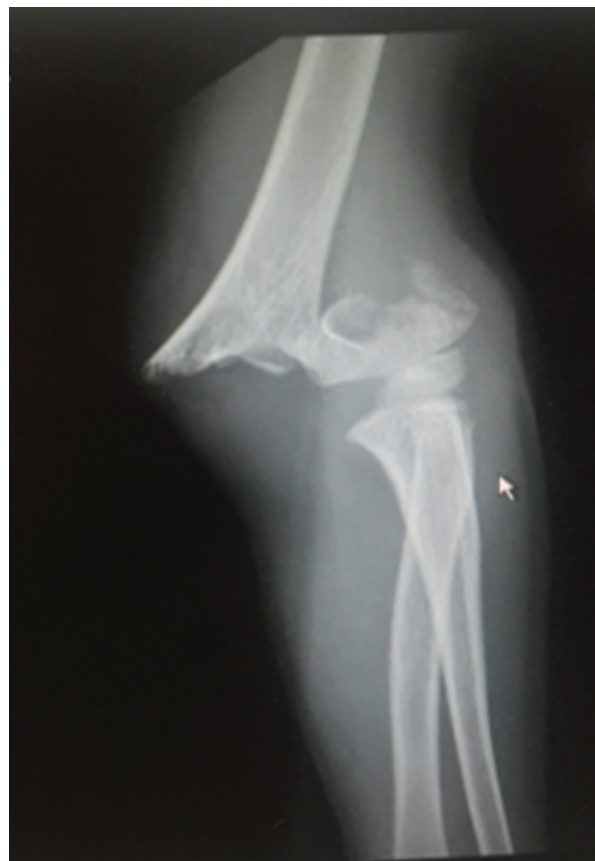**Case Report**

A 7-year-old girl was transferred to our emergency department after a fall with an outstretched arm which resulted in a supracondylar fracture of the left humerus, Gartland type III

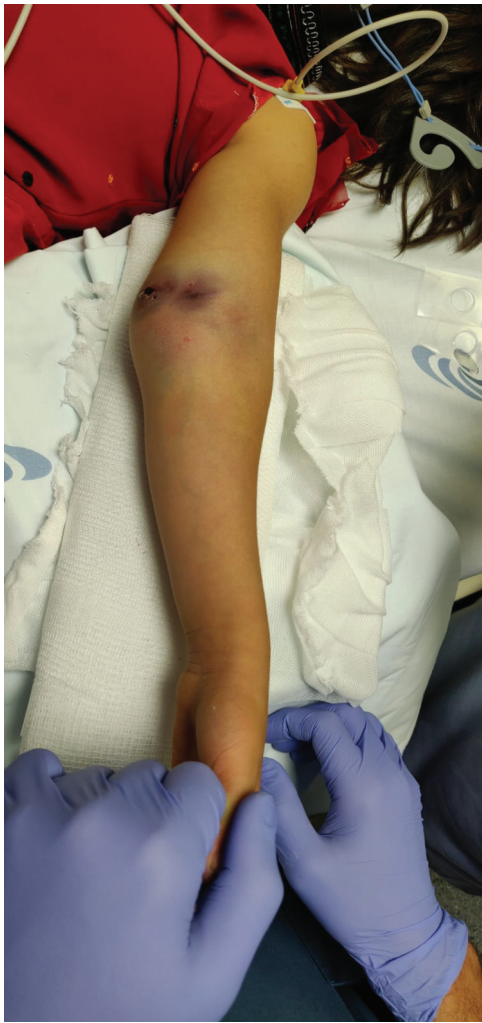(►Fig. 1). She had been previously immobilized with a posterior splint at an outside hospital.

Upon presentation, she complained of pain and had a cold and reddish forearm, with a peripheral oxygen saturation of 89% to 90% and weak palpable radial and ulnar pulses (►Fig. 2).

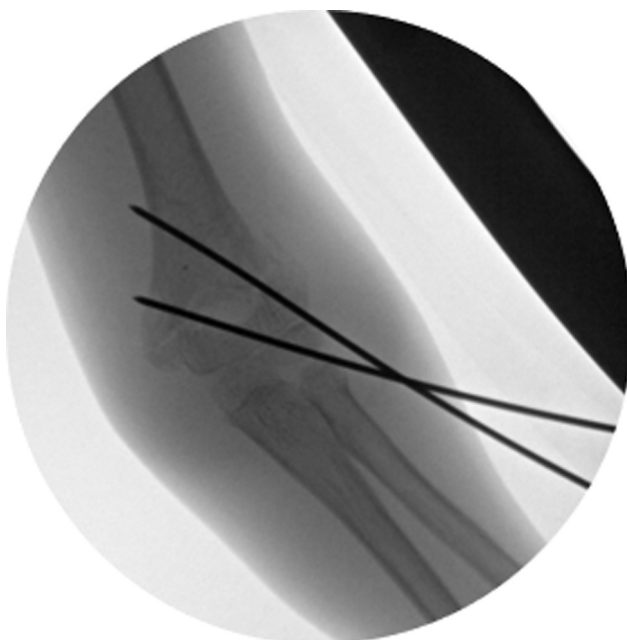
After splint removal, the pain subsided, she had a weak radial pulse, normal capillary refill, and the hand oximetry reached 98%. On an emergency basis, the patient underwent a smooth manipulation with closed reduction and pinning with 2 divergent lateral Kirschner wires and immobilization in a posterior splint at 120° of flexion (►Fig. 3). Six hours postoperatively, the child had a pain-free and warm upper extremity, a peripheral oxygen saturation of 100%, and palpable distal pulses.



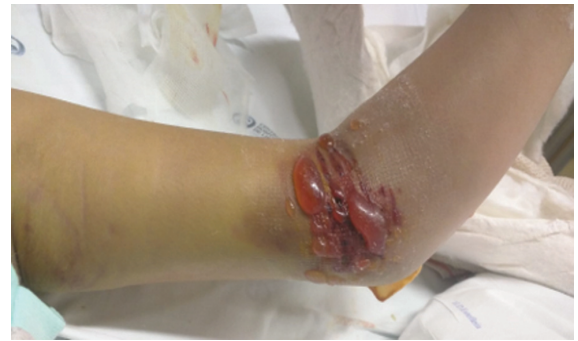**Fig. 1** Radiograph of the supracondylar humerus fracture (Gartland type III).



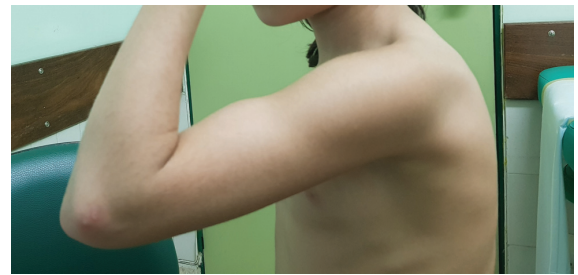**Fig. 2** Ecchymosis in the antecubital fossa.



**Fig. 3** Closed reduction and fixation with two percutaneous Kirschner wires.



**Fig. 4** Edema and blistering of the skin 48 hours postoperatively.



**Fig. 5** Range of motion at three months of follow-up.

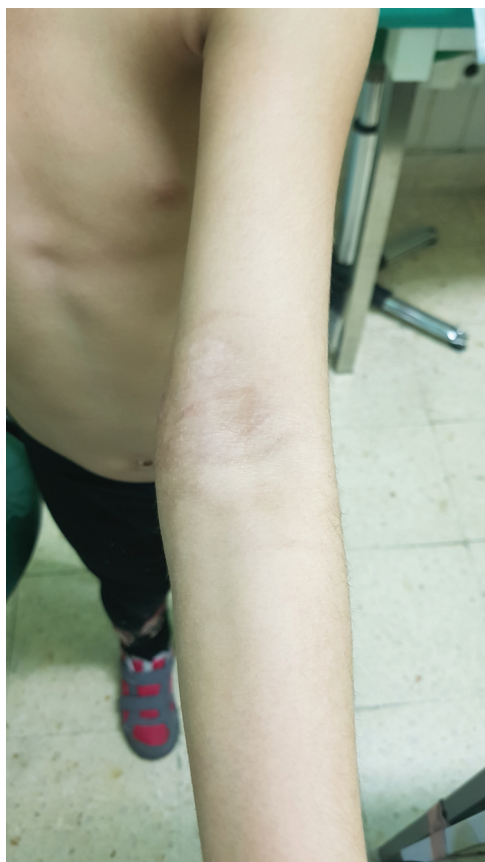At 48 hours following surgery, there was persistent pain and progressive tender edema with skin blistering (► **Fig. 4**). The peripheral pulses were normal, and there was no pain exacerbation, with passive mobilization of the fingers. After excluding compartment syndrome, a venous duplex ultrasonography was performed, which revealed deep venous thrombosis (DVT) of the humeral vein.

Treatment with 20 mg of subcutaneous low-molecular-weight heparin was initiated and maintained for 3 months. One week after surgery, the child was pain-free, with edema improvement, and was discharged from the hospital. At 3 months of follow-up, the fracture had healed, and the elbow had full range of motion ( $0^{\circ}$  to  $120^{\circ}$ ), without additional skin or vascular complications (► **Figs. 5** and **6**). There were no embolic events. The studies conducted were negative for thrombophilia.

## Discussion

The management of supracondylar fractures of the humerus can be demanding. Early complications include damage to neurovascular or muscular structures and compartment syndrome.<sup>9</sup> Neurological injuries, most frequently in the form of neuropraxia, are common (~20%), affecting mostly the median nerve and its anterior interosseous branch.<sup>3,9</sup> The most disastrous injuries are vascular, for, when left untreated, they can lead to neurologic deficits, muscle stiffness or Volkmann ischemic contractures.<sup>9</sup> Hardware-related complications and malunion sequelae are usually later events.<sup>9</sup>

According to the literature, pediatric trauma patients have a prevalence of VTE of 0.3 to 0.8 for every 1,000 trauma discharges.<sup>7</sup> In addition, emergent or urgent surgeries are more likely to result in VTE than elective procedures.<sup>6</sup>



**Fig. 6** Intact skin and full extension at three months of follow-up.

For the diagnosis, clinical suspicion is needed and a detailed vascular examination is crucial, with assessment of pulses, temperature of the limb, capillary return and pulse oximetry.<sup>3</sup> The use of intraoperative or postoperative ultrasound is also helpful to assess the patency of the vessels.<sup>4</sup> In some cases, pulse oximetry waveform can be used to determine the need for vascular exploration.<sup>10</sup>

The sequelae of VTE, namely postthrombotic syndrome, death, and the risk of recurrence have not been fully investigated in children.<sup>5</sup> The morbidity of DVT depends on the location and severity of the injury, inducing mainly pain and swelling when in the extremities.<sup>5</sup>

In children, VTE is associated with increased mortality, particularly among the younger patients, and it varies from 1% to 8%.<sup>5,6</sup> Guzman et al.<sup>7</sup> searched for an association between VTE and mortality in children, and they concluded that patients with upper-limb fractures and VTE had the highest overall mortality rate (6.4%). This increased mortality is thought to be due to a delay in diagnosis and treatment (owing to a lower index of suspicion) and/or because of the anatomical proximity of the upper-extremity veins to the right-sided chambers of the heart.<sup>7</sup>

The rationale to identify the groups at risk of developing VTE among children is to prevent death secondary to pulmonary embolism.<sup>7</sup> Currently, there is no consensus for thromboprophylaxis in the pediatric field, nor risk-stratification for VTE.<sup>5,6</sup>

Given the rare incidence of VTE in this age group, delays in diagnosis are frequent. In the case herein reported, the

edema, skin coloration and blistering were crucial to raise suspicion. So far, there are many studies focusing on arterial and nervous complications, but none about venous thromboembolism in this setting.

The aim of the present case report is to raise attention to a rare vascular complication of a humeral supracondylar fracture. To our knowledge, the present is the first report of this complication.

All orthopedic surgeons must be aware of the existence of upper-extremity DVT to make an early diagnosis.

We, therefore, recommend a detailed neurovascular examination before and after surgery, and, if the clinical suspicion is high, an evaluation with Doppler sonography.

#### Ethics Statement

The present study was performed in compliance with the World Medical Association's Declaration of Helsinki on Ethical Principles for Medical Research Involving Human Subjects.

#### Financial Support

The authors declare that they have received no financial support for the research, authorship and/or publication of the present article.

#### Conflict of Interests

The authors have no conflict of interests to declare.

#### References

- Claireaux H, Goodall R, Hill J, et al. Multicentre collaborative cohort study of the use of Kirschner wires for the management of supracondylar fractures in children. *Chin J Traumatol* 2019;22(05):249–254
- Saarinén AJ, Helenius I. Paediatric supracondylar humeral fractures: the effect of the surgical specialty on the outcomes. *J Child Orthop* 2019;13(01):40–46
- Leiblein M, Lustenberger T, Schulz A-K, Schmitz-Rixen T, Marzi I. Neurovascular complications after supracondylar humerus fractures in children. *Trauma Case Rep* 2017;8:16–19
- Louahem D, Cottalorda J. Acute ischemia and pink pulseless hand in 68 of 404 Gartland type III supracondylar humeral fractures in children: Urgent management and therapeutic consensus. *Injury* 2016;47(04):848–852
- Mahajerin A, Croteau SE. Epidemiology and Risk Assessment of Pediatric Venous Thromboembolism. *Front Pediatr* 2017;5:68
- Baker D, Sherrod B, McGwin G Jr, Ponce B, Gilbert S. Complications and 30-day outcomes associated with venous thromboembolism in the pediatric orthopaedic surgical population. *J Am Acad Orthop Surg* 2016;24(03):196–206
- Guzman D, Sabharwal S, Zhao C, Sabharwal S. Venous thromboembolism among pediatric orthopedic trauma patients: a database analysis. *J Pediatr Orthop B* 2018;27(02):93–98
- O'Brien SH, Candrilli SD. In the absence of a central venous catheter, risk of venous thromboembolism is low in critically injured children, adolescents, and young adults: evidence from the National Trauma Data Bank. *Pediatr Crit Care Med* 2011;12(03):251–256
- Tomaszewski R, Wozowicz A, Wysocka-Wojakiewicz P. Analysis of Early Neurovascular Complications of Pediatric Supracondylar Humerus Fractures: A Long-Term Observation. *BioMed Res Int* 2017;2017:2803790
- Soh RCC, Tawng DK, Mahadev A. Pulse oximetry for the diagnosis and prediction for surgical exploration in the pulseless perfused hand as a result of supracondylar fractures of the distal humerus. *Clin Orthop Surg* 2013;5(01):74–81