

Financiamento: Inexistente
 Conflito de interesses: Inexistente

Referências

1. Aggege S. Sem hospícios, morrem mais doentes mentais. *O Globo*, Rio de Janeiro. 2007 09 dez/set; Seção O País: 14.
2. Datasus. *Informações de Saúde: Estatísticas vitais - mortalidade e nascidos vivos*. citado 10 dez 2007. Disponível em: <http://www.datasus.gov.br>.
3. Laurenti R, Mello Jorge MHP, Gotlieb SLD. A confiabilidade dos dados de mortalidade e morbidade por doenças crônicas não-transmissíveis. *Cienc Saude Coletiva*. 2004;9(4):909-20.
4. Mello Jorge MHP, Gotlieb SLD, Laurenti R. O sistema de informações sobre mortalidade: problemas e propostas para o seu enfrentamento I — Mortes por causas naturais. *Rev Bras Epidemiol*. 2002;5(2):197-211.
5. Sampaio ALP, Caetano D. Mortalidade em pacientes psiquiátricos: revisão bibliográfica. *J Bras Psiquiatr*. 2006;55(3):226-31.

Selective mutism and the anxiety spectrum – a long-term case report

Mutismo seletivo e o espectro da ansiedade – relato de um caso de longa evolução

Dear Editor,

Selective mutism (SM) is a disorder characterized by inability to talk in specific situations, despite of being able to talk in familiar places. With a prevalence of 0.3%-1% in school-age children,^{1,2} most cases (79%) start at preschool age and have transitory course.^{3,4} Psychotherapeutic interventions and selective serotonin reuptake inhibitors are considered first and second line treatments, respectively.^{1,5}

We report a case of SM in a 17-year-old girl whose symptoms started when she was 4 years old and have persisted during adolescence. She stopped talking to everyone after a haircut. She panicked every time her mother went out or when she was left at school. She didn't talk for 45 days, and then progressively recovered, talking first to her sisters, then to other relatives.

One year later, she stopped talking again after her bike had been stolen. Three months later, she started to chat with relatives and two close friends. She hasn't talked to anyone else since then. Despite this fact, she regularly goes to school and has friends of her age, with whom she communicates through e-mails and mimics. Neither academic nor cognitive impairment have been detected along all school years. She likes to dance and to play handball. When she needs something that requires talking, her mother does it on her behalf, which prevents her from being exposed and increases avoidance of anxiety situations.

According to DSM-IV criteria, a diagnosis of SM was made. Assessed through a semi-structured interview (Schedule for affective disorders and schizophrenia for school-age children,

K-SADS), she met diagnostic criteria for Separation Anxiety Disorder (in the past), current diagnosis of Specific Phobia. She didn't have any other anxious (including social anxiety), affective or psychotic symptoms.

Before her referral, she was treated with psychodynamic therapy and took paroxetine (20 mg/daily) for 12 months without improvement. At our service, she was treated with cognitive-behavioral therapy (CBT) for 10 months with poor outcome. Then, CBT was associated with sertraline (150 mg/daily). After 3 months, the level of anxiety on CBT exposures lowered. She started to shout when playing handball, she talks louder to her mother in public places, and talks to friends through lips movements. Though she isn't talking to many people yet, she is clearly less anxious.

There is some controversy whether SM is an anxiety disorder (AD) or an independent diagnosis. Previously, SM was considered an oppositional behavior, a psychotic symptom or a dissociative disorder. In DSM-IV, SM is classified under Other Disorders of Childhood. SM has many aspects in common with AD: pre-morbid temperament (shyness, behavioral inhibition), parent-child overdependence, overlapping diagnoses with other AD (social phobia, separation anxiety), and high prevalence of parents with AD.⁵ Some authors propose that SM is an extreme manifestation of social phobia.² Our patient denied having social anxiety in situations that don't involve talking, but other anxiety symptoms were observed, such as early manifestation of separation anxiety, supporting the hypothesis that SM should be considered an anxiety spectrum disorder.

Although genetic, behavioral, psychodynamic and family factors must be considered, the etiology of SM remains unknown.¹ The available options for clinical treatment are based on open-label studies, case reports and clinical experience.^{3,5} This case has shown a better outcome when biological and psychotherapy interventions were associated, which may indicate a field for future researches. Having SM as a subcategory of AD may benefit its comprehension, not only as a symptom, but as a unique disorder with its own characteristics.

Gizela Turkiewicz, Lilian Lerner Castro,
 Marcia Morikawa, Carolina Zadrozny Gouvêa da Costa
 Serviço de Psiquiatria da Infância e Adolescência,
 Psychiatry Institute, Universidade de São Paulo (USP),
 São Paulo (SP), Brazil

Fernando Ramos Asbahr
 Serviço de Psiquiatria da Infância e Adolescência,
 Psychiatry Institute, Universidade de São Paulo (USP),
 São Paulo (SP), Brazil
 Department of Psychiatry, Universidade de São Paulo
 (USP), São Paulo (SP), Brazil

Financial support: None
 Conflict of interests: None

References

1. Anstendig K. Selective mutism: a review of the treatment literature by modality from 1980-1996. *Psychotherapy*. 1998;35(3):381-91.
2. Yeganeh R, Beidel DC, Turner SM, Pina AA, Silverman WK. Clinical distinctions between selective mutism and social phobia: an investigation of childhood psychopathology. *J Am Acad Child Adolesc Psychiatry*. 2003;42(9):1069-75.
3. Schwartz RH, Freedy AS, Sheridan MJ. Selective mutism: are primary care physicians missing the silence? *Clin Pediatr*. 2006;45(1):43-8.
4. Black B, Uhde TW. Psychiatric characteristics of children with selective mutism: a pilot study. *J Am Acad Child Adolesc Psychiatry*. 1995;34(7):847-56.
5. Anstendig KD. Is selective mutism an anxiety disorder? Rethinking its DSM-IV classification. *J Anxiety Disord*. 1999;13(4):417-34.

Poststroke manic symptoms: an unusual neuropsychiatric condition

Sintomas maniformes pós-AVC: uma condição neuropsiquiátrica infreqüente

Dear Editor,

Recently, we have published a case report describing a patient with history of manic behavior that started three weeks after a right medial frontal lobe stroke that was successfully managed with valproic acid.¹

Our Department of Psychiatry has evaluated a second case with poststroke hypomania symptoms.

A 57-year-old Caucasian man, married, salesman, with a 15-year history of hypertension and diabetes was admitted to our ward with occasional episodes (six per month) of irritability, emotional lability, reduced sleep need, rapid speech and thoughts. Each episode lasted for two days approximately. These symptoms had begun after a severe case of stroke affecting his right temporal-parietal lobe with unspecific lesions in the white matter in both hemispheres eight months before the admission. Magnetic resonance scan was carried out soon after the stroke and showed an area at the right temporal-parietal lobe compatible with stroke and few chronic ischemic lesions widespread throughout the white matter (Figure 1).

Although he did not fulfilled clinical criteria for manic episode according to DSM-IV-TR, his Young Mania Rating Scale (YMRS) classification was 21 (range 0-20) during one of the episodes. No previous history of any psychiatric disorder, including mood or substance use disorders, could be evidenced.

A neurological examination was performed whereas he scored 28 out of 30 in the Folstein Mini-Mental State Examination. No cognitive deficits were observed.

Laboratory work-up, including complete blood count, creatine kinase level, electrolytes, renal, liver and thyroid function tests, serology for syphilis and HIV were unrevealing.

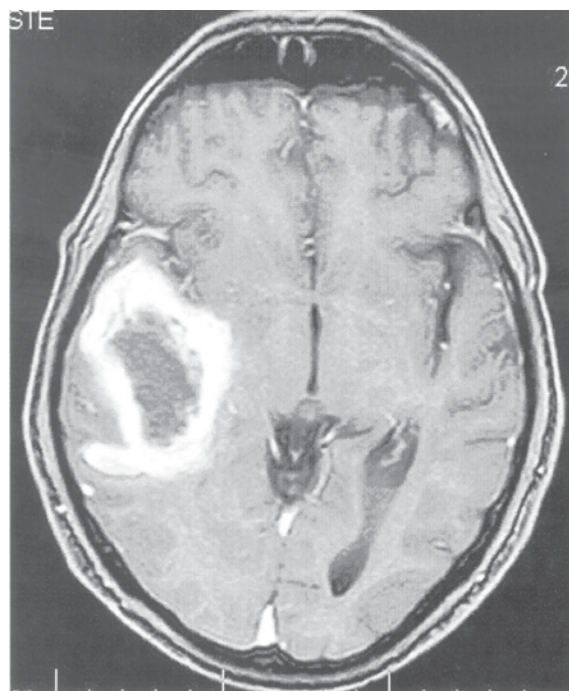


Figure 1 - NMR showing stroke affecting mainly the right temporal lobe

Valproic acid (750 mg/day) was initiated with good improvement of his symptoms (YMRS scoring 10 during "mood episodes"; serum level of valproic acid was 79.0 $\mu\text{g/ml}$).

Discussion: Some papers discuss a probable correlation between mania episodes after right hemisphere lesions, mainly in right orbitofrontal and basotemporal cortices, the dorsomedial thalamic nucleus and the head of the caudate nucleus.¹⁻³

In our patients, both presented symptoms of mania after a stroke that affected the right portion of the brain. Despite the two cases, classic poststroke mania syndrome is not frequently observed, and the major hypothesis for this is that it takes more than one area with a dysfunction to make this occur. Also, an increase in serotonin receptor binding on the right hemisphere, caused by stroke event, may explain why mania episodes are always related to injuries on the right lobe of the brain.¹⁻³

It has also been discussed a connection between the white matter hyperintensities (WMH) lesions in poststroke mania cases, including our cases. These could be a result from vascular cerebral tissue insults and there is also accumulated evidence supporting a role of WMH in the pathophysiology of adult-onset bipolar disorder.⁴

There are some drugs used for the treatment of this condition, like olanzapine, lithium, carbamazepine and valproic acid. In both our cases, the last one had the most successful result. Perhaps, mood stabilizing anticonvulsants may be the agents of choice in the treatment of secondary mania, besides the propensity for seizures in the poststroke period.¹⁻³

Felipe Filardi da Rocha

Psychiatric Service, School of Medicine,
Universidade Federal de Minas Gerais (UFMG),