


Anne Karoline Santos<sup>1</sup> , Jaqueline Silveira<sup>1</sup>, Valéria Cabral Neves<sup>2</sup>, Talita Gianello Gnoato Zotz<sup>3</sup>, Arlete Ana Motter<sup>3</sup>, Marimar Goretti Andrezza<sup>4</sup>

# Atelectasis and lung changes in preterm neonates in the neonatal period: a blind radiological report and clinical findings

*Atelectasia e alterações pulmonares em recém-nascidos prematuros no período neonatal: laudo radiológico cego e achados clínicos*

1. Child and Adolescent Medical Care Program, Complexo Hospital de Clínicas, Universidade Federal do Paraná - Curitiba (PR), Brazil.  
2. Pediatric Intensive Care Unit, Complexo Hospital de Clínicas, Universidade Federal do Paraná - Curitiba (PR), Brazil.  
3. Course of Physiotherapy, Universidade Federal do Paraná - Curitiba (PR), Brazil.  
4. Neonatal Intensive Care Unit, Complexo Hospital de Clínicas, Universidade Federal do Paraná - Curitiba (PR), Brazil.

**Conflicts of interest:** None.

Submitted on December 13, 2018

Accepted on May 5, 2019

## Corresponding author:

Anne Karoline Santos  
Programa de Atenção Hospitalar em Saúde da Criança e Adolescente  
Complexo Hospital de Clínicas da Universidade Federal do Paraná  
Rua General Carneiro, 181 - Alto da Glória  
Zip code: 80060-900 - Curitiba (PR), Brazil  
E-mail: annekaroline@hotmail.com

**Responsible editor:** Werther Brunow de Carvalho

DOI: 10.5935/0103-507X.20190047

## ABSTRACT

**Objective:** To determine the occurrence and characteristics of atelectasis, opacities, hypolucency and pulmonary infiltrates observed on chest X-rays of preterm infants in a neonatal intensive care unit.

**Methods:** This was a cross-sectional observational study. From August to December 2017, all chest radiographs of newborn infants were analyzed. The study included the chest radiographs of preterm neonates with gestational ages up to 36 weeks in the neonatal period that showed clear changes or suspected changes, which were confirmed after a radiologist's report. Radiological changes were associated with possible predisposing factors.

**Results:** During the study period, 450 radiographs were performed on preterm neonates, and 37 lung changes were identified and classified into 4 types: 12 (2.66%) changes were

described as opacities, 11 (2.44%) were described as atelectasis, 10 (2.22%) were described as pulmonary infiltrate, and 4 (0.88%) were described as hypolucency. A higher occurrence of atelectasis was noted in the right lung (81.8%). Among the abnormal radiographs, 25 (67.6%) newborn infants were receiving invasive mechanical ventilation.

**Conclusion:** Considering the radiological report, no significance was found for the observed changes. Atelectasis was not the most frequently observed change. The predisposing factors for these changes were extreme prematurity, low weight, male sex, a poorly positioned endotracheal tube and the use of invasive mechanical ventilation.

**Keywords:** Infant, premature; Thorax/diagnostic imaging; Pulmonary atelectasis; Diagnostic imaging; Premature birth; Intensive care units, neonatal

## INTRODUCTION

Atelectasis is a condition that occurs due to the collapse of alveolar units. One of the main characteristics is a reduction in lung volume, which destabilizes the relationship between ventilation and perfusion and causes pulmonary shunting.<sup>(1)</sup>

Compared to the lungs of an adult, preterm neonates have different physiological and anatomical lung characteristics that predispose them to atelectasis. Due to lung immaturity, the number of alveoli is reduced, with low surfactant synthesis and the absence or underdevelopment of collateral ventilation, resulting in decreased lung compliance. In contrast, the chest cavity has increased compliance due to its cartilaginous structure.<sup>(1-3)</sup>



The main factors that contribute to atelectasis in premature neonates are the use of mechanical ventilation, poor endotracheal tube (ETT) placement, mucus plugs, elective or accidental extubation and diseases such as bacterial pneumonia, bronchopulmonary dysplasia, pleural effusion, respiratory distress syndrome, meconium aspiration syndrome, gastroesophageal reflux and pneumothorax.<sup>(4)</sup>

Typically, atelectasis is visualized on chest radiographs as increased density and decreased volume associated with decreased intercostal spaces, deviation of mediastinal structures, such as the trachea and the heart, elevation of the ipsilateral diaphragm and hyperinflation of the contralateral lung.<sup>(5)</sup> However, technical problems, such as X-ray beam underpenetration and inadequate centralization, compromise the quality of the exam, which may result in nonspecific imaging features described as hypolucency or opacity.<sup>(6,7)</sup>

Another radiological feature frequently observed on the chest X-rays of premature neonates is hypolucency, which may suggest pulmonary edema, hemorrhage, atelectasis or consolidations. Opacities may occur due to lung collapse or pleural effusion and to pulmonary infiltrates attributable to the accumulation of fluid in the interstitial space as a result of some inflammatory process.<sup>(6,8)</sup> However, for an accurate diagnosis, these radiological changes must be associated with other classic signs of the suspected disease.<sup>(4)</sup>

Specific radiological features may appear on a chest radiograph and may affect a lobe, a segment or the entire lung.<sup>(9)</sup> Chest radiography is one of the most commonly used tests to show classic signs of atelectasis, opacities, hypolucency and pulmonary infiltrates. Chest X-ray is an important tool for diagnostic support and clinical evaluation of patients admitted to the intensive care unit (ICU).<sup>(1)</sup>

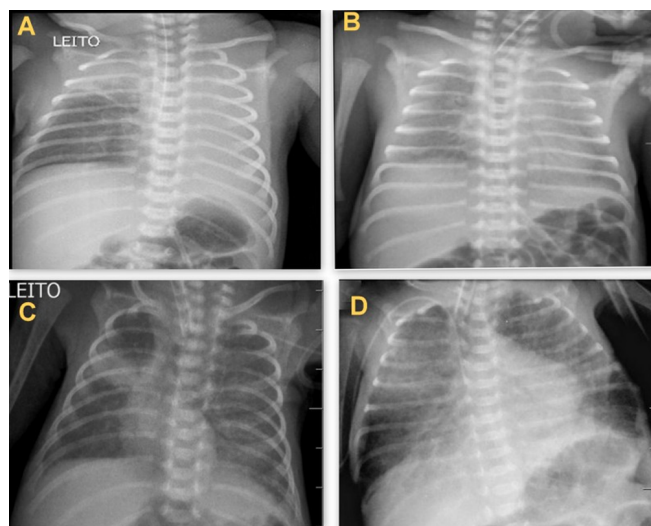
For physiotherapists working in this area, knowledge about the radiological findings specific to each change on chest images and their associated factors is of utmost importance because they provide guidance for determining the most appropriate plan for a patient. As a result, the present study aimed to assess the occurrence and characteristics of atelectasis, opacities, hypolucency and pulmonary infiltrates in preterm infants (PTIs) and to verify these features' locations and possible associated factors.

## METHODS

This is a prospective cross-sectional observational study conducted at a neonatal ICU of a public university hospital from August to December 2017. The project was approved by the Institutional Ethics Committee of the institution according to opinion 2.192.954.

Chest radiographs were performed following the medical referral routine in preterm neonates admitted to the hospital with suspected pulmonary alterations. Data were collected daily. Cases that met the inclusion criteria were selected: chest radiographs of PTIs with a gestational age (GA) up to 36 weeks + 6 days admitted to the neonatal ICU (NICU) during the neonatal period. New cases of lung changes were considered when resolution of the previous change was observed in at least one normal imaging test. Informed consent forms were signed by the parents. The exclusion criteria were radiographs without adequate framing or radiological changes.

Chest radiographs that showed lung changes (Figure 1) were selected and sent to a medical radiologist who analyzed the images and wrote a report blinded to the patient's clinical information to avoid inspection bias and ensure that only the imaging test contributed to the diagnosis.<sup>(10)</sup> Then, data from medical records were collected, such as sex, GA, weight, 5-minute Apgar score, days of life, diagnosis and the use of some type of ventilatory support (invasive or noninvasive) or oxygen therapy.



**Figure 1** - Radiological changes. (A) Atelectasis in the left lobe and right apex of the lung. (B) Diffuse hypolucency. (C) Opacity on the right middle third of the lung. (D) Diffuse pulmonary infiltrates.

The data were entered in a Microsoft Office Excel® spreadsheet, reviewed and exported to Statio Statsoft® statistical software. Subsequently, the data were analyzed by descriptive statistics with the use of the absolute and relative frequencies, means, minimum and maximum values and standard deviation.

## RESULTS

Between August and December 2017, 121 newborns were admitted to the NICU, 82 of whom were PTIs. A total of 713 chest radiographs were performed during this period, including 450 on PTIs, as shown in figure 2.

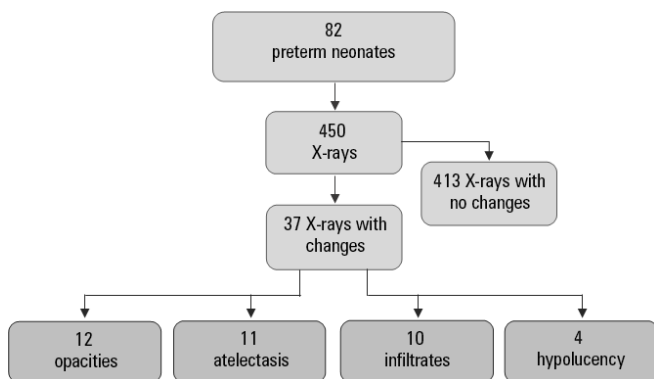


Figure 2 - Flowchart of radiological changes in preterm neonates.

A total of 37 chest radiographs of the NICU patients were evaluated by the medical radiologist during the study. Of these, 12 (32.4%) lung changes were described as opacities, 11 (29.7%) were described as atelectasis, 10 (27%) were described as pulmonary infiltrates, and 4 (10.8%) were described as hypolucency. Considering only the 450 chest X-rays of the PTIs, 2.66% of the lung changes over four months were opacities, 2.44% were atelectasis, 2.22% were infiltrates and 0.88% were hypolucency.

The epidemiological characteristics of the sample and the clinical variables are shown in table 1. The clinical diagnoses of the preterm neonates were divided into two groups: pulmonary and extrapulmonary. Patients admitted due to respiratory distress syndrome and meconium aspiration syndrome were included in the group with pulmonary diseases. Patients admitted due to malformations and neonatal asphyxia were included in the extrapulmonary diagnosis group.

Nine patients exhibited recurrence of the different lung changes observed or even the same change at different periods, with at least one normal chest radiograph between the abnormal images. Two patients showed only one lung change on the chest radiograph during the neonatal period.

The types of ventilatory support that the PTIs received when they exhibited a change on chest X-rays are described in table 2. Of the 25 patients receiving invasive mechanical ventilation (IMV), 14 (56%) had a well-placed endotracheal tube (ETT). Of the 11 (44%) patients in whom the ETT was poorly positioned, 2 (8%) had an electively placed ETT positioned in the right primary bronchus, 3 (12%) had an ETT positioned high (above T1), and 6 (24%) had an ETT positioned low (close to the carina). Some type of lung change was noted in all the radiological exams in which the ETT was poorly positioned. The poorly positioned ETIs were adequately repositioned after chest radiography.

Lung changes were observed in two patients after accidental extubation, one of whom showed opacity while the other showed atelectasis. Two cases of atelectasis were caused by placement of the ETT in the right primary bronchus.

Nine cases of atelectasis were diagnosed in the right lung, one case was diagnosed in the left lung, and one case of bilateral atelectasis (with complete collapse of the left lung and collapse of the right apex) was diagnosed. Of the four X-ray examinations described as hypolucency, hypolucency was observed on the right side in two cases and affected both lungs in the other two cases. Of the ten cases described as pulmonary infiltrates, 8 had bilateral involvement, pulmonary infiltrates affected the middle third of the right lung in one case, and pulmonary infiltrates affected the base of the left lung in one case. Of the 12 cases described as opacities, 7 cases had opacities were on the right side and 5 had bilateral opacities. Regarding the side most frequently affected by the other lung changes, 19 (51.3%) changes were located in a lobe of the right lung, 2 (5.5%) changes affected some segment of the left lung, and 16 (43.2%) changes exhibited changes in some segment on the right and left sides (Table 3).

## DISCUSSION

Pulmonary structural immaturity associated with pulmonary surfactant deficiency often predisposes

**Table 1** - Epidemiological characteristics of the sample and clinical variables

	<b>Atelectasis</b> <b>11 (29.7%)</b>	<b>Hypo-small differences</b> <b>4 (10.9%)</b>	<b>Pulmonary infiltrates</b> <b>10 (27%)</b>	<b>Opacities</b> <b>12 (32.4%)</b>
Gestational age (weeks)	26.0 ± 3.4	27.3 ± 1.5	27.1 ± 1.8	29.6 ± 3.3
Up to 28	7	3	7	5
29 - 32	3	1	3	4
33 - 36	1	-	-	3
Weight (g)	1.390 (506 - 2.620)	1.120 (515 - 1.390)	637 (485 - 1.150)	931 (515 - 3.375)
Sex				
Female	3	-	1	7
Male	8	4	9	5
5-minute Apgar score				
8-10	2	2	2	3
3-7	7	1	-	3
0-2	2	1	8	6
Diagnosis				
Pulmonary	5	2	9	3
Extrapulmonary	6	2	1	9
Days of life	14 (1 - 29)	2,5 (1 - 4)	19 (2 - 24)	11 (1 - 28)
< 15	6	4	4	6

n = 37 preterm neonates. The results are expressed as the mean ± standard deviation; n or the median (minimum-maximum).

**Table 2** - Pulmonary radiological changes according to ventilatory support

<b>n = 37</b>	<b>Atelectasis</b> <b>11 (29.7%)</b>	<b>Hypolucency</b> <b>4 (10.9%)</b>	<b>Pulmonary infiltrates</b> <b>10 (27%)</b>	<b>Opacities</b> <b>12 (32.4%)</b>
MV	7	2	9	7
NIV	1	2	-	3
NC	3	-	1	2

MV - mechanical ventilation; NIV - noninvasive ventilation; CN - nasal catheter. The results are expressed as n.

**Table 3** - Locations of pulmonary changes on chest radiographs

	<b>Atelectasis</b> <b>11 (29.7%)</b>	<b>Hypolucency</b> <b>4 (10.8%)</b>	<b>Pulmonary infiltrates</b> <b>10 (27%)</b>	<b>Opacities</b> <b>12 (32.4%)</b>
Right apex	4	-	-	1
Right middle third	2	-	1	1
Right base	-	1	-	5
Total right	3	1	-	-
Left base	-	-	1	-
Total left	1	-	-	-
Bilateral	1	2	8	5

preterm neonates to respiratory function impairment with variable manifestations, such as lung changes.<sup>(11)</sup> However, several associated factors may contribute to the development of these lung changes, such as the use of IMV, poor ETT placement, abdominal muscle weakness, accidental extubation and pulmonary complications during hospitalization.<sup>(4,7)</sup>

In the present study, 22 (59.4%) of the 37 preterm neonates with some lung change in the neonatal period were extremely premature infants with a GA of less than 28 weeks, which corroborates the study by Oliveira et al.<sup>(12)</sup> confirming an association of GA with respiratory diseases and reporting that 50% of premature children developed respiratory complications.

The literature reports that low birth weight and GA are considered determining factors in the evolution of a newborn,<sup>(12)</sup> which is similar to the results of the present sample because most (75.6%) of the preterm neonates weighed less than 1,500g.

Another factor that may have contributed to the appearance of lung changes was the use of IMV as 67.6% of the PTIs exhibiting lung changes on chest radiography were receiving IMV. A study characterizing the profile of preterm neonates in the NICU found that 93.8% of the children had respiratory diseases during hospitalization and 90.1% required IMV.<sup>(12)</sup> This finding is relevant to the present study because respiratory diseases that lead to the need for IMV tend to evolve with the emergence of radiological changes on imaging tests.

Pediatric studies have shown that atelectasis is the most common complication in children undergoing mechanical ventilation.<sup>(7,13,14)</sup> However, in those studies, atelectasis was compared with other clinical diagnoses or complications, such as accidental extubation, and not with changes on chest X-ray images.

In the chest radiographs included in the present study, 12 changes observed were described as opacities, representing the most common lung change. Atelectasis was described in 11 chest radiology images. The literature reports that when diagnosing atelectasis, an increase in local density (opacity) should be observed in the imaging test, indicating that the alveolar units may have collapsed. However, with opacity of a lung segment but no other associated features, atelectasis cannot be confirmed and hypotheses for alveolar collapse cannot be ruled out.<sup>(1)</sup>

Notably, the presence of opacity or atelectasis may correspond to alveolar collapse and loss of alveolar volume. Although most chest radiographs are not confirmed as atelectasis, specific treatments are needed due to signs of decreased aeration, lung volume and lucency on a chest image, such as physical therapy for pulmonary re-expansion, intermittent positive pressure breathing and noninvasive ventilation, to avoid invasive measures such as bronchoscopy and IMV.<sup>(15)</sup>

In a retrospective study evaluating atelectasis in patients under mechanical ventilation, 90% of the patients were found to have partial collapse of the right lung, confirming that the right side is more frequently affected due to the anatomical peculiarities of newborns.<sup>(7)</sup>

Two cases of elective ETT placement were noted, which caused atelectasis of the entire left lung in these PTIs. Elective intubation in newborns often results in ETT placement in the right primary bronchus due to its anatomical position being more straight than the left

primary bronchus in addition to the difficulty associated with properly positioning an ETT due to the size of the airway.<sup>(4,7)</sup>

Lung changes may also occur after episodes of unscheduled extubation. In two patients, the lung changes observed on the chest X-rays after accidental extubation were opacity and atelectasis, which were caused by the abrupt loss of positive airway pressure, leading to pulmonary collapse. In a study evaluating the efficacy of a physical therapy protocol in patients after accidental extubation to prevent pulmonary collapse, approximately 20% of the newborns showed evidence of some degree of nonprogrammed postextubation collapse characterized by increased pulmonary opacity on radiographs within 24 hours after the event.<sup>(16)</sup>

The most common radiological abnormality found in patients receiving mechanical ventilation was pulmonary infiltrates. Sarmiento et al.<sup>(17)</sup> describe that in pulmonary diseases such as acute respiratory distress syndrome, meconium aspiration, pneumonia and bronchiolitis, this radiological change occurs due to an inflammatory process, which leads to collapse of alveolar units and a reduction in lung volume, in addition to causing an increased risk of infection associated with the use of mechanical ventilation.

Limitations of the present study were related to the small size of the sample, which was sampled by convenience. However, this small sample size is justified by the short period of data collection. Another limitation is related to the fact that X-ray is not a gold standard technique for diagnosing pulmonary atelectasis; therefore, the radiological reports suggest a change but do not confirm a diagnosis. Other studies are recommended with a greater number of PTIs and more specialist and nonspecialist examiners to compare the views of those who only evaluate images and those who assess the associations of the imaging features with the patient.

## CONCLUSION

Considering the radiological report, the observed changes showed no significant differences. Atelectasis was not the most frequently found change on the chest radiographs of preterm neonates; opacity was the most frequent finding. However, this finding does not rule out the hypothesis of lung collapse. The side most affected by atelectasis was the right side. Extreme preterm, low-weight male patients under invasive mechanical ventilation and with poorly positioned endotracheal tubes are more likely to develop lung changes that can be observed on chest

radiographs. Recognition of the characteristics of each alteration leads to the most appropriate physiotherapeutic approach for each newborn infant, which may prevent the progression of more severe pulmonary complications.

### Contributions of the authors

Anne Karoline Santos: conception and design of the study, data acquisition, data analysis and interpretation, article writing or critical review of relevant intellectual content, final approval of the version to be submitted.

Jaqueline Silveira: data acquisition and data analysis and interpretation.

Valéria Cabral Neves: analysis and interpretation of the data, article writing and critical review of relevant intellectual content, final approval of the version to be submitted.

Talita Gianello Gnoato Zotz: critical review of relevant intellectual content, final approval of the version to be submitted.

Arlete Ana Motter: critical review of relevant intellectual content, final approval of the version to be submitted.

Marimar Goretti Andreazza: Analysis and interpretation of the data, article writing or critical review of relevant intellectual content, final approval of the version to be submitted.

## RESUMO

**Objetivo:** Verificar a ocorrência e as características de atelectasias, opacidades, hipotransparências e infiltrados pulmonares evidenciados ao raio X de tórax dos recém-nascidos prematuros, de uma unidade de terapia intensiva neonatal.

**Métodos:** Trata-se de estudo observacional transversal. No período de agosto a dezembro de 2017 foram analisadas todas as radiografias de tórax de recém-nascidos. Foram incluídas no estudo as radiografias de tórax de recém-nascidos prematuros com idade gestacional até 36 semanas, no período neonatal que apresentassem alterações evidentes na imagem ou suspeita de alterações, que fossem confirmadas após laudo do médico radiologista. As alterações radiológicas foram associadas com possíveis fatores predisponentes.

**Resultados:** No período, foram realizadas 450 radiografias nos recém-nascidos prematuros, sendo que, em 37, foram

descritas quatro alterações: 12 (2,66%) descritas como opacidades, 11 (2,44%) como atelectasias, 10 (2,22%) como infiltrados pulmonares e 4 (0,88%) como hipotransparências. Observou-se maior ocorrência das atelectasias no pulmão direito (81,8%). Dentre as radiografias com alterações, 25 (67,6%) recém-nascidos estavam sob o uso da ventilação mecânica invasiva.

**Conclusão:** Considerando o laudo radiológico, as alterações observadas têm ocorrências sem diferença estatisticamente significativa. A atelectasia não foi a alteração mais encontrada. Os fatores que podem ter predisposto ao aparecimento das alterações foram a prematuridade extrema, o baixo peso, o sexo masculino, o mal posicionamento da cânula endotraqueal e o uso de ventilação mecânica invasiva.

**Descritores:** Recém-nascido prematuro; Tórax/diagnóstico por imagem; Atelectasia pulmonar; Diagnóstico por imagem; Nascimento prematuro; Unidades de terapia intensiva neonatal

## REFERENCES

- Johnston C, Carvalho WB. Atelectasias em pediatria: mecanismos, diagnóstico e tratamento. *Rev Assoc Med Bras.* 2008;54(5):455-60.
- Peroni DG, Boner AL. Atelectasis: mechanisms, diagnosis and management. *Paediatr Respir Rev.* 2000;1(3):274-8.
- Tauil KA. Comportamento das propriedades mecânicas do sistema respiratório em neonatos, lactentes e crianças saudáveis. *Pediatr Mod.* 2013;49(2).
- Alvares BR, Pereira IM, Mezzacappa MA, Stopiglia MS, Pires CS. Pulmonary atelectasis in newborn infants: etiology and radiological aspects. *Sci Med (Porto Alegre).* 2012;22(1):43-52.
- Sarmento GJ, Peixe AA, Carvalho FA. *Fisioterapia respiratória em pediatria e neonatologia.* 2a ed. São Paulo: Manole; 2011.
- Alvares BR, Pereira IC, Araújo Neto AS, Sakuma ET. Achados normais no exame radiológico de tórax do recém-nascido. *Radiol Bras.* 2006;39(6):435-40.
- Dominguez MC, Alvares BR. Atelectasia pulmonar em recém-nascidos com doenças clinicamente tratáveis submetidos a ventilação mecânica: aspectos clínicos e radiológicos. *Radiol Bras.* 2018;51(1):20-5.
- Pryor JA, Webber BA, editores. *Fisioterapia para problemas respiratórios e cardíacos.* 2a ed. Rio de Janeiro: Guanabara Koogan; 2002.
- Oliva Hernández C, Lopez de Vergara RG, Galván Fernández C, Marrero Pérez CL. Atelectasia. Bronquiectasias [Internet]. Madrid: Asociación Española de Pediatría; 2008. [cited 2019 Jun 7]. Available from: [http://www.aeped.es/sites/default/files/documentos/1\\_4.pdf](http://www.aeped.es/sites/default/files/documentos/1_4.pdf)
- Brasil. Ministério da Saúde. Secretaria de Ciência, Tecnologia e Insumos Estratégicos. Departamento de Ciência e Tecnologia. Diretrizes metodológicas: Elaboração de revisão sistemática e metanálise de estudos de acurácia diagnóstica [Internet]. Brasília: Ministério da Saúde; 2014. [citado 2018 Set 28]. Disponível em: [http://bvsm.s.saude.gov.br/bvs/publicacoes/diretrizes\\_metodologicas\\_estudos\\_acuracia\\_diagnostica.pdf](http://bvsm.s.saude.gov.br/bvs/publicacoes/diretrizes_metodologicas_estudos_acuracia_diagnostica.pdf)
- Barbosa AR. Consequências da prematuridade no sistema respiratório [dissertação]. Portugal: Faculdade de Medicina, Universidade de Coimbra; 2015.

12. Oliveira CS, Casagrande GA, Grecco LC, Golin MO. Perfil de recém-nascidos pré-termo internados na unidade de terapia intensiva de hospital de alta complexidade. *ABCS Health Sci.* 2015;40(1):28-32.
13. Torres-Castro C, Valle-Leal J, Martínez-Limón AJ, Lastra-Jiménez Z, Delgado-Bojórquez LC. Complicaciones pulmonares asociadas a ventilación mecánica en el paciente neonatal. *Bol Med Hosp Infant Mex.* 2016;73(5):318-24.
14. Principi T, Fraser DD, Morrison GC, Farsi SA, Carrelas JF, Maurice EA, et al. Complications of mechanical ventilation in the pediatric population. *Pediatr Pulmonol.* 2011;46(5):452-7.
15. Johnston C, Zanetti NM, Comaru T, Ribeiro SN, Andrade LB, Santos SL. I Recomendação brasileira de fisioterapia respiratória em unidade de terapia intensiva pediátrica e neonatal. *Rev Bras Ter Intensiva.* 2012;24(2):119-29.
16. Bagley CE, Gray PH, Tudehope DI, Flenady V, Shearman AD, Lamont A. Routine neonatal postextubation chest physiotherapy: a randomized controlled trial. *J Paediatr Child Health.* 2005;41(11):592-7.
17. Sarmento GJ, Papa DC, Raimundo RD. Princípios e práticas de ventilação mecânica em pediatria e neonatologia. São Paulo: Manole; 2011. p. 198-211.