

# L-arginine action in cutaneous flap evolution under nicotine exposure in rats

## *Ação da L-arginina na evolução de retalhos cutâneos de ratos sob exposição à nicotina*

MARCUS VINICIUS THOMÉ NORA GUIMARÃES<sup>1</sup>; GUILHERME HENRIQUE GONÇALVES MOREIRA<sup>2</sup>; LUANA PARMINONDI ROCHA<sup>2</sup>; JOÃO EDUARDO LEAL NICOLUZZI TCBC-PR<sup>3</sup>; CARLOS JOSÉ FRANCO DE SOUZA TCBC-PR<sup>3</sup>; JOÃO CARLOS DOMINGUES REPKA<sup>4</sup>

### A B S T R A C T

**Objective:** To evaluate whether treatment with L-arginine influences the healing of skin flaps in rats exposed to nicotine. **Methods:** 40 male Wistar rats weighing  $142.4 \pm 10.1$  g were separated into four groups: GC: treatment with 7.4 pH phosphate buffer, submitted to skin flap and observation for ten days; GN: exposure to nicotine for four weeks, submitted to skin flap and observation for ten days; GA: treatment with 7.4 pH phosphate buffer for four weeks, submitted to skin flap and arginine treatment for ten days; GAN: exposure to nicotine for four weeks, submitted to skin flap and treatment with arginine for ten days. We evaluated: areas of necrosis, re-epithelialization, inflammatory reaction and formation of granulation tissue by HE stain; the total area of deposition and differentiation of collagens I and III by histometry with picrosirius staining; and the scar vascular density by immunohistochemical staining with monoclonal anti-CD34 antibodies. **Results:** The percentages of necrotic areas in GN and GNA were higher ( $p < 0.001$ ) than in GC and GA. In histological scores, collagen deposition, and the percentage of type I collagen, GA and GC were similar to each other ( $p > 0.05$ ), but higher ( $p < 0.001$ ) than GA and GNA; as for vascular densities, they were lower in GN and GAN ( $p < 0.001$ ) than in GC and GA. **Conclusion:** Exposure to nicotine inhibited the effects of arginine and in unexposed rats there was induction of angiogenesis and improvement in the total collagen deposition in the skin flaps.

**Key words:** Nicotine. Arginine. Collagen. Wound healing. Free tissue flaps

### INTRODUCTION

Smoking is identified as the leading cause of preventable death in the world, and in Brazil it is estimated that 22.4% of the population are smokers<sup>1</sup>. The smoking habit is given as a cause of healing changes secondary to the harmful effects of nicotine on the vasculature, especially in skin flaps. Alternatives to avoid these effects have been the subject of scientific research<sup>2</sup>.

Wound healing is a dynamic process involving biochemical and physiological phenomena<sup>3</sup>. In this context, experimental studies have shown that arginine dietary supplementation in rats increases the tensile strength of healing injured tissue and collagen deposition<sup>4,5</sup>.

Arginine, a semi-essential amino acid, the precursor of nitric oxide, ornithine and proline among other molecules, is recruited in the acute and chronic phases of healing. The catabolism of arginine in healing wound occurs

by two main routes, the isoenzymes, which synthesize nitric oxide, and the two arginase isoenzymes<sup>6</sup>.

The influence of nicotine on the impaired relaxation of endothelium in the pathogenesis of ischemic skin flaps and the potential use of nitric oxide precursor for the prevention or treatment of these ischemic processes have been described<sup>7,8</sup>.

Thus, L-arginine stands out as a physiological precursor in nitric oxide synthesis<sup>2,9</sup>. Considering the anti-angiogenic effect induced by smoking habit and the search for alternatives that can provide smokers with a better postoperative healing condition from the angiogenic standpoint, and also considering the effect of nitric oxide as an arginine catabolite to stimulate angiogenesis, this study aims to evaluate whether treatment with arginine in rats previously exposed to nicotine and making undergoing skin flaps, influences angiogenesis in the healing process of these flaps.

Work done at the Post-Graduation Program in Surgery at the Pontifical Catholic University of Paraná, Curitiba, Paraná Sate - PR, Brazil.

1. MSc Graduate, Post-Graduation Program in Surgery, Pontifical Catholic University of Paraná; 2. Resident, General Surgery, Angelina Caron Hospital, Campina Grande do Sul, Paraná; 3. Staff, General Surgery and Transplants Service, Angelina Caron Hospital, Campina Grande do Sul, Paraná; 4. Coordinator, Education and Research, Angelina Caron Hospital, Campina Grande do Sul, Paraná.

## METHODS

We used 40 Wistar rats (*Rattus norvegicus*, Rodentia Mammalia), not inbred, weighing  $142.4 \pm 10.1$  g, obtained from the animal house of the Universidade Federal do Paraná. The sample was split into four groups of five (Table 1). The animals were kept in polypropylene boxes suitable for the species and maintained in specific environment with controlled temperature and humidity under illumination cycles automatically set every 12 hours. They received a chow specific to the species and water ad libitum. The project was approved by the Ethics Committee for Animal Research of Angelina Caron Hospital under Protocol 018/09.

The rats in groups N and NA (Table 1) were exposed to nicotine at a dose of 2mg/kg/day in two daily subcutaneous inoculations of 1mg/kg, with an interval of 12 hours. Nicotine (SIGMA® - 5260 N) was used in 20% aqueous solution, prepared in pH 7.4 phosphate buffer and sterilized by filtration through MF membranes (Millipore-membrane SCWP304F0 Millipore®)<sup>10-12</sup>.

The treatments with L-arginine were daily and subcutaneously performed in rats of Groups A and NA (Table 1), at a dose of 300mg/kg/day<sup>13</sup>. L-arginine (Merck®) was diluted to 20% in pH 7.4 phosphate buffer and sterilized by MF membrane filtration.

Treatments with pH 7.4 phosphate buffer were performed daily and subcutaneously in rats of groups C, A and N (Table 1), in doses equivalent to the weights. We used pH 7.4 phosphate buffer solution, sterilized by MF membrane filtration.

For surgery, rats were anesthetized intramuscularly with the combination of 100mg/kg of ketamine hydrochloride and 10mg/kg of xylazine hydrochloride. After shaving the dorsal region and performing antisepsis with iodine alcohol, we proceeded to mark the rectangular area of the flap, which extended 8cm in caudal direction from the inferior angle of the scapula, with a width of 4cm. Incision was made involving the skin and subcutaneous tissue of the right, left and caudal edges of the flap marking. The area of skin was dissected and

then repositioned in its original bed and fixed with eight symmetrically distributed 6.0 monofilament nylon stitches<sup>10,11</sup>. Daily dressings on the back of the animals were performed for ten days to protect the flaps.

Quantification of the skin flap necrosis area occurred with animals sedated with inhaled halothane. We obtained molds in plastic sheets from the flaps that evidenced the areas of viable vascularized tissue and of necrotic tissue, which were scanned. Then, the images generated were analyzed with the software Paint-Autocad-2002® using standard scales, and flaps planimetric analysis was performed by recording the total area, the area of viable vascularized tissue and the necrotic tissue area, all in square centimeters<sup>10</sup>.

After the death of animals, induced by lethal inhalation of halothane in a closed circuit, we collected three fragments of skin and subcutaneous tissue from the flaps suture areas, identified as BD (right edge), BE (left edge) and BC (caudal edge), which were immediately placed in vials with buffered formalin solution for fixation.

For histological healing evaluation, three samples of each skin flap preparations were subjected to staining method using hematoxylin and eosin (HE) and analyzed according to histological parameters of re-epithelialization, inflammatory reaction and granulation tissue formation. For each parameter a score was established and the result of each sample was the average obtained from the three fragments BD, BE, BC, so that each group of animals had a final score, allowing the classification of groups in three phases of the healing process.

Quantitative evaluation of existing collagen in the suture line of the flap was made by Picrosirius staining to recognize the total density of collagen and collagen fractions I (mature) and III (immature) under the microscope with polarized light, as thicker and strongly birefringent fibers present colored in shades of orange to red (type I collagen) and the finer and dispersed, weakly birefringent fibers are stained in green (collagen III)<sup>14</sup>. For quantitative evaluations images were captured by a camera, transmitted to a color monitor, and digitized. The image analysis was performed using the software Image-Plus® 4.5 for PC. In each cut we

**Table 1 -** Composition of groups.

Groups	Observations
Control	(C) Rats undergoing treatment with pH 7.4 phosphate buffer for four weeks following the making of standardized skin flap and observation for 10 days with pH 7.4. phosphate buffer treatment.
Nicotine	(N) Rats subjected to exposure to nicotine for four weeks followed by making of standardized skin flap and observation for 10 days with pH 7.4. phosphate buffer treatment.
Arginine	(A) Rats undergoing treatment with pH 7.4 phosphate buffer for four weeks following the making of standardized skin flap and observation for 10 days with arginine treatment.
Arginine-Nicotine	(AN) Rats subjected to exposure to nicotine for four weeks followed by making of standardized skin flap and observation for 10 days with arginine treatment.

analyzed the percentage of area occupied by red and yellow (collagen I) and green (collagen III) fibers. For each sample, total area and the percentages of collagen types I and III were obtained by the means of the three fragments BD, BE and BC<sup>15</sup>.

The three samples of each flap were also subjected to immunohistochemical method to search the CD34 marker as a parameter for evaluating the healing vascular density<sup>15</sup>. We employed the anti-CD34 monoclonal antibody, clone QBEnd10 (Dako®) and the counts were performed in areas with the highest number of capillaries and small venules in three distinct fields using magnification of 200X. For counts of microvessels we considered cells stained brown, both isolated and grouped. For each sample the healing vascular density was established by averaging the three fragments BD, BE and BC.

The evaluation of the normal distribution of the results was performed using the Kolmogorov-Smirnov test and expressed as mean  $\pm$  standard deviation. The variables were tested by analysis of variance (ANOVA) and p values  $<0.05$  were considered statistically significant.

## RESULTS

Groups nicotine (GN) and arginine-nicotine (GNA) showed percentages of  $23.7 \pm 7.7$  and  $17.4 \pm 7.1$  for areas of necrosis, being significantly higher than the control group (CG), which showed  $7.1 \pm 3\%$ . The arginine group had necrosis areas of  $6.5 \pm 3.1\%$  and did not differ from the control group (Figure 1).

The analysis of the mean scores of histological evaluations of the skin flaps showed that the control groups and the ones treated with arginine had similar scores on the criteria re-epithelialization ( $p > 0.05$ ), inflammation ( $p > 0.05$ ) and formation of granulation tissue ( $p > 0.05$ ), whose scores were significantly higher than those observed in groups of rats exposed to nicotine (GA) and exposed to nicotine and treated with arginine (Figure 2).

The evaluation of collagen synthesis demonstrated by means of histometric evaluations of the total areas of collagen, representing the right, left and caudal edges of the skin flap samples, were significantly higher in the control and arginine groups than the average observed in the groups of rats exposed to Nicotine (GA) and exposed to nicotine and treated with arginine (Figure 3).

Likewise, the evaluation of Histometric mean mature collagen, representing the right, left and caudal edges of the skin flap samples, were significantly higher in control and arginine groups than the mean observed in groups of rats exposed to nicotine (GA) and exposed nicotine and treated with arginine (Figure 4).

There were significant differences in mean counts of vessels stained by anti-CD34 between right, left and caudal edges between groups. The highlights are the means observed in the caudal edges in all groups studied, which

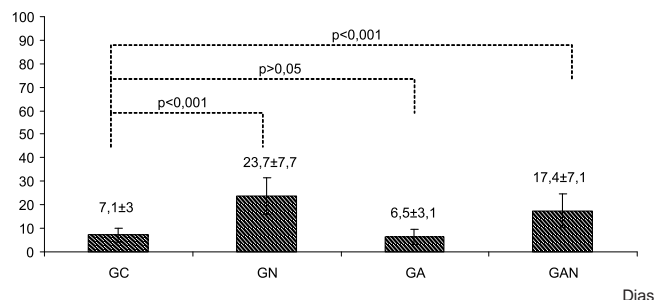


Figure 1 - Means and standard deviations of the percentages of skin flaps necrosis areas.

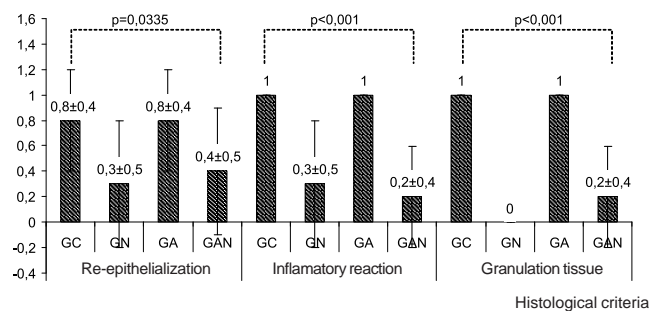


Figure 2 - Means and standard deviations of scores of skin flaps histological findings.

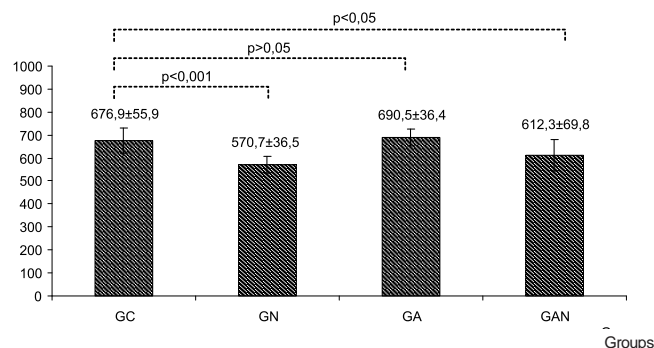
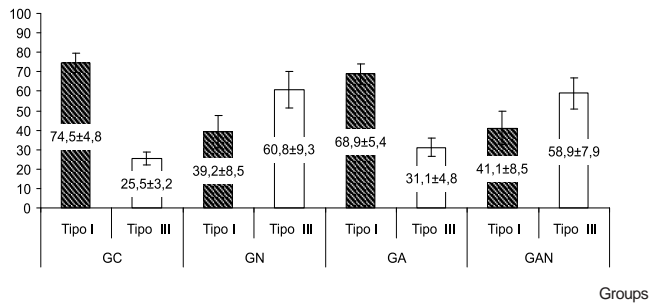


Figure 3 - Means and standard deviations of the total areas of collagens in Mm².

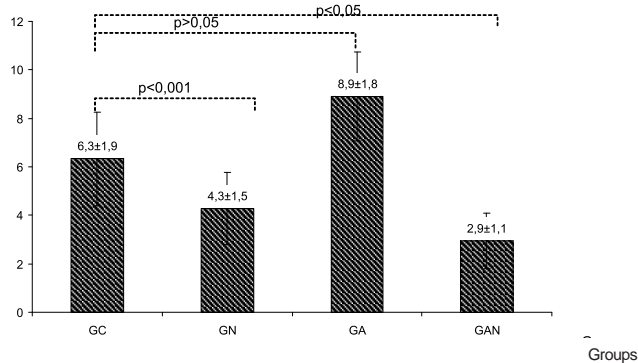
were lower than the averages of the other edges of the flap. In statistical evaluations between the means of fragments BD, BE and BC by groups, it was observed that the GN ( $4.3 \pm 1.5$ ) and GAN ( $2.9 \pm 1.1$ ) groups had significantly lower vessels than the GC ( $6.3 \pm 1.9$ ) and GA ( $8.9 \pm 1.8$ ) (Figure 5).

## DISCUSSION

The deleterious effects of smoking are directly related to the number of cigarettes smoked per day, which determine the daily of nicotine exposure intensity in experimental models<sup>16</sup>.



**Figure 4** - Graphical representation of means and standard deviations of the percentages of collagen types I and III.



**Figure 5** - Graphical representation of means and standard deviations of scores of vessels stained by anti-CD34 monoclonal antibody according to groups.

In this study, the dose of nicotine administered to rats, 2mg/kg for four weeks, was equivalent to high exposure, mimicking heavy smoking<sup>16</sup>.

The theme ischemia and angiogenesis in experimental dorsal skin flap model proposed by Macfarlane<sup>12</sup> is widely used to evaluate other experimental strategies for the improvement of distal necrosis of that flap.

Briefly, in this model are described the effects of antioxidants, such as vitamin C, vitamin E and ginkgo biloba, with less tissue damage and increased neovascularization<sup>17</sup>.

The association of mannitol with Vitamin C reduced, but did not prevent, the occurrence of necrosis<sup>18</sup>. Iontophoresis, as a way of administration of hydralazine hydrochloride, was not effective to increase the viability of the flap, but when associated with histamine by the same route, there was increased viability<sup>19</sup>, the same occurring with minoxidil<sup>20</sup>.

The association between pentoxifylline and buflomedil hydrochloride was assessed on survival of flaps induced in rats exposed to nicotine at doses that produce levels comparable the ones of human smokers. It was found that the association between the drugs improved clinical response with survival of the flaps, and the authors considered the association as effective in reversing the effects caused by nicotine<sup>21</sup>.

The dose of 2mg/kg of nicotine and the subcutaneous administration used in this study were also

used to evaluate the effects of terazosin, a neuroreceptor antagonist, and demonstrated their effectiveness in preventing necrosis, but when combined with propranolol, a beta-blocker, the previous protective effect of necrotic reaction was not observed<sup>22</sup>.

Rates of necrosis in rat dorsal skin flaps of 28.5% in the control group and 45.7% in the group exposed to nicotine for seven days preoperatively and seven days postoperatively were reported in studies with methodologies different from this, as patches were longer and therefore more ischemic, and nicotine exposure was performed by inhalation<sup>23,24</sup>.

In this study, daily treatment with 300mg/kg with arginine during the postoperative period of ten days did not prevent, but mitigated the occurrence of necrosis in rat dorsal flaps in GA (6.5 ± 3.1%) and GAN (17.4 ± 7.1%) groups. The use of arginine in an experimental study with myocutaneous, pedicled dorsal flap was related to the fall on blood concentrations of pyruvate, lactate and ketone bodies on the 14th day. The authors suggested the occurrence of increased utilization of these metabolites by the healing tissues, possibly due to an anabolic action of the L-arginine supply, and concluded that supplementation with L-arginine has effect on serum concentrations of substrates and on cutaneous and muscle healing<sup>25</sup>.

Our explanation for the defective synthesis of collagen in rats exposed to nicotine was that the ischemic flaps exposed to nicotine generated tensions that only allowed fibroblast cell division, since a higher tensions were required for collagen synthesis, This was verified with oral L-Arginine<sup>26</sup>.

In this study there were significant differences between groups in the three histological criteria evaluated: re-epithelialization (p = 0.0335), inflammatory response (p < 0.001) and formation of granulation tissue (p < 0.001).

As for re-epithelialization, in the comparison between pairs of groups there was no significant difference (p > 0.05). The analysis of the inflammatory reaction showed that the GC group showed significantly better results than GN and GAN groups (p < 0.001); the same happened with GA compared to GAN (p < 0.001).

Regarding the formation of granulation tissue, which translates the proliferative phase of wound healing, we observed the same trend as the previous criterion, as GC showed significantly better results than GN and GAN (p < 0.001), the same as GA in relation to GAN (p < 0.001).

Histological alterations in the healing of the skin flaps of rats exposed to nicotine in the present study did not differ from histological findings of other authors<sup>26,27</sup>, ie, there were significant changes in evaluations of the criteria re-epithelialization, inflammatory reaction and formation of granulation tissue. Those authors stressed that the changes described were caused by a decrease in tissue pO<sub>2</sub>, since this decrease is a result of the effects of nicotine, as previously verified that good healing crucially depends on oxygen supply to tissues<sup>27,28</sup>, thus strengthening the

findings of this study, that by making an ischemic flap exposed to nicotine, a known vasoconstrictor, followed by arginine treatment, had mean scores of histologic patterns more similar to those of the control group.

In this study, GC showed an average total collagen significantly higher than GN and GAN ( $p < 0.001$ ). However, there was no difference when compared to GA ( $p > 0.05$ ), whose average was higher than GC's. GN had significantly lower ( $p < 0.001$ ) average than the GA, but similar to GAN ( $p > 0.05$ ). GA showed a significantly higher average than GAN ( $p < 0.01$ ).

The dose of nicotine used by Salles Junior *et al*<sup>10</sup> caused decreased blood flow at more distal points of skin flaps of rats evaluated by the laser flowmetry, and similarly, in the present study it decreased the proportion between the rates of type I and type III collagen.

As for type I collagen, considering the average percentage of the three fragments (BD, BE and BC), in GC it was significantly higher ( $p < 0.001$ ) than in GN and GAN. In GA it was significantly higher than the in GN ( $p < 0.001$ ) and in GAN ( $p < 0.01$ ). Based on these findings, we can infer an effect of arginine.

These statements were reiterated by other authors<sup>26</sup>, who inferred that the collagen deposition, epithelialization and angiogenesis are tissue oxygenation-dependent phenomena. The delayed wound healing observed in the group exposed to nicotine (GN) and exposed to nicotine and treated by L-arginine (GAN) may be explained by decreased proliferation of fibroblasts and macrophages induced by nicotine<sup>2</sup>.

There are few studies that inform healing vascular density in the experimental conditions evaluated in this study, ie, the mean scores of vessels stained by anti-CD34 antibody, between the right, left and caudal borders in the groups assessed. In the caudal of all groups the averages were lower than the other edges of the flap. After the averages of fragments BD, BE and BC were obtained by groups, it was observed that groups GN and GAN had significantly lower average vessels than GC and GA ( $P < 0.001$ ).

It is widely diffused that arginine is a precursor of Nitric Oxide, which has therapeutic properties such as stimulating immune response, aiding in healing process, vasodilation and angiogenesis<sup>29</sup>.

In an experimental study with the method similar to the present study's, in order to evaluate the immunohistochemical staining with anti-CD34 monoclonal antibodies and the influence of L-arginine on microvascular development in the small intestine of early-weaned pigs, it was reported that dietary supplementation with 0.7% L-arginine enhances expression of angiogenic factors in the intestine. However, excessive supplementation of L-arginine (1.2%) induced stress and bowel dysfunction<sup>30</sup>.

Treatment with arginine at a dose of 300mg/kg in the healing of skin flap in rats not exposed to nicotine, displayed induction of angiogenesis and increased total collagen deposition. In rats exposed to nicotine, no effects were observed related with improvement of necrosis, histological pattern, deposition and maturation of collagen and increase in healing vascular density.

## R E S U M O

**Objetivo:** Avaliar se o tratamento com L-arginina influencia a cicatrização de retalhos cutâneos em ratos expostos à nicotina.

**Métodos:** Foram utilizados 40 ratos Wistar pesando  $142,4 \pm 10,1$ g separados em quatro grupos: GC- tratamento com solução tampão fosfatos pH 7,4, confecção de retalho cutâneo, observação por 10 dias; GN- exposição à nicotina por quatro semanas, confecção de retalho cutâneo, observação por dez dias; GA- tratamento com solução tampão fosfatos pH 7,4 por quatro semanas, confecção de retalho cutâneo, tratamento com arginina por dez dias; GAN- exposição à nicotina por quatro semanas, confecção de retalho cutâneo, tratamento com arginina por dez dias. Foram avaliadas as áreas de necrose, re-epitelização, reação inflamatória e formação de tecido de granulação, pela coloração HE, a área de deposição total e a diferenciação de colágenos I e III por histometria com a coloração de picrosírius, e, através da marcação imunistoquímica com anticorpo monoclonal anti-CD34, a densidade vascular cicatricial. **Resultados:** As porcentagens de áreas de necrose de GN e GNA foram maiores ( $p < 0,001$ ) do que GC e GA. Nos escores histológicos, a deposição de colágeno e a porcentagem de colágeno tipo I, no GC e GA foram similares ( $p > 0,05$ ) e maiores ( $p < 0,001$ ) do que em GA e em GNA e, nas densidades vasculares, GN e GAN foram menores ( $p < 0,001$ ) do que em GC e em GA. **Conclusão:** A exposição à nicotina inibiu os efeitos da arginina, e nos ratos não expostos, induziu melhora na angiogênese e na deposição de colágeno total nos retalhos cutâneos.

**Descritores:** Nicotina. Arginina. Colágeno. Cicatrização. Retalhos de tecido biológico.

## REFERENCES

1. Iglesias R, Jha P, Pinto M, Silva VLC, Godinho J. Controle do Tabagismo no Brasil [online]. Washington, DC: Banco Internacional para Reconstrução e Desenvolvimento / Banco Mundial; 2007 [acessado em: out 2011]. Disponível em: <http://portal.saude.gov.br/portal/arquivos/pdf/Controle%20do%20Tabagismo%20no%20Brasil.pdf>
2. Mosely LH, Finseth F, Goody M. Nicotine and its effect in wound healing. *Plast Reconstr Surg.* 1978;61(4):570-5.
3. Mandelbaum SH, Di Santis EP, Mandelbaum MHS. Cicatrização: conceitos atuais e recursos auxiliares – Parte I. *An Bras Dermatol.* 2003;78(4):393-410.

4. Seiffter E, Rettura G, Barbul A, Levenson SM. Arginine: an essential amino acid for injured rats. *Surgery*. 1978;84(2):224-30.
5. Witte MB, Barbul A. General principles of wound healing. *Surg Clin North Am*. 1997;77(3):509-28.
6. Moncada S, Palmer RM, Higgs EA. Nitric oxide: physiology, pathophysiology, and pharmacology. *Pharmacol Rev*. 1991;43(2):109-42.
7. Billiar TR, Simmons R. The therapeutic use of L-arginine to increase nitric oxide production. *Nutrition*. 1992;8(5):371-3.
8. Das UN. L-arginine, nitric oxide and collagen vascular diseases: a potential relationship? *Nutrition*. 1992;8(5):371.
9. Medeiros AC, Lima FP, Dantas Filho AM, Melo NMC, Azevedo IM. A nicotina atua como fator deletério na reparação da parede abdominal. *Acta Cir Bras*. 2003;18(1):19-23.
10. Salles Júnior GS, Melo RCI, Schmidt FR, Grega FH, Dietz U, Araújo U, et al. Avaliação da exposição e interrupção da nicotina em tempos diferentes na evolução de retalho cutâneo ao acaso de dorso de ratos por meio de fluxometria a laser e de picrosirius. *Rev bras cir plast*. 2008;23(4):322-7.
11. McFarlane RM, Deyoung G, Henry RA. The design of a pedicle flap in the rat to study necrosis and its prevention. *Plast Reconstr Surg*. 1965;35:177-82.
12. Campos H, Ferreira LM, Santos WLC, Araújo MCM. Efeitos da nicotina nos retalhos cutâneos em ratos. *Acta Cir Bras*. 2001;16(4):206-10.
13. Shukla A, Rasik AM, Shankar R. Nitric oxide inhibits wound collagen synthesis. *Mol Cell Biochem*. 1999;200(1-2):27-33.
14. Junqueira LC, Cossermelli W, Brentani R. Differential staining of collagen type I, II and III by Sirius Red and polarization microscopy. *Arch Histol Jpn*. 1978;41(3):267-74.
15. Hsu SM, Raine L, Fanger H. Use of avidin-biotin-peroxidase complex (ABC) in immunoperoxidase techniques: a comparison between ABC and unlabelled antibody (PAP) procedures. *J Histochem Cytochem*. 1981;29(4):577-80.
16. Agência Nacional de Vigilância Sanitária (ANVISA). A ANVISA na redução do tabagismo [online]. Brasília, Brasil; 2007. [acessado em: set. 2011]. Disponível em: [http://bvsm.sau.gov.br/bvs/publicacoes/anvisa\\_reducao\\_tabagismo.pdf](http://bvsm.sau.gov.br/bvs/publicacoes/anvisa_reducao_tabagismo.pdf)
17. Pace D, Campos AC, Graf R. Efeito de substâncias antioxidantes (vitamina C, vitamina E e ginkgo biloba) na viabilidade de retalho cutâneo dorsal em ratos. *Rev Soc Bras Cir Plást*. 2006;21(2):77-81.
18. Yoshida WB, Campos EBP. Ischemia and reperfusion in skin flaps: effects of mannitol and vitamin C in reducing necrosis area in a rat experimental model. *Acta Cir Bras*. 2005;20(5):358-63.
19. Esteves Júnior I, Tacani PM, Liggieri VC, Ruggi BG, Ferreira LM, Liebano RE. Histamine iontophoresis on the viability of random skin flap in rats. *Acta Cir Bras*. 2009;24(1):48-51.
20. Bittencourt RC, Biondo-Simões MLP, Paula JB, Martynetz J, Groth A. Influence of minoxidil on ischemic cutaneous flaps in rats. *Acta Cir Bras*. 2005;20(6):450-4.
21. Leal PR, Cammarota MC, Sbalchiero J, Marques MM, Moreira M. Efeitos da pentoxifilina e o cloridrato de buflomedil em retalhos randomizados em ratos sob influência da nicotina. *Rev Soc Bras Cir Plast*. 2004;19(3):31-42.
22. Fonseca AV, Ferreira LM, Gomes HC, Percario S. Terazosin and propranolol as blockers to the deleterious effect of nicotine in a random skin flap in the rat. *Acta Cir Bras*. 2004;19(3):186-95.
23. Kivisaari J, Vihersaari T, Renvall S, Niinikoski J. Energy metabolism of experimental wounds at various oxygen environments. *Ann Surg*. 1975;181(6):823-8.
24. Kaufman T, Eichenlaub EH, Levin M, Hurwitz DJ, Klain M. Tobacco smoking: impairment of experimental flap survival. *Ann Plast Surg*. 1984;13(6):468-72.
25. Penaforte L-RAG, Guimarães SB, Farias RAF, Alves GC, Oliveira TR, Vasconcelos PRC, et al. Efeitos da L-Arginina sobre as concentrações in vivo de metabólitos no sangue e em retalho miocutâneo contendo cicatriz cirúrgica, em ratos wistar. *Rev Bras Cir Plast*. 2003;18(3):61-6.
26. Komorowska-Timek E, Timek TA, Brevetti LS, Szuba A, Stuehlinger M, Hardesty RA, et al. Oral administration of L-arginine decreases necrosis of the epigastric skin flap in the rat. *Ann Plast Surg*. 2004;53(1):73-8.
27. Niinikoski J, Hunt TK, Dunphy JE. Oxygen supply in healing tissue. *Am J Surg*. 1972;123(3):247-52.
28. Murohara T, Asahara T, Silver M, Bauters C, Masuda H, Kalka C, et al. Nitric oxide synthase modulates angiogenesis in response to tissue ischemia. *J Clin Invest*. 1998;101(11):2567-78.
29. Neilly PJ, Kirk SJ, Gardiner KR, Rowlands BJ. The L-arginine/nitric oxide pathway—biological properties and therapeutic applications. *Ulster Med J*. 1994;63(2):193-200.
30. Zhan Z, Ou D, Piao X, Kim SW, Liu Y, Wang J. Dietary arginine supplementation affects microvascular development in the small intestine of early-weaned pigs. *J Nutr*. 2008;138(7):1304-9.

Received on 21/05/2012

Accepted for publication 30/07/2012

Conflict of interest: none

Source of funding: no

#### How to cite this article:

Guimarães MVTN, Moreira GHG, Rocha LP, Nicoluzzi JEL, Souza CJF, Repka JCD. L-arginine action in cutaneous flap evolution under nicotine exposure in rats. *Rev Col Bras Cir*. [periódico na Internet] 2013;40(1). Disponível em URL: <http://www.scielo.br/rcbc>

#### Address for correspondence:

John Carlos Domingues Repka  
Email: [repka@hospitalcaron.com.br](mailto:repka@hospitalcaron.com.br)