

The role of P16^{INK4a} and P53 immunostaining in predicting recurrence of HG-CIN after conization treatment

O papel da expressão imunoistoquímica do P16^{INK4a} e do P53 na predição da recorrência da nic-ag após tratamento por conização

FERNANDA VILLAR FONSECA¹; FLÁVIO DANIEL S. TOMASICH, TCBC-PR²; JULIANA ELIZABETH JUNG³; CARLOS AFONSO MAESTRI¹; NEWTON SÉRGIO DE CARVALHO⁴

A B S T R A C T

Objective: To evaluate the expression of p16^{INK4a} and p53 biomarkers in conization specimens from patients with high grade cervical intraepithelial neoplasia (HG-CIN), correlating them with the ability to predict the recurrence. **Methods:** we conducted a retrospective study of patients with HG-CIN in cervical biopsy treated with conization between January 1999 and January 2006 who had a minimum follow-up of 18 months. The expression of the p16 and p53 was assessed by tissue microarrays and correlated with disease recurrence. For analysis, we used the test of proportions (chi-square), considering value $p \leq 0.05$, 95% CI and calculations of sensitivity, specificity and accuracy of these immunomarkers in predicting recurrence. **Results:** the series comprised 83 patients aged between 16 and 86 years (35 ± 11.7), divided into two groups: 30 with HG-CIN recurrence (study group) and 53 without recurrence (control group). Mean age, parity, smoking and conization technique were similar in both groups. The p53 expression was present in 43% of the study group and 57% of the control group, and the p16 was present in 43% of the study group and in 57% of the control group ($p > 0.05$). p53 had a positive predictive value (PPV) of 42% and negative predictive value (NPV) of 73%, sensitivity 70%, specificity of 47% and accuracy of 59%. The p16, PPV 42%, NPV 72%, sensitivity 66%, specificity of 49% and accuracy of 56%. **Conclusion:** immunohistochemistry expression of p53 and p16 showed low sensitivity and low specificity as predictors of HG-CIN recurrence after conization treatment.

Key words: Cervical Intraepithelial Neoplasia. Conization. Recurrence. Biological Markers.

INTRODUCTION

Cervical cancer still presents itself as a public health problem in Brazil and worldwide, both for its high incidence and for its high morbidity and mortality^{1,2}.

What differentiates this from other cancers is its development from well-defined, pre-invasive lesions, of known behavior and slow evolution, called "cervical intraepithelial neoplasia (CIN)"³.

Apart from the lesion recurrence in the first years of follow-up, women who were treated for CIN 2 or 3 remain at risk of developing carcinoma for a long period⁴.

The recurrence rates after conservative treatment vary between 13% and 26% in the most recent works⁵⁻⁷. It is still not possible to predict which cases of CIN will progress or regress. Regular follow-up by cytology can provide good efficacy by detecting cell changes and thus achieve significant reduction in cervical cancer morbidity and mortality through early diagnosis. However, the cost-effectiveness of this follow-up is still under debate⁸.

The detection of cell changes caused by the unregulated expression of viral oncoproteins appear promising as the characterization of tumor progression markers. Identifying and establishing the changing pattern of these proteins may define markers with high positive predictive power⁴.

The cellular tumor suppressor protein p16^{INK4a} has been identified as a marker of infection by HPV (human papilloma virus). In a transformant HPV infection, E6 and E7 viral oncogenes substantially interfere with apoptosis and cell cycle regulation. Affected cells strongly express p16 to control the activation of the irregular cell cycle, and can be detected by immunohistochemistry^{9,10}.

The protein 53 (p53) is a tumor suppressor protein which in humans is encoded by the TP53 gene¹¹. As the "guardian of the genome", it may stop the cell cycle in response to DNA damage. The HPV E6 viral oncogene modifies the p53 and inactivates it, interfering with cell cycle control¹¹.

1. Serviço de Patologia Cervical do Hospital Erasto Gaertner (HEG), Curitiba, PR, Brasil; 2. Universidade Federal do Paraná (UFPR), Curitiba, PR, Brasil; 3. Serviço de Anatomia-patológica do Hospital Erasto Gaertner (HEG), Curitiba, PR, Brasil; 4. Departamento de Tocoginecologia da Universidade Federal do Paraná.

The importance of p53 inactivation in cervical carcinogenesis has been well documented. However, studies have failed to demonstrate different scores of p53 immunoreactivity in cervical intraepithelial neoplasia and cervical cancer. Conflicting results have also reported the relationship between p53 expression and progression of cervical intraepithelial neoplasia¹².

Few studies have correlated the ability to predict HG-CIN recurrence with the immunohistochemistry expression of tumor proteins^{13,14}.

Given the importance of assessing the role of biomarkers in predicting the progression of HG-CIN injuries, this study aims to evaluate the expression of p16^{INK4a} and p53 in conization specimens from patients with cervical intraepithelial neoplasia using tissue microarrays immunohistochemistry, and correlate their expression with the ability to predict disease recurrence.

METHODS

We evaluated 83 patients with histologically confirmed high grade cervical intraepithelial neoplasia (CIN 2 and 3), which were treated by conization at the Hospital Erasto Gaertner, Curitiba / PR from January 1999 to January 2006.

The patient sample was divided into two groups: Study group (patients with HG-CIN recurrence after conization within a follow-up of 18 months); and Control group (patients with no disease recurrence after conization treatment within the same period).

The study was duly approved by the Ethics in Research Committee of HEG, under Protocol number 1,947.

Sample selection

Inclusion criteria: women followed in the HEG Cervical Pathology Service, between 16 and 86 years of age, who underwent cytology, colposcopy and biopsy of the cervix showing HG-CIN, and treated by conization, with identification of any CIN degree in the cone histological product, and with a minimum of 18-month follow-up. The follow-up was considered appropriate when comprised of cytology, colposcopy and, if necessary, biopsy in six-month intervals.

Exclusion criteria: insufficient data from medical records, post-conization clinical follow-up time less than 18 months, patients undergoing hysterectomy for benign disease, presence of invasive carcinoma in biopsy or conization specimen, absence of CIN evidence after microscopic evaluation of the conization specimen, and paraffin blocks in inadequate conditions for the realization of immunohistochemistry.

the presence of CIN 1, 2 or 3 in cytology, colposcopy and / or cervical biopsy during follow-up was determined as disease recurrence.

Immunohistochemistry preparation technique and reading

The expression of the proteins was observed in tissue microarray slides prepared from the conization specimen paraffin block.

New sections were made from the original blocks of each patient by the tissue microarray technology, to be submitted to the application of p53 and p16^{INK4a} immunomarkers, by hand, at the Experimental Pathology Laboratory PUCPR.

Each tissue slide was made of 20 samples, one patient each, totaling six slides per tissue immunomarker, without identifying the group of origin, so that the immunohistochemistry reading was performed avoiding contamination bias.

The immunohistochemical kits used were: prediluted p53 antibody (mouse monoclonal, clone DO-7, diluted 1:100, Biocare Medical®, Concord, USA); prediluted p16 Antibody (monoclonal mouse, clone 16p04-JC2, diluted 1:100, Bio Sb®, Santa Barbara, California, USA).

After preparation, the slides were subjected to the following processes: deparafinization; antigen retrieval with pH 6.0 citrate; endogenous peroxidase blocking; 1:100 dilution of each antibody and application of the primary antibody on each slide after washing with PBS specific to each immunomarker; application of the secondary antibody, and finally, application of specific DAB and counterstaining.

We determined using following immunohistochemical elements: reaction positivity and its intensity (qualitative analysis), reaction positivity standard (quantitative analysis) and immunolocalization (assessed only for p16 antibody).

Immunohistochemical elements were defined in similarly to the Jung *et al.* research, published in 2010, in their study of tumor progression markers¹⁵.

Qualitative analysis was divided into positive and negative reaction. The reaction was considered positive when impregnated, with brownish staining, the nuclei and/ or cytoplasm of at least 25% of the viable and evaluable tumor sample. A negative reaction was considered when there was no characteristic color of the immunohistochemical reaction.

The positive reaction was divided into two groups: strongly positive (when the staining intensity was similar to the used control) and weakly positive (when the intensity of staining was substantially lower than that of the positive control used, which can only be clearly observed with 100x magnification).

The quantitative analysis was classified as: diffuse positivity (the reaction was positive in an extension which included more than 50% of the viable and evaluable sample); severe multifocal positivity (the reaction was positive to an extent comprised between 25 and 50% of the viable and evaluable tumor sample); and mild multifocal positivity (the reaction was positive in an extension which included less than 25% of the viable and evaluable sample).

For p16 we also determined the immunolocalization, which we classified as follows: nuclear pattern of positivity, cytoplasmic pattern of positivity, simultaneous nuclear and cytoplasmic pattern of positivity.

The immunomarker showed brownish coloration at the nuclear level to the positive cuts for p53 and brownish at the nuclear and cytoplasmic level for p16 (Figure 1).

After applying these criteria, the study resulted in 83 patients, 30 in the study group and 53 patients in the control group (Figure 2).

Statistical analysis

We statistically studied the variables with SPSS 12.0 software, seeking a confidence interval higher than 95% and a 5% significance level.

For pairing of the two groups we evaluated age, parity, type of treatment performed and time of post-treatment follow-up.

For the comparison of the age variable, we used the Student's t test. For comparison of the variable parity was used the nonparametric Mann-Whitney test.

In the analysis of immunomarkers, for the comparison of positivity immunoreaction between groups we used the chi-square and/or the Fisher's exact tests and identified the value of p. We also performed the calculation

of the positive predictive value (PPV) and negative predictive value (NPV), sensitivity, specificity and accuracy of each marker in predicting recurrence.

RESULTS

The study group had a mean age of 36±12 years (95% CI: 33-40), average parity of 3±2 children (95% CI: 2-4), 42% were smokers and 95% were treated with conization by high frequency cautery (HFC) and 5% with the cold knife conization.

The control group had a mean age of 34±12 years (95% CI: 31-37), average parity of 3±2 children (95% CI: 2-3), 50% were smokers and 92% were treated by HFC and 8% with cold knife conization.

There was no statistically significant difference between groups when compared by age (p=0.2), parity (p=0.2), smoking (p=0.5) and conization technique (p=0.7).

Of the 83 patients analyzed, all had CIN 2 or 3 in the biopsy prior to cervical conization and the cone specimen histology showed results between CIN 1 and 3. Conization specimens of the control group comprised three cases of CIN 1, 25 cases of CIN 2, 26 cases of CIN 3, while the ones

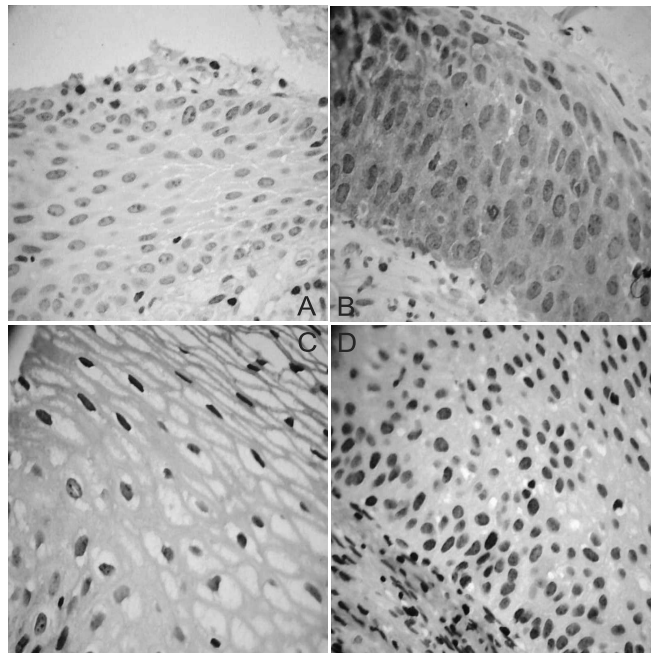


Figure 1 - The contrast of the immunohistochemical expression of p53 and p16^{INK4} biomarkers in histological specimens of cervical intraepithelial neoplasia.

Source: Anatomical pathology laboratory, HEG.

A- negative reaction for p16 (neither nucleus nor cytoplasm gets stained); B- positive reaction for p16 (brownish color in the nuclei and cytoplasm); C- negative reaction for p53 (no staining in the nuclei); D- positive reaction for p53 (brownish coloring of the nuclei).

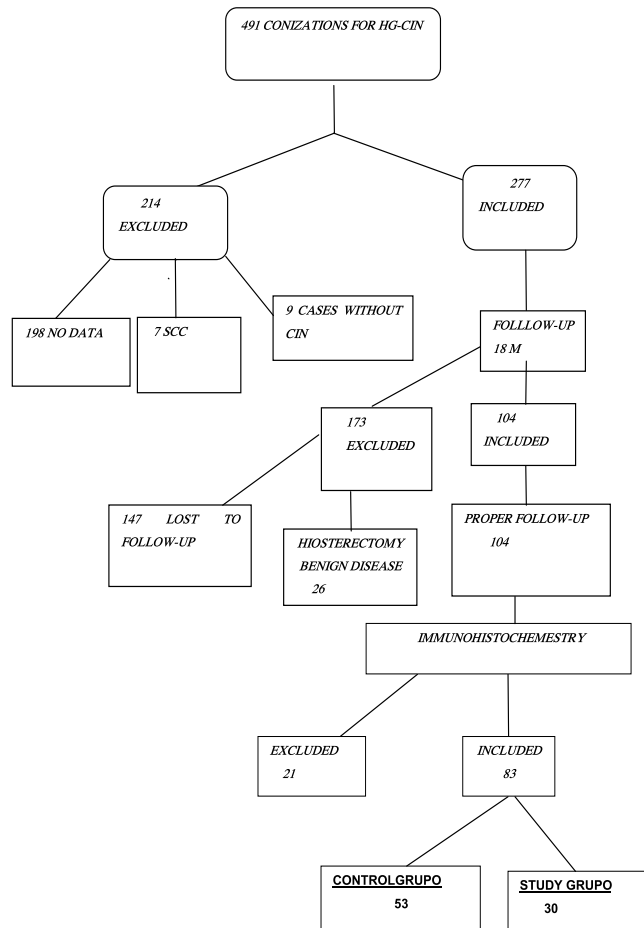


Figure 2 - Consort Diagram (Study Design).

from the study group consisted of three cases of CIN 1, nine cases of CIN 2 and 18 cases of CIN 3, showing no statistical difference of CIN severity degree between groups with respect to the recurrence risk ($p = 0.1$).

As for immunomarkers, each group was individually evaluated for recurrence and/or clinical cure and we computed the positive predictive value (PPV), negative positive value (NPV), sensitivity, specificity and accuracy of each marker in predicting recurrence.

The p53 was present in 43% ($n=21$) of the study group patients and in 57% ($n=28$) of the control group, and was not identified in 73% ($n=25$) of patients in control group and in 26% ($n=9$) of the study one. It therefore exhibited no statistical significance to predict disease recurrence, with p value of 0.1 (Table 1).

The p16 was found in 43% ($n=20$) of the study group patients and in 57% ($n=27$) of the control group. It was not detected in 72% ($n=26$) of the control group patients and in 28% ($n=10$) of the study group. So, it also showed no statistical significance to predict recurrence, with $p=0.1$ (Table 1).

Based on these data, the p53 PPV was 42%, and the NPV, 73%. It had a sensitivity of 70%, specificity of 47% and accuracy of 59% for predicting CIN recurrence.

For p16, the PPV was 42%, and NPV, 72%, with a sensitivity of 66%, specificity of 49% and accuracy of 56% of the test to predict disease recurrence.

There was no significant difference in the quantitative analysis of immunohistochemical reaction between the groups studied for p53 (Table 1).

For the p16 quantitative analysis, the only pattern clearly identified in the immunohistochemical reaction was

the one distinguishing between strong, weak and negative protein presence, as among those who exhibited strong reaction, 58% were from the study group, among the ones showing weak reaction, 74% were in the control group and for those who showed no reaction, 72% were in the control group, identifying a value of $p=0.02$ (Table 1).

Also regarding p16, when the groups were compared in quantitative analysis, we identified that 70% of those who showed no reaction were in the control group, and among those with strong/diffuse pattern of reaction staining the nucleus and cytoplasm, 61% were in the study group (Table 1).

DISCUSSION

Over the past decades, several epidemiological and laboratory studies have shown that invasive cervical cancer is a complex disease with many genetic and environmental determinants³. Despite adequate treatment of the precursor lesion, CIN recurrence occurs on average in 1-25% of cases, which increases the risk of invasive cancer^{16,17}.

Determining the risk of development and prognosis, as well as the success of treatment in response to a particular medication and/or procedure, are the main reason for the identification of biomarkers⁸.

Many recent studies have found the importance of p16 and p53 in cervical neoplasia^{9,12-14,17-34}. The vast majority rated the immunomarker positivity percentage for the presence of cervical intraepithelial neoplasia and correlated with the lesion severity^{9,12,13,17,18,21-29}. However,

Table 1 - Qualitative and quantitative analysis of immunohistochemical p16 and p53 reactions as tests able to predict recurrence of HG-CIN treated by conization.

	Immuno reaction	P53		P16	
		Control	Study	Control	Study
General analysis	Positive	28 (57%)	21 (43%)	27 (57%)	20 (43%)
	Negative	25 (73%)	9 (27%)	26 (72%)	10 (28%)
	Significance	P= 0.1		P= 0.1	
Quantitative analysis	Difuse (+)	10 (63%)	6 (37%)	19 (56%)	15 (44%)
	Multifocal, intense (+)	7 (54%)	6 (46%)	2 (67%)	1 (33%)
	Multifocal, mild (+)	11 (55%)	9 (45%)	6 (60%)	4 (40%)
	Negative	25 (73%)	9 (27%)	26 (68%)	12 (32%)
Qualitative analysis	Strong (+)	15 (62%)	9 (38%)	10 (42%)	14 (58%)
	Weak (+)	13 (52%)	12 (48%)	17 (74%)	6 (26%)
	Negative	25 (73%)	9 (27%)	26 (73%)	10 (27%)
Positive predictive value		42%		42%	
Negative predictive value		73%		72%	
Sensitivity		70%		66%	
Specificity		47%		49%	
Accuracy		59%		56%	

few studies related immune reaction with disease recurrence and/or prognosis^{13,14,31}.

A Korean study¹³ tried to correlate the route related to pRb with the risk of recurrence. It analyzed 265 histological blocks of patients treated for CIN with immunohistochemistry for p16 and found a smaller percentage of such reaction in CIN 1, 2 and 3 patients who had recurrence than in the group without recurrence, similar to our findings.

A more recent study²⁶, conducted in Greece, sought to identify the main changes that occurred in biomarkers related to HPV after six months of CIN treatment and tried to identify how their expression could predict treatment failure. While most of the evaluated markers, including p16, showed high rates of negative expression, they concluded that it is still necessary to examine more treatment failure cases to be able to identify a marker with high accuracy and ensure a quality follow-up.

Another recent study¹⁴, analyzing 55 cases of CIN 2 and 3 in cervical biopsies, studied how markers related to pRb and p53 pathways could be useful in identifying lesion regression. It concluded that the high percentage of pRb and p53 expressions were associated with increased odds of regression, which, in a way, contradicts our findings, which could not relate overexpression of p16 and p53 with disease recurrence.

Differently, some older studies have attempted to relate the expression of p53 and p16^{27,28} with the prognosis of invasive carcinoma. The first²⁷ found a relation between p53 overexpression and poor prognosis of cervical invasive carcinoma, correlating such expression with shorter disease free-survival and increased recurrence risk. The second²⁸, however, evaluating the expression of p53 and p16 in patients with clinical stage 1b and 2a of cervical cancer, could not identify this correlation with prognostic factors.

Since there is not in the literature an absolute standard reading of these immunomarkers, the criteria set out in this study were determined based on the manufacturer's instructions, the standards set by most studied and also in the authors' subjective evaluation, determining the following immunohistochemical elements: positivity of the reaction and its intensity (qualitative analysis), reaction positivity pattern (quantitative analysis) and immunolocalization (only evaluated for p16 antibody).

Most of the studies listed above⁹ can identify a direct relationship between the percentage of positive expression of these markers with disease severity, but have difficulty finding an absolute standard and 100% reproducible that can identify the severity of injuries⁹. Maybe this subjectivity can be seen as a limiting factor of using this technology.

American authors¹⁷ found positivity percentage of 100% in p16 expression in high-grade intraepithelial lesions, but correlated this positivity with the presence of high oncogenic risk HPV, showing a strong association

between diffuse and strong positivity and high-risk HPV lesions¹⁷.

In the same study¹⁷, p16 expression showed diffuse positivity in 70.2% of cases of high-grade lesions and 37.5% of low-grade lesions, and 84.8% of diffuse p16 positivity was related to the presence of high oncogenic risk HPV¹⁷.

In the present study, we could see a higher positivity of the p16 in patients whose evolution of CIN 3 was unfavorable, which can be correlated with HPV type, since different types of HPV may have different degrees of immunoreactivity, but this was a limitation of this study, since we did not genotype HPV.

When comparing the two groups, we did not observe significant difference in p16 positivity, but the comparative positivity in both groups at the same CIN degree was higher in the study group; and 61% of cases with strong and diffuse positivity were in the group with unfavorable evolution, suggesting a trend. A study with a larger number of cases might confirm this pattern of p16 marking as a feature of unfavorable evolution and/or high risk HPV transforming infection.

A study conducted in Costa Rica, generalizing their data for a cohort of 10,000 women, found a positive predictive value of 13.9% of p16 in CIN 3 and a negative predictive value of 100%, concluding that future studies are needed to assess when the clinical management should be modified based on the p16 positive results²².

A meta-analysis, in 2006, argued that in recent years, p16 has been extensively studied as a diagnostic aid in various scenarios of gynecological disease. So, like many markers, p16 is not 100% sensitive and specific for all injuries. However, there are many areas where there is no doubt about its value, often in combination with other markers, which includes identification of cervical high degree focal lesions and the separation of high grade lesions from benign ones mimicking high degree¹⁰.

Another more recent meta-analysis concluded that despite good evidence of correlation between the HPV infection severity with the positivity of p16, its reproducibility is still insufficient to standardize it in clinical practice⁹.

Evaluating the data found p53 positivity in this study, when considering its expression in the control and study groups, we could not find any more frequent pattern of positivity in the immunomarker quantitative analysis, reinforcing the idea of better negative than positive predictive value of such immunomarker, showing that when the marker is negative the chance of unfavorable evolution of post-conization CIN is very small, but when it is positive, one cannot predict its evolution, except by follow-up.

By studying the low-grade intraepithelial lesions and correlating them with HPV type, some¹¹ concluded that p53 expression in low-grade lesions increases progressively in low oncogenic risk HPV infections and is less proportionately expressed in intermediate and high oncogenic risk HPV infections, which may be related to the

different functions of the E6 protein on the HPV type and p53 degradation¹¹.

Other investigators^{19,32} failed to identify a gradually larger p53 expression pattern the higher the severity of the disease, concluding that alterations in p53 play a major role in the pathogenesis of cervical squamous cell carcinoma, but p53 expression is not sufficient to conclude on cervical carcinogenesis¹⁹.

Similar to our study, three other studies^{12,25,30} simultaneously evaluated the positivity of p16 and p53 in

cervical HPV-induced lesions. However, they assessed the increased markers positivity regarding CIN severity, not recurrence.

Taking all these data into account, it seems the expression of both p16 as p53 in conization biopsies strongly emphasizes the relationship of the HPV infection severity with the development of cervical intraepithelial neoplasia, but cannot be considered markers capable to predict disease recurrence after treatment with conization.

R E S U M O

Objetivo: avaliar a expressão dos biomarcadores p16^{INK4a} e p53, nas peças de conização de pacientes com neoplasia intraepitelial cervical de alto grau (NIC-AG), correlacionando com a capacidade de prever o risco de recorrência. **Métodos:** estudo retrospectivo de pacientes com NIC-AG em biópsia de colo uterino, tratadas por conização, entre janeiro de 1999 e janeiro de 2006 e seguimento mínimo de 18 meses. A expressão dos biomarcadores p16 e p53 foi avaliada através de técnica de microarranjos teciduais e correlacionada com a recorrência da doença. Para análise utilizou-se o teste das proporções (qui-quadrado), considerando o valor $p \leq 0,05$, IC95% e cálculos de sensibilidade, especificidade e acurácia destes imunomarcadores na predição de recorrência.

Resultados: oitenta e três pacientes, idade entre 16 e 86 anos ($35 \pm 11,7$), divididas em dois grupos: 30 com recorrência da NIC-AG (grupo estudo) e 53 sem recorrência (grupo controle). A média de idade, paridade, hábito de fumar e técnica de conização foram semelhantes nos dois grupos. A expressão do p53 esteve presente em 43% do grupo estudo e 57% do grupo controle e para o p16 esteve presente em 43% do grupo estudo e 57% do grupo controle ($p > 0,05$). O p53 apresentou valor preditivo positivo (VPP) de 42% e valor preditivo negativo (VPN) de 73%, sensibilidade de 70%, especificidade de 47% e acurácia de 59%. O p16, VPP de 42% e VPN de 72%, sensibilidade de 66%, especificidade de 49% e acurácia de 56%. **Conclusão:** a expressão imunohistoquímica do p53 e do p16 apresentaram baixa sensibilidade e baixa especificidade como marcadores capazes de prever a recorrência da NIC-AG tratada por conização.

Descritores: Neoplasia Intraepitelial Cervical. Conização. Recidiva. Marcadores Biológicos.

REFERENCES

1. WHO. Cervical cancer. Internet. Acessado em: 15 set 2012. Disponível em: <http://www.who.int/en/>
2. INCA. Câncer de colo uterino/ taxas brutas de incidência, estimativa 2012. Internet. Acessado em: 15 set 2012. Disponível em: <http://www.inca.gov.br/estimativas/2012>.
3. Sarian LO, Derchain SFM, Bastos JFB. Métodos diagnósticos para o rastreamento do câncer de colo [editorial]. Rev Bras Ginecol Obstet 2010;32(8):363-7.
4. Wright TC Jr, Massad LS, Dunton CJ, Spitzer M, Wilkinson EJ, Solomon D, et al. 2006 consensus guidelines for the management of women with cervical intraepithelial neoplasia or adenocarcinoma in situ. Am J Obstet Gynecol. 2007;197(4):340-5.
5. Fonseca FV, Tomasich FDS, Jung JE. Lesões cervicais intraepiteliais de alto grau: avaliação dos fatores determinantes de evolução desfavorável após conização. Rev Bras Ginecol Obstet. 2011;33(11):334-40.
6. Lubrano A, Medina N, Benito V, Arencibia O, Falcón JM, Leon L, et al. Follow-up after LLETZ: a study of 682 cases of CIN 2-Cin 3 in a single institution. Eur J Obstet Gynecol Reprod Biol. 2012;161(1):71-4.
7. Nogara PR, Manfroni LA, da Silva MC, Consolaro ME. The "see and treat" strategy for identifying cytologic high-grade precancerous cervical lesions among low-income Brazilian women. Int J Gynaecol Obstet. 2012;118(2):103-6.
8. Termini L, Villa LL. Biomarcadores na triagem do câncer do colo uterino. J bras doenças sex transm. 2008;20(2):125-31.
9. Tsoumpou I, Arbyn M, Kyrgiou M, Wentzensen N, Koliopoulos G, Martin-Hirsch P, et al. p16(INK4a) immunostaining in cytological and histological specimens from the uterine cervix: a systematic review and meta-analysis. Cancer Treat Rev. 2009;35(3):210-20.
10. O'Neill CJ, McCluggage WG. p16 expression in the female genital tract and its value in diagnosis. Adv Anat Pathol. 2006;13(1):8-15.
11. Giannoudis A, Herrington CS. Differential expression of p53 and p21 in low grade cervical squamous intraepithelial lesions infected with low, intermediate, and high risk human papillomaviruses. Cancer. 2000;89(6):1300-7.
12. Bragança JF, Sarian LO, Pitta DR, Maito AB, Vassallo J, Pignataro F, et al. Expression of p16 and cervical infection with high-risk human papillomaviruses are not related to p53 activity in cervical intraepithelial neoplasia. Int J Gynecol Cancer. 2008;18(5):1060-4.
13. Nam EJ, Kim JW, Kim SW, Kim YT, Kim JH, Yoon BS, et al. The expressions of the Rb pathway in cervical intraepithelial neoplasia: predictive and prognostic significance. Gynecol Oncol. 2007;104(1):207-11.
14. Ovestad IT, Gudlaugsson E, Skaland I, Malpica A, Munk AC, Janssen EA, et al. The impact of epithelial biomarkers, local immune response and human papillomavirus genotype in the regression of cervical intraepithelial neoplasia grades 2-3. J Clin Pathol. 2011;64(4):303-7.
15. Jung JE, Anselmi Júnior R, Gennaro L, Leme FEG, Martins APC, Hirth CG, et al. Immunohistochemical assessment of E-cadherin, b-catenin, CEACAM-1 and PTEN: tumor progression markers in melanoma. J Bras Patol Med Lab. 2010;46(2):111-8.
16. Keating JT, Cviko A, Riethdorf S, Riethdorf L, Quade BJ, Sun D, et al. Ki-67, cyclin E, and p16INK4 are complementary surrogate biomarkers for human papilloma virus-related cervical neoplasia. Am J Surg Pathol. 2001;25(7):884-91.

17. Nam K, Ryu A, Jeon S, Kim J, Kwak J, Park B. Clinical significance of a negative loop electrosurgical excision procedure biopsy in patients with biopsy-confirmed high-grade cervical intraepithelial neoplasia. *J Low Genit Tract Dis.* 2015;19(2):103-9.
18. Ekalaksananan T, Pientong C, Sriamporn S, Kongyngyoes B, Pengsa P, Kleebkaow P, et al. Usefulness of combining testing for p16 protein and human papillomavirus (HPV) in cervical carcinoma screening. *Gynecol Oncol.* 2006;103(1):62-6.
19. Mittal KR, Lin O, Chan W, Goswani S, Demopoulos RI. Cervical squamous dysplasias and carcinomas with immunodetectable p53 frequently contain HPV. *Gynecol Oncol.* 1995;58(3):289-94.
20. Cheah PL, Looi LM. P53 immunohistochemical expression: messages in cervical carcinogenesis. *Pathology.* 2002;34(4):326-31.
21. Agoff SN, Lin P, Morihara J, Mao C, Kiviat NB, Koutsky LA. p16(INK4a) expression correlates with degree of cervical neoplasia: a comparison with Ki-67 expression and detection of high-risk HPV types. *Mod Pathol.* 2003;16(7):665-73.
22. Wang SS, Trunk M, Schiffman M, Herrero R, Sherman ME, Burk RD, et al. Validation of p16INK4a as a marker of oncogenic human papillomavirus infection in cervical biopsies from a population-based cohort in Costa Rica. *Cancer Epidemiol Biomarkers Prev.* 2004;13(8):1355-60.
23. Queiroz C, Silva TC, Alves VA, Villa LL, Costa MC, Travassos AG, et al. P16(INK4a) expression as a potential prognostic marker in cervical pre-neoplastic and neoplastic lesions. *Pathol Res Pract.* 2006;202(2):77-83.
24. Salcedo MMBP, Silveira GPG, Zettler CG. A expressão da proteína p16 e herpes simples vírus tipo 2 em lesões pré-neoplásicas e neoplásicas do colo do útero. *Rev Bras Ginecol Obstet.* 2008;30(2):61-6.
25. Tosun G, Sendag F, Zeybek B, Cosan Terek M, Guven C, Zekiogly O, et al. Immunohistochemical expressions of p16 and p53 proteins in cervical intraepithelial neoplasia and in benign cervical tissue. *Eur J Gynaecol Oncol.* 2010;31(6):627-31.
26. Valasoulis G, Koliopoulos G, Founta C, Kyrgiou M, Tsoumpou I, Valari O, et al. Alterations in human papillomavirus-related biomarkers after treatment of cervical intraepithelial neoplasia. *Gynecol Oncol.* 2011;121(1):43-8.
27. Brenna SMF. Expressão proteica de p53 e c-myc como marcadores no prognóstico do carcinoma de colo uterino. *Rev Bras Ginecol Obstet.* 2000;22(8):529.
28. Novik PR. Estudo do valor prognóstico da expressão imunoistoquímica de p53 e p16 no carcinoma do colo do útero estádios Ib e IIa. *Rev Bras Ginecol Obstet.* 2003;25(6):453.
29. Klaes R, Benner A, Friedrich T, Ridder R, Herrington S, Jenkins D, et al. p16INK4a immunohistochemistry improves interobserver agreement in the diagnosis of cervical intraepithelial neoplasia. *Am J Surg Pathol.* 2002;26(11):1389-99.
30. Wang JL, Zheng BY, Li XD, Angström T, Lindström MS, Wallin KL. Predictive significance of the alterations of p16INK4A, p14ARF, p53, and proliferating cell nuclear antigen expression in the progression of cervical cancer. *Clin Cancer Res.* 2004;10(7):2407-14.
31. Guerra F, Rocher AE, Villacorta Hidalgo J, Díaz L, Vighi S, Cardinal L, et al. Argentophilic nucleolus organizer region as a proliferation marker in cervical intraepithelial neoplasia grade 1 of the uterine cervix. *J Obstet Gynaecol Res.* 2014;40(6):1717-24.
32. Shukla S, Dass J, Pujani M. p53 and bcl2 expression in malignant and premalignant lesions of uterine cervix and their correlation with human papilloma vírus 16 and 18. *South Asian J Cancer.* 2014;3(1):48-53.
33. Andrade CE, Scapulatemo-Neto C, Longatto-Filho A, Vieira MA, Tsunoda AT, Da Silva ID, et al. Prognostic scores after surgical treatment for cervical intraepithelial neoplasia: a proposed model and possible implications for post-operative follow-up. *Acta Obstet Gynecol Scand.* 2014;93(9):941-8.
34. Cardoso FA, Campaner AB, Silva MA. Prognostic value of p16(INK4a) as a marker of clinical evolution in patients with cervical intraepithelial neoplasia grade 3 (CIN 3) treated by cervical conization. *APMIS.* 2014;122(3):192-9.

Received in: 16/09/2015

Accepted for publication: 08/12/2015

Conflict of interest: none.

Source of funding: none.

Mailing address:

Fernanda Villar Fonseca

E-mail: fvffonseca74@gmail.com