

# Effects of simvastatin on 5-fluorouracil-induced gastrointestinal mucositis in rats.

## *Efeitos da simvastatina na mucosite gastrointestinal induzida por 5-fluorouracil em ratos.*

ALDO DA CUNHA MEDEIROS, ECBC-RN<sup>1</sup>; ÍTALO MEDEIROS AZEVEDO<sup>1</sup>; MARÍLIA LEITE LIMA<sup>1</sup>; IRAMI ARAÚJO FILHO, TCBC-RN<sup>1</sup>; MARÍLIA DANIELA MOREIRA<sup>1</sup>

### A B S T R A C T

**Objective:** simvastatin has pleiotropic anti-inflammatory and immunomodulatory effects potentially useful to prevent chemotherapy-induced gastrointestinal mucositis. Studies on this are scarce. This study aimed to examine the effects of simvastatin on gastric and intestinal mucositis after 5-fluorouracil (5-FU) treatment in rats. **Methods:** rats weighing 270±18g were divided into two groups. The 5-FU+saline group (5-FU/SAL) rats were treated with 5-FU (50mg/kg) plus 0.9% saline orally (gavage) once daily for five days. The 5-FU+simvastatin (5-FU/SIMV) group was treated with 5-FU (50mg/kg), plus simvastatin (10mg/kg), in the same way. The rats were euthanased on the sixth day, then their stomach and intestine were photographed and removed for exams. Dosages of serum TNF- $\alpha$ , IL-1 $\beta$ , IL-6 and histopathology were done for stomach and intestine. **Results:** body-weight was significantly lower in rats treated with 5-FU+saline than the weight loss of the 5-FU/SIMV group rats. TNF- $\alpha$  expression was lower in 5-FU/SIMV group (172.6±18pg/ml) than in 5-FU/SAL (347.5±63pg/ml). Serum IL-1 $\beta$  was lower in 5-FU/SAL group (134.5±23pg/ml) than in 5-FU/SIMV (48.3±9pg/ml). Serum IL-6 was 61.8±15pg/ml in 5-FU/SIMV and 129.4±17pg/ml in 5-FU/SAL groups. These differences were significant ( $p < 0.05$ ). Mucosal damage in stomach and jejunum were observed in rats receiving 5-FU alone. In the stomach and jejunum, simvastatin caused significant protective effects against 5-FU-induced mucosal injury. **Conclusion:** simvastatin attenuated gastric and intestinal mucositis related to 5-FU therapeutics in animal model. These data encourage forthcoming clinical studies addressing the usefulness of statins in the prevention and treatment of gastrointestinal mucositis.

**Keywords:** Chemotherapy, Adjuvant. Mucositis. Simvastatin. Rodentia.

### INTRODUCTION

Chemotherapy-induced oral and gastrointestinal mucositis is one of the most common adverse events of chemotherapy for cancer<sup>1</sup>. It is associated with a high risk of infection, pain, chemotherapy dose reduction, and infection-related death. A clinical practice guideline for the prevention and treatment of cancer chemotherapy-induced gastrointestinal mucositis was published in 2004<sup>2</sup>. Sonis *et al.* described the perspectives on cancer therapy-induced mucosal injury<sup>3</sup>.

Quantitative and qualitative changes in gastrointestinal mucin in experimental animals treated with 5-fluorouracil (5-FU) have been reported, demonstrating its importance in the gastrointestinal mucosal barrier<sup>4</sup>. Gastrointestinal mucositis induced by cancer treatment is considered a serious side effect of chemotherapy; it promotes severe

ulceration and inflammation of the gastrointestinal tract, mainly in the small intestine<sup>5,6</sup>. Interruption of the cancer treatment due to mucositis usually leads to a reduction in cure rates, increased treatment costs, decreased quality of life and, consequently, worsened disease prognosis<sup>7</sup>. Currently, there is no curative intervention for inflammatory mucositis induced by cancer treatment. Palliative measures for mucositis include oral cryotherapy, soft laser application and systemic administration of drugs, such as glucocorticoids, growth factors and others<sup>8,9</sup>. Considering the high cost of some therapeutic procedures for mucositis and their low efficacy, the development of alternative treatments, statins and natural products have been considered<sup>10</sup>.

Some of the cholesterol-independent or "pleiotropic" beneficial effects of statins include improvement in endothelial function by endothelial nitric oxide synthase (eNOS) upregulation, macrophage

<sup>1</sup> - Federal University of Rio Grande do Norte, Department of Surgery, Natal, RN, Brazil.

proliferation<sup>10</sup>, reduction of platelet activity<sup>11</sup>, stabilization of atherosclerotic plaques<sup>12</sup>, antioxidant properties<sup>13</sup>, anti-inflammatory and immunomodulatory effects<sup>14</sup>. Given the importance of the subject, the present study aims to examine the effects of simvastatin in an experimental model of gastrointestinal mucositis induced by 5-FU, as determined through cytokines and histological markers.

## **METHODS**

The experimental protocol was approved by the Ethics in Research Committee of the Onofre Lopes University Hospital - UFRN/CEUA (nº 07/17). We treated the animals according to the principles stipulated by the 11,794/2008 Brazilian Act for the handling and maintenance of laboratory animals.

### **Animals**

We used Wistar rats (*Rattus norvegicus albinus*, *Rodentia mammalia*) weighing 270±18g in this study. These animals were from the Center of Health Sciences of UFRN-Brazil animal care facility. They were housed in individual cages in a temperature and humidity-controlled environment, with a 12-h darklight cycle. At the beginning of the experimental period, we weighed the animals after fasting for 24h. During treatment, rats were given food (Prevence®) and water *ad libitum*.

### **Experimental design and procedures**

We randomly divided the animals into two groups of six rats each. We administered 5-FU orally by gavage (50mg/kg) once daily for five days to all rats. In the experimental group (5-FU/SIMV, n=6), oral simvastatin suspension (10mg/kg) was given by gavage, starting in the first day of 5-FU administration, for five days. In the control group (5-FU/SAL, n=6), saline solution was administered in the same doses and time limits. The animals were weighed daily for weight control.

After five days of treatment with 5-FU, we collected blood from the animals by cardiac puncture under anesthesia with ketamine 70mg/kg and xylazine 10mg/kg intraperitoneally (ip) and then killed the rats with thiopental sodium overdose (100mg/kg) i.p. The blood was centrifuged and the serum separated for TNF- $\alpha$ , IL-1 $\beta$  and IL-6 dosage by the ELISA technique (Peprotec kits, USA), according to manufacturer's instructions.

After tricotomy and antiseptics of the abdominal wall, we performed a medium laparotomy for photographic documentation of the abdominal cavity. We then removed the stomach and small intestine for macroscopic and microscopic examination.

### **Macroscopic examination of the stomach and small intestine (jejunum)**

We opened the stomach with an incision in the great curvature, and the intestine (jejunum) with a longitudinal incision. We examined them for edema, ulcerations and hemorrhage according to the criteria: intense edema (score 3) when we saw fluid externally and internally in the wall of the stomach or intestine; moderate (score 2) when edema was confined to the mucosa; mild (score 1) between normal and moderate; none (score 0), when normal. The intensity of the hemorrhage was determined as follows: clot and intraluminal blood (score 3); mucosal and wall hematomas (score 2); telangiectasia or vessel dilation (score 1); normal (score 0).

### **Histopathology**

We fixed the stomach and intestine in 10% buffered formalin, embedded them in paraffin, cut them in 5- $\mu$ m slices, and stained them with hematoxylin and eosin. The histopathological examination was done by a pathologist without previous knowledge of the study groups, analyzing five microscopic fields of each organ per animal.

The material was classified according to standard scores on a scale from 0 to 3, according to Lima *et al.*<sup>15</sup>: 0, epithelial and connective tissue without vasodilatation, absent or discrete inflammatory cellular infiltrate, absence of haemorrhage, edema, ulcers or abscesses; 1, discrete vascular congestion, discrete cell infiltration of mononuclear leukocytes, absence of haemorrhage, edema, ulcers or abscesses; 2, moderate vascular congestion, epithelial hydropic degeneration (vacuolation), moderate cellular infiltrate with predominance of polymorphonuclear leukocytes, presence of haemorrhagic areas, edema and occasional small ulcers; 3, acute vascular congestion, marked vasodilation, marked cellular infiltrate, predominantly polymorphonuclear, presence of hemorrhagic areas, edema and extensive ulcers. These criteria were adapted to the stomach and intestine, based on an oral mucositis study<sup>16</sup>.

### Statistical analysis

We expressed the results of the macro and microscopic data as mean  $\pm$  standard deviation using Student's t-test and the BioEstat 5.0 software. We considered differences between groups significant when  $p < 0.05$ .

## RESULTS

In body weight records, 5-FU/saline treated rats showed greater body mass loss than 5-FU/simvastatin treated rats ( $p < 0.05$ ).

### Serum cytokine dosage

The expression of TNF- $\alpha$  occurred to a lower degree in the serum of rats treated with 5-FU+simvastatin ( $172.6 \pm 18$  pg/ml) than in those receiving 5-FU+saline ( $347.5 \pm 63$  pg/ml). IL-1 $\beta$

expression was significantly higher in the group receiving saline (5-FU/SAL -  $122.9 \pm 26$  pg/ml) than in the simvastatin (5-FU/SIMV -  $44.8 \pm 8$  pg/ml) one. Expression of IL-6 was also lower in the 5-FU/SIMV group ( $52.4 \pm 13$  pg/ml) than in the 5-FU/SAL group ( $123.6 \pm 18$  pg/ml). The data are summarized in table 1.

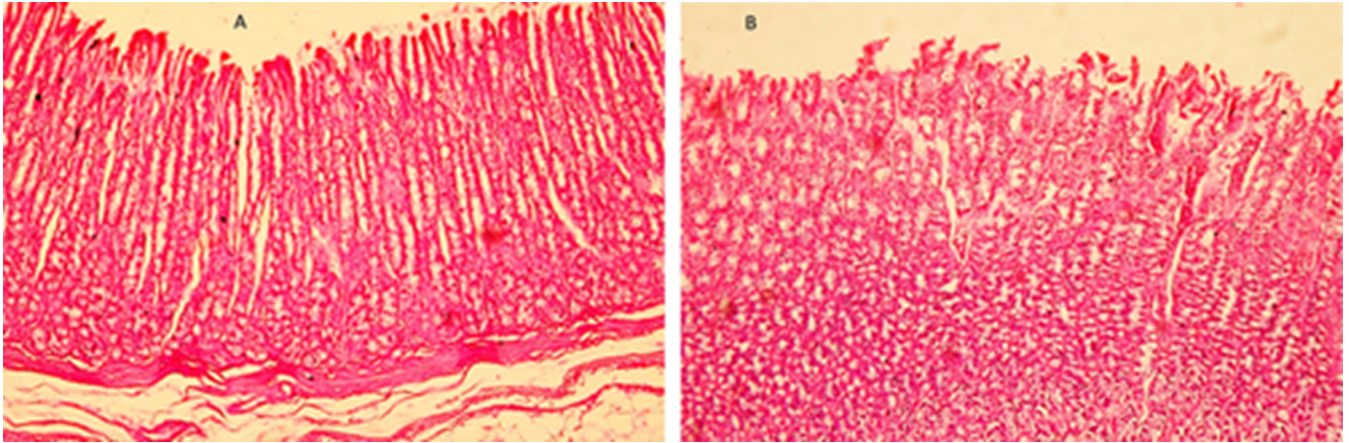
**Table 1.** Values of serum cytokines of animals submitted to 5-FU treatment, associated with saline or simvastatin.

Groups	TNF- $\alpha$ (pg/mL)	IL-1 $\beta$ (pg/mL)	IL-6 (pg/mL)
5-FU/SAL	$347.5 \pm 63$	$122.9 \pm 26$	$123.6 \pm 18$
5-FU/SIMV	$172.6 \pm 18^*$	$44.8 \pm 8^*$	$52.4 \pm 13^*$

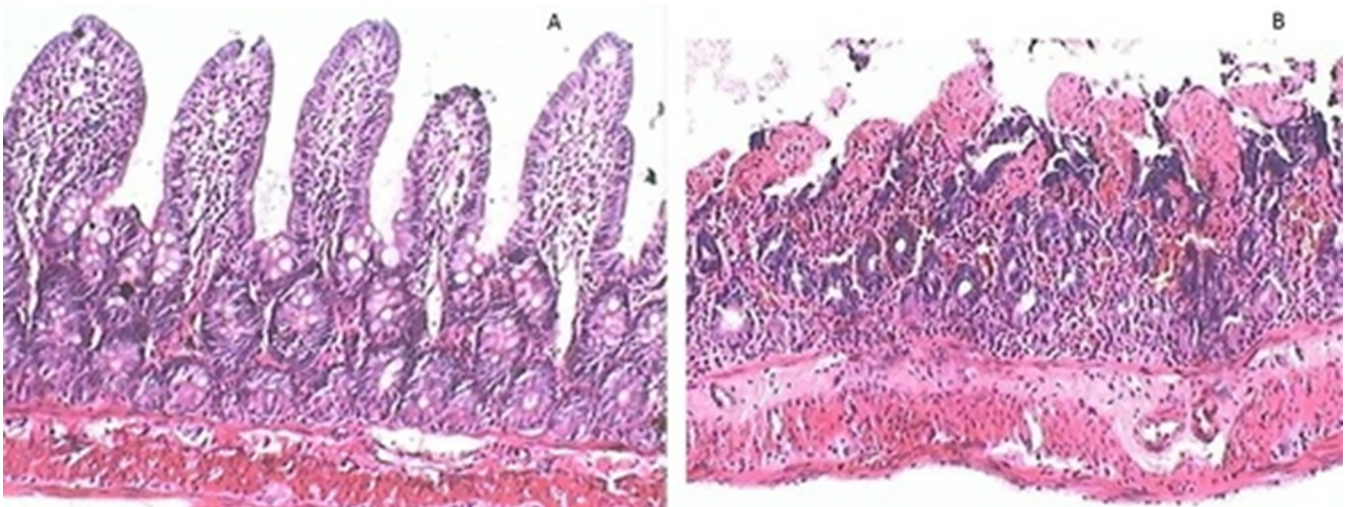
\*  $p < 0.05$  compared to the dosages of 5-FU/SAL group rats by the Student's T-test; 5-FU/SAL, group of rats treated with 5-fluorouracil and saline; 5-FU/SIMV, group of rats treated with 5-fluorouracil and simvastatin.

### Histopathology

The stomach and jejunum in the 5-FU exposed organs had a deformed cytoskeleton, increased necrotic cell counts, reduction of villi, atrophy, crypts and muscular layer, associated with edema, disruption of crypts, inflammatory infiltrate and vacuolization. Followed by simvastatin treatment, the cytotoxicity signs in the stomach and jejunum induced by 5-FU exposure had notable morphological improvements, as well as marked by reduced necrotic cell numbers and inflammation. Figure 1-A shows photomicrographs of a representative stomach image of a simvastatin-treated rat, and 1-B, of a saline-treated animal. Figure 2-A shows a photomicrograph of the small intestine of a rat treated with simvastatin, and 2-B, of an animal treated with saline. Comparing the scores extracted from the histopathological images, the differences in microscopy were significant ( $p < 0.05$ ). These data are summarized in table 2.



**Figure 1.** A) stomach photomicrography of a 5-FU/simvastatin group animal; B) stomach of a 5-FU/saline group rat. H-E 200x.



**Figure 2.** A) animal intestine photomicrography of the 5-FU/simvastatin group; B) rat intestine of the 5-FU/saline group. H-E 200x.

**Table 2.** Values of the histological scores in the stomach and jejunum of the animals submitted to treatment with 5-FU, saline or simvastatin.

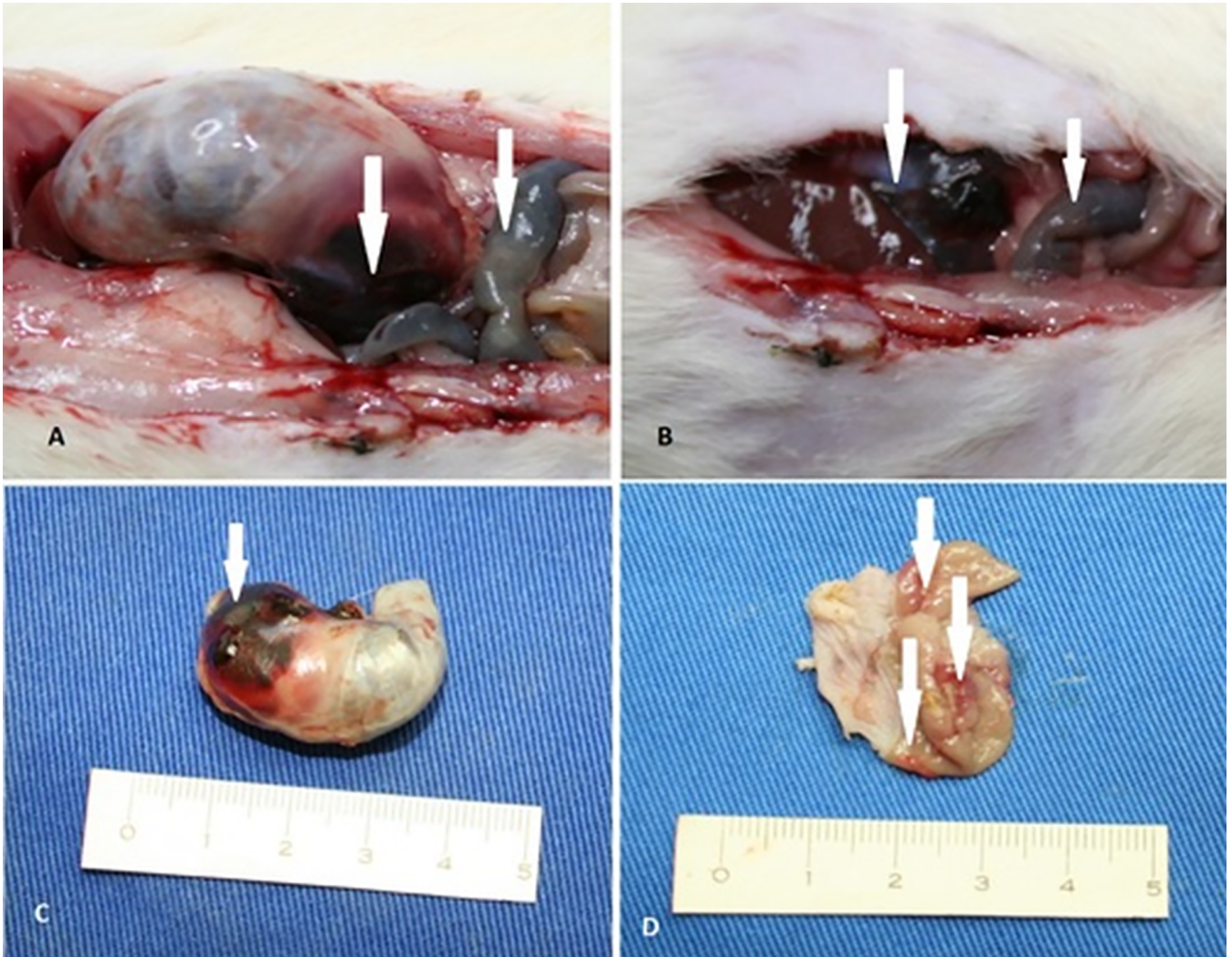
Groups	Stomach	Jejunum
5-FU/SAL	26±3.2	20±2.7
5-FU/SIMV	14±1.8*	9±2,2*

\*  $p < 0.05$  when comparing the histology scores of the examined organs from by the Student's *t*-test; 5-FU/SAL, group of rats treated with 5-FU and saline; 5-FU/SIMV, group of rats treated with 5-FU and simvastatin.

Macroscopy revealed blood and clots inside the stomach and jejunum walls, as well as gastric mucosal ulcerations in all animals treated with 5-FU+saline (Figure 3). We observed these changes only in one rat of the 5-FU+simvastatin group. In the others, the mucosa was congested, without blood or ulcerations.

## DISCUSSION

5-FU remains one of the most widely used chemotherapy drugs for the treatment of advanced gastric cancer because of its extensive antitumor activity, as well as synergism with other antineoplastic drugs<sup>17</sup>. However, its efficacy is relatively low due to the high frequency of its haematological and gastrointestinal toxicities. Gastrointestinal mucositis is a common side effect induced by 5-FU, leading to interruptions and delays in the treatment of tumors, a major determinant of morbidity and mortality in oncology<sup>18</sup>. Despite attempts to reduce the incidence and intensity of mucositis, there is currently no effective prophylactic and/or therapeutic treatment<sup>2</sup>.



**Figure 3.** A) abdomen of a 5-FU/saline group animal, opened by laparotomy. Stomach and intestine (arrows) filled with blood; B) intestine filled with blood (arrows); C) blood seen by transparency in rat stomach (arrow); D) open stomach showing mucosal ulcers (arrows).

Some studies have demonstrated a protective role of statins against radiotherapy and doxorubicin-induced cytotoxicity in endothelial cells *in vitro*<sup>19</sup>, as well as against cytotoxicity and inflammatory responses *in vivo*<sup>20,21</sup>. These data point to a more general organoprotective role of statins against tissue damage caused by antineoplastic drugs and radiotherapy. Assuming that endothelial cells are of particular relevance to inflammatory responses, the protection of endothelial cells by statins is indicative of their anti-mucositis activity in 5-FU treatment *in vivo*. This hypothesis corroborates data showing that statins

prevent mucosal damage and inflammation in hamsters after administration of 5-FU<sup>22</sup>. However, non-hormonal anti-inflammatory drugs did not alleviate radiation-induced oral mucositis in a mouse model<sup>23</sup>, showing that alternative preventive and therapeutic options are needed. Our results demonstrated that simvastatin exerted significant effects on the protection of gastric and intestinal mucosa in rats treated with 5-FU. The mechanisms underlying the development of this mucositis have been investigated; one reported hypothesis is that the cyclooxygenase pathway mediates tissue injury and pain through the upregulation of pain-

evoking prostaglandin E2 and proinflammatory cytokines<sup>24,25</sup>. In fact, our results demonstrated that serum TNF- $\alpha$ , IL-1 $\beta$ , and IL-6 were high in 5-FU-treated rats, and the treatment with simvastatin significantly reduced the expression of these pro-inflammatory cytokines. Previous study of our laboratory examining cystitis induced by cyclophosphamide concluded that pretreatment simvastatin attenuated urotelium inflammation and decreased the activity of cytokines<sup>26</sup>.

Zeigler *et al.* found inhibitory effects of lovastatin on human keratinocytes *in vitro*, following treatment with two different types of mucositis induced by anticancer chemotherapy. Moreover, the statin was found to be genoprotective in keratinocytes and revealed cytoprotective activity, which was related to the inhibition of apoptotic cell death<sup>27</sup>.

Our *in vivo* results suggest that simvastatin might be useful for the prophylaxis and treatment of gastrointestinal mucositis, rather than improving the repopulation of the damaged epithelium, which is a favored therapeutic strategy. Our pre-clinical data provide a promising basis for forthcoming clinical studies addressing the question of whether statins, alone or in combination with drugs that stimulate regenerative processes, can improve supportive measures aiming to alleviate chemotherapy-induced mucositis.

In conclusion, simvastatin attenuates gastric and intestinal mucositis related to 5-FU therapeutics in this animal model. These data encourage forthcoming *in vivo* and clinical studies addressing the usefulness of statins in the prevention of gastrointestinal mucositis.

## R E S U M O

**Objetivo:** examinar os efeitos da sinvastatina na mucosite gástrica e intestinal após o tratamento com 5-fluorouracil (5-FU), determinados pela expressão de citocinas e histologia em ratos. **Métodos:** ratos pesando 270 $\pm$ 15g foram divididos em dois grupos. O grupo 5-FU+salina foi tratado com 5-FU (50mg/kg) mais solução salina a 0,9% por gavagem uma vez ao dia por cinco dias. O grupo 5-FU+sinvastatina foi tratado com 5-FU (50mg/kg), mais sinvastatina (10mg/kg), da mesma forma. Foi feita a eutanásia dos animais no sexto dia. O estômago e o intestino foram fotografados e removidos para exame. Dosagens séricas de TNF- $\alpha$ , IL-1 $\beta$ , IL-6 e histopatologia (coloração HE) do estômago e intestino foram realizadas. **Resultados:** o peso corporal diminuiu em ratos no grupo 5-FU+salina. A sinvastatina não inibiu a perda de peso induzida pelo 5-FU. Danos significativos da mucosa no estômago e no jejuno foram observados em ratos que receberam apenas 5-FU. As dosagens séricas de citocinas foram significativamente menores no grupo 5-FU+sinvastatina do que no grupo 5-FU ( $p<0,05$ ). A sinvastatina causou efeitos protetores significativos contra as lesões da mucosa gástrica e jejunal induzidas por 5-FU. **Conclusão:** a sinvastatina atenua a mucosite gástrica e intestinal relacionada à terapêutica com 5-FU. Nossos dados encorajam futuros estudos pré-clínicos e clínicos sobre a utilidade das estatinas na prevenção da mucosite gastrointestinal.

**Descritores:** Mucosite. Quimioterapia Adjuvante. Sinvastatina. Roedores.

## REFERENCES

1. Keefe DM, Schubert MM, Elting LS, Sonis ST, Epstein JB, Raber-Durlacher JE, Migliorati CA, McGuire DB, Hutchins RD, Peterson DE; Mucositis Study Section of the Multinational Association of Supportive Care in Cancer and the International Society for Oral Oncology. Updated clinical practice guidelines for the prevention and treatment of mucositis. *Cancer*. 2007;109(5):820-31.
2. Rubenstein EB, Peterson DE, Schubert M, Keefe D, McGuire D, Epstein J, Elting LS, Fox PC, Cooksley C, Sonis ST; Mucositis Study Section of the Multinational Association for Supportive Care in Cancer; International Society for Oral Oncology. Clinical practice guidelines for the prevention and treatment of cancer therapy-induced oral and gastrointestinal mucositis. *Cancer*. 2004;100(9 Suppl):2026-46.

3. Sonis ST, Elting LS, Keefe D, Peterson DE, Schubert M, Hauer-Jensen M, Bekele BN, Raber-Durlacher J, Donnelly JP, Rubenstein EB; Mucositis Study Section of the Multinational Association for Supportive Care in Cancer; International Society for Oral Oncology. Perspectives on cancer therapy-induced mucosal injury: pathogenesis, measurement, epidemiology, and consequences for patients. *Cancer* 2004;100(9 Suppl):1995-2025.
4. Saegusa Y, Ichikawa T, Iwai T, Goso Y, Okayasu I, Ikezawa T, et al. Changes in the mucus barrier of the rat during 5-fluorouracil-induced gastrointestinal mucositis. *Scand J Gastroenterol.* 2008;43(1):59-65.
5. Yeoh AS, Gibson RJ, Yeoh EE, Bowen JM, Stringer AM, Giam KA, et al. A novel animal model to investigate fractionated radiotherapy-induced alimentary mucositis: the role of apoptosis, p53, nuclear factor-kappaB, COX-1, and COX-2. *Mol Cancer Ther.* 2007;6(5):2319-27.
6. Han X, Wu Z, Di J, Pan Y, Zhang H, Du Y, et al. CXCL9 attenuated chemotherapy-induced intestinal mucositis by inhibiting proliferation and reducing apoptosis. *Biomed Pharmacother.* 2011;65(8):547-54.
7. Touchefeu Y, Montassier E, Nieman K, Gastinne T, Potel G, Bruley des Varannes S, et al. Systematic review: the role of the gut microbiota in chemotherapy- or radiation-induced gastrointestinal mucositis - current evidence and potential clinical applications. *Aliment Pharmacol Ther.* 2014;40(5):409-21.
8. Keefe DM. Gastrointestinal mucositis: a new biological model. *Support Care Cancer.* 2004;12(1):6-9.
9. Lalla RV, Schubert MM, Bensadoun RJ, Keefe D. Anti-inflammatory agents in the management of alimentary mucositis. *Support Care Cancer.* 2006;14(6):558-65.
10. Aikawa M, Rabkin E, Sugiyama S, Voglic SJ, Fukumoto Y, Furukawa Y, et al. An HMG-CoA reductase inhibitor, cerivastatin, suppresses growth of macrophages expressing matrix metalloproteinases and tissue factor in vivo and in vitro. *Circulation.* 2001;103(2):276-83.
11. Huhle G, Abletshauser C, Mayer N, Weidinger G, Harenberg J, Heene DL. Reduction of platelet activity markers in type II hypercholesterolemic patients by a HMG-CoA-reductase inhibitor. *Thromb Res.* 1999;95(5):229-34.
12. Rosenson RS, Brown AS. Statin use in acute coronary syndromes: cellular mechanisms and clinical evidence. *Curr Opin Lipidol.* 2002;13(6):625-30.
13. Stoll LL, McCormick ML, Denning GM, Weintraub NL. Antioxidant effects of statins. *Drugs Today (Barc).* 2004;40(12):975-90.
14. Shin SK, Cho JH, Kim EJ, Kim EK, Park DK, Kwon KA, et al. Anti-inflammatory and anti-apoptotic effects of rosuvastatin by regulation of oxidative stress in a dextran sulfate sodium-induced colitis model. *World J Gastroenterol.* 2017;23(25):4559-68.
15. Lima V, Brito GA, Cunha FQ, Rebouças CG, Falcão BA, Augusto RF, et al. Effects of the tumor necrosis factor-alpha inhibitors pentoxifyline and thalidomide in short-term experimental oral mucositis in hamsters. *Eur J Oral Sci.* 2005;113(3):210-7.
16. Wanzeler AMV, Júnior SMA, Gomes JT, Gouveia EHH, Henriques HYB, Chaves RH, et al. Therapeutic effect of andiroba oil (*Carapa guianensis* Aubl.) against oral mucositis: an experimental study in golden Syrian hamsters. *Clin Oral Investig.* 2017;22(5):2069-79.
17. Wöhrer SS, Raderer M, Hejna M. Palliative chemotherapy for advanced gastric cancer. *Ann Oncol.* 2004;15(11):1585-95.
18. Rolston KV. The burdens of cancer therapy: clinical and economic outcomes of chemotherapy-induced mucositis. *Cancer.* 2004;100(6):1324-5; author reply 1325-6.
19. Damrot J, Nübel T, Epe B, Roos WP, Kaina B, Fritz G. Lovastatin protects human endothelial cells from the genotoxic and cytotoxic effects of the anticancer drugs doxorubicin and etoposide. *Br J Pharmacol.* 2006;149(8):988-97.
20. Haydont V, Bourgier C, Pocard M, Lusinchi A, Aigueperse J, Mathé D, et al. Pravastatin inhibits the Rho/CCN2/extracellular matrix cascade in human fibrosis explants and improves radiation-induced intestinal fibrosis in rats. *Clin Cancer Res.* 2007;13(18 Pt1):5331-40.

21. Henninger C, Huelsenbeck J, Huelsenbeck S, Grösch S, Schad A, Lackner KJ, et al. The lipid lowering drug lovastatin protects against doxorubicin induced hepatotoxicity. *Toxicol Appl Pharmacol.* 2012;261(1):66-73.
22. Medeiros CA, Leitão RF, Macedo RN, Barboza DR, Gomes AS, Nogueira NA, et al. Effect of atorvastatin on 5-fluorouracil-induced experimental oral mucositis. *Cancer Chemother Pharmacol.* 2011;67(5):1085-100.
23. Haagen J, Krohn H, Röllig S, Schmidt M, Wolfram K, Dörr W. Effect of selective inhibitors of inflammation on oral mucositis: preclinical studies. *Radiother Oncol.* 2009;92(3):472-6.
24. Lalla RV, Pilbeam CC, Walsh SJ, Sonis ST, Keefe DM, Peterson DE. Role of the cyclooxygenase pathway in chemotherapy-induced oral mucositis: a pilot study. *Support Care Cancer.* 2010;18(1):95-103.
25. Morales-Rojas T, Viera N, Morón-Medina A, Alvarez CJ, Alvarez A. Proinflammatory cytokines during the initial phase of oral mucositis in patients with acute lymphoblastic leukaemia. *Int J Paediatr Dent.* 2012;22(3):191-6.
26. Dantas AC, Batista-Júnior FF, Macedo LF, Mendes MN, Azevedo IM, Medeiros AC. Protective effect of simvastatin in the cyclophosphamide-induced hemorrhagic cystitis in rats. *Acta Cir Bras.* 2010;25(1):43-6.
27. Ziegler V, Albers A, Fritz G. Lovastatin protects keratinocytes from DNA damage-related proapoptotic stress responses stimulated by anticancer therapeutics. *Biochim Biophys Acta.* 2016;1863(6 Pt A):1082-92.

Received in: 02/03/2018

Accepted for publication: 08/28/2018

Conflict of interest: none.

Source of funding: CNPq (Conselho Nacional de Desenvolvimento Científico e Tecnológico).

**Mailing address:**

Aldo da Cunha Medeiros

E-mail: [aldom@uol.com.br](mailto:aldom@uol.com.br)

[aldo@ufrnet.br](mailto:aldo@ufrnet.br)

