

Revision articles

Contributions of the electromyography of needle for the study of swallowing in humans

Contribuições da eletromiografia de agulha para o estudo da deglutição em seres humanos

Luciana Rodrigues Belo⁽¹⁾Sílvia Vasconcelos⁽²⁾Maria das Graças Wanderley de Sales Coriolano⁽³⁾Nadja Asano⁽⁴⁾Amdore Guesel Asano⁽⁵⁾Otávio Gomes Lins⁽¹⁾

⁽¹⁾ Universidade Federal de Pernambuco, UFPE, Recife, Pernambuco, Brasil.

⁽²⁾ Real Hospital Português, RHP, Recife, Pernambuco, Brasil.

⁽³⁾ Departamento de Anatomia da Universidade Federal de Pernambuco, UFPE, Recife, Pernambuco, Brasil.

⁽⁴⁾ Departamento de Medicina Clínica da Universidade Federal de Pernambuco, UFPE, Recife, Pernambuco, Brasil.

⁽⁵⁾ Ambulatório de Neurologia do Hospital das Clínicas da Universidade Federal de Pernambuco, HC/UFPE, Recife, Pernambuco, Brasil.

Source: Bolsa REUNI

Conflict of interest: non-existent

Received on: March 12, 2015

Accepted on: July 11, 2016

Mailing address:

Luciana Rodrigues Belo
Rua Abel de Sá Bezerra Cavalcanti, 161,
apt 601, Casa Amarela
Recife – PE - Brasil
CEP: 52051-270
E-mail: lucianabelo@yahoo.com.br

ABSTRACT

Intramuscular EMG is performed by the doctor, from the fixing needle electrodes or thin wire for the study of isolated muscles or deep muscles. This study aims to identify and describe the contributions of intramuscular electromyography, for the evaluation of swallowing in humans. The search, carried out between April and March 2015, in the databases PubMed, BIREME, AND BANK OF THESES OF CAPES, resulted in 21 references, of which only seven met our inclusion criteria. Selected articles make important contributions to the understanding of the electrophysiological behavior and electrophysiological during swallowing and it is believed that the lack of studies using this tool in humans should be the annoyance and risks caused by the introduction of the needle into the belly muscle and maybe the introduction of a thin wire (fine wire or wire cooper) is more interesting for the aid diagnosis of neuromuscular disorders and nerve that compromise swallowing, the ability to dramatically reduce the annoyance caused by the needle.

Keywords: Electromyography; Deglutition; Muscles

RESUMO

A Eletromiografia intramuscular é realizada pelo médico, a partir da fixação de eletrodos de agulha ou de fio fino para o estudo de músculos isolados ou músculos profundos. Esse estudo tem como objetivo identificar e descrever as contribuições da eletromiografia intramuscular, para a avaliação da deglutição em seres humanos. A busca, realizada no período entre abril e março de 2015, nos bancos de dados da PUBMED, BIREME E BANCO DE TESES DA CAPES, resultaram em 21 referências, das quais, apenas sete se enquadraram nos critérios de inclusão. Os artigos selecionados trazem contribuições importantes para o entendimento do comportamento eletrofisiológico e eletrofisiopatológico durante a deglutição e acredita-se que a escassez de estudos utilizando essa ferramenta em seres humanos deva-se ao incômodo e riscos causados pela introdução da agulha no ventre muscular e talvez a introdução de um fio fino (*fine wire* ou *cooper wire*), seja mais interessante para o auxílio diagnóstico de denervations e transtornos neuromusculares que comprometam a deglutição, pela possibilidade de reduzir drasticamente o incômodo causado pela agulha.

Descritores: Eletromiografia; Deglutição; Músculos

INTRODUCTION

The assessment of swallowing includes the use of specific clinical protocols and complementary tests, which aim to analyze the integrity of the structures involved in this mechanism. In addition to endoscopy and videofluoroscopy of swallowing, the literature indicates that Surface Electromyography (sEMG) and Intramuscular Electromyography (SMEI) as important tools in electrophysiological evaluation of this function¹⁻⁶.

Electromyography can be used for the diagnosis of neuromuscular diseases or trauma, and the kinesiological study of muscles in certain motor activities. Portney and Roy (2004)⁷ differentiate clinical electromyography of kinesiological electromyography. In clinical EMG, performed by physicians, nerve conduction velocity tests are performed. While in kinesiological EMG, it is possible to study muscle function while performing specific tasks or therapeutic regimens⁸.

The kinesiological EMG can be performed from surface electrodes, needle electrodes, the fine wire type or hook wire electrodes. SEMG has been widely studied and used by many researchers and health professionals, and corresponds to a non-invasive and without contraindications that aims to capture the electrical activity of muscles or muscle groups, from fixing surface electrodes on the skin parallel to the muscle fibers^{2,3,9-11}.

However, when studying the muscles of the face and neck by sEMG, there is a greater probability of crosstalk funding (activity of neighboring muscles), making the isolated assessment of certain muscles, in addition to the high variability within and between subjects, limiting analysis of electrophysiological findings^{12,13}. The SMEI has a great advantage over the EMGs, by minimizing the capture activity from neighboring muscles and signal interference, secondary to the displacement

between the electrode and the skin, in order, that the fixing is directly inside the muscle under study¹⁴.

This technique is performed by physicians from the introduction of needle electrodes or fine Wire type set in the muscle membrane^{14,15}. Thus, the aim of this review was to describe the contributions of SMEI, for the evaluation of swallowing in humans.

METHODS

The research was conducted by three researchers. Two researchers (LB and MGWS) sought the data independently and blindly initially. The third researcher (OGL), established as a proofreader. It has been consulted in cases of doubt to establish agreement between ideas. Articles were included published in the last 15 years (1999-2013), with human beings of both sexes, whose sample was made up of children, youth, adults, healthy elderly subjects (without neurological sequelae). Articles were excluded if they did not use the data obtained from needle electromyography in swallowing evaluation, review articles and studies with animal models.

The search was carried out between April and March 2015. The descriptors were chosen according to the lists DeCS and MeSH. The list of DeCS descriptors were: Swallowing and electromyography. The MeSH list descriptors were: *déglutition*, Swallowing and electromyography.

Keywords were also used to extend the search (Figure 1). References of selected articles were analyzed for other studies, which could have been omitted from the electronic search. Banks portal Bireme data were used (Medline, Lilacs, IBECs, Scielo, Cochrane Library, and other banks that portal), the Pubmed, and bank Capes theses. The search strategy applied followed Castro recommendations *et al.*¹⁶, Dickersin *et al.*¹⁷ and the Cochrane Collaboration.

#1. ("fine wire" or "hook wire" or "laryngeal EMG" or "needle EMG")

#2. ("EMG" or "**electromyography**")

#3. ("**déglutition**" or "swallowing" or "swallow")

Intersection: #1 and #2 and #3

Figure 1. Descriptors used in the search. Bold the DeCS/MeSH descriptors list.

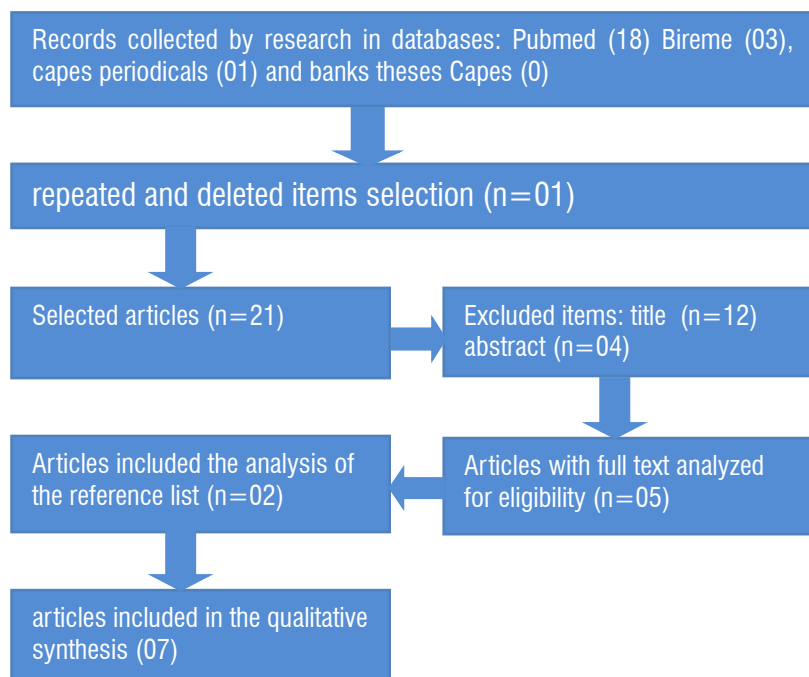


Figure 2. Search and selection of articles: Pubmed, Bireme and Capes theses database.

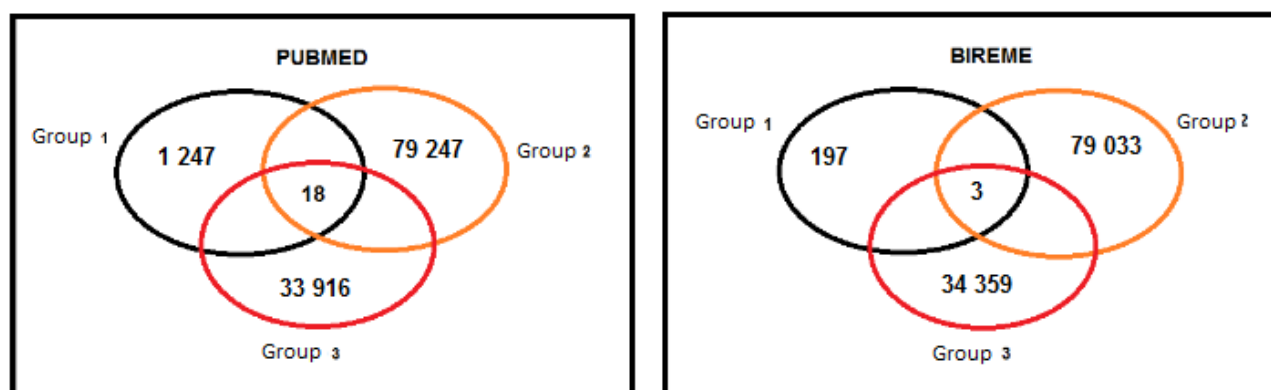


Figure 3. Represents the number of articles found in each block, and the number of items that were analyzed after the crossroads of Information in common among the articles; the intersection of three sets.

There were found 18 articles in PUBMED portal; three articles in BIREME portal and work on PERIODIC CAPES and no article in CAPES OF THESESES BANK potentially relevant and were stored for analysis. Of the three selected items from PORTAL BIREME (one was repeated in the results of the survey in Pubmed portal), getting 18 articles of PUBMED, two articles of BIREME portal, and another article of Periodicos. Capes for analysis. Among the 21 articles analyzed, 16 were excluded for not meeting the inclusion criteria. After analyzing the results of the five articles that were selected, two were included. Finalizing the collection with the addition of seven articles: Vitti & Basmajian (1977)¹⁸; Ertekin et al. (2000)¹⁹; Ertekin et al. (2001)²⁰;

Baudon et al. (2002)²¹; Renault et al. (2011)²²; Alkan et al. (2012)²³; Inokuchi et al. (2014)²⁴ (Figure 2, Figure 3).

REVIEW IN THE LITERATURE

Analyzing the articles and the instrumentation used it was observed that only the items Ertekin (Ertekin et al. (2000)¹⁹, and Ertekin et al. (2001)²⁰ and Alkan et al. (2012)²³, used a control group of subjects considered normal, while Baudon et al. (2002)²¹ and Renault et al. (2011)²² used recommended normal data for previous studies.

Only items Ertekin (Ertekin et al, 2000)¹⁹ and Ertekin et al, 2001)²⁰ and Alkan et al. (2012)²³ described the

filters that have been configured on the EMG machine, but did not report the sampling frequency, while Inokuchi et al. (2014)²⁴ reported only the sampling frequency (Table 1).

The lack of agreement among researchers, as to the most appropriate technical specification, hinders the replication of their studies and can lead to different results. Only two (Vitti & Basmajian (1977)¹⁸ and Inokuchi et al. (2014)²⁴ used electrodes of the fine wire type or hook wire, although the most suitable in kinesiology studies because they cause less interference and discomfort to patients (Table 1).

Electromyography is used to assess the scope of diseases or traumas as well as a tool for studying kinesiological neuromuscular function. The kinesiological EMG aims to examine the function and / or muscle performance, while performing specific tasks purposeful, or therapeutic regimens. For this, the therapist examines patterns of muscle response onset and cessation of activity, muscle fatigue and muscle response level in relation to the effort; type of muscle contraction and position. This type of test may be performed by surface electrodes for the study of superficial muscles and needle or thin wire electrodes (fine wire) for detecting the electrical activity of specific muscles and / or deep⁷.

Few items with humans who have studied the electromyographic activity from needle electrodes or fine wire type during swallowing were found. In the search performed in the databases referred to above, seven articles were selected to describe the contributions of intramuscular electromyography for the evaluation of swallowing in humans. Tables 1 and 2 are important methodological information to those provisions.

EMGi's contributions to the study of swallowing in humans

Vitti & Basmajian (1977)¹⁸

Vitti & Basmajian (1977)¹⁸ aimed to analyze comprehensively intramuscular myoelectric activity of muscles: temporal, masseter, medial pterygoid, anterior belly of the digastric, mylohyoid and geniohyoid in "normal" individuals with bipolar type electrodes "fine wire" during jaw movements, chewing and swallowing. Evaluated 29 participants considered normal, with all the teeth in the oral cavity (Table 2).

As this review aims to describe the contributions of EMG i for evaluation of swallowing, the line of reasoning will focus on the results found in this function.

The data were analyzed according to the analog method of classification developed by Basmajian (1974), as follows: "O", *no activity*; " ± " *insignificant activity*;" + " *Slightly on*," ++ " *moderate activity*," +++ " *very marked activity*, and" ++++ " *to marked activity*.

Vitti & Basmajian (1977)¹⁸ studied the electrical activity in the following tests: saliva swallowing and swallowing a volume of water not described in the article. As a result, there was found that during saliva swallowing is the full participation of suprahyoid muscles, confirming the findings of Cunningham and Basmajian (1969)²⁵, Lehr et al. (1971)²⁶, and Hrycyszyn and Basmajian (1972)²⁷. Marked activity occurred in the anterior belly of the digastric and the mylohyoid muscle, followed by moderate activity of the geniohyoid muscle.

The medial pterygoid was activated in 82% of the sample, with wide participation. In other muscles, the activity ranged from negligible to light. In the temporal muscle, the activity was present in 23-36% while the masseter in 55% of cases. The researchers believe that the activity observed in the temporal muscle, masseter and medial pterygoid is probably the result of contact of the posterior teeth when swallowing occurs, as shown in cinefluoroscopic studies²⁸.

This study analyzed the swallowing of water in three stages: 1-Sipping, 2- retaining water for 5 seconds and 3- swallowing. In the first phase, there is no activity in the temporal muscle, masseter and medial pterygoid. Potential insignificant was observed in the anterior belly of the digastric, mylohyoid and geniohyoid, ranging between 46 and 64% of cases. This activity is probably a result of mild depression jaw, necessary to keep the glass of water between his lips.

During the second stage, holding the water in the oral cavity, all muscles remained electrophysiological silence. In the last phase, swallowing, it found the total activity in the anterior belly of the digastric, mylohyoid and geniohyoid. Insignificant activities were observed in some cases, the anterior and posterior portions of the temporal and masseter muscles while in the medial temporal potential was inactive. On the other hand, the pterygoid muscle showed moderate activity in 86% of cases. Vitti & Basmajian (1977)¹⁸ believe that this activity may occur to keep the posterior tooth contact.

It was mentioned in the methods as given in the command swallowing events. Only the results, the

authors mention that the participants keep the glass of water between his lips to sip; however, that time is carried over? What volume of water administered? The authors also did not mention the sample filters and frequency programmed into the device.

The study by Vitti and Basmajian (1977)¹⁸ back as a contribution demonstrating the EMG activation of muscles: the anterior digastric Venter, milohyoideous, geniohyoideous (suprahyoid muscles), medial pterygoid, masseter and temporal (muscles lifts the jaw) in different times of swallowing in humans.

*Ertekin et al. (2000)*¹⁹

Ertekin et al. (2000)¹⁹ investigated the pathophysiology of dysphagia in amyotrophic lateral sclerosis (ALS) by clinical and electrophysiological measurements such as: larynx displacement from a piezoelectric sensor; electromyographic activity surface of suprahyoid muscles (EMG-MSH) and intramuscular electromyographic activity of the cricopharyngeal muscle (SMEI through needle electrodes) during swallowing of different water volumes (Table 1 and 2). As a result, they found that the activity of suprahyoid muscles in the dry swallowing (saliva) was significantly longer, while the larynx repositioning time remained within the normal range in patients with ALS.

The cricopharyngeal muscle of patients with ALS showed severe abnormalities during the voluntary swallowing, which, according to the authors, may be due to the delay in the opening of the upper esophageal sphincter and/or by premature closure of this sphincter; the total duration of opening was short, with unexpected bursts of motor units and the lack between the muscles lifts of the larynx and the opening of the upper esophageal sphincter was significant.

Ertekin et al. (2000)¹⁹ concluded that there are two pathophysiological mechanisms in the dysphagia of it: the first concerns the delay or absence of triggering the reaction in pharyngeal voluntary swallowing; and preservation of activity in the reflex automatic swallowing; the second is related to the hypertonicity and hyperreflexivity of the cricopharyngeal muscle. The authors believe that this is due to the progressive degeneration of the fibers corticobulbars.

Ertekin et al. (2000)¹⁹ brings as a contribution to a better understanding of the pathophysiological characteristics of swallowing in Amyotrophic Lateral Sclerosis with the analysis of electrophysiological parameters obtained from the semg of the supra-hyoid muscles, EMHi of needle of the cricopharyngeal muscle and the

establishment of a limit of dysphagia. What proves to be possible to identify changes in electromyographic activity during swallowing of patients with ALS and thus promote the therapeutic planning and systematic monitoring of the treatment and/or management in these cases.

*Ertekin et al. (2001)*²⁰

The study by Ertekin et al. (2001)²⁰ aimed to show the existence and frequency of subclinical electrophysiological abnormalities in oropharyngeal swallowing in myotonic dystrophy, as well as to clarify the pathophysiological mechanisms in this disorder through the following findings: displacement of the larynx, from a piezoelectric sensor; electromyographic activity surface of suprahyoid muscles (EMG-MSH) and intramuscular electromyographic activity of the cricopharyngeal muscle (SMEI through needle electrodes) during swallowing of different water volumes (Table 1 and 2).

The electrophysiological behavior of the cricopharyngeal muscle was considered normal in eight patients with myotonic dystrophy. Of these eight, two were diagnosed with dysphagia, and six were considered non-dysphagia. The tonic activity of the cricopharyngeal muscle rest was off by 400 to 500 msec, while performing the raising and lowering of the larynx. In the five remaining patients, all with dysphagia, EMG cricopharyngeal muscle was considered pathological and showed clinical signs and symptoms suggestive of CNS involvement.

In this study, the examination of the cricopharyngeal muscle was considered normal in most patients with myotonic dystrophy with or without dysphagia. Although for about 40%, all with dysphagia, the electrophysiological examination of the cricopharyngeal muscle showed several abnormalities. During swallowing, early firing activity and silence recovery appeared in EMG and tended to be high amplitude and long duration. In three patients with congenital myotonia, EMG cricopharyngeal muscle was normal, both at rest and during swallowing. Ertekin et al. (2001)²⁰ concluded that the involvement of the CNS may contribute to the delay in the swallowing reflex shooting and abnormal EMG EES can identify dysphagia in this disease.

Ertekin et al. (2001)²⁰ bring as contributions, physiopathological features of swallowing in myotonic dystrophy, with the analysis of electrophysiological parameters obtained from the semg of the supra-hyoid muscles, EMHi of the cricopharyngeal muscle and the establishment of a limit of dysphagia. As Ertekin et al.

(2000)¹⁹, allows us to believe that the EMG can identify changes in muscle activity during swallowing of these patients and thus promote the therapeutic planning and systematic monitoring of the treatment and/or management by a speech.

*Baudon et al. (2002)*²¹

The aim of the survey of Baudon et al. (2002)²¹ was to evaluate the motor dysfunction by manometry and electromyography of intramuscular needle, the genioglossus muscle and tireohioideous, during sucking and swallowing of newborn infants, with a result of Pierre Robin (SPR). These patients had upper airway obstruction and dysphagia disease (Table 1 and 2).

The EMG showed lack of sucking and swallowing in 24 of 28 patients. The riots were mild in six, moderate in six and severe in 12 patients. All patients demonstrated manometric disorders such as: relaxation is incomplete or assichronous of upper esophageal sphincter (15). Activity of the EES with wave multi-peaks (17), waves of amplitudes too high (14) and asynchronous relaxation of the lower esophageal sphincter higher (19). The frequency of disturbances and mean blood pressures at rest of both: upper esophageal sphincter and less were significantly higher than in patients with gastro-esophageal reflux disease.

These results were obtained from the comparison of the data found in this study, with recommended normal data in previous studies by Renault & Raimbault (1992)²⁹. These researchers, in the study entitled "Electromyographie faciale, linguale pharyngée et chez l'enfant: une méthode d'étude des troubles de succion-déglutition et de leur physiopathologie" found the electromyographic activity from needle electrodes of the genioglossus muscles and tireohyoideous, to analyze the coordination between the suction and swallowing newborns considered normal.

They believed that the activity of the genioglossus is related to the suction process and the activity of the muscle tireohyoideous with swallowing. Baudon et al. (2002) concluded that the 21 manometry and EMG were able to identify malfunctions in the motor organization of the tongue, pharynx, and esophagus; even in the absence of clinical disorders in swallowing.

The identification from the SMEI, incoordination between the suction and swallowing found in the search Baudon et al. (2002)²¹ has important contributions to the objective record of evaluation and management of patients with Pierre Robin Sequence. A lack of coordination between these two functions enhances the risk

of penetration and aspiration of salivary content and / or feed.

*Renault (2011)*²²

Renault (2011)²² evaluated the relevance of EMG combined techniques in the evaluation and management of children with Pierre Robin sequence (SPR) from the needle electromyography of facial muscles, tongue, pharynx and larynx (Table 1 and 2); They followed 81 infants among them 57 with Pierre Robin sequence alone (SPRI) and 24 with Pierre Robin sequence associated (SPRA) (Table 2).

As a result, they found electrophysiological signs of neural impairment in facial muscles in 17 of 24 patients with Pierre Robin sequence associated. The soft palate muscles showed traces of low amplitude in 41.4% of patients who required two surgical steps to the soft palate repair; 18.5% of those who needed only one surgical step. In electrophysiological studies during bottle-feeding, patients with moderate or severe abnormality of oral coordination / pharyngeal required more prolonged enteral feeding, patients with mild abnormalities or regular coordination.

Neurogenic electromyographic signals were detected in at least one of the facial muscles or oral, for 17 of 24 patients with Spra, and one of 57 patients with SPRI ($p < 0.0001$). Neurogenic signs were more frequently detected in the face and the soft palate, which in the language. Electromyographic signs of denervation of the facial muscles have been identified in the muscles of the tongue and soft palate in four patients.

Abnormal coordination patterns between sucking and swallowing were classified into three stages of severity, from, electromyography: (a) light: this suction, however, alternating between sucking and swallowing irregular; (B) Moderate: Suction present with synchronous or random pharyngeal phase; or (c) severe: the language did not perform the rhythmic sucking activity, and inactive or tonic pharyngeal phase. Renault et al. (2011), as well as Baudon et al. (2002)²¹ compared their results with proposed normal data in previous studies, however, Renault et al. (2011)²², cites Renault (2001)³⁰, as being the source of such data, and in fact, this article describes the facial electromyography in newborns and young infants with congenital facial weakness, which leads us to believe that failed to referencing these normal findings and it is likely, given the similarity in the studies and the authors, the normal data used by Renault et al. (2011)²² are based on data

obtained in Renault & Raimbault²⁹, as well as the study of Baudon et al. (2002)²¹

Renault et al. (2011)²², bring relevant data to corroborate the results found by Baudon et al. (2002)²¹ assisting the analysis and interpretation of electrophysiological data of the muscles involved in swallowing.

Alkan et al. (2012)²³

The research of Alkan et al. (2012)²³ presented to analyze the relationship between the severity level of the gastroesophageal reflux, patterns of contraction and behavior of the cricopharyngeal muscle through the analysis of measures of electrophysiological cricopharyngeal muscle, from the intramuscular electromyography with electrode of needle. For this purpose, there were compared 24 patients with gastroesophageal reflux disease, with 21 healthy volunteers. The severity of reflux was diagnosed through endoscopy upper GI series,²⁴ and the application of the protocol Demeester score (Table 1 and 2).

The gastroesophageal reflux disease was mild in 15 patients and moderate to severe in nine patients. The record of the triggering of motor units was normal in both groups during the period pre-swallow/post-swallowing. The research kinesiological revealed that the number of patients who showed no shots of electromyographic activity during the period of pre-swallowing had a positive correlation with the severity of reflux and the quantity of liquid swallowed. Shots passed were observed in patients with reflux and in the control group. The duration of the pre-swallowing and the shots passed (rebound burst) was similar in all groups.

The duration of swallowing, corresponding to the period of silence, electrophysiological was shorter in patients with gastroesophageal reflux disease lightweight, when compared to the group of healthy subjects, and the group with moderate dysphagia and severe. The swallowing in parts (piece meal deglutition) the volume of 10 ml was high in patients with gastroesophageal reflux disease moderate to severe. Also, found a positive correlation of the number of swallowing with the severity of reflux.

Alkan et al. (2012)²³ concluded that electromyography of needle of the upper esophageal sphincter, was normal in patients with gastroesophageal reflux disease. The ratings kinesiological, showed an increase in piecemeal deglutition and in the number of swallowing, and correlated, thus, positively correlated with the severity of reflux. And bring as contributions, important results on the electrophysiological behavior

of the cricopharyngeal muscle during your rest and in swallowing in patients with gastroesophageal reflux disease.

Inokuchi et al. (2014)²⁴

In this study, the researchers analyzed the electromyographic signal, picked up by fine-wire electrodes, during swallowing, to determine the typical sequence of activation of muscles involved in swallowing in normal subjects (no dysphagia). From their results, they determined the time of activation of the muscles (of the geniohyoid, anterior belly of the digastric, esternohyoideous and masseter) and compared these times between the different consistencies (Tables 1 and 2).

Considering the “onset” of of the geniohyoid muscle as reference (first moment of swallowing - 0s), these researchers found that the intake of thickened liquids, the masseter, of the geniohyoid and anterior digastric belly, they were activated always simultaneously; while esternohyoideous muscle was activated later. With solid foods, the contraction of the masseter precedes the time of activation of of the geniohyoid muscle and anterior digastric belly, while the activation of the muscle was later esternohyoideous and lagging behind swallowing liquids.

The role of the masseter differs between solid and liquid food so that the change in its delay is expected. The timing contraction of of the geniohyoid muscles and anterior digastric belly was consistent with its important role in laryngeal elevation. The contraction of the muscle esternohyoideous was always after the other muscles studied both in swallowing liquids and solids.

This sequence confirms previous studies, which described the events related to swallowing. Initially, there is the closing of the mouth and jaw stabilization by the action of the levator muscles of the jaw (masseter among them). Then the suprahyoid muscles (especially genius-hyoid and digastric anterior belly) move the hyoid bone, upper and above. This action facilitates the clearance of the mouth by the action of the tongue and opening of the upper esophageal sphincter. Finally, infrahyoid muscles, represented by esternohyoideous, pull the hyoid bone inferiorly and subsequently providing their return to resting position characterizing the end of swallowing^{31,32}.

Inokuchi et al. (2014)²⁴ found that the pattern of activation of the hyoid muscles during swallowing food consistencies of the different supports the concept

of the central pattern generator to the pharyngeal swallowing (Table 2).

In this article, the authors did not mention what was offered in liquid consistency thickened, and also not mentioned the band pass filter set in electromyography equipment. The absence of such information can hamper the realization of this protocol in other studies; besides the fact that different methodologies may lead to different results.

However, it can be considered that the study confirms the findings of different researchers and brings as contributions activation sequence of muscles involved in swallowing. This information can come to help the electrophysiological evaluations, with incoordination identification muscle activation that would result in deficits in oral motor control and risk of penetration and/or aspiration of food content, requiring further research to validate the results.

In the past, the needle electromyography was quite used to further the understanding of the electrophysiological behavior of muscles involved in swallowing and to be quite uncomfortable, most studies have been conducted in animal models.

These studies are not recent; the first survey was conducted by Doty and Bosman in 1956³³. In this study, the electromyographic during swallowing was observed in 22 muscles of the mouth area, pharynx and larynx of monkeys, dogs and cats through electromyography needle (cooper wire type electrodes).

These scholars have identified a complex of muscles that considered key to the mechanism of swallowing, they are: higher pharyngeal constrictor, palatopharyngeal, palatoglossus, posterior intrinsic muscles of the tongue, styloglossus, stylohyoid, geniushyoid and mylohyoid. Surprisingly, different from that found

in the study of Vitti and Basmajian (1977)¹⁸, Doty and Bosman (1956)³³ found electrophysiological silence of digastric and sternohyoideous muscles, besides the previous sternothyroid and intrinsic muscles of the tongue of cats and dogs during swallowing. Thexton (2007)³⁴ recreated the study Doty and Bosman (1956)³³ evaluating swallowing eight young pigs from the radiographic simultaneous study the electromyographic examination, carried out with the hook type electrodes (fine wire) 16 muscles and get results that approached the description by Doty and Bosman, identifying a main complex of muscles involved in this mechanism. However, the mylohyoid muscle has not been activated early on in relation to the other and of the geniohyoid muscle there was not part of this complex. Some classically considered inactive muscles showed active in the pharyngeal phase of swallowing, including the digastric.

There is disagreement on the results of these studies which may be related to methodological differences, such as equipment specifications, different contents and volumes offered, various samples (different animal species with a variation in the thickness and length of the studied muscles) and including the limitations imposed by own method of analysis. However, it is notorious and devoted the importance of mylohyoid muscles, of the geniohyoid and anterior digastric belly swallowing humans, acting synergistically and jointly. The mylohyoid raises hyoid bone, the floor of the mouth and tongue and plays an important role in the early stages of swallowing. The anterior belly of the digastric directs the hyoid bone up and forward and of the geniohyoid muscle also acts on the rise and the hyoid anteriorly swallowing³⁵.

Table 1. Technical specifications of electromyography.

	Ertekin et al, 2000 ¹⁸	Ertekin et al, 2001 ¹⁹	Baudon et al, 2002 ²⁰	Renault et al, 2011 ²¹	Inokuchi et al, 2014 ²²	Alkan et al, 2012 ²³
Muscles	- Movement of the larynx -MSH -Cricopharynxeous	- Movement of the larynx -MSH - Cricopharynxeous	- Genioglossus -Tireohioideous	-Orbicular of the eyes -Elevator of the velum -Palatoglosso -Genioglosso -Tieohioideous	-Geniohioideous -Anterior belly of digastric -Esternohioideous	-Muscle cricopharynxeous
Electrodes	Bipolar surface and electrode of needle (DMC-37).	Bipolar surface and electrode of needle (DMC-37).	Monopolar concentric needle	Concentric needle (25 mm 30 of caliber)	Hook wire 40 gauge and needle with 27 de caliber of 12,5 mm, hypodermic and sterile. And used the retificated and integrated signal.	Bipolar concentric needle of 26 gauge.
Technical Specifications						
Filter	Band-pass of 100 Hz – 10kHz, amplificado, retificado e integrado	Band-pass of 100 Hz – 10kHz, amplified, retificated and integrated.	Does not refer	Does not refer	Does not refer	Band-pass (100Hz – 10KHz).
Sample charge	Does not refer	Does not refer	Does not refer	Does not refer	1,5 à 3 KHz	Does not refer
Other integrated resources	Sensor Piezoelectric: filter band-pass: 0.01-20 Hz	Sensor Piezoelectric: Filter band-pass of 0.01-20 Hz	_____	_____	_____	_____
Associated tests	_____	_____	Manometry	_____	VF: Exposition de 5 min à 90 KV	_____
Parameters electrophysiological	-TRL -DD -TRDD - VD (jitter) -A EMG of MSH -LD	-Coordination between the sucking and swallowing.	-Maximum Amplitude of suction; -Coordination between the sucking and swallowing	-Moments of the beginning of muscle activation (onset)	-DD -PD -PPD -DPD -DR -Nº D	-Electromyographic amplitude

EMG: Electromyography; Hz: Hertz; kHz: Kilohertz; mm: mm; EMGi: intramuscular Electromyography; KV: Kilovolt; microvolts: microvolts; TRL-Time for the repositioning of the larynx; DD-Duration of swallowing; TRDD-Time for carrying out the shooting of swallowing; VD-variability of swallowing (jitter); AEMG: EMG Amplitud; MSH: supra-hyoid Muscles; LD: dysphagia limit; PD: Peace meal deglutition; PPD: Presence of pre-swallowing; DPD: length of pre-swallowing; Dr: Shots passed; Paragraph (D): number of swallows.

Table 2. Methodological characteristics of selected articles of BIREME and PUBMED.

	Vitti & Basmajian, 1977 ¹⁸	Ertekin et al, 2000 ¹⁹	Ertekin et al, 2001 ²⁰	Baudon et al, 2002 ²¹	Renault et al, 2011 ²²	Alkan et al, 2012 ²³	Inokuchi et al, 2014 ²⁴
Title	Integrated action of the muscles of mastication: simultaneous EMG eight intramuscular electrodes	Fisiopatológicos mecanismos of dysphagia orofaringea in Amyotrophic Lateral Sclerosis	Electrophysiological assessment of oropharyngeal swallowing in myotonic dystrophy.	Motor dysfunction of upper digestive tract in the Pierre Robin Sequence evaluated by Electromyography of swallowing and esophageal manometry-sucção.	Facial, lingual and pharyngeal electromyography in children with Pierre Robin sequence	Electrophysiological findings of cricofaríngeo muscle in patients with gastroesophageal reflux disease	Electromyography of swallowing with intramuscular fine wire electrodes in humans healthy: following activation of muscles hióideos
Objective	Analyse comprehensively the myoelectric activity of masseter, temporal intramuscular, medial pterygoid, belly of the digastric, milo-hióideo and geniú-hióideo muscles in normal subjects "	Investigate the pathophysiological mechanisms of dysphagia in her through clinics and eletrofisiológicas measures	Show the existence and frequency of sub-clinical abnormalities in oro-pharyngeal swallowing and sort the mechanisms of dysphagia in DM by EMG.	Evaluate the motor dysfunction in children with PRS that upper airway obstruction manifestamvam and congenital dysphagia.	Assess the relevance of the combined techniques of EMG in evaluation and management of children with SPR	Analyze the relationship between the level of severity of GERD and contraction patterns and behavior of DBM through analysis of electrophysiological measures of this muscle	Analysis of the electromyographic signal during swallowing to determine the typical muscle activation sequence hióideos.
Population/ Age	29 healthy adults/20-47years	43/36-72 years-50/30 SHE-75 years-normal	18/19-66 years-30 DM/25-65 years-normal	28/babies to term (15 to 45 days)-SPR 16/ under 3 months of age-infants with gastroesophageal reflux (GERD)	81/babies at the end of the first month showing the SPR	24 patients with GERD/age less than 60 years 21 healthy subjects/age below 60 years	Thirteen healthy adults/22 ± 4 years
Sample	The sample was composed of healthy subjects. There was no comparisons.	The sample was composed of two main groups-1: GND, 2: GD. The GD group was subdivided into: subject with SCPD, SCBI and SCBP	The sample was composed of 4 groups: 1: disfágico, 2: disfágico, 3: not with symptoms of CNS involvement, 4: showing congenital myotonia for the study of the effects of myotonia.	The sample was composed of 3 groups. 1: ADR and absence of dysphagia; 2: ADR and presence of dysphagia requiring VA and 3: PAIR and presence of dysphagia with use of nasopharyngeal tube.	The sample was composed of three groups: 1: ADR and DT with AOL before a month of born, 2: ADR, but with DD, 3: with COUPLE that prevent any attempt of AVO and present DD.	The sample was composed of three groups: Group 1: healthy Group 2 participants: GERD take Group 3: moderate to severe GERD	The sample was composed of healthy subjects. Comparisons were made between the consistencies and muscles tested
Tests	Intake of water: (a) sipping water; (b) water retention in the mouth for 5 seconds (c) swallowing	-Swallowing test of growing volumes of water-LD-swallowing dry test (saliva)	Swallowing of growing volumes of water of 1, 3, 5, 10, 15 and 20 ml-LD	-The suction-swallowing EMG the baby sucked water from a bottle (for comparison between the 3 groups with SPR); -For dried deglutições was asked 10 manometry (to compare the PRS group with babies with GERD).	-Weeping and suction; -Flashing Movements; -Coordination between swallowing and sucking, while baby sucks water from a bottle.	-swallowing dry 3 ml of water-5 ml of water-10 ml of water	-10 ml of a liquid thickened-6 g banana; -6 g of tofu consistent-6 g of a "cookie"
Used tools	-EMGi with bipolar electrode type fine wire EMG graduation method proposed by Basmajian (1974)	-Laringeo Sensor (pie-zoelétrico); -Songs-EMGi with needle electrode	-Laringeo Sensor (pie-zoelétrico); -Songs-EMGi with needle electrode	-Needle EMGi-esophageal Manometry.	-Needle EMGi	-EMGi with needle-electrode pH monitoring-protocol Demeester score-gastrointestinal Endoscopy high	-EMGi with hook-wire electrode-Songs-VF

Conclusion	DS: activation occurs: the medial pterygoid and MSH, fickle and take masseter muscle contraction SAC: MSH activation occurs so fickle and vile. CHECK: there's the recrutamento of myoelectric activity. FROM: recruit the contraction of MSH and medial pterygoid muscle	There are 2 pathophysiological mechanisms in dysphagia of SHE: 1-the firing of the reflex, swallowing volunteer is late or absent; While in automatic reflex, swallowing is preserved. 2-MCF: hypertonic and can be found hiperreflexivo. and DPFC related	CNS involvement may contribute to the delay in the firing of the swallowing reflex, and abnormal EMG findings from EES cause dysphagia in this disease.	The EMG and manometry were able to identify shortcomings in the Organization of motor language, pharynx and esofago even in the absence of clinical disorders in swallowing.	The EMG on SPR revealed abnormalities in swallowing, even in cases considered normal, making it possible to evaluate both the gravity and the duration of the potential of dysphagia. And the low amplitude detected in MPM demonstrate the need for two surgical steps of repair of cleft palate.	The EMGi ESS needle was normal in patients with GERD. Cinesiológicas assessments showed increased Peacemeal deglutition and number of swallows and that there was a positively with the severity of the reflux	The pattern of activation of hióideos muscles found in swallowing of different food consistencies corroborates with the default generator concept central to the swallowing pharyngeal.

ALS: Amyotrophic Lateral Sclerosis; DM: muscular dystrophy; SPR: Sequence of Pierre Robin; EMG: Electromyography; GERD: Gastroesophageal Reflux Disease; ml: ml; CENTRAL NERVOUS SYSTEM: central nervous system; EES: Upper esophageal sphincter; LD: Limit of dysphagia; SEMG: Surface Electromyography; EMGi: intramuscular Electromyography; VF: Videofluoroscopy; MCF: cricopharyngeal; DPFC: progressive degeneration of the fibers corticobulbars; GND- Group not with dysphagia; GD- group with dysphagia; SCPB- PSEUDOBULBAR concern; SCBI -subjects with inferior bulbar concern; SCBP - individuals with bulbar commitment and pseudobulbar; VA - track alternative ADR absence of respiratory disorders; DT ; AOL -oral feeding freedom; ADR- absence of respiratory disorders, DD- lasting dysphagia; pair-presence of respiratory changes; AVO- oral feeding; DS: swallowing of saliva; SAC: drinking water from glass; STRAW: holding the water in the oral cavity; From: swallowing of water; MPM: muscles of the soft palate.

CONCLUSION

The selected articles make important contributions to the understanding of the electrophysiological behavior and electrophysiological during the mechanism of swallowing, and it is believed that the lack of research using intramuscular EMG for analysis of swallowing in humans should be the trouble and risks caused by the introduction of needle into the muscle belly and maybe the introduction of a thin wire (fine wire or wire cooper) is more interesting for the aid diagnosis of neuromuscular disorders and nerve that compromise swallowing, the ability to dramatically reduce the annoyance caused by the needle.

REFERENCES

- Crary MA, Baldwin BO. Surface electromyographic characteristics of swallowing in dysphagia secondary to brainstem stroke. *Dysphagia*. 1997;12:180-7.
- Ertekin C, Palmer JB. Physiology and electromyography of swallowing and its disorders. *Suppl Clin Neurophysiol*. 2000; 53:148-54.
- Vaiman M. Standardization of surface electromyography utilized to evaluate patients with dysphagia. *Head Face Med*. 2007;3: 26.
- Gokyigit M, Pazarci N, Ercan I, Seker S, Turgut S, Ertekin C. Identification of distinct swallowing patterns for different bolus volumes. *Clinical Neurophysiology*. 2009;120(9):1750-4.
- Pelman A, Palmer P, McCulloch T, Vandaele D. Electromyography activity from human laryngeal, pharyngeal, and submental muscles during swallowing. *J Appl Physiol*. 1999;86:1663-9.
- Logemann JA. Non-imaging techniques for the study of swallowing. *Acta Otorhinolaryngol Belg*. 1994;48:139-42.
- Portney L, Roy SH. Eletromiografia e testes de velocidade de condução nervosa. In: O` Sullivan SB, Schmitz TJ. *Fisioterapia: avaliação e tratamento*. São Paulo: Manole, 2004. p. 213-56.
- Preston DC, Shapiro BE. Electromyography and Neuromuscular Disorders: Clinical Electromyography and Neuromuscular disorders. In: Preston DC, Shapiro BE. *Neuromuscular Junction Disorders*, Elsevier- Butterworth – Heinemann, 2005. p. 407-24.
- Vaiman M, Eviatar E, Segal S. Surface electromyographic studies of swallowing in normal subjects: A review of 440 adults. Report 2. Quantitative data: Amplitude measures. *Otolaryngol Head Neck Surg*. 2004;131(5):773-80.
- Belo LR, Lins S, Cunha D, Lins O, Amorim C. Eletromiografia de superfície da musculatura supra-hióidea durante a deglutição de idosos sem doenças neurológicas e idosos com Parkinson. *Rev CEFAC*. 2009;11(2):268-80.

11. Coriolano MGW, Lins OG, Belo LR, Menezes DC, Moraes SRA, Asano AG et al. Monitorando a deglutição através da eletromiografia de superfície. *Rev CEFAC*. 2010;12(3):434-40.
12. Cram J, Kasman GS. The basics of electromyography. In: Criswell E. *Cram's Introduction to surface electromyography*. 2ª edição. Massachusetts: Jones and Bartlett Publishers; 2011. p.35-61.
13. Hillel AD. The Study of Laryngeal Muscle Activity in Normal Human Subjects and in Patients With Laryngeal Dystonia Using Multiple Fine-Wire Electromyography. *Laryngoscope*. 2001;111:1-47.
14. Rudroff T. *Kinesiological Fine Wire EMG: A practical introduction to fine wire EMG applications*. Arisona: Noraxon U.S.A; [citado em 2008]. Disponível: <http://www.noraxon.com/downloads/educational.php3>
15. De Luca CJ. The Use of Surface Electromyography in Biomechanics. *J Appl Biomech*. 1997;13:135-63.
16. Castro AA, Clarck OAC, Atallah AN. Optimal search strategy for clinical trials in the Latin American and Caribbean Health Science Literature Database (LILACS database): Update. *Med J/Rev Paul Medm*. 1999;117(3):138-9.
17. Dickersin K, Scherer R, Lefebvre C. Identifying relevant studies for systematic reviews – Systematic Reviews. *BMJ*. 1994;309:1286-91.
18. Vitti M, Basmajian JV. Integrated actions of masticatory muscles: Simultaneous EMG from Eight intramuscular electrodes. *Anat Rec*. 1977;187(2):173-89.
19. Ertekin C, Aydogdu I, Yüceyar N, Kiylioglu N, Tarlaci S, Uludag B. Pathophysiological mechanisms of oropharyngeal dysphagia in amyotrophic lateral sclerosis. *Brain*. 2000;123:125-40.
20. Ertekin C, Yüceyar N, Aydogdu I, Karasoy H. Electrophysiological evaluation of oropharyngeal swallowing in myotonic dystrophy. *J Neurol Neurosurg Psychiatry*. 2001;70:363-71.
21. Baudon JJ, Renault F, Goutet JM, Flores-Guevara R, Soupre V, Gold F et al. Motor dysfunction of the upper digestive tract in Pierre Robin sequence as assessed by sucking-swallowing electromyography and esophageal manometry. *J Pediatr*. 2002;140:719-23.
22. Renault F, Baudon JJ, Galliani E, Flores-Guevara R, Marlin S, Garabedian EN, Vazquez MP. Facial, lingual, and pharyngeal electromyography in infants with pierre robin sequence. *Muscle & Nerve*. 2011;43(6):866-71.
23. Alkan Z, Demir A, Yigit O, Adatepe T, Kesici B, Kocak I et al. Cricopharyngeal Muscle Electromyography Findings in Patients with Gastroesophageal Reflux Disease. *Otolaryngol Head Neck Surg*. 2012;147(2):295-301.
24. Inokuchi H, Gonzáles- Fernandes M, Koichiro M, Brodsky M, Yoda M, Taniguchi H et al. Electromyography of swallowing with fine wire intramuscular electrodes in healthy human: Activation Sequence of selected hyoid muscles. *Dysphagia*. 2014;29:713-21.
25. Cunningham DP, Basmajian JV. Electromyography of genioglossus and geniohyoid muscles during deglutition. *Anat. Rec*. 1969;165:401-10.
26. Lehr RP, Blanton PL, Biggs NL. An Electromyographic study of the mylohyoid muscles. *Anat Rec*. 1971;169(4):651-60.
27. Hrycyszyn AW, Basmajian JV. Electromyography of the oral stage of swallowing in man. *Am. J. Anat*. 1972;133:333-40.
28. Cleall JF. Deglutition: A Study of form and function. *Am. J. Orthodont*. 1965;51(8):566-94.
29. Renault F, Raimbault J. Electromyographie faciale, linguale et pharyngée chez l'enfant: une méthode d'étude des troubles de succion-déglutition et de leur physiopathologie. *Neurophysiol Clin*. 1992;22:249-60.
30. Renault F. Facial electromyography in newborn and young infants with congenital facial weakness. *Dev Med Child Neurol*. 2001;43(6):421-7.
31. Ohsawa S, Yamamoto S, Kanda A. Lower lip-lifting brace for bilateral facial nerve palsy: a case report. *Arch Phys Med Rehabil*. 2001;82(12):1737-9.
32. Tamura F, Fukui T, Kikutani T, Machida R, Yoshida M, Yoneyama T et al. Lip-closing function of elderly people during ingestion: comparison with young adults. *Int J Orofacial Myology*. 2009;35:33-43.
33. Doty RW, Bosma JF. An electromyographic analysis of reflex deglutition. *J Neurophysiol*. 1956;19:44-60.
34. Thexton AJ, Crompton AW, German RZ. Electromyographic activity during the reflex pharyngeal swallow in the pig: Doty and Bosma (1956) revisited. *J Appl Physiol*. 2007;102:587-600.
35. Zemlim WR. *Princípios de anatomia e fisiologia em fonoaudiologia*. Porto Alegre: Artmed; 2002.