

# Rheumatoid arthritis evolving with rheumatoid vasculitis. Case report\*

*Artrite reumatoide evoluindo com vasculite reumatoide. Relato de caso*

Adrian Nogueira Bueno<sup>1</sup>, Renata Magalhães Alves<sup>2</sup>

\* Received from Teaching Hospital Alzira Vellano, University José do Rosário Vellano (UNIFENAS). Alfenas, MG.

## SUMMARY

**BACKGROUND AND OBJECTIVES:** Rheumatoid arthritis (RA) is a chronic, mostly insidious disease of unknown etiology, the primary manifestation of which is persistent synovitis symmetrically affecting peripheral joints. Cartilaginous injuries and bone erosions with subsequent changes in articular integrity are the primary marks of the disease. RA is a systemic disease affecting other organs and systems such as skin, heart, lungs, and muscles and, less commonly, blood vessels leading to rheumatoid vasculitis. This study aimed at describing an RA case evolving with rheumatoid vasculitis, which is a rare and severe condition.

**CASE REPORT:** Female patient, 61 years old, with RA starting with lower limbs edema, pain, erythema and local heat, and evolving with hard nodules which ulcerated. The gluteus region had erythema in plaques, without pruritus, painless, with nodules similar to those of the legs, which also ulcerated. Moderate pain was controlled with oral tramadol and paracetamol.

**CONCLUSION:** Rheumatoid vasculitis is a severe RA complication which may lead to limb amputation and evolves with moderate pain easily controlled with weak opioids.

**Keywords:** Rheumatic fever, Rheumatoid arthritis, Vasculitis.

## RESUMO

**JUSTIFICATIVA E OBJETIVOS:** A artrite reumatoide (AR) é uma doença crônica, na maioria é insidiosa, de etiologia desconhecida, cuja principal manifestação é a sinovite persistente com acometimento de articulações periféricas de forma simétrica. A lesão na cartilagem e as erosões ósseas com as mudanças subsequentes na integridade articular são as principais marcas da doença. A AR é uma doença sistêmica, em que acomete outros órgãos e sistemas, como pele, coração, pulmões, músculos e, mais raramente, vasos sanguíneos levando a vasculite reumatoide. O objetivo deste estudo foi descrever um caso de AR evoluindo com vasculite reumatoide, uma condição rara e grave.

**RELATO DO CASO:** Paciente sexo feminino, 61 anos, portadora de AR que iniciou com quadro de edema nos membros inferiores, dor, eritema e calor local, evoluiu com nódulos duros que ulceraram. Na região glútea apresentou eritema em placas, sem prurido, indolor, com nódulos semelhantes aos das pernas que também ulceraram. A dor de intensidade moderada foi controlada com tramadol e paracetamol, por via oral.

**CONCLUSÃO:** A vasculite reumatoide é complicação grave da AR que pode levar a amputação do membro e evolui com dor moderada facilmente controlada com opioides fracos.

**Descritores:** Artrite reumatoide, Febre reumática, Vasculite.

## INTRODUCTION

Rheumatoid arthritis (RA) or rheumatoid disease (Dre) is of chronic inflammatory origin and affects 0.5% to 1% of world population, without distinction of races and being more common among females<sup>1,2</sup>.

It may start at any age, being more common from 30 to 50 years of age. To date, it has multifactorial etiology relating environmental, behavioral and genetic (HLA-

1. Rheumatologist and Professor of Rheumatology of the School of Medicine, University José do Rosário Vellano (UNIFENAS). Alfenas, MG, Brazil.

2. Medical Student, University José do Rosário Vellano (UNIFENAS). Alfenas, MG, Brazil.

Correspondence to:

Adrian Nogueira Bueno, MD.

Rua Irmão Mário Esdras, 42 – Vila Pinto  
37010-660 Varginha, MG.

Phone: (35) 3212-8740

E-mail: adrian\_6349@hotmail.com

DR4 and maybe DR1 in some populations) factors, immune unbalance and neuroendocrine changes<sup>3</sup>.

RA is a systemic inflammatory disorder which may affect several tissues and organs, such as skin, blood vessels, heart, lungs and muscles, but it primarily affects joints producing inflammatory nonsuppurative synovitis which in general evolves to joint cartilage destruction and joint ankylosis<sup>1</sup>.

Clinical evolution may vary from moderate short-lasting oligoarticular disease with minor joint injury to progressive irreversible polyarthritis with marked functional loss<sup>4</sup>.

Most frequently involved joints at early disease are wrists, metacarpophalangeal, hands proximal interphalangeal, metatarsophalangeal joints, shoulders and knees, with severe pain in the morning and at night, and joint stiffness lasting 60 minutes or more in the morning and after prolonged immobilization periods<sup>3</sup>.

Systemic RA manifestations may be considered as arising from the release of synovial inflammatory substances, such as IL-1, TNF and IL6. In addition, complex immunes produced inside the synovium enter the circulation and may cause systemic vasculitis<sup>4</sup>.

This study aimed at describing a case of RA evolving with rheumatoid vasculitis, which is a rare and severe condition.

## CASE REPORT

Female patient, 62 years old, Caucasian, with history of rheumatic fever since 8 years of age, treated with muscular benzathine penicillin every 21 days, however evolving with heart sequelae. Eighteen years later she was submitted to surgery to replace mitral valve with biological prosthesis. Two months ago she presented lower limbs edema, ankle pain, local erythema and heat, evolving with hard nodules which ulcerated (Figure 1). She also presented erythema in plaques in the gluteus region, without pruritus, painless, with nodules similar to those of the legs, which have also ulcerated (Figure 2). Moderate pain was controlled with oral tramadol (37.5 mg) and paracetamol (500 mg) every 6 hours.

Laboratory tests have shown the following results: VHS = 20 mm, GGT = 134 u/l, PCR = 12, anti-CCP = 380, FAN = -(neg), PPD = -(neg), TSH = 1.94 mg/dL, normal blood count, 24 h proteinuria = 0.25 g and creatinine clearance = 44.8 mL/min/1,73m<sup>2</sup>. Pulsotherapy was performed with methylprednisolone (1 g) for three days and then with cyclophosphamide for 6 months, with significant vasculitis remission and pain intensity improvement.

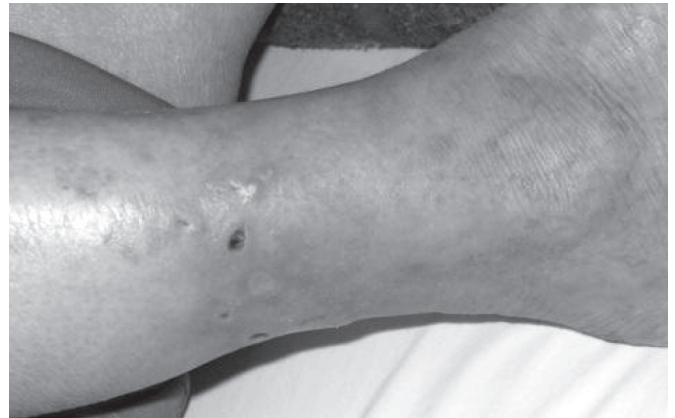


Figure 1 – Vasculitic lesion secondary to rheumatoid arthritis on right lower limb.

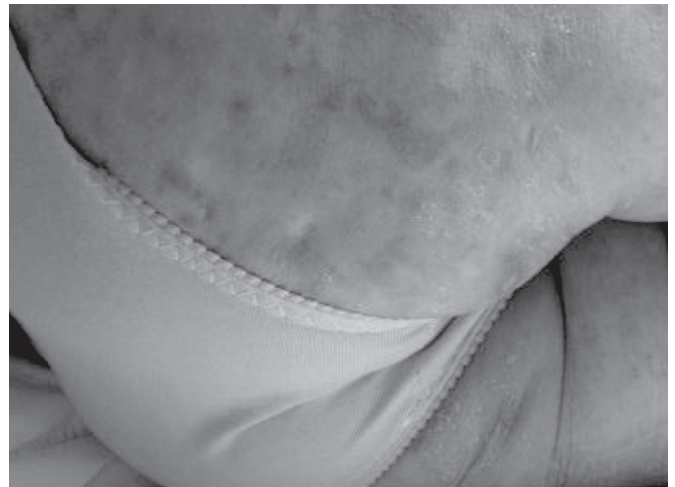

Figure 2 – Vasculitic lesion secondary to rheumatoid arthritis on the gluteus region.

## DISCUSSION

Skin affection is very variable and may encompass from periungual infarctions to extremities gangrene, including lower limb ulcers and skin erythemas. Although uncommon, *vasa nervorum* affection may cause peripheral neuropathy with sensory and motor involvement. As most extra-articular manifestations, vasculitis is especially seen in seropositive patients, almost always unrelated to the joint disease activity<sup>1</sup>.

Rheumatoid vasculitis may affect any organ, being commonly observed in patients with severe arthritis and high rheumatoid factor titles. Skin vasculitis in general is presented as groups of small brownish spots in ungual bed and folds and in digital pulps<sup>4</sup>.

Types of vasculites are: leukocytoclastic vasculitis – in general presented as palpable purpura and results in inflammation of post-capillary venules; small vessels vasculitis – presented as small digital pulp infarctions and

frequently associated to mild distal sensory neuropathy caused by vasculitis in nervous vessels; medium vessels vasculitis – may mimic polyarteritis nodosa with visceral arteritis, multiple mononeuritis and reticular livedo and pyoderma gangrenosum<sup>5</sup>.

## CONCLUSION

Rheumatoid vasculitis is a severe rheumatoid arthritis complication which may lead to limb amputation and evolves with moderate pain easily controlled with weak opioids.

## REFERENCES

1. Rantalaiho V, Kautiasnen H, Virta L, et al. Trends in treatment strategies and the usage of different disease-modifying anti-rheumatic drugs in early rheumatoid arthritis in Finland. Results from a nationwide register in 2000-2007. *Scand J Rheumatol* 2011;40(1):16-21.
2. Hamilton JA, Tak PP. The dynamics of macrophage lineage populations in inflammatory and diseases. *Arthritis Rheum* 2009;60(5):1210-21.
3. Sokka T, Makinen H. Remission makes its way to rheumatology. *Arthritis Res Ther* 2010;(4):129.
4. Mottonen T, Makinen H, Puolakka K. The goal for the treatment of rheumatoid arthritis should be remission. *Duodecim* 2010;126(12):1457-64.
5. Carter PJ. Potent antibody therapeutics by design. *Nat Rev Immunol* 2006;6(5):343-57.

Presented in October 28, 2010.

Accepted for publication in November 22, 2011.