



Laser therapy in pressure ulcers: evaluation by the Pressure Ulcer Scale for Healing and Nursing Outcomes Classification

Laserterapia em úlcera por pressão: avaliação pelas *Pressure Ulcer Scale For Healing e Nursing Outcomes Classification*

Laserterapia en úlcera por presión: evaluación por la *Pressure Ulcer Scale For Healing y Nursing Outcomes Classification*

Sofia Palagi¹, Isis Marques Severo², Dóris Baratz Menegon³, Amália de Fátima Lucena²

¹ Universidade Federal do Rio Grande do Sul, Hospital de Clínicas, Residência Multiprofissional em Adulto Crítico, Porto Alegre, RS, Brazil.

² Universidade Federal do Rio Grande do Sul, Escola de Enfermagem, Porto Alegre, RS, Brazil.

³ Universidade Federal do Rio Grande do Sul, Hospital de Clínicas, Serviço de Enfermagem em Saúde Pública, Porto Alegre, RS, Brazil.

ABSTRACT

Objective: To describe the pressure ulcer healing process in critically ill patients treated with conventional dressing therapy plus low-intensity laser therapy evaluated by the Pressure Ulcer Scale for Healing (PUSH) and the result of Wound Healing: Secondary Intention, according to the Nursing Outcomes Classification (NOC). **Method:** Case report study according to nursing process conducted with an Intensive Care Unit patient. Data were collected with an instrument containing the PUSH and the result of the NOC. In the analysis we used descriptive statistics, considering the scores obtained on the instrument. **Results:** A reduction in the size of lesions of 7cm to 1.5cm of length and 6cm to 1.1cm width, in addition to the increase of epithelial tissue and granulation, decreased secretion and odor. **Conclusion:** There was improvement in the healing process of the lesion treated with adjuvant therapy and the use of NOC allowed a more detailed and accurate assessment than the PUSH.

DESCRIPTORS

Pressure Ulcer; Laser Therapy; Wound Healing; Treatment Outcome; Nursing Process; Intensive Care Units.

Corresponding author:

Amália de Fátima Lucena
Rua São Manuel, 963, Bairro Rio Branco
CEP 90620-110 – Porto Alegre, RS, Brazil
afatimalucena@gmail.com

Received: 05/21/2015
Approved: 07/02/2015

INTRODUCTION

Pressure ulcers (PU) are areas of damage in the skin and underlying structures resulting from isolated or combined pressure with shear and/or friction, which can be classified according to the degree of tissue damage observed⁽¹⁾.

PU are configured as one of the most prevalent complications in hospitalized patients with high incidence in Intensive Care Units (ICU) due to the severity of the patient and the complexity of their treatment, associated with difficult implementation of preventive measures in skin integrity maintenance⁽¹⁻²⁾. Brazilian studies have shown that the incidence of PU in ICU varies from 25.8% to 62.5% and in the international literature it is 13% to 21%⁽²⁻⁴⁾, which shows that, despite preventive measures, PU are still common in critically ill patients, thus, becoming a constant challenge for health professionals⁽⁵⁻⁷⁾.

The high incidence of PU is considered a negative indicator in the quality of nursing care, however, there are situations in which even though preventable, they are inevitable. In this case, the implementation of appropriate treatment is necessary, which urges nurses to seek new interventions^(2,4-5). Among the resources for the treatment of PU, the dressing with different toppings is considered the standard treatment, but with benefit in the medium and long term healing process, depending on the extent and depth of the lesion and the patient's condition⁽⁴⁻⁵⁾. Thus, new treatments to accelerate the healing process of these lesions have been investigated, among which ultrasound, Ozone therapy and Low-Level Laser Therapy – (LLLT)⁽⁸⁻⁹⁾.

The LLLT is amplified in low light radiated power capable of promoting biochemical, bioelectric and bioenergetic effects⁽¹⁰⁾, presented by the National Pressure Ulcer Advisory Panel (NPUAP)⁽¹⁾ as a way of further treatment for the PU. However, there is still lack of evidence about its effectiveness, which may be related both to the absence of protocols that standardize its use and the different experimental models used in humans, making it difficult to compare studies.

Added to this, there was also the absence of investigations evaluating the use of the LLLT with standard instruments, such as, a Pressure Ulcer Scale for Healing (PUSH)⁽¹¹⁾ and Nursing Outcomes Classification (NOC)⁽¹²⁾.

The PUSH is a specific instrument for evaluating the PU healing process with three parameters: the wound area, the wound tissue type and exudate amount. The sub scores for these parameters, when combined, generate a total score, which can range from zero to 17. Higher scores indicate worse PU and low scores indicates improvement in PU healing processes⁽¹¹⁾.

The NOC⁽¹²⁾ is a nursing outcomes classification tool that has been used in studies of clinical practice⁽¹³⁻¹⁴⁾ for evaluation of nursing interventions with standardized language use. According to this classification, the evaluation of a nursing outcome assumes the initial collection of patient data, in order to support an accurate nursing diagnosis (ND) to establish appropriate goals and interventions. To describe a ND one can use the NANDA International Classification (NANDA-I)⁽⁶⁾, in the same way that the Nursing Interventions Classification (NIC) is used to describe interventions⁽¹⁵⁾.

Thus, taking into account investigations that suggest that LLLT is a safe, effective, and complement form of treatment for the PU, with potential benefit to accelerate the healing process⁽¹⁶⁾, to increase tissue granulation⁽¹⁷⁾, to decrease

wound^(16,18), to reduce inflammatory process⁽¹⁷⁾ and to reduce pain⁽¹⁶⁾, we developed the present study. The objective was to describe the pressure ulcer healing process in critically ill patients treated with conventional dressing therapy plus low-intensity laser therapy evaluated by Pressure Ulcer Scale for Healing (PUSH)⁽¹¹⁾ and the result Wound Healing: Secondary Intention, according to Nursing Outcomes Classification (NOC)⁽¹²⁾.

The finality of the study was to monitor the PU healing process in critically ill patients by the use of non-invasive measurement techniques, which are able to define the lesion stages of evolution in a more sensitive, objective, reproducible and comparable way than clinical evaluation alone⁽¹⁹⁾.

METHOD

This is a case-report study⁽²⁰⁾ guided by the nursing process and the classification systems NANDA-I, NIC and NOC^(6,12,15), in a high complexity teaching hospital ICU, in the city of Porto Alegre, Brazil. The research subject consisted of one patient selected according to the following criteria: 18 years old or older, without gender or race restrictions, with PU Class II or higher and surface area of around 30cm. Exclusion criteria were: pregnancy, PU with surface area greater than 45cm², PU with extensive tunneling, uncontrolled diabetes mellitus, immunosuppression, acute bleeding, thrombocytopenia and use of corticosteroids.

Data collection for the evaluation of the lesion was performed by three research Nurses (two with experience in ICUs and one in dermatology) trained to use the instrument that included the PUSH scale⁽¹¹⁾ and the result from NOC Wound Healing: Secondary Intention with 12 indicators (granulation, scar formation, decreased wound size, purulent drainage, serous drainage, sanguineous drainage, serosanguineous drainage, surrounding skin erythema, periwound edema, blistered skin, macerated skin and foul wound odor). These indicators were selected by the researchers based on their clinical practice. For all of them, conceptual and operational definitions have been prepared according to the literature, considering its magnitude in five points Likert scales according to NOC, in order to allow an objective and reliable evaluation⁽¹²⁾.

The assigned PUSH score⁽¹¹⁾ and the result indicators of NOC⁽¹²⁾ resulted from the consensus of the three nurses who applied the instrument immediately prior to LLLT. The photographic record of the evolution of wound healing was also performed.

The application of LLLT intervention was performed by the research nurse specialist in dermatology, by means of a laser Aluminum-Gallium-Indium-Phosphorus (AlGaInP), with a wavelength of 660nm (Po - 30Wpeak) brand *Ibramed Indústria Brasileira de Equipamentos Médicos*[®] with continuous light emission and pulsed once a day, three times a week for five consecutive weeks, with a total of 15 applications. At the edges of the lesion, it was applied in a timely manner with 4 J/cm² and a distance between the points of 1cm². In the center of the PU application form was scanned for both pen laser was at a distance of 1 cm of tissue⁽²¹⁾ over a period of three to four minutes. The laser used emits visible red light, which required the use of personal protective goggles for the eyes of the professionals in the application of therapy. The patient did not need to use protective goggles, since the laser application was on his back.

In addition to receiving adjuvant therapy (LLLT), the patient was treated with local dressing daily as PU protocol of the institution⁽²²⁾, which included use of 0.9% saline heated solution to hygiene lesion and specific coverage as the evolution of lesion, such as hydrogel, medium chain triglycerides, zinc oxide and silver alginate.

Data was analysed by descriptive statistics, considering PUSH and NOC scores in order to allow the identification of factors that could corroborate or contradict the improvement of the healing process of the PU.

The study was approved by the Research Ethics Committee of the Health Institution, under Protocol 14032.

RESULTS

This case report study used NANDA-I, NIC and NOC classifications^(6,12,15) to describe the elements of nursing practice in the clinical setting of patient care with PU undergoing adjuvant intervention of LLLT. Thus, initially, the history and physical examination is presented, followed by Nursing diagnosis (ND), initial evaluation of PU with the NOC⁽¹²⁾ and PUSH⁽¹¹⁾ before the intervention (composed by dressing adjuvant LLLT) and the results obtained after implementation of interventions during the study.

HISTORY AND PHYSICAL EXAMINATION

F.M., male, 57 years old, white, retired, 98,2kg, 1,74cm, BMI 32.5 kg/m², with history of hypertension, compensated diabetes mellitus, secondary paraplegia due to spinal cord injury after a car accident in 1988, recurrent erysipelas in the lower limbs, active alcoholism, former smoker, and PU in the sacral and gluteal region for about a year.

Patient was admitted to the emergency of the hospital in late March 2014 due to intermittent contractions of the masseter and upper limbs, associated with significant respiratory effort. He was transferred to the ICU with acute respiratory failure and suspected of serious tetanus, with likely source of infection in PU once family reported that the wheelchair used for personal hygiene was rusted. Tetanus was treated with immunoglobulin and tetanus vaccine, and instituted all external

stimuli protective measures to patient with tetanus. The PU was classified as stage III, affected in the sacral region, right and left gluteal region, with tunneling and devitalized tissue, macerated edges, pus secretion in big quantities, extremely foul odor and fungal dermatitis in the underlying skin requiring surgical debridement of the lesion, and daily dressings.

In August 2014, the patient remained in the ICU, but with clinical stabilized chart in relation to complications from tetanus. However, the PU remained with slow healing, which motivated this study, with planning to use of LLLT as adjuvant. At that time, F.M. had no major pain complaints and communicated well despite the tracheostomy and intermittent mechanical ventilation with Ayre at 5L/min. His weight was 82.5Kg, 1.74cm height and BMI 27.08 kg/m². The PU had 7 cm length, 6 cm width with tunnel of 3 cm in length and area of 42cm², had granulation tissue, defined borders, presence of serosanguineous secretion in moderate quantity and slightly foul odor. The patient evacuated and urinated in diapers, keeping the wound with excessive moisture and possible contamination. Score 12 in applying the Braden Scale⁽⁷⁾, that is, high risk. Family members were present in daily visits.

NURSING DIAGNOSIS

Clinical judgment of the information collected pointed many ND that were listed for the patient, one of them were Impaired Tissue Integrity related to impaired physical mobility and mechanical factors (pressure, abrasion, friction); since, so far, is what best defines the state of PU⁽⁶⁾. Based on this ND the goals were defined to be achieved, using the NOC⁽¹²⁾.

ESTABLISHMENT OF GOALS - NOC

We evaluated the Impaired tissue integrity, through the result of NOC Wound Healing: secondary intention with 12 indicators⁽¹²⁾, allowing us to describe the state of PU reliably and set the goals to be achieved after the proposed interventions. The lower scores indicate worse results and the state of the lesion before the intervention. The higher scores indicate the goals to be achieved after the intervention (Table 1).

Table 1 – Initial assessment of PU and goals to be achieved through the outcome Wound Healing: secondary intention outcome from NOC – Porto Alegre, RS, Brazil, 2014.

Indicators	Initial assessment before the intervention	Goals to be achieved after the intervention
Granulation*	4	5
Scar formation*	1	5
Decreased wound size*	1	5
Purulent drainage †	5	5
Serous drainage†	5	5
Sanguineous drainage†	5	5
Serosanguineous drainage†	3	5
Surrounding skin erythemat	2	5
Paeriwound edemat	3	5
Blistered skint	5	5
Macerated skint	3	5
Foul wound odort	4	5

*1=None; 2=Limited; 3=Moderate; 4=Substantial; 5=Extensive.

†1=Extensive; 2=Substantial; 3=Moderate; 4=Limited; 5=None.

In parallel with the evaluation performed with the result of the NOC(12), we used the PUSH scale(11) which checks the wound area, the wound tissue type and exudate amount (Table 2).

Table 2 – Initial assessment of the PU using PUSH scale – Porto Alegre, RS, Brazil, 2014.

PUSH	Initial assessment before intervention
Length x width*	10
Exudate amount†	2
Tissue type§	2

* 0=0cm²; 1=<0.3cm²; 2=0.3 – 0,6 cm²; 3=0.7 – 1.0cm²; 4=1.1cm² – 2.0cm²; 5=2.1 – 3.0cm²; 6=3.1 – 4.0cm²;7=4.1 – 8.0cm²; 8=8,1 – 12,0cm²; 9=12,1 – 24cm²; 10=>24cm².

† 0=None; 1=Light; 2=Moderate; 3= Heavy.

§ 0= Closed/Resurfaced; 1=Epithelial tissue; 2=Granulation tissue; 3= Slough; 4=Necrotic tissue.

NURSING INTERVENTIONS – NIC

To achieve the established goals, we planned and implemented the interventions based on the NIC: Pressure Ulcer Care and of Laser Precautions(15). Thus, the lesion was treated with a daily dressing and adjuvant therapy with LLLT in order to promote accelerated wound healing and reduce the risk of clinical complications.

EVALUATION OF HEALING RESULTS PU (NOC AND PUSH)

The evaluation of the results after the intervention was carried out reusing the result of NOC, called Wound Healing: secondary intention with 12 selected indicators(12), and the PUSH scale(11). This evaluation took place three times a week, over five weeks (as described in the method section), always before the patient would receive LLLT and dressing interventions. The evolution of the lesion was also photographed over this period (Figure 1).

After the sixth day of LLLT use, there was a reduction in the size of the lesion, which had, at the time, 4cm of length, width of 2.8cm and with an area of 11.2cm². There was also increased granulation and epithelial tissue (but with the presence of devitalized tissue in a part of the lesion), decreased serosanguineous secretion but still present in moderate amounts, no foul odor, increased maceration and perilesional erythema. This clinical chart demanded stronger orientation to the nursing staff and family members about the need to control moisture in diapers, opting for the use of urine collector. Patient decubitus changes were intensified, though with some difficulty to mobilize when sitting on the chair.

On the ninth day of evaluation, the patient was anxious due to his transference from the ICU to a clinic inpatient unit of the hospital. However, the lesion continued showing progress in the healing process. On that day, he presented a PU with 4cm length and 1.8cm width,

with an area of 7,2cm², covered by granulation tissue, defined borders, serosanguineous secretion drainage in moderate amount, without the presence of foul odor, perilesional region with reduction of the erythema and maceration. The patient continued to use an urine collector and the nurse of the unit was instructed to request an airflow mattress.

On the 12th day of PU evaluation, he presented a further reduction in size, with 1.5cm length and 1.5cm width, with 3cm² area. The borders of the lesion were viable and delimited with epithelialization tissue, and in the center of the lesion with granulation tissue. The lesion had a small amount of exudate serosanguineous without foul odor, skin adjacent to the lesion without erythema and without maceration. Diuresis in diapers because the “uripen” was injuring the penis and was removed.

On the 15th day of evaluation and final LLLT use, the PU had 1.5cm length and 1.1cm width, with 1,65cm² area. We highlight the reduction of 7cm length injury to 1.5cm and 6cm to 1.1cm width, comparing the first and the 15th day of assessment. Epithelial tissue remained in the ascendancy, with significant reduction of the amount of serosanguineous secretion without foul odor. Nevertheless, erythema and perilesional maceration had mild worsening, probably due to the diuresis in diapers, which increased perineal moisture. To reduce this problem the team and the family members were told about the need to increase the frequency of diaper changes.

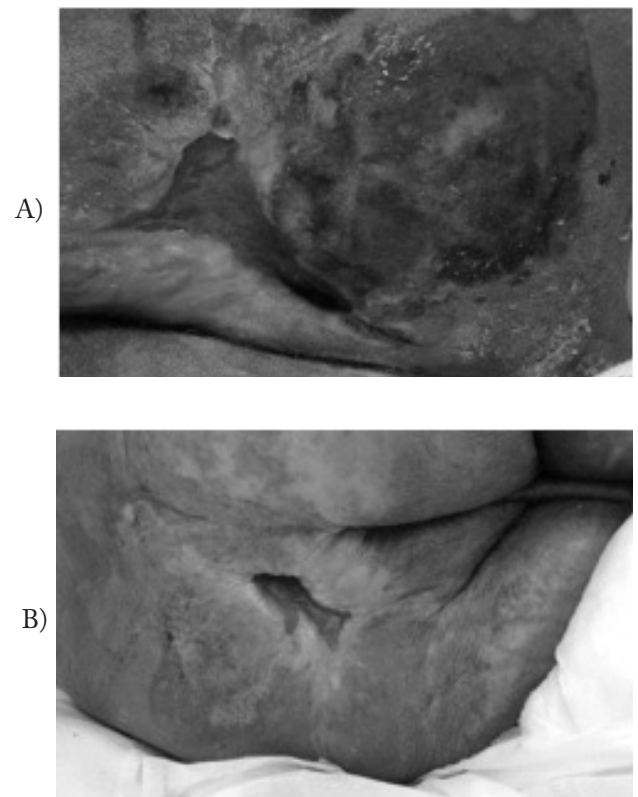


Figure 1 – Initial assessment of the PU (a) and evaluation on day 15 of follow-up (b) – Porto Alegre, Brazil, 2014.

Table 3 summarizes the indicating scores of the NOC results⁽¹²⁾ in five distinct moments of the evaluation of PU treated with LLLT added to dressing.

The evolution of the scores on the PUSH scale⁽¹¹⁾ were also analyzed in five distinct moments of the healing process of PU and are summarized in Table 4.

Table 3 – PU evaluation by the Wound Healing: Secondary Intention with 12 indicators from NOC. Porto Alegre, RS, Brazil, 2014.

Indicators	Day 1 1 st week	Day 6 2 nd week	Day 9 3 rd week	Day 12 4 th week	Day 15 5 th week
Granulation*	4	5	5	5	5
Scar formation*	1	3	3	4	4
Decreased wound size*	1	4	5	5	5
Purulent drainage †	5	5	5	5	5
Serous drainage †	5	5	5	5	5
Sanguineous drainage †	5	5	5	5	5
Serosanguineous drainage†	3	3	3	4	4
Surrounding skin erythema †	2	3	4	5	4
Periwound edemat	3	4	4	5	5
Blistered skint	5	5	5	5	5
Macerated skin †	3	2	3	4	4
Foul wound odor wound	4	5	5	5	5

*1=None; 2=Limited; 3=Moderate; 4=Substantial; 5=Extensive.

†1=Extensive; 2=Substantial; 3=Moderate; 4=Limited; 5=None.

Table 4 – PU evaluation using the Pressure Ulcer Scale for Healing – PUSH – Porto Alegre, RS, Brazil, 2014.

PUSH	Day 1 1 st week	Day 6 2 nd week	Day 9 3 rd week	Day 12 4 th week	Day 15 5 th week
Length x width*	10	8	7	5	4
Exudate amount†	2	2	2	1	1
Tissue type§	2	2	2	1	1

* 0=0cm2; 1=<0.3cm2; 2=0.3 – 0,6 cm2; 3=0.7 – 1.0cm2; 4=1.1cm2 – 2.0cm2; 5=2.1 – 3.0cm2; 6=3.1 – 4.0cm2;7=4.1 – 8.0cm2; 8=8,1 – 12,0cm2; 9=12,1 – 24cm2; 10=>24cm2.

† 0=None; 1=Light; 2=Moderate; 3= Heavy.

§0= Closed/Resurfaced; 1=Epithelial tissue; 2=Granulation tissue; 3= Slough; 4=Necrotic tissue.

DISCUSSION

This study showed a significant decrease in the size of the PU, as its size decreased from 7cm to 1.5cm length and 6cm to 1.1cm width in a five-week period. Additionally, there was an increase in tissue granulation and epithelialization, decreased secretion serosanguineous and odor from the wound. The maceration and erythema around the wound also showed progressive improvement after the third day of LLLT use. This improvement can be explained by the fact that LLLT leads to release of histamine, serotonin and bradykinin, resulting in stimulation of ATP production and micro-circulation, an increase of epidermal regeneration rates,

analgesic, anti-inflammatory, antiedema and wound healing actions⁽²¹⁾.

The scar evolution of PU observed is configured as an inspiration and motivation for the use of LLLT in treating patients with this type of multifactorial lesion etiology, such as metabolic disorders, extremes of age, nutritional dysfunction, urinary or fecal incontinence, hydration, mobility conditions and sensory perception⁽¹⁾. Critically ill patients are exposed to many of these factors related to the uniqueness of their health condition because they require mechanical ventilation, use of vasoactive drugs, sedation, altered level of consciousness, movement restriction for a long time and hemodynamic instability,

which constitute important elements for the development of PU⁽²³⁻²⁴⁾. Thus, it is essential that preventive care is introduced earlier⁽²³⁻²⁴⁾, although in some cases prevention was not able to ensure the development of the lesion, which requires effective treatment when it appears.

In the case of this patient, considering his history of paraplegia, he also presented restriction for the changes of position in bed for a long period due to tetanus complications. This restricted the possibilities for prevention and treatment of PU, which performed slow healing process, despite the daily dressings, being observed an acceleration of the healing process after adjuvant use of LLLT.

The evaluation of the healing process of the PU were shown using the Wound Healing: Secondary Intention with 12 indicators from NOC⁽¹²⁾, which were defined operationally, considering the magnitude of the five points Likert scale. Thus, it obtained more detailed and reliable measurement results after the LLLT intervention compared with the PUSH scale use⁽¹¹⁾.

It was found that in the PUSH scale⁽¹¹⁾, the item *tissue type* score equates to a different tissue, there is no possibility of scoring the presence of two distinct tissues and even the progress of each. In the NOC⁽¹²⁾, each indicator consists of a different tissue, thus, it is possible to mark more than one tissue type and rate the progress in each lesion.

In the item *Quantity of exudate*, the PUSH⁽¹¹⁾ defines the scale scores to none, light, moderate and heavy, this is a subjective evaluation, since it does not point parameters to define what each of them are. Similarly, the PUSH⁽¹¹⁾ does not identify the different types of secretion. When using the NOC indicators⁽¹²⁾, these questions could be specified, because addressed the professional operational definitions to assess objectively each of these elements in a standardized manner⁽²⁵⁻²⁶⁾. That is, it was possible to quantify the exudate and characterize its aspect along with the PU healing process.

We highlight that this study was the first to use NOC⁽¹²⁾ associated with PUSH⁽¹¹⁾ and that despite these classification

systems help the adoption of standardized terms and confer visibility to the work of nurses, it had not been explored in this way yet, which gives importance to our findings. The results showed that the NOC⁽¹²⁾ can be used safely in patients' assessments for PU treatment, as their indicators favoured the evaluation and description of the healing process of the lesion treated with LLLT use, which proved promising and effective as an adjuvant therapy.

CONCLUSION

We conclude that there was significant improvement in the healing process of the PU treated with adjuvant LLLT, which was shown by the Healing Wounds: secondary intention according to NOC, and PUSH scale, in addition to evidence of photographic record. The scores related to NOC indicators called Scar formation, Decreased wound size, Serosanguineous drainage, Surrounding skin erythema and Peri wound edema, Macerated skin and Foul wound odor after LLLT use, pointed to a lesion improvement. On the other hand, the PUSH scores decreased, indicating a reduction in size and wound exudate, and increased tissue epithelialization.

Thus we speculate the possibility of using LLLT on PU treatment protocols, because this intervention accelerated tissue proliferation and increased local vascularization, with granulation tissue formation by promoting rapid healing of the lesion. The case report study proved an important method to support the design of future clinical studies with a larger and randomized sample capable of producing greater levels of evidence of the benefits of this therapy, as this research has the limitation of using a single patient.

We also conclude that the use of the NOC classification allowed a more detailed evaluation of the evolution of the healing process of the lesion than the PUSH, due to the increased number of available indicators, proving it a good alternative to assess the effectiveness of nursing interventions.

RESUMO

Objetivo: Descrever o processo de cicatrização de úlcera por pressão em paciente crítico tratado com terapêutica convencional de curativo acrescida de laserterapia de baixa intensidade avaliada pela Pressure Ulcer Scale for Healing (PUSH) e pelo resultado Cicatrização de Feridas: segunda intenção, da Nursing Outcomes Classification (NOC). **Método:** Estudo de caso norteado pelo processo de enfermagem realizado com paciente de unidade de terapia intensiva. Os dados foram coletados com instrumento contendo a PUSH e o resultado da NOC. Na análise utilizou-se a estatística descritiva, considerando-se as pontuações obtidas no instrumento. **Resultados:** Observou-se redução nas dimensões da lesão de 7cm para 1,5cm de comprimento e de 6cm para 1,1cm de largura, além do aumento do tecido epitelial e de granulação, diminuição da secreção e odor. **Conclusão:** Houve melhora no processo de cicatrização da lesão tratada com terapia adjuvante e o uso da NOC permitiu uma avaliação mais detalhada e precisa do que da PUSH.

DESCRIPTORIOS

Úlcera por Pressão; Terapia a Laser; Cicatrização; Resultado do Tratamento; Processos de Enfermagem; Unidades de Terapia Intensiva.

RESUMEN

Objetivo: Describir el proceso de cicatrización de úlcera por presión en paciente crítico tratado con terapêutica convencional de curativo agregada a la laserterapia de baja intensidad evaluada por la Pressure Ulcer Scale for Healing (PUSH) y el resultado Cicatrización de Heridas por segunda intención, de la Nursing Outcomes Classification (NOC). **Método:** Estudio de caso orientado por el proceso de enfermería llevado a cabo con paciente de unidad de terapia intensiva. Los datos fueron recogidos con instrumento conteniendo la PUSH y el resultado de la NOC. En el análisis se utilizó la estadística descriptiva, considerándose las puntuaciones obtenidas en el instrumento. **Resultados:** Se observó reducción en las dimensiones de la lesión de 7cm a 1,5cm de largo y de 6cm a 1,1cm de ancho, además del aumento del tejido epitelial y de granulación, y la reducción de la secreción y el dolor. **Conclusión:** Hubo mejora en el proceso de cicatrización de la lesión tratada con terapia adyuvante, y el uso de la NOC permitió una evaluación más detallada y precisa que la PUSH.

DESCRIPTORES

Úlcera por Presión; Terapia por Láser; Cicatrización de Heridas; Resultado del Tratamiento; Procesos de Enfermería; Unidades de Cuidados Intensivos.

REFERENCES

1. National Pressure Ulcer Advisory Panel (NPUAP); European Pressure Ulcer Advisory Panel (EPUAP); Pan Pacific Pressure Injury Alliance (PPPIA). Prevention and treatment of pressure ulcers: quick reference guide. Perth, Australia: Cambridge Media; 2014.
2. Rogenski NM, Kurcrag P. The incidence of pressure ulcers after the implementation of a prevention protocol. *Rev Latino Am Enfermagem*. 2012;20(2):333-9.
3. Hyun S, Li X, Vermillion B, Newton C, Fall M, Kaewprag P, et al. Body mass index and pressure ulcers: improved predictability of pressure ulcers in intensive care patients. *Am J Crit Care*. 2014;23(6):494-500.
4. Manzano F, Navarro MJ, Roldán D, Moral MA, Leyva I, Guerrero C, et al. Pressure ulcer incidence and risk factors in ventilated intensive care patients. *J Crit Care*. 2010;25(3):469-76.
5. Alves P, Mota F, Ramos P, Vales L. Epidemiology of pressure ulcers: interpreting data epidemiological as an indicator of quality. *Servir*. 2013;58(1-2):10-8.
6. NANDA International. Nursing diagnoses: definitions & classification, 2015-2017. Oxford: Wiley Blackwell; 2014.
7. Costa IG, Caliri MHL. Predictive validity of the Braden Scale for patients in intensive care. *Acta Paul Enferm*. 2011;24(6):772-7.
8. Olyai M, Rad FS, Elahifar MA, Garkaz A, Mahsa G. High-frequency and noncontact low-frequency ultrasound therapy for venous leg ulcer treatment: a randomized, controlled study. *Ostomy Wound Manage*. 2013;59(8):14-20.
9. Zhang J, Guan M, Xie C, Luo X, Zhang Q, Xue Y. Increased growth factors play a role in wound healing promoted by noninvasive oxygen-ozone therapy in diabetic patients with foot ulcers. *Oxid Med Cell Longev*. 2014;2014:273475.
10. Dissemmond J. Physical treatment modalities for chronic leg ulcers. *Hautarzt*. 2010;61(5):387-96.
11. Santos VL, Azevedo MA, Silva TS, Carvalho VM, Carvalho VF. Crosscultural adaptation of the pressure ulcer scale for healing to the portuguese language. *Rev Latino Am Enfermagem*. 2005;13(3):305-13.
12. Moorhead S, Johnson M, Maas ML, Swanson E. Nursing Outcomes Classification (NOC): measurement of health outcomes. 5th ed. Philadelphia: Elsevier; 2013.
13. Lucena AF, Santos CT, Pereira AGS, Almeida MA, Dias VLM, Friedrich MA. Clinical profile and nursing diagnosis of patients at risk of pressure ulcers. *Rev Latino Am Enfermagem*. 2011;19(3):523-30.
14. Azzolin K, Mussi CM, Ruschel KB, Souza EN, Lucena AF, Rabelo-Silva ER. Effectiveness of nursing interventions in heart failure patients in home care using NANDA-I, NIC, and NOC. *Appl Nurs Res*. 2013;26(4):239-44.
15. Bulechek GM, Butcher HK, Dochterman JM, Wagner C. Nursing Interventions Classification (NIC). 6th ed. Philadelphia: Elsevier; 2013.
16. Hopkins JT, McLoda TA, Seegmiller JG, David Baxter G. Low-level laser therapy facilitates superficial wound healing in humans: a triple-blind, shamcontrolled study. *J Athl Train*. 2004;39(3):223-9.
17. Pinto NC, Pereira HC, Stolf NAG, Chavantes MC. Low level laser therapy in acute dehiscence saphenectomy: therapeutic proposal. *Rev Bras Cir Cardiovasc*. 2009;24(1):88-91.
18. Andrade FSSD, Clark RMO, Ferreira ML. Effects of low-level laser therapy on wound healing. *Rev Col Bras Cir*. 2014;41(2):129-33.
19. Araújo TM, Araújo MF, Caetano JA. Using the braden scale and photographs to assess pressure ulcer risk. *Rev Esc Enferm USP*. 2012;46(4):858-64.
20. Yin RK. Case study research: design and methods. 4th ed. Los Angeles: Sage; 2009.
21. Franek A, Krol P, Kucharzewski M. Does low output laser stimulation enhance the healing of crural ulceration? Some critical remarks. *Med Eng Phys*. 2002;24(9):607-15.
22. Menegon DB, Bercini RR, Brambila MI, Scola ML, Jansen MM, Tanaka RY. Implantação do protocolo assistencial de prevenção e tratamento de úlcera de pressão do Hospital de Clínicas de Porto Alegre. *Rev Hosp Clin Porto Alegre*. 2007;27(2):61-4.
23. Simao CMF, Caliri MHL, Santos CB. Agreement between nurses regarding patients' risk for developing pressure ulcer. *Acta Paul Enferm*. 2013;26(1):30-5.
24. Tayyib N, Coyer F, Lewis PA. A two- arm cluster randomized control trial to determine the effectiveness of a pressure ulcer prevention bundle for critically ill patients. *J Nurs Scholarsh*. 2015;47(3):237-47.
25. Chianca TC, Salgado PO, Albuquerque JP, Campos CC, Tannure MC, Ercole FF. Mapping nursing goals of an Intensive Care Unit to the Nursing Outcomes Classification. *Rev Latino Am Enfermagem*. 2012;20(5):854-62.
26. Almeida MA, Seganfredo DH, Barreto LNM, Lucena AF. Validation of indicators of the nursing outcomes classification for hospitalized adults at risk of infection. *Texto Contexto Enferm*. 2014;23(2):309-17.