

SONOGRAPHIC FEATURES OF PORTAL HYPERTENSION IN SCHISTOSOMIASIS MANSONI

Rogério Augusto PINTO-SILVA (1), Wilson Luiz ABRANTES (2), Carlos Maurício Figueiredo ANTUNES (1) & Jose Roberto LAMBERTUCCI (1)

SUMMARY

The diagnostic value of real-time sonography in the study of portal hypertension was assessed in 66 patients with hepatosplenic schistosomiasis mansoni, all with Symmers's fibrosis and esophageal varices. Seventy-one individuals without schistosomiasis were selected as controls. The inner diameters of the portal vessels were measured by sonography in all patients and controls: splenoportography was also performed in the schistosomal group. Intra-splenic pressure was over 30 cm of water in 44 of 60 patients with schistosomiasis. The upper limit of normality for portal vessel diameters was set through receiver operating characteristic curve at 12 mm for portal vein, 9 mm for splenic vein at splenic hilus, and 9 mm for superior mesenteric vein. The best discriminative vein for the diagnosis of portal hypertension was the splenic vein followed by the portal vein. A direct correlation was observed between the diameter of the splenic vein, measured by sonography, and the intra-splenic pressure. Except for the paraumbilical and mesenteric veins, more frequently identified by sonography, there was no statistical difference in the frequency of visualization of splanchnic vessels by sonography or splenoportography.

KEYWORDS: Schistosomiasis; Sonography; Splenoportography; Portal Hypertension.

INTRODUCTION

Schistosomiasis mansoni is a major health problem in Brazil. The disease may have an acute and a chronic phase. The latter may present three progressively more severe forms: intestinal, hepatointestinal and hepatosplenic. It is estimated that 10% of infected patients develop the hepatosplenic form. The characteristic hepatic lesion, caused by *S. mansoni*, is a periportal fibrosis with relatively normal hepatic parenchyma. Hemorrhage from esophageal varices is a common cause of mortality among those with hepatosplenic schistosomiasis²⁰.

Demonstration of the existence and extent of portosystemic venous collaterals in patients with schistosomiasis is important, as it helps the surgical team to plan the best therapeutic approach to patients with hepatosplenic schistosomiasis, portal hypertension and upper gastrointestinal bleeding²². Invasive procedures such as angiography are considered the most accurate means of demonstrating such collaterals^{6,15}. Recently, however, with the development of noninvasive imaging techniques, it became possible to document their existence by sonography^{14,15,19}.

(1) Faculdade de Medicina da UFMG, Belo Horizonte, MG, Brasil

2) Hospital Felício Rocho

Endereço para Correspondência: Dr. José Roberto Lambertucci, Faculdade de Medicina da UFMG. Av. Alfredo Balena, 190. 30130-100 - Belo Horizonte, MG, Brasil

Splenoportography is widely used in Brazil, because it is easy to perform, permits measurement of splenic pulp pressure (an indirect measure of portal venous pressure), assessment of portal vein and collaterals and visualization of portal branches within the liver⁹. It has been more frequently used as an operative procedure, and it has proved to be a valuable tool with few complications².

There has been no comparative study of sonography and angiography on patients with hepatosplenic schistosomiasis^{1,10,11,23}.

In this study, the sonographic features of portal hypertension in schistosomiasis mansoni are studied. A control group, made up of individuals with no evidence of liver or systemic diseases, is also examined by sonography; normal and abnormal values for the caliber of portal vessels are defined. The value of sonography and splenoportography in the diagnosis of the portal hypertension of schistosomiasis is compared, and a correlation between intra-splenic pressure and the caliber of portal vessels, measured by sonography, is also described.

PATIENTS AND METHODS

Patients

From June 1986 to October 1991, 66 patients (51 male and 15 female; age range: 15-45 years; mean age: 32 years) with hepatosplenic schistosomiasis and portal hypertension, whose Symmers's fibrosis have been confirmed by surgical liver biopsy, underwent abdominal sonography as part of preoperative routine. All patients had esophageal varices confirmed by endoscopy and 58 reported some form of previous digestive bleeding. Thirty six patients excreting eggs of *S. mansoni* in feces were treated for schistosomiasis with oxamniquine¹⁶. Informed consent was obtained for this study. Sera from patients with schistosomiasis tested negative for hepatitis B.

All patients with schistosomiasis were operated on: 44 had a distal splenorenal anastomosis constructed and 22 were submitted to esophagogastric devascularization plus splenectomy². A hepatic wedge biopsy was taken from the

left lobe of the liver; the biopsy specimens were read by a pathologist and the diagnosis of Symmers' fibrosis established. All patients survived the surgery and were discharged from the hospital.

Seventy one patients (28 male and 43 female; age range 13-65 years; mean age: 36 years) without schistosomiasis (at least one negative parasitological stool examination for *S. mansoni* ova; they also denied previous contact with stream water in schistosomiasis endemic areas) and presenting no evidence of liver disease or other systemic diseases were selected as controls. This group was recruited among individuals referred to the ultrasound clinic during the five-year period of the present study.

Ultrasonography

All ultrasound examinations were performed in overnight fasting patients, who previously received laxatives, using real-time equipments with electronic linear (Sonoline 2300, Siemens, Germany), linear/convex (Shimasonic SDL-300, Shimadzu, Japan) and linear mechanical sector (SAL-55, Toshiba, Japan) 3.5 MHz transducers.

During ultrasonography, the inner diameter of the portal vessels were measured: 1) the portal vein at the hepatic hilus; 2) the splenic vein back to the pancreatic body and near the splenic hilus; 3) the superior mesenteric vein two centimeters far from the splenomesenteric junction and, 4) portal collaterals were searched, specially left, right and short gastric veins, splenorenal and paraumbilical veins. The diameters of splenic or mesenteric veins were also measured during maximal inspiration and at the end of subsequent expiration, and the variation calculated as percentage⁵.

Angiography

Splenoportography was performed in all patients with hepatosplenic schistosomiasis just before starting surgery with the technique described by others^{2,6,12,18}. Splenic pulp pressure was measured in 60 patients and was over 30 cm of water in 44. The value of sonography and splenoportography in the evaluation of portal hypertension was compared in 37 patients with

hepatosplenic schistosomiasis. For these 37 selected patients a standart procedure was designed: three films were obtained over a 30-second period, beginning just after the end of the injection of contrast medium into the spleen. The radiographic films were read by one of us (RAPS) without knowing the result of sonography.

In 4 patients, arterial portography was made after catheterization of mesenteric or celiac arteries; numerous films were taken and those that better revealed the portal vessels were selected. The diameters were also measured in the same anatomical places.

Data analysis

Although both groups (schistosomotic and controls) were comparable in height, weight and body area, patients with schistosomiasis tended to be of smaller complexion when compared to controls. So, both groups were stratified by sex, weight, height and body area using as cut-points measures near the mean values: 60kg, 160 cm and 1.6 m², respectively.

The calibers of the portal vessel were compared between groups and between strata in the same group. The variance of veins diameters was determined by Bartlett's test. If they were homogeneous, ANOVA test was performed. Otherwise, Kruskal-Wallis H test results were taken for comparison between case and control patients.

ROC (Receiver Operating Characteristic) curves were built for all vessels considering groups and strata and comparing its ability to diagnose portal hypertension based on the diameters of the vessels¹³.

The mean calibers of portal vessels for 3 strata of intra-splenic pressure were also compared: 1) an inferior one, from 15 to 30 cm of water (n=16), 2) an intermediate one, from 31 to 40 cm (n=31), and 3) a superior stratum, from 41 to 52 cm of water (n=13).

Comparisons between methods (sonography and angiography) were performed with Chi-square by Mantel-Haenzel test. Vein calibers

were compared by analysis of variance (ANOVA) and Kruskal-Wallis non-parametric test.

All statistical tests were performed using the EpiInfo v. 5 software.

RESULTS

The hepatic sonogram showed the characteristic features of schistosomal periportal fibrosis in all patients (Figure 1). They also presented massive enlargement of the spleen. Signs of old thrombosis were present in 3 cases (4.5%): one at the left branch of the portal vein in the liver and extending to a dilated paraumbilical vein, one at the splenomesenteric junction, and the last one in the left branch of the portal vein and in the splenomesenteric junction.

The calibers of splanchnic veins were significantly different ($p \leq 0.01$) between schistosomiasis and control patients (Figure 2).

There were no differences between the areas of different ROC curves of the anthropometric strata and the whole group for each vein. ROC curves (Figure 3) of the portal vessels showed that the upper limit of normality can be set at 12 mm for portal vein, 8 mm for splenic vein at pancreas level and 9 mm for mesenteric vein.

ROC curves also showed that the best discriminative vein for the diagnosis of portal hyper-

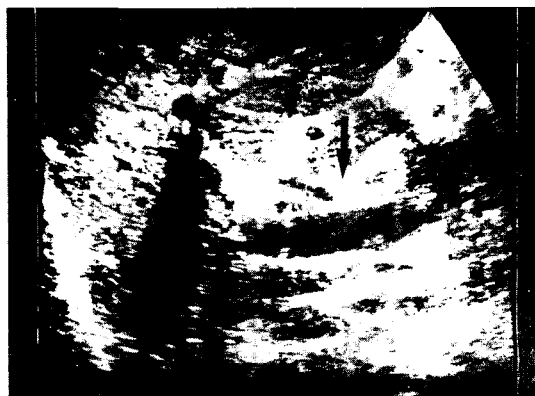


Fig. 1. Sonogram of the liver showing echogenic thickening (arrow) of the wall of the portal vein (PV) in hepatosplenic schistosomiasis.

tension in hepatosplenic schistosomiasis was the splenic vein followed by the portal vein (Figure 3).

No patient with schistosomiasis showed respiratory variation in the diameter of the portal vessels over 50%.

Eight different types of hepatofugal collaterals were found during sonographic examination; more frequently there were 2 to 3 collateral vessels. Left and short gastric veins and the paraumbilical vein were more frequently described than others (Figure 4). Splenoportography disclosed six different types of collaterals; most patients had one or two vessels. Except for the paraumbilical vein, more frequently identified by sonography (15 times against three times by splenoportography), there was also no statistical difference in the visualization of other vessels by both methods (Figure 5).

Comparisons between the diameters of the portal vessels with the 3 strata of intra-splenic pressure showed that an increase in the diameter of the splenic vein at pancreas level correlates well with an increase in portal pressure (Figure 6).

Arterial portograms were considered of good quality in all four patients. Splenoportograms were of low quality in two patients, and were considered regular or good in 35. Two patients had large spontaneous splenorenal collaterals that bypassed almost all blood flow from the portal vessels to vena cava, hindering portal visualization. One patient complained of itching in the vicinity of the punctured skin; in another one, hemoperitoneum was found during surgery.

The average diameter of the portal vein was 19.8 when measured by angiography and 14.5 by sonography and the values for the superior mesenteric vein were 23.0 and 12.8 for angiography and sonography, respectively. The average diameter of portal vessels was smaller when measured by sonography; statistical difference, however, was significant only for portal and mesenteric veins.

DISCUSSION

Patients with hepatosplenic schistosomiasis, portal hypertension, esophageal varices and prior

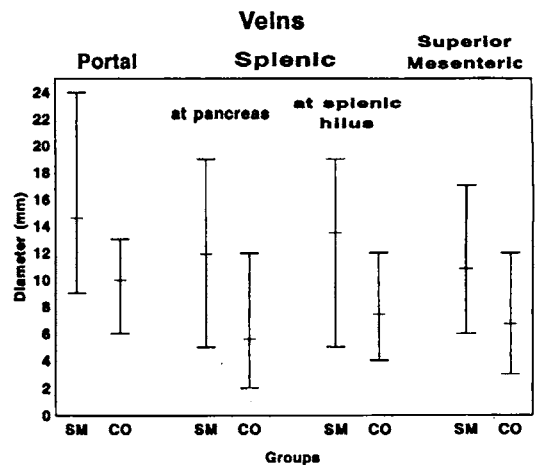


Fig. 2. Diameters of the veins of the portal system of schistosomal (SM) and control groups (CO). Maximum, minimum and mean values.

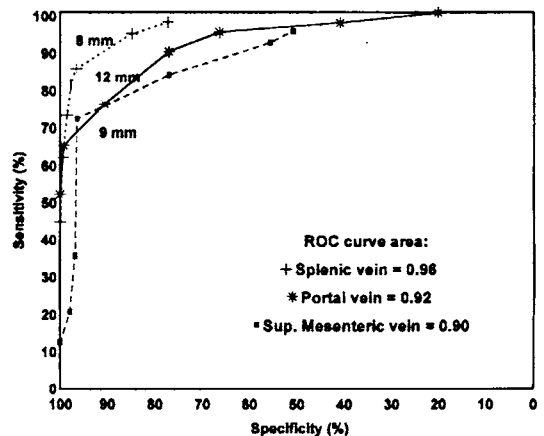


Fig. 3. Sensitivity and specificity of the diameters of splenic, portal, and mesenteric veins in the diagnosis of portal hypertension in schistosomiasis. The best cut-off points between normality and portal hypertension are also shown (splenic vein - 8 mm; portal vein - 12 mm; mesenteric vein - 9 mm).

digestive bleeding were selected for this study. Sonographic visualization of the portal vessels was obtained in most cases. The mean caliber of portal vessels in patients with schistosomiasis was significantly greater when compared with the mean

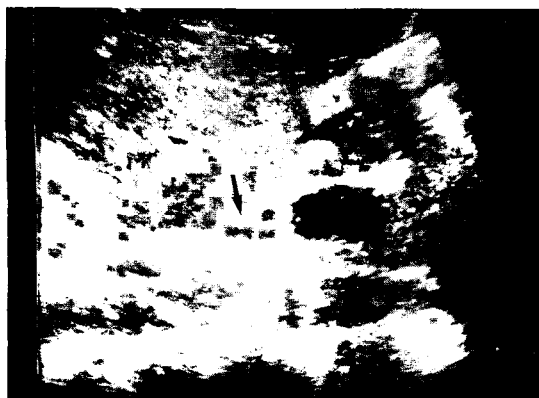


Fig. 4. Left gastric vein (arrow) joining splenic vein (SV) at midline in hepatosplenic schistosomiasis.

obtained for individuals in the normal control group. The increase in the diameter of the splenic vein in hepatosplenic schistosomiasis was impressive; its mean diameter in patients with portal hypertension was twice the caliber measured in the control group.

Stratification and determination of the different ROC curves for two strata of sex, weight, height and body area showed that they have no influence over the diameter of portal vessels.

The upper limit of normality for the diameter of portal vessels was set through ROC curve analysis at 12 mm for the portal vein, 8 mm for the splenic vein at the pancreatic body and 9 mm at the splenic hilus, and 9 mm for the superior mesenteric vein. Diameters over 14 mm for the portal vein and 12 mm for the splenic vein were 100% specific for the diagnosis of portal hypertension. ROC curve analysis has been used before only in patients with liver cirrhosis²⁶.

The upper limit of normality for the diameters of the portal vessels has not yet been firmly established. For the portal vein, for example, some authors have chosen 12 mm⁷, while others suggested 20 mm²⁴.

In our patients with schistosomiasis the area under the ROC curves indicated that the best discriminative vessel for the diagnosis of portal hypertension was the splenic vein (sensitivity of 85% and specificity of 96%) followed by the portal vein

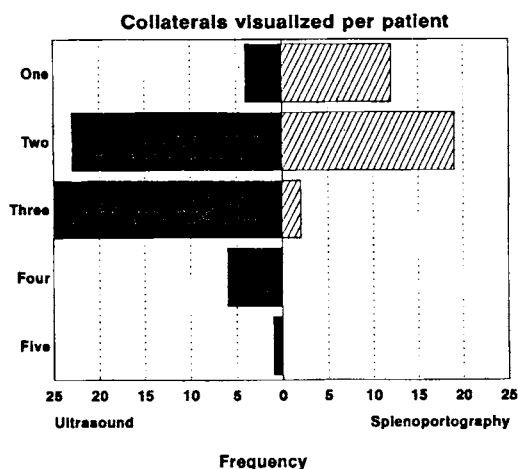


Fig. 5. Frequency of visualization of portal collateral veins per patient in the schistosomal group by splenopography and ultrasonography.

(sensitivity of 76% and specificity of 90%). It is worth noting that ZOLI et al²⁶, also using ROC curve analysis to study cirrhotic patients, found the superior mesenteric vein to be the best discriminative vessel to diagnose portal hypertension.

Intra-splenic pulp pressure is an accurate indication of portal venous pressure⁴. Using 3 strata of intra-splenic pressure, it was observed that the

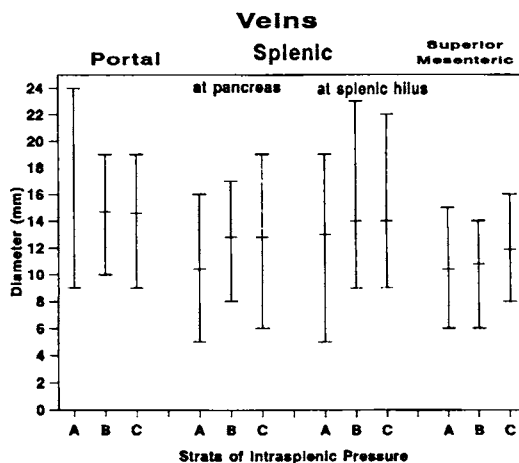


Fig. 6. Diameters of portal vessels in 3 strata of intrasplenic pressure (A - 15-30 cm of water; B - 31-40 cm of water; C - 41-52 cm of water).

splenic vein presented a trend to enlarge with increases in intra-splenic pressure.

ANDRADE & CHEEVER³ have suggested that the arterial blood flow to the spleen is increased in patients with hepatosplenic schistosomiasis (with massive splenomegaly) and that splenic arterio-venous shunts may contribute to portal hypertension in schistosomiasis. This "forward factor" may explain the predominant distension of the splenic vein in our patients and its absence in liver cirrhosis^{8,25}.

Some authors⁵ claim that a diminished response of portal vessels to respiration represent an early sign of portal hypertension. In the present study, no patient with hepatosplenic schistosomiasis showed respiratory variation in the diameter of portal vessels over 50%. ROC curve analysis indicated that under 20% variation there was 96% specificity for a sensitivity of 88%. This test offers no advantage over the measure of the diameter of the splenic and portal veins in the diagnosis of portal hypertension.

In the literature, comparisons of angiography and sonography, in patients with cirrhosis and portal hypertension, have favoured angiography. Percutaneous transhepatic portography was the technique chosen by most investigators. Our data for schistosomiasis mansoni show a slight superiority of sonography over splenoportography in the evaluation of portosystemic collaterals.

Improvement of ultrasound equipment and the accumulation of knowledge about the sonographic features of portal collaterals may explain our good results. Moreover, splenomegaly of moderate to large size and left liver lobe hypertrophy, observed in hepatosplenic schistosomiasis, might have improved the visualization of collaterals.

Sonography of the portal system, however, present some limitations: 1) valuable anatomic information can be provided but the blood flow direction information needed for preoperative evaluation is lacking in the equipment used in this study. The introduction of pulsed Doppler instrumentation may eventually resolve this; 2) overlying bowel gas (frequently observed in schistosomotic patients), obesity (rare in schis-

tosomiasis) and massive ascites may hinder the study.

It may be appropriate to use sonography as the first-choice procedure in the evaluation of hepatosplenic schistosomiasis, leaving angiography for those cases in need of supplementary information.

RESUMO

Aspectos ultra-sonográficos da hipertensão portal na Esquistossomose Mansonii

Sessenta e seis pacientes com esquistossomose mansoni hepatoesplênica foram examinados pela ultra-sonografia do abdomen. Trinta e sete também submetteram-se à esplenoportografia. Todos apresentavam fibrose de Symmers e varizes de esôfago. Selecionaram-se setenta e um indivíduos sem esquistossomose como controles. Mediu-se o diâmetro dos vasos porta nos pacientes e controles. A pressão intra-esplênica encontrava-se acima de 30 cm de água em 44 de 60 pacientes com esquistossomose. Os limites superiores da normalidade para os vasos do sistema porta foram definidos como 12 mm para a veia porta, 9 mm para a veia esplênica no hilo e 9 mm para a veia mesentérica superior. O aumento do diâmetro da veia esplênica mostrou-se a alteração mais sensível para o diagnóstico de hipertensão porta, seguido pelo aumento do diâmetro da veia porta. Observou-se correlação direta entre o diâmetro da veia esplênica e da pressão intra-esplênica. Não houve diferença significativa na frequência de visualização dos vasos esplâncnicos quando se usou a sonografia ou a esplenoportografia, exceto para as veias paraumbilical e mesentérica, mais frequentemente diagnosticadas pela ultra-sonografia.

REFERENCES

1. ABDEL-WAHAB, M.F. & STRICKLAND, G.T. - Abdominal ultrasonography for assessing morbidity from schistosomiasis. 2. Hospital studies. *Trans. roy. Soc. trop. Med. Hyg.*, 87:135-137, 1993.
2. ABRANTES, W.L. - Hipertensão portal. In: DANI, R. & CASTRO, L.P., ed. *Gastroenterologia Clínica*. 2.

- ed. Rio de Janeiro, Guanabara Koogan, 1988. p 983-1000.
3. ANDRADE, Z.A. & CHEEVER, A.W. - Alterations of the intrahepatic vasculature in hepatosplenic schistosomiasis mansoni. *Amer. J. trop. Med. Hyg.*, 20:425-432, 1971.
 4. ATKINSON, M. & SHERLOCK, S. - Intrasplenic pressure as index of portal venous pressure. *Lancet*, 1:1325-1327, 1954.
 5. BOLONDI, L.; GANDOLFI, L.; ARIENTI, V. et al. - Ultrasonography in the diagnosis of portal hypertension: diminished response of portal vessels to respiration. *Radiology*, 142:167-172, 1982.
 6. BURCHARTH, F.; NIELBO, N. & ANDERSEN, B. - Percutaneous transhepatic portography. II. Comparison with splenoportography in portal hypertension. *Amer. J. Roentgenol.*, 132:183-185, 1979.
 7. CERRI, G.G.; ALVES, V.A.F. & MAGALHÃES, A. - Hepatosplenic schistosomiasis mansoni: ultrasound manifestations. *Radiology*, 153:777-780, 1984.
 8. CHEEVER, A.W. & ANDRADE, Z.A. - Pathological lesions associated with *Schistosoma mansoni* infection in man. *Trans. roy. Soc. trop. Med. Hyg.*, 61:626, 1967.
 9. COUTINHO, A.D. - Hemodynamic studies of portal hypertension in schistosomiasis. *Amer. J. Med.*, 44:547-557, 1968.
 10. DACH, J.L.; HILL, M.C.; PELAEZ, J.C.; LEPAGE, J.R. & RUSSELL, E. - Sonography of hypertensive portal venous system: correlation with arterial portography. *Amer. J. Roentgenol.*, 137:511-517, 1981.
 11. DOKMECI, A.K.; KIMURA, K.; MATSUTANI, S. et al. - Collateral veins in portal hypertension: demonstration by sonography. *Amer. J. Roentgenol.*, 137:1173-1177, 1981.
 12. FOSTER, J.H.; CONKLE, D.M.; CRANE, J.M. & BURKO, H. - Splenoportography. An assessment of its value and risk. *Ann. Surg.*, 5:773-781, 1974.
 13. HANLEY, J.A. & MCNEILL, B.J. - The meaning and use of the area under a Receiver Operating Characteristic (ROC) curve. *Radiology*, 143:29-36, 1982.
 14. HATZ, C; JENKINS, J.M. & TENNER, M., ed. - Ultrasound in schistosomiasis. *Acta trop. (Basel)*, 51:1-97, 1992.
 15. HILL, M.C.; DACH, J.L. & SHAWKER, T.H. - Ultrasonography in portal hypertension. *Clin. Gastroent.*, 14:83-104, 1985.
 16. LAMBERTUCCI, J.R.; GRECO, D.B.; PEDROSO, E.R.P. et al. - A double blind trial with oxamniquine in chronic schistosomiasis mansoni. *Trans. roy. Soc. trop. Med. Hyg.*, 76:751-755, 1982.
 17. NIEDERAU, C.; SONNENBERG, A.; MULLER, J.E. et al. - Sonographic measurements of the normal liver, spleen, pancreas, and portal vein. *Radiology*, 149:537-540, 1983.
 18. PANKE, W.F.; BRADLEY, E.G.; MORENO, A.H.; RUZIKA, F.F. & RUSSELO, L.M. - Technique, hazards, and usefulness of percutaneous splenic portography. *J. Amer. med. Ass.*, 169:1032-1037, 1959.
 19. PINTO-SILVA, R.A. & LAMBERTUCCI, J.R. - The value of ultrasonography in the diagnosis of hepatosplenic schistosomiasis. *An. Fac. Med. Univ. Fed. Minas Gerais*, 35:28-38, 1986.
 20. PRATA, A. - Infection with *S. mansoni*. In: JORDAN, P. & WEBBE, G., ed. *Schistosomiasis: epidemiology, treatment and control*. London, William Heinemann Medical Books, 1982. p. 105-227.
 21. PROIETTI, F.A. & ANTUNES, C.M.F. - Sensitivity, specificity and positive predictive value of selected clinical signs and symptoms associated with schistosomiasis mansoni. *Int. J. Epidem.*, 18:680-683, 1989.
 22. RAIA, S.; MIES, S. & MACEDO, A.L. - Portal hypertension in schistosomiasis. *Clin. Gastroent.*, 14:57-82, 1985.
 23. SUBRAMANYAM, B.R., BALTHAZAR, E.J., MADAMBA, M.R. et al. - Sonography of portosystemic venous collaterals in portal hypertension. *Radiology*, 146:161-166, 1983.
 24. WEILL, F.S. - Cirrhosis and portal hypertension. In: WEILL, F.S., ed. *Ultrasonography of digestive diseases*. St. Louis, C.V. Mosby, 1982. p. 537-548.
 25. ZOLI, M.; CORDIANI, M.R.; MARCHESINI, G. et al. - Ultrasonographic follow-up of liver cirrhosis. *J. clin. Ultrasound*, 18:91-96, 1990.
 26. ZOLI, M.; DONDI, C.; MARCHESINI, G. et al. - Splanchnic vein measurements in patients with liver cirrhosis: a case control study. *J. Ultrasound Med.*, 4:641-646, 1985.

Recebido para publicação em 26/11/1993
Aceito para publicação em 01/06/1994