


## A case of round pneumonia due to *Enterobacter hormaechei*: the need for a standardized diagnosis and treatment approach in adults

Raúl Alberto Jiménez-Castillo<sup>1</sup> , Leonardo René Aguilar-Rivera<sup>1</sup>, Edgar Francisco Carrizales-Sepúlveda<sup>2</sup>, Ricardo Andrés Gómez-Quiroz<sup>1</sup>, Anabella Rosalía Llantada-López<sup>1</sup>, Julio Edgardo González-Aguirre<sup>1</sup>, Homero Náñez-Terreros<sup>1</sup>, Erick Joel Rendón-Ramírez<sup>1</sup>

### ABSTRACT

Round pneumonia is an unusual radiological manifestation of a bacterial lung infection. We present the case of an elderly male patient who arrived at the emergency room with a productive cough and exertional dyspnea. His chest x-ray and CT showed a round opacity and air bronchograms in the right upper lobe. Taken together, the patient's symptoms and images strongly suggest a pulmonary infection. Empirical antibiotic therapy with ceftriaxone and clarithromycin was started. The sputum culture was positive for *Enterobacter hormaechei* and the bacterium was sensitive to levofloxacin; therefore, the antibiotic therapy was changed. Despite the treatment, the patient progressed to respiratory failure and septic shock, dying six days after admission. Although round pneumonia is uncommon, it is a potentially curable disease and clinicians should always consider it in their differential diagnosis.

**KEYWORDS:** Round pneumonia. Adults. Liver cirrhosis. *Enterobacter hormaechei*

### INTRODUCTION

Round pneumonia is an unusual radiological manifestation that varies from a small circular mass to a large undefined round opacity<sup>1</sup>. Only one percent of round pneumonia cases occur in adults<sup>2</sup>. Clinical presentations range from asymptomatic to a history of fever, productive cough and chills<sup>3,4</sup>. We report the case of an elderly adult admitted to the emergency room with exertional dyspnea.

### CASE REPORT

A 64-year-old male with a history of alcohol consumption and liver cirrhosis arrived at the emergency department with a two-day history of productive cough and exertional dyspnea. The initial examination revealed a temperature of 36 °C, blood pressure 100/60 mmHg, heart rate 78 bpm and respiratory rate 19 bpm with an oxygen saturation of 96% in ambient air. On admission, a round opacity was observed in the right upper lobe on his chest X-ray (**Figure 1**). Laboratory tests were within normal ranges. Antibiotic therapy for community-acquired pneumonia was started with intravenous ceftriaxone and oral clarithromycin. The sputum culture was positive for *E. hormaechei* and the bacterium was sensitive to levofloxacin. Therapy was modified accordingly. Matrix-Assisted Laser Desorption Ionization–Time of Flight Mass Spectrometry analysis was used for the initial bacterial

<sup>1</sup>Universidad Autónoma de Nuevo León, Facultad de Medicina y Hospital Universitario “Dr. José Eleuterio González”, Departamento de Medicina Interna, Monterrey, México

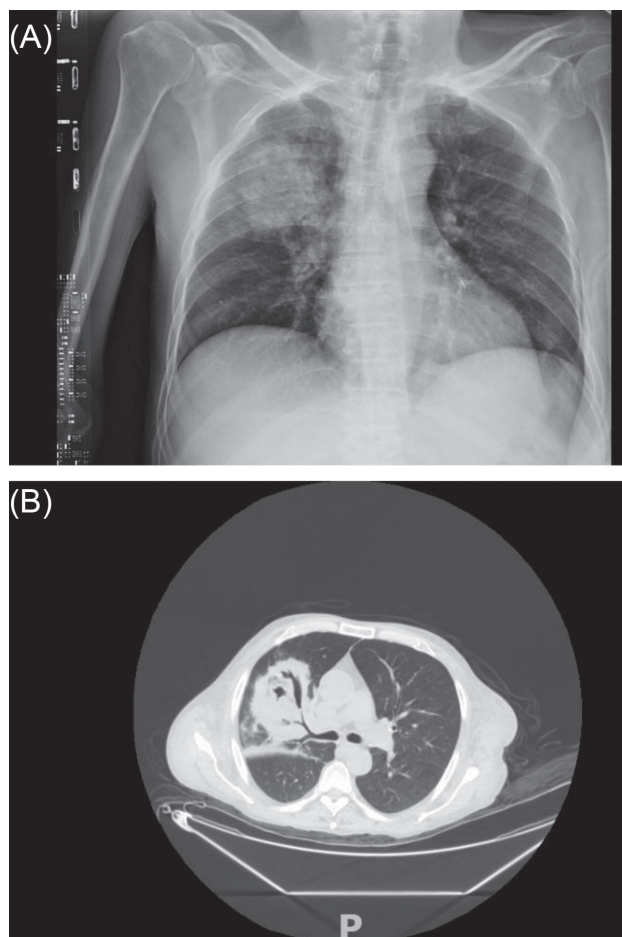
<sup>2</sup>Universidad Autónoma de Nuevo León, Facultad de Medicina y Hospital Universitario “Dr. José Eleuterio González”, Departamento de Cardiología, Monterrey, México

**Correspondence to:** Raúl Alberto Jiménez-Castillo  
Universidad Autónoma de Nuevo León, Facultad de Medicina y Hospital Universitario “Dr. José Eleuterio González”, Departamento de Medicina Interna, Av. Francisco I. Madero y Av. Gonzalitos, s/n, Colonia Mitras, Centro, Monterrey, C.P. 64460, México  
Tel: +52 818333 8381

**E-mail:** [raulalbertojc10@gmail.com](mailto:raulalbertojc10@gmail.com)

**Received:** 10 July 2020

**Accepted:** 23 November 2020



**Figure 1** - (A) Well circumscribed opacity in the right upper lobe of the chest x-ray of our 64-year-old patient; (B) A focal round opacity with an air bronchogram at the upper lobe of the right lung on a chest CT scan was seen in our patient.

identification, while antimicrobial susceptibility testing was performed with the MicroScan WalkAway 96 plus system (Beckman Coulter Life Sciences, Indianapolis, IN, USA), proven by the Minimum Inhibitory Concentration (MIC), and interpretation/classification following the Clinical and Laboratory Standards Institute guidelines<sup>5</sup> (Table 1).

Forty-eight hours after presentation to the emergency room, the patient developed a systemic respiratory distress syndrome, was intubated and transferred to the intensive care unit. Mechanical ventilation with a lung-protective strategy was provided. During his ICU stay the patient developed hemodynamic instability. Additional blood cultures were drawn and there was a subsequent antibiotic therapy escalation with imipenem/cilastatin; however, the patient did not respond and died of septic shock.

## DISCUSSION

Round pneumonia is a radiological and clinical entity described as the result of an infection that spreads

**Table 1** - Minimum inhibitory concentration (MIC) values of antimicrobial agents against *E. hormaechei*.

Antibiotic	MIC	Interpretation
Amikacin	≤ 16	Susceptible
Amoxicillin-clavulanate	> 16/8	Resistant
ampicillin-sulbactam	> 16/8	Resistant
Ampicillin	> 16	Resistant
Cefazolin	> 16	Resistant
Cefepime	≤ 4	Susceptible
Cefotaxime	> 32	Resistant
Ceftazidime	> 16	Resistant
Ceftriaxone	> 32	Resistant
Cefuroxime	> 16	Resistant
Ciprofloxacin	≤ 1	Susceptible
Ertapenem	1	Intermediate
Gentamicin	≤ 2	Susceptible
Imipenem/cilastatin	≤ 1	Susceptible
Levofloxacin	≤ 2	Susceptible
Meropenem	≤ 1	Susceptible
Piperacillin-tazobactam	32	Intermediate
Tetracycline	≤ 4	Susceptible
Tigecycline	≤ 2	Susceptible
Tobramycin	≤ 4	Susceptible
Trimethoprim-sulfamethoxazole	≤ 2/38	Susceptible

centrifugally through the accessory connections between bronchioles and alveoli (canals of Lambert), between alveoli (pores of Kohn), or by destroying the acini walls. Another theory sustains that underdeveloped pores of Kohn and the absence of canals of Lambert limit the spread of the organism, resulting in a focal, round lesion in the lung<sup>1</sup>.

Physicians are obliged to differentiate between an infectious and a malignant etiology, which appears to be challenging in this presentation. An air bronchogram is found in 5- 50% of cases on CT scans in adults<sup>1</sup>; however, up to 65% of malignant nodules present with this same radiological pattern. Therefore, an air bronchogram does not seem to help distinguishing between round pneumonia and malignancy.

Wagner *et al.*<sup>1</sup> reported that round pneumonia is more frequent in the lower lobe; accordingly, upper lobe lesions are especially suspicious of malignancy. It is important to note that, in contrast to what is reported in the existing literature, the predominance of these lesions in the upper lobe of the lung was found in the most contemporary review: nine (53.0%) cases in the upper lobes, six (35.3%) cases

in the lower lobe and 2 (12.7%) cases in the middle lobe (Table 1). The predominance of the upper lobe has also been confirmed in this case. The mean age of patients of the cited studies is 45.2 years; this finding is similar to a previously reported case with a mean age of 40.9<sup>3</sup>. This may help raising the suspicion that this is an infectious rather than a neoplastic process.

Infectious round infiltrates resolve over time, and the recommended assessment is through a repeated chest X-ray approximately eight weeks after treatment initiation<sup>6,7</sup>. However, studies in pediatric populations suggest that a follow-up chest X-ray is of limited value for those with a good response to medication<sup>8</sup>. Current practice guidelines of community-acquired pneumonia do not indicate the follow-up of patients with thoracic images if clinical improvement is evident, but recommendations for adults diagnosed with round pneumonia are not explicitly stated<sup>9</sup>.

Similar to patients with lobar pneumonia, the ideal antibiotic treatment should be directed against the most common bacterial pathogens (*Streptococcus pneumoniae*, *Klebsiella pneumoniae*, and *Haemophilus influenzae*)<sup>4,10</sup>. However, some authors suggest that Q fever is currently the leading cause of round pneumonia in adults.

First-line therapy consists of doxycycline, but macrolides (erythromycin and clarithromycin) and quinolones (levofloxacin) are also curative and prevent the progression to

chronic Q fever<sup>11</sup>. The duration of treatment for community-acquired pneumonia in current guidelines suggests a short 5-day course of antibiotics. Only patients without clinical improvement receive extended antibiotic therapy and further diagnostic approach<sup>9</sup>. Current antibiotic regimens for round pneumonia are typically long and highly heterogeneous, with duration ranging from 1 to 6 weeks (Table 2)<sup>3,4,12-24</sup>. In this regard, evidence-based recommendations on the duration of antibiotics in round pneumonia are needed. The pathogen identified in our case was *E. hormaechei*, which is a bacteria of the family Enterobacteriaceae that grows in most routine microbiological media and is identified by conventional tests<sup>25</sup>. Susceptibility testing can be performed using agar dilution, broth microdilution or disk diffusion. *E. hormaechei* is commonly susceptible to aminoglycosides, third-generation cephalosporins, carbapenems, and TMP/SMX, but resistant to aminopenicillins and penicillin G. According to a previous study, it is also susceptible to fluoroquinolones, but this finding contrasts with other reports<sup>26</sup>. Our patient had a poor clinical response to intravenous levofloxacin; for this reason, we switched to imipenem/cilastatin, but with no response. Risk factors for infection with *Enterobacter* spp. include immunosuppression, recent surgery, length of ICU stay, presence of an indwelling vascular or urinary catheter, and previous use of antibiotics<sup>26,27</sup>.

**Table 2 -** Main clinical, radiological and treatment characteristics of case reports on round pneumonia over the last 20 years.

Articles	Sex	Age	Risk factors	Main complaint	Chest image	Subsequent image	Antibiotic	Treatment duration	Bacterial pathogen	Outcome
Gupta <i>et al.</i> <sup>12</sup>	Female	29	None	Fever and cough	Chest X-ray and chest CT scan, right upper lobe	ChestX-ray, 2 weeks	Not specified	2 weeks	Not identified	Resolution
Yoshimura <i>et al.</i> <sup>13</sup>	Male	43	History of recent travel	Fever, fatigue, and headache	Chest X-ray and chest CT scan, right lower lobe	Not specified, 2 months	minocycline	3 days	<i>Rickettsia typhi</i>	Resolution
Mahmood <i>et al.</i> <sup>14</sup>	Female	74	Current smoker and older age	Dry cough and shortness of breathe	Chest X-ray and chest CT scan, right lower lobe	chest CT scan, 8 weeks	Not specified	Not specified	<i>Streptococcus pneumoniae</i>	Resolution
Harvey <i>et al.</i> <sup>15</sup>	Female	70	Older age	Fever, shortness of breathe, and productive cough	Chest X-ray and chest CT scan, right upper lobe	chest CT, not specified	co-amoxiclav and clarithromycin	Not specified	Not identified	Resolution
Cunha <i>et al.</i> <sup>16</sup>	Male	50	schizophrenia	Cough, fever, myalgias, and shortness of breathe	Chest X-ray, right upper lobe	ChestX-ray, 8 weeks	doxycycline	6 weeks	Not identified	Resolution
Köhne <i>et al.</i> <sup>17</sup>	Male	55	Current smoker, seizures. Parkinson's disease	Fever and cough	Chest X-ray and chest CT scan left upper lobe	chest CT scan, 2 weeks	ceftriaxone	2 weeks	Not identified	Resolution
Velasco-Tirado <i>et al.</i> <sup>18</sup>	Male	58	zoonosis (cats)	Fever, chills, headache, and abdominal pain	Chest X-ray and chest CT scan, right upper lobe	chest CT scan, 2 weeks	doxycycline	Not specified	<i>Rickettsia typhi</i>	Resolution

**Table 2** - Main clinical, radiological and treatment characteristics of case reports on round pneumonia over the last 20 years (cont.).

Articles	Sex	Age	Risk factors	Main complaint	Chest image	Subsequent image	Antibiotic	Treatment duration	Bacterial pathogen	Outcome
Velasco-Tirado <i>et al.</i> <sup>18</sup>	Male	20	zoonosis (dog)	Fever, dry cough, arthralgias, myalgias, headache, sweating and vomiting	ChestX-ray , Right middle lobe	ChestX-ray, 2 weeks	doxycycline	Not specified	<i>Rickettsia typhi</i>	Resolution
Kara <i>et al.</i> <sup>19</sup>	Female	26	None	Fever and myalgia	Chest X-ray and chest CT scan, Right middle lobe	Not specified	clarithromycin	10 days	None.	Resolution
Rodríguez <sup>20</sup>	Female	44	Current smoker, diabetes	Fever, dyspnea, chest pain	Chest X-ray and chest CT scan left lower lobe	ChestX-ray, 1 week	co-amoxiclav	7 days	None	Resolution
Jiménez-Castillo <i>et al.</i> <sup>21</sup>	Male	40	HIV infection	Fever, headache, and fatigue	Chest x-ray and chest CT scan left lower lobe	Chest X-ray and chest CT scan, 4 days	Co-trimoxazole	21 days	<i>Pneumocystis jirovecii</i>	Resolution
Violante-Cumpa <i>et al.</i> <sup>22</sup>	Male	44	Diabetes and chronic kidney disease	Dyspnea, orthopnea, and asthenia	Chest X-ray h and chest CT scan left upper lobe	Not specified	Ceftriaxone and clarithromycin	7 days	None	Resolution
Zhang <i>et al.</i> <sup>23</sup>	Male	43	None	Fever, chills, and cough	Chest X-ray and chest CT scan left upper lobe	chest CT scan, 2 weeks and 6 weeks	Ceftriaxone and azithromycin	2 weeks	none	Resolution
Zylberman <i>et al.</i> <sup>24</sup>	Female	24	None	Fever and dry cough	Chest X-ray and chest CT scan, right upper lobe.	ChestX-ray, 1 week	erythromycin	1 week	<i>Chlamydia psittaci</i>	Resolution
Zylberman <i>et al.</i> <sup>24</sup>	Female	34	None	Fever, dyspnea, and hemoptysis	Chest X-ray and chest CT scan, right upper lobe	Chest X-ray and chest CT scan, 1 week	Ampicillin–sulbactam plus clarithromycin	11 days	none	Resolution
Durning <i>et al.</i> <sup>4</sup>	Female	58	None	Fever, cough, and dyspnea.	Chest X-ray left lower lobe	ChestX-ray, 2 weeks	Levofloxacin	14 days	none	Resolution
Camargo <i>et al.</i> <sup>3</sup>	Female	57	Current smoker	Asymptomatic	Chest X-ray right lower lobe	ChestX-ray, 3 weeks	none	none	Not applicable	Resolution

Round pneumonia is an easily treatable infection as was corroborated by most of the cases reviewed here, but patients with abnormal immunity could progress rapidly to a life-threatening presentation<sup>10</sup>. We treated our patient according to bacterial susceptibility; despite this, his clinical evolution was unsatisfactory, potentially due to his history of liver cirrhosis, which has been associated with several abnormalities in innate and adaptive components of the immune system, leading to a state of acquired immunodeficiency and failure to resolve with standard therapy<sup>28</sup>. Laboratory tests for evaluation of cellular or antibody deficiencies were not available in our hospital at that moment.

The need for a standardized diagnosis and treatment approach in adults with round pneumonia is present. To the best of our knowledge, this is the first report on a case of round pneumonia due to *E. hormaechei*. There are several causes of oval lesions on chest images, however, clinicians should always have in mind this atypical presentation of a common disease.

## ACKNOWLEDGMENTS

We thank Sergio Lozano-Rodríguez, MD, for his critical review of the manuscript.

## CONFLICT OF INTERESTS

The authors declare that they have no conflict of interests.

## REFERENCES

1. Wagner AL, Szabunio M, Hazlett KS, Wagner SG. Radiologic manifestations of round pneumonia in adults. *AJR Am J Roentgenol.* 1998;170:723-6.
2. Zinkernagel AS, Schaffner A, Himmelman A. Photo quiz. Round pneumonia due to *Streptococcus pneumoniae*. *Clin Infect Dis.* 2001;32:1188.
3. Camargo JJ, Camargo SM, Machuca TN, Perin FA. Round

- pneumonia: a rare condition mimicking bronchogenic carcinoma. Case report and review of the literature. Sao Paulo Med J. 2008;126:236-8.
4. Durning SJ, Sweet JM, Chambers SL. Pulmonary mass in tachypneic, febrile adult. Chest. 2003;124:372-5.
  5. Clinical and Laboratory Standards Institute. Performance standards for antimicrobial susceptibility testing: M100. 30th ed. Wayne: CLSI; 2020.
  6. Harris M, Clark J, Coote N, Fletcher P, Harden A, McKean M, et al. British Thoracic Society guidelines for the management of community acquired pneumonia in children: update 2011. Thorax. 2011;66 Suppl 2:i1-23.
  7. Lakhanpaul M, Atkinson M, Stephenson T. Community acquired pneumonia in children: a clinical update. Arch Dis Child Educ Pract. 2004;89:ep29-34.
  8. McCrossan P, McNaughten B, Shields M, Thompson A. Is follow up chest X-ray required in children with round pneumonia? Arch Dis Child. 2017;102:1182-3.
  9. Metlay JP, Waterer GW, Long AC, Anzueto A, Brozek J, Crothers K, et al. Diagnosis and treatment of adults with community-acquired pneumonia: an official clinical practice guideline of the American Thoracic Society and Infectious Diseases Society of America. Am J Respir Crit Care Med. 2019;200:e45-67.
  10. Soubani AO, Epstein SK. Life-threatening "round pneumonia". Am J Emerg Med. 1996;14:189-91.
  11. Antón E. A frequent error in etiology of round pneumonia. Chest. 2004;125:1592-3.
  12. Gupta S, Goyal P, Rosinski A. A disappearing lung mass: round pneumonia. Am J Med. 2019;132:e656-7.
  13. Yoshimura Y, Sakamoto Y, Kwangyeol L, Amano Y, Tachikawa N. Round pneumonia with murine typhus after travel to Indonesia. J Travel Med. 2015;22:353-4.
  14. Mahmood T, Jou-Tindou AJ, Khasawneh FA. Round pneumonia in an elderly woman. Clin Case Rep. 2014;2:15-6.
  15. Harvey E, Varatharaj A. Round pneumonia. QJM. 2014;107:239.
  16. Cunha BA, Gran A, Simon J. Round pneumonia in a 50-year-old man. Respir Care. 2013;58:e80-2.
  17. Köhne R, Karabulut N, Herek D. Round pneumonia. JBR-BTR. 2012;95:150-1.
  18. Velasco-Tirado V, Hernández-Cabrera M, Pisos-Álamo E, Pérez-Arellano JL. Rickettsia typhi: a new causative agent of round pneumonia in adults. Enferm Infecc Microbiol Clin. 2012;30:427-8.
  19. Kara PH, Demircan A, Akinci E, Bildik F, Aygencel G, Ozsarac M. Focal mass-like opacity on chest radiography: round pneumonia. J Emerg Med. 2010;39:e89-90.
  20. Rodríguez E. A propósito de un caso de neumonía redonda. Semergen. 2018;44:515-6.
  21. Jiménez-Castillo RA, Fernández LT, Vera-Pineda R, Carrizales-Sépulveda EF, García-Arellano G, González Aguirre JE. Round opacity as a presentation of pneumocystis jirovecii pneumonia in an HIV-infected patient. Am J Emerg Med. 2019;37:176.e3-4.
  22. Violante-Cumpa JR, Violante-Cumpa KA, Carrizales-Sépulveda EF. Unusual radiographic presentation of pneumonia in adults with chronic kidney disease. Intern Emerg Med. 2019;14:811-2.
  23. Zhang Y, Yu YS, Tang ZH, Chen XH, Zang GQ. Round pneumonia in an adult. Southeast Asian J Trop Med Public Health. 2014;45:207-13.
  24. Zylberman M, Cordova E, Farace G. Round pneumonia in adults, an unusual presentation of lung parenchymal infection: a report of two cases and review of the literature. Clin Pulm Med. 2006;13:229-31.
  25. O'Hara CM, Steigerwalt AG, Hill BC, Farmer 3rd JJ, Fanning GR, Brenner DJ. Enterobacter hormaechei, a new species of the family Enterobacteriaceae formerly known as enteric group 75. J Clin Microbiol. 1989;27:2046-9.
  26. Davin-Regli A, Bosi C, Charrel R, Ageron E, Papazian L, Grimont PA, et al. A nosocomial outbreak due to Enterobacter cloacae strains with the E. hormaechei genotype in patients treated with fluoroquinolones. J Clin Microbiol. 1997;35:1008-10.
  27. Wenger PN, Tokars JI, Brennan P, Samel C, Bland L, Miller M, et al. An outbreak of Enterobacter hormaechei infection and colonization in an intensive care nursery. Clin Infect Dis. 1997;24:1243-4.
  28. Albillos A, Lario M, Álvarez-Mon M. Cirrhosis-associated immune dysfunction: distinctive features and clinical relevance. J Hepatol. 2014;61:1385-96.