

PARACOCCIDIOIDOMYCOSIS: A RECENTLY PROPOSED CLASSIFICATION OF ITS CLINICAL FORMS

Marcello Franco¹, Mário Rubens Montenegro¹, Rinaldo Pôncio Mendes²,
Silvio Alencar Marques², Neusa L. Dillon² and Norma Geresa da Silva Mota³

Many attempts have been made to define the clinical forms of human paracoccidiodomycosis¹⁵. Several classifications are based on different parameters of the disease such as entry route (tegumentary or pulmonary¹⁵); presence or absence of signs and/or symptoms (infection vs. disease^{2 14}); organs involved (lymphatic form; pulmonary form¹⁵); presence or absence of activity (active; latent¹²); type of evolution (progressive; regressive^{12 20}); duration of the disease (acute; subacute; chronic⁴); clinical course (localised; systemic^{4 26}); type of infection (primary; endogenous or exogenous reinfection¹⁹); presence or absence of sequelae (cor pulmonale; Addison's disease¹²); pathological anatomy (isolated organic form; pseudotumoral forms²²) and immunohistological response (polar forms²¹).

This variety of criteria is an indication of the partial acceptance of most of them. This is comprehensible since we still do not know where the fungus comes from and how it invades the human host, making difficult the evaluation of the early phases of the disease.

In the "Segundo Encontro sobre Paracoccidiodomycose" held in Botucatu, Brazil, in 1983, a committee of experts* was nominated with the objective of proposing a classification of clinical forms of the disease. A questionnaire was circulated among the members and the committee reconvened at the Inter-

national Colloquium on Paracoccidiodomycosis held in February 1986 in Medellin, Colombia. During the meeting, the written comments of all members were analysed and a new simple classification was agreed. The members also agreed on the necessity of disseminating information on the new classification to the South American specialists.

In this paper we describe this new classification (Table 1) and outline its correlation with the natural history of paracoccidiodomycosis (Figure 1).

Table 1 - Proposed Classification of Paracoccidiodomycosis.

-
1. Paracoccidiodomycosis Infection
 2. Paracoccidiodomycosis Disease
 - 2.1. Acute or subacute form (Juvenile type)
 - 2.1.1. Moderate
 - 2.1.2. Severe
 - 2.2. Chronic form (Adult type)
 - 2.2.1. Unifocal
 - Mild
 - Moderate
 - Severe
 - 2.2.2. Multifocal
 - Mild
 - Moderate
 - Severe
 3. Residual forms (Sequelae)
-

1. Department of Pathology, School of Medicine/UNESP, Botucatu, São Paulo, Brazil.

2. Department of Infectious and Parasitic Disease, Dermatology, and Radiology, School of Medicine/UNESP, Botucatu, São Paulo, Brazil.

3. Department of Microbiology and Immunology/IBBMA/UNESP, Botucatu, São Paulo, Brazil.

Correspondence to: Dr. Mário R. Montenegro, Dept^o Patologia, Faculdade de Medicina de Botucatu/UNESP, 18610 Botucatu, São Paulo, Brasil.

(* The committee include Dr. Maria de Albornoz (Caracas, Venezuela), Dr. Gildo Del Negro (São Paulo, Brazil), Dr. Adhemar Fiorillo (Ribeirão Preto, Brazil), Dr. Alberto Londero (Santa Maria, Brazil), Dr. Ricardo Negroni (Buenos Aires, Argentina), Dr. Antar Padilha-Gonçalves (Rio de Janeiro, Brazil) and Dr. Angela Restrepo (Medellin, Colombia). In Medellin, Dr. Marcello Franco (Botucatu, Brazil) and Dr. Maria Shikanai-Iasuda (São Paulo, Brazil) also participated. The committee was chaired by Dr. Mário Rubens Montenegro (Botucatu, Brazil).

Recebido para publicação em 28/4/86

From its natural habitat, *Paracoccidioides brasiliensis* (*P. brasiliensis*) penetrates the host, usually the lungs or exceptionally through the integument. Once within the tissues, the parasite may be immediately destroyed or may multiply, to produce a *inoculation lesion*. The fungus then drains into the regional lymph nodes, producing a *satellite lymphatic lesion*. The inoculation and the satellite lymphatic lesions form the *primary complex*: lung + lymph node of the hilus or integument + draining lymph nodes. Haematogenic dissemination of the fungus may occur at this moment, with the establishment of lesions in any organ of the host constituting *metastatic foci*. Throughout this period, there may be no apparent signs or symptoms, the silent *paracoccidiodomycosis infection*.

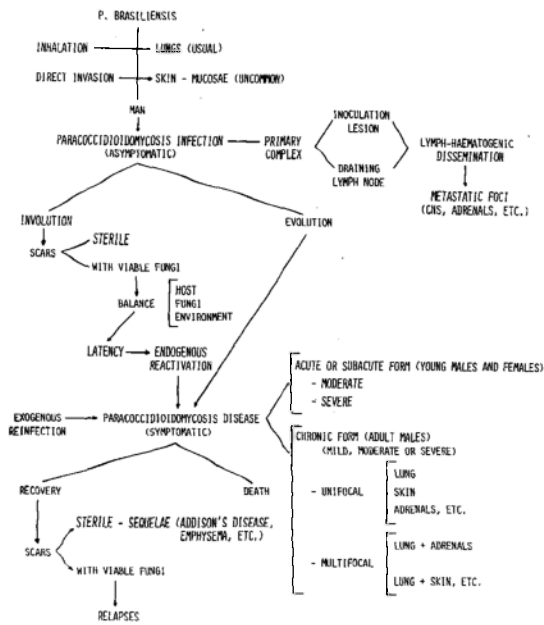


Fig. 1 – Paracoccidioidomycosis: natural history and clinical forms.

However host sensitization may occur with the development of an immunospecific response and positivity of the paracoccidioidin intradermal test.

The foci in this initial form may: i) regress with fungus destruction and formation of *sterile scars*; ii) regress with the maintenance of viable fungi and formation of quiescent foci; or iii) progress leading to the appearance of signs and symptoms.

The onset of clinical manifestations characterises the beginning of *paracoccidioidomycosis disease*, which may arise in three different ways:

1. Direct evolution from the primary complex without latency.
2. Reactivation of quiescent foci from the primary complex (endogenous reinfection).
3. Exogenous reinfection after a previous infection.

Once established, the disease may evolve in two ways:

(1) *Acute or subacute form* – the disease is established from an usually undetected primary lesion and progresses rapidly, by lymphatic and lympho-haematogenic dissemination to the monocytic-macrophagic system (spleen, liver, lymph nodes, bone marrow). The clinical picture is characterised by systemic lymph node involvement, hepatosplenomegaly and bone marrow dysfunction. This picture may mimic a systemic lymphoproliferative disease and depending on the degree of dissemination, can be subtyped to moderate or severe forms. It affects young patients of

both sexes. In most cases, the specific humoral immune response tends to be maintained with high antibody titers, but there is severe depression of the cellular immunity. Histopathology reveals loose granulomata with large numbers of actively multiplying fungi.

(2) *Chronic form* – the disease starts from the primary complex or from quiescent foci and develops slowly, remaining localized or involving more than one organ or system. Symptoms may be referred to a single (unifocal form) or to more than one organ or system (multifocal form). As most of the cases of chronic paracoccidioidomycosis start in the lungs, the disease may remain there with slow and progressive morphologic and clinical pulmonary involvement, the *pulmonary unifocal form*. The infection may then spread by bronchogenic, lymphatic or lympho-haematogenic routes, the *multifocal form*. Less frequently, primary progressive and isolated muco-cutaneous involvement occurs the *tegumentary unifocal form*.

On the other hand, the disease may start from metastatic foci, such as those in the central nervous system, intestine, bone, adrenals, genital organs etc. The patients seek medical care because of the involvement of an organ or system not related to the area of inoculation, the *extra pulmonary unifocal form*.

Depending on the clinical findings and the patient's general condition, chronic forms can be subtyped in mild, moderate or severe. Patients may die or recover: the healed lesions may contain viable fungi (quiescent foci) or leave sequelae (respiratory insufficiency; chronic cor pulmonale; Addison's disease). Under conditions favourable to the parasite, the disease may be reactivated from quiescent foci, thus reinitiating the cycle.

The chronic form affects almost only adult males. The specific humoral response is variable; cellular immunity is preserved in the unifocal forms but may be depressed in the multifocal forms. Histopathology reveals more compact epithelioid granulomata with smaller numbers of fungi.

The proposed classification is based on the natural history of the disease. We started from the principle that the natural history of paracoccidioidomycosis, as has been described for other deep mycoses, should follow the same steps as that classically described for tuberculosis, the model disease for chronic granulomatous disorders^{6 7 11 13}.

There is both direct and indirect evidence for the occurrence of paracoccidioidomycosis infection without disease. Namely the detection of fibrous and/or calcified pulmonary nodules containing dead or viable fungi³; the existence of scarred lesions in the lymph nodes of the pulmonary hilus³¹; the detection of a pulmonary primary complex with lymphangitis and satellite adenopathy in a surgical fragment from a patient with lung carcinoma³² and the relatively

high percentage of positive skin tests for paracoccidioidomycosis among normal individuals living in endemic areas^{2 14 17}. Although well characterised for histoplasmosis and coccidioidomycosis¹⁵, a symptomatic paracoccidioidomycosis infection (Fava Netto: personal communication) is seldom diagnosed.

For the classification of the clinical forms of paracoccidioidomycosis we started from the fact that the mycosis may evolve: 1) rapidly with a tendency towards dissemination and impairment of patient's general condition, usually affecting young individuals of both sexes, or 2) slowly, with localized lesions, involving a smaller number of organ systems and generally affecting adult males. These two types of evolution respectively characterize the acute or subacute form and the chronic form^{4 10 12 19 28 30}.

The recognition of the acute or subacute form is widespread in the literature. The entry route of the fungus usually goes undetected, since these patients rarely have a history of tegumentary lesion or radiologically detectable lung damage^{4 5 15}. The disease may diffusely involve the reticuloendothelial system, replacing these tissues with macrophages that do not succeed in destroying the fungus or blocking its multiplication. The overall picture may simulate leukemia or malignant systemic reticulosis in severe forms. It may involve more localized segments of the lymphoid or reticuloendothelial system with a picture simulating a lymphoma (moderate form)⁵. Patients with the acute or subacute forms have been classified as belonging to the anergic or negative pole of paracoccidioidomycosis³³. They usually exhibit a marked decrease of the cellular immune response to *P. brasiliensis* antigens²¹. Antibody titers are high⁸.

However most of the patients have chronic forms of disease. In these cases the host has greater defense against the parasite which leads to a more protracted and localized course. Progressing from the inoculation lesion the disease may remain restricted or localized thus characterising the unifocal pulmonary (more frequent) or the tegumentary unifocal chronic forms^{9 16}. The disease may also manifest itself by symptoms referred to other organs or systems starting from reactivation of quiescent metastatic foci (other unifocal forms). It should be pointed out here that in cases of unifocal organic involvement specific lesions in other organs, with no clinical manifestations have been found^{24 25}. When the lesions in these other organs expand and cause clinical manifestations, the patients exhibit the multifocal chronic form. Frequent examples are tegumentary-pulmonary, pulmonary-adrenal and pulmonary-lymphatic involvement.

A few chronic forms originating from metastatic foci are more circumscribed and encapsulated charac-

terizing the pseudotumoral forms, the most outstanding example being the paracoccidioma^{27 29}.

Patients with chronic forms maintaining a good general condition, intact cell immunity and exhibiting granulomata of the sarcoid type are classified as belonging to the hyperergic or positive pole of the disease³³.

Paracoccidioidomycosis usually behaves as a disease of insidious onset and slow evolution, with relapses in which clinical manifestations may differ from those of previous attacks¹¹. Variations in the intensity, extent, dissemination, and characteristics of the lesions will occur in a given patient depending on changes in fungal virulence, fluctuations of the defense and immunological mechanisms of the host and on environmental factors¹¹. When a patient is classified in a clinical form, we should not forget that he is at a particular phase of a dynamic and polymorphic disease.

There are signs indicating that paracoccidioidomycosis exhibit variations in the frequency of clinical forms in different regions of the same country^{5 15} or in different countries^{1 12 15 18 23 28}. This suggests either the existence of distinct *P. brasiliensis* strains, variation in the susceptibility of exposed individuals or environmental factors. These are important and as yet unelucidated aspects of the disease. The only way of comparing patients from different regions is by establishing an easily applicable, generally accepted simple classification of the clinical forms. This is the main purpose of this communication.

REFERENCES

1. Albornoz MB. Paracoccidioidomycosis: estudio clinico y inmunologico en 40 pacientes. Archivos del Hospital Vargas (Caracas) 18:5-22, 1976.
2. Albornoz MB. Paracoccidioidomycosis-infección. In: Paracoccidioidomycose. Blastomicose sul-americana. Del Negro G, Lacaz CS, Fiorillo AM (eds), São Paulo, Sarvier-Edusp. pp. 91-96, 1982.
3. Angulo-Ortega A. Calcifications in paracoccidioidomycosis: are they the morphological manifestation of subclinical infections? In: Paracoccidioidomycosis. Proceedings First Panamerican Symposium, PAHO, Washington, Scientific Publications n° 254, pp. 129-133, 1972.
4. Barbosa W. Blastomicose sul-americana. Contribuição ao seu estudo no Estado de Goiás, Goiânia. Tese de docência livre. Faculdade de Medicina da Universidade Federal de Goiás, Goiânia, 1968.
5. Barbosa W, Daher R, Oliveira AR. Forma linfática abdominal da blastomicose sul-americana. Revista do Instituto de Medicina Tropical de São Paulo 10: 16-27, 1968.
6. Bayer AS. Fungal pneumonias: pulmonary coccidioidal syndromes (Part I). Primary and progressive primary

- coccidioidal pneumonias – Diagnostic, therapeutic and prognostic considerations. *Chest* 79: 575-583, 1981.
7. Bayer AS. Fungal pneumonia: pulmonary coccidioidal syndromes (Part II). Miliary, nodular, and cavitary pulmonary coccidioidomycosis; chemotherapeutic and surgical considerations. *Chest* 79: 686-691, 1981.
 8. Biagioni L, Souza MJ, Chamma LG, Mendes RP, Marques SA, Mota NGS, Franco M. Serology of paracoccidioidomycosis. II. Correlation between class-specific antibodies and clinical forms of the disease. *Transactions of the Royal Society of Tropical Medicine and Hygiene* 78: 617-621, 1984.
 9. Castro RM, Cucé LG, Fava Netto C. Paracoccidioidomycose. Inoculação experimental “in animal nobile”. Relato de um caso. *Medicina Cutânea Ibero-Latino-Americana* 3: 289-292, 1975.
 10. Fava Netto C. Contribuição para o estudo imunológico da blastomicose de Lutz. *Revista do Instituto Adolfo Lutz* 21: 99-194, 1961.
 11. Franco MF, Montenegro MRG. Anatomia patológica. In: Paracoccidioidomycose. Blastomicose sul-americana. Del Negro G, Lacaz CS, Fiorillo AM (eds) São Paulo, Sarvier – Edusp. pp. 97-117, 1982.
 12. Giraldo R, Restrepo A, Gutiérrez F, Robledo M, Londoño F, Hernández H, Sierra F, Calle G. Pathogenesis of paracoccidioidomycosis: a model based on the study of 45 patients. *Mycopathologia* 58: 63-70, 1976.
 13. Goodwin Jr RA, Shapiro JL, Thurman GH, Thurman SS, Des Prez RM. Disseminated histoplasmosis: clinical and pathological correlations. *Medicine* 59: 1-33, 1980.
 14. Lacaz CS, Passos Filho MCR, Fava Netto C, Macarron B. Contribuição para o estudo da “blastomicose infecciosa”. Inquérito com a paracoccidioidina. Estudo sorológico e clínico-radiológico dos paracoccidioidinopositivos. *Revista do Instituto de Medicina Tropical de São Paulo* 1: 254-259, 1959.
 15. Lacaz CS. *Micologia médica*, 6ª. ed, São Paulo, Sarvier S/A Editora, pp. 229-274, 1977.
 16. Lacaz CS, Castro RM, Minami PS, Viegas AC. Blastomycosis sudamericana con localización perianal primitiva. *Dermatologia (México)* 8: 242-250, 1964.
 17. Londero AT. Epidemiologia da paracoccidioidomycose. *Ars Curandi* 7: 14-22, 1975.
 18. Londero AT. Paracoccidioidomycosis. In: Infectious diseases. Hoeprich PD (ed) 3rd ed, Harper & Row Publication, Maryland, USA, in press.
 19. Londero AT, Ramos CD, Lopes JO. Paracoccidioidomycose: classificação das formas clínicas. *Revista Uruguaya de Patologia Clínica y Microbiología* 14: 3-9, 1976.
 20. Londero AT. Paracoccidioidomycose. I – Patogenia, formas clínicas, manifestações pulmonares e diagnóstico. *Jornal de Pneumologia* 12: 41-57, 1986.
 21. Mota NGS, Iwasso MTR, Peraçoli MTS, Audi RC, Mendes RP, Marcondes J, Marques SA, Dillon NL, Franco MF. Correlation between cell-mediated immunity and clinical forms of paracoccidioidomycosis. *Transactions of the Royal Society of Tropical Medicine and Hygiene* 79: 765-772, 1985.
 22. Motta LC, Pupo JA. Granulomatose paracoccidioidica (blastomicose brasileira). *Anais da Faculdade de Medicina de São Paulo* 12: 407-426, 1936.
 23. Negroni P, Negroni R. Nuestra experiencia de la blastomycosis sudamericana en la Argentina. *Mycopathologia* 26: 264-272, 1965.
 24. Padilha Gonçalves A. Localizações ganglionares da micose de Lutz (Blastomicose brasileira). *Boletim da Academia Nacional de Medicina* 1: 5-17, 1962.
 25. Padilha Gonçalves A. Adenopathy in paracoccidioidomycosis. In: Paracoccidioidomycosis. Proceedings of First Panamerican Symposium, PAHO, Washington, Scientific Publication n° 254: 189-190, 1972.
 26. Padilha Gonçalves A. Paracoccidioidomycose. Atualidade, Classificação. *Anais Brasileiros Dermatologia* 60 (supl 1): 271-280, 1985.
 27. Pereira WC, Raphael A, Sallum J. Lesões neurológicas na blastomicose sul-americana. Estudo anatomopatológico de 14 casos. *Arquivos de Neuro-Psiquiatria* 23: 95-112, 1965.
 28. Restrepo A. Paracoccidioidomycosis. *Acta Medica Colombiana* 3: 33-65, 1978.
 29. Restrepo A, Bedout C, Cano LE, Arango MD, Bedoya V. Recovery of *Paracoccidioides brasiliensis* from a partially calcified lymph node lesion by microaerophilic incubation of liquid media. *Sabouradia* 19: 295-300, 1981.
 30. Restrepo A, Robledo M, Giraldo R, Hernández H, Sierra F, Gutiérrez F, Londoño F, López R, Calle G. The gamut of paracoccidioidomycosis. *American Journal of Medicine* 61: 33-42, 1976.
 31. Severo LC. Paracoccidioidomycose. Estudo clínico e radiológico das lesões pulmonares e seu diagnóstico. Tese de Mestrado. Porto Alegre, 1979.
 32. Severo LC, Geyer G.R, Londero AT, Porto NS, Rizzon CFC. The primary pulmonary lymph node complex in paracoccidioidomycosis. *Mycopathologia* 67: 115-118, 1979.
 33. Zamith VA, Lacaz CS, Siqueira AM, Santos CRA, Oliveira ZNP. Paracoccidioidomycose – forma hiperérgica com prováveis lesões de micide (blastomíctide ou paracoccidioidomíctide). Registro de um caso. *Anais Brasileiros de Dermatologia* 56: 273-278, 1981.