

Schistosomiasis mansoni of the bladder simulating bladder cancer: a case report

Esquistossomose mansônica simulando câncer de bexiga: relato de caso

Mário Luis Casella¹, Victor Silvestre Soares Fanni¹, Douglas Otto Verndl¹,
Monique Camila Basso², Luiz Figueiredo Mello¹ and Sidney Glina¹

ABSTRACT

The relationship between bladder tumors and *Schistosoma haematobium* is well known, but only sporadic cases of bladder infection due to *Schistosoma mansoni* have been reported. In this case, a 48-year-old woman with macroscopic hematuria, dysuria and a palpable abdominal mass was investigated. Ultrasound showed a large exophytic mass in the bladder. Transurethral resection of the bladder revealed viable eggs of *Schistosoma mansoni*. The patient was treated clinically with oxamniquine and surgery was performed to resect the large mass. This case shows that schistosomiasis Mansoni in the bladder can simulate bladder cancer.

Key-words: *Schistosoma mansoni*. Bladder cancer. Leiomyoma. Schistosomiasis. Oxamniquine.

RESUMO

É bem conhecida a relação entre tumor vesical e *Schistosoma haematobium*, porém somente casos esporádicos de infecção vesical por *Schistosoma mansoni* foram relatados. Neste caso, uma mulher de 48 anos com hematúria macroscópica, disúria e massa abdominal palpável foi investigada, ultra-sonografia mostrou uma grande massa exofítica na bexiga. A ressecção transuretral de bexiga evidenciou ovos viáveis de *Schistosoma mansoni*. A paciente foi tratada clinicamente com oxaminiquine e uma cirurgia foi realizada para ressecar a grande massa. Este caso mostra que a esquistossomose mansônica vesical pode simular um câncer vesical.

Palavras-chaves: *Schistosoma mansoni*. Câncer de bexiga. Leiomioma. Esquistossomose. Oxaminiquine.

Schistosoma mansoni infection is an endemic disease in Brazil and gastrointestinal affection is very common. However, there have only been anecdotal reports of bladder infection due to *Schistosoma mansoni*, in contrast with the known risk of developing bladder cancer in patients affected by *Schistosoma haematobium*.

CASE REPORT

A 48-year-old female patient originating from an endemic area for schistosomiasis in Brazil (Bahia) was seen at our hospital because of abnormal menstrual bleeding, gross hematuria, urinary frequency and dysuria. Physical evaluation showed a palpable painful mass in the pelvic region. Ultrasound showed a large exophytic lesion filling almost the entire bladder (**Figure 1**).

Cystoscopy revealed a large regular rounded mass of diameter 8 cm without any visible stalk. Transurethral biopsy showed chronic cystitis and viable eggs of *Schistosoma mansoni*. Colonoscopy showed ulcers in the rectum-sigmoid.

The patient was treated clinically with oxamniquine. Her renal function deteriorated and ultrasound showed bilateral dilatation of the ureter. A double-J catheter was then placed in both ureters. The patient continued to present impaired renal function and

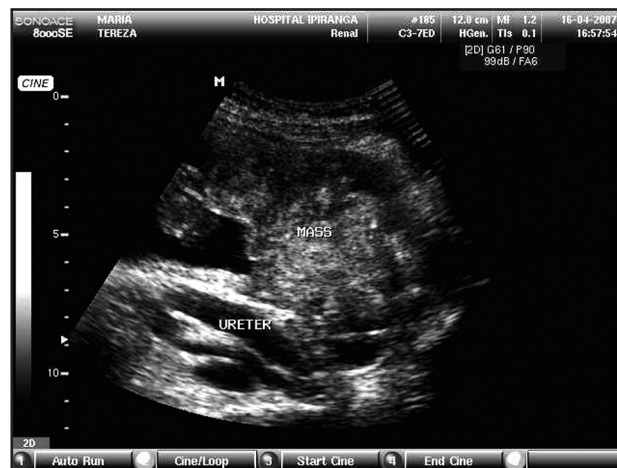

FIGURE 1

Ultrasound on the bladder showing a bladder mass.

1. Department of Urology, Ipiranga Hospital, São Paulo, SP. 2. Department of Pathology, Ipiranga Hospital, São Paulo, SP.

Address to: Dr. Mário Luis Casella. Rua Bartolomeu Faria 402/32, 02730-050 São Paulo, SP, Brasil.

Tel: 55 11 2069-9629

e-mail: mlcasella@ig.com.br

Received in 12/03/2009

Accepted in 18/08/2009

bilateral dilatation of the ureter and renal pelvis (as shown by tomography). After opening up a left-side nephrostomy, the renal function improved. Resection of the bladder mass was performed and it was possible to maintain the bladder because there was a stalk between the mass and the bladder (**Figure 2**). Hysterectomy was also performed because of the abnormal menstrual bleeding. The mass was found to measure 12cm across its largest diameter (**Figure 3**). Microscopic examination of the lesion showed a chronic granulomatous inflammatory process with *Schistosoma mansoni* eggs, spindle cell bundles and myxoid degeneration of the stroma (**Figure 4**). The immunohistochemical findings were compatible with leiomyoma (caldesmon and smooth muscle actin positive). The patient's evolution was uneventful with complete remission of the symptoms and restoration of renal function.

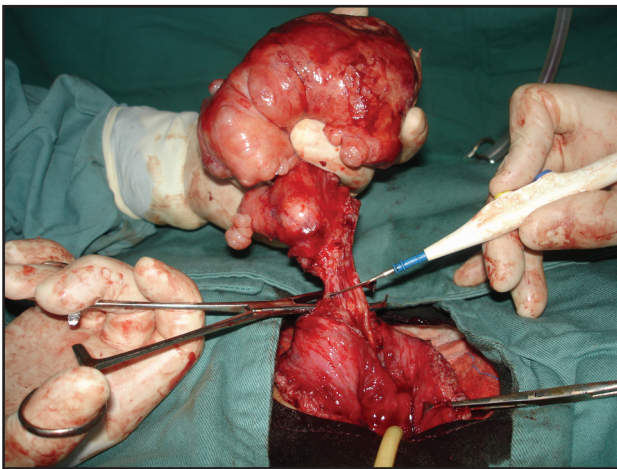


FIGURE 2

Stalk between the bladder and the mass.

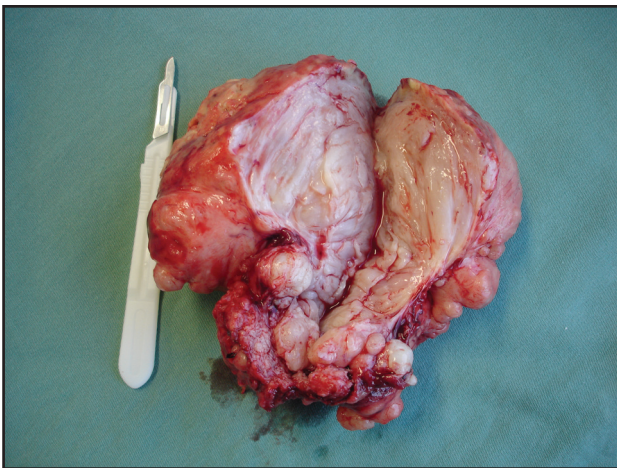


FIGURE 3

Macroscopic appearance of the resected mass.

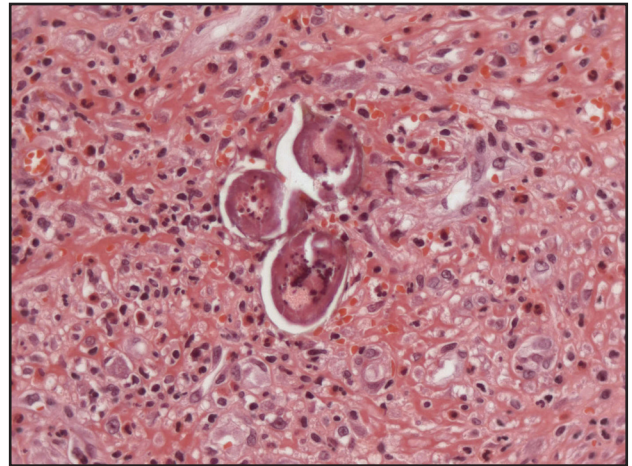


FIGURE 4

Viable *Schistosoma mansoni* eggs inside the leiomyoma (hematoxylin-eosin 400X).

DISCUSSION

The case reported here shows a rare form of ectopic schistosomiasis Mansonis. Only four other cases of bladder involvement have been reported anywhere in the world, all of them in Brazil and published in Portuguese. In 1944, a necropsy study² showed one case. In 1977, Sayão et al⁴ described the case of a 37-year-old man affected with this rare bladder form of the disease, who was treated only with drugs. Mitre et al³ described another case of a 23-year-old man with dysuria and terminal hematuria who was treated with oxamniquine in association with transurethral resection of the lesions. Lopes et al¹ reported the case of a 36-year-old man for whom the treatment was also transurethral resection in association with oxamniquine. In our case, the transurethral resection with biopsy was of great importance in the diagnosis, based on the suspicion of a bladder cancer. However, unfortunately, the lesion was so big that was impossible to resect it all transurethrally. Moreover, the use of oxamniquine associated with surgery seems to be important for curing the patient because of the large size of the mass. Another important observation is that the bladder mass caused by schistosomiasis simulated bladder cancer.

REFERENCES

1. Lopes EJ, Santos TC, Martins V. Esquistossomose mansônica simulando neoplasia da bexiga. *Revista da Sociedade Brasileira de Medicina* 39:287-288, 2006.
2. Meira JA. Esquistossomose mansônica com localização vesical. *Seara Médica* 3:61, 1944.
3. Mitre A, Alfer Jr W, Nahas W, Arap S. Esquistossomose mansônica vesical simulando tumor: Relato de um caso. *Revista da Associação Médica Brasileira* 26:74-76, 1980.
4. Sayão RH, Cury J, Carneiro Neto J, Sayão MH. Esquistossomose mansônica vesical. *Jornal Brasileiro de Urologia* 3:114-116, 1977.