

# A rare case of gastric mucormycosis in an immunocompetent patient

**Bruno Fernandes Barros Brehme de Abreu<sup>[1]</sup>, Márcio Luís Duarte<sup>[1]</sup>, Lucas Ribeiro dos Santos<sup>[2]</sup>, Angelo Sementilli<sup>[3]</sup> and Felipe Nunes Figueiras<sup>[4]</sup>**

[1]. Radiologia, WEBIMAGEM, São Paulo, SP, Brasil.

[2]. Endocrinologia, Faculdade de Ciências Médicas de Santos, Santos, SP, Brasil.

[3]. Patologia, Irmandade da Santa Casa da Misericórdia de Santos, Santos, SP, Brasil.

[4]. Radiologia, Hospital Guilherme Álvaro, Santos, SP, Brasil.

### Abstract

We report the case of a 23-year-old immunocompetent patient who presented at the emergency department of a Brazilian hospital with epigastric pain and fever. After an investigation that included a computed tomography scan and upper gastrointestinal endoscopy with biopsy, a diagnosis of mucormycosis was established. The patient exhibited favorable progress after surgery and antifungal therapy. Mucormycosis is a rare condition that usually affects immunocompromised patients, with a high mortality rate of up to 85%. Correct diagnosis and fast initiation of therapy are required to ensure improved patient prognosis.

**Keywords:** Mucormycosis. Stomach diseases. Computed tomography.

### INTRODUCTION

Mucormycosis is a rare, opportunistic fungal infection led by fungal agents within the order *Mucorales*<sup>1</sup>; occurs almost solely in immunocompromised hosts, such as patients with diabetes mellitus (which is a major predisposing factor), burns, malnutrition, leukemia, lymphoma, septicemia, renal disease, and following long-term treatment with steroids and antibiotics; and is associated with high mortality rates<sup>1-3</sup>.

Nevertheless, 19% of patients have no underlying condition at the time of infection. Patients with human immunodeficiency virus (HIV) infection represent only 2% of those with zygomycosis<sup>4</sup>. Based on autopsy data, the prevalence is 1-5 cases per 10,000 individuals with hematological neoplasms, which is far less prevalent than invasive *Candida* or *Aspergillus* infections<sup>4</sup>.

### CASE REPORT

A 23-year-old woman presented with a 1-month history of diffuse abdominal pain, which was predominantly epigastric, in addition to abdominal distension, vomiting, and fever. The patient reported normal feeding. Also, refers previous tuberculosis, with complete treatment; no other previous diseases; and no alcoholism, smoking, or illicit drug use.

Physical examination showed a tender abdomen, painful to superficial and deep palpation, with no other notable signs. A complementary examination revealed the following:

- Hemoglobin: 11.0g/dL
- Hematocrit: 30.9%
- Platelets: 336,000/mm<sup>3</sup>
- Creatinine: 0.6mg/dL
- Urea: 26mg/dL
- Leukocytes: 3,695/mm<sup>3</sup>
- C-reactive protein: 11.25mg/dL
- Sodium: 141mEq/L
- Potassium: 3.7mEq/L
- Serology for HIV: negative

In the following investigation, contrast-enhanced radiography revealed a hypotonic stomach with excess of fluid retention and difficulty in emptying (**Figure 1**). Computed tomography (CT) with oral contrast showed diffuse gastric distension associated with diffuse parietal thickening, and heterogeneous impregnation by contrast, identifying the gastric antrum lumen containing liquid contents (**Figure 1** and **Figure 2**). The stomach exhibited inferior displacement of the intestine and transverse colon loops (**Figure 2**).

Upper gastrointestinal endoscopy revealed enanthematic gastritis of slight intensity. Based on the anatomopathological evaluation, the gastric segment measured 25.0×12.0×6.0cm and was smooth, serous, gleaming, and brownish in color. The mucosa was brownish in color with pre-clearing and a firm consistency, with thickened regions up to 5.0cm. The biopsy demonstrated chronic granulomatous and suppurative diffuse

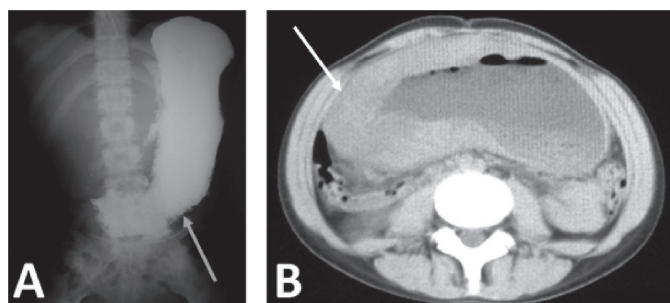
**Corresponding author:** Dr. Márcio Luís Duarte

**e-mail:** marcioluisduarte@gmail.com

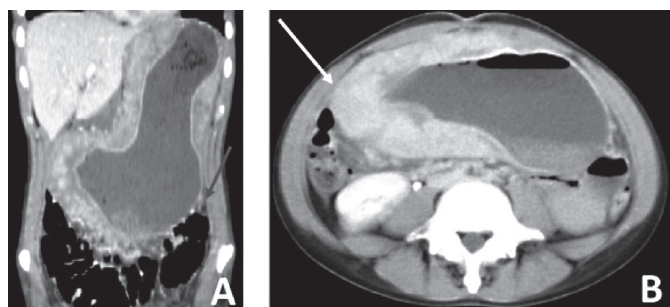
**Received** 3 August 2017

**Accepted** 4 April 2018





**FIGURE 1:** **A.** Contrast-enhanced radiography reveals a hypotonic stomach with excess fluid retention and difficulty in emptying (arrow). **B.** CT scan in the axial section without contrast demonstrating diffuse gastric distension associated with diffuse parietal thickening (arrow). **CT:** computed tomography.



**FIGURE 2:** Post-contrast CT scans. **A.** Venous phase in the sagittal section and **B.** late phase, demonstrating the stomach exhibiting inferior displacement of the thin intestinal loops and transverse colon. Diffuse gastric distension was associated with diffuse parietal thickening, which presented heterogeneous impregnation with contrast (arrow). **CT:** computed tomography.

gastritis, associated with marked fibrosis of the gastric wall, presenting voluminous zygomyces hyphae (**Figure 3**).

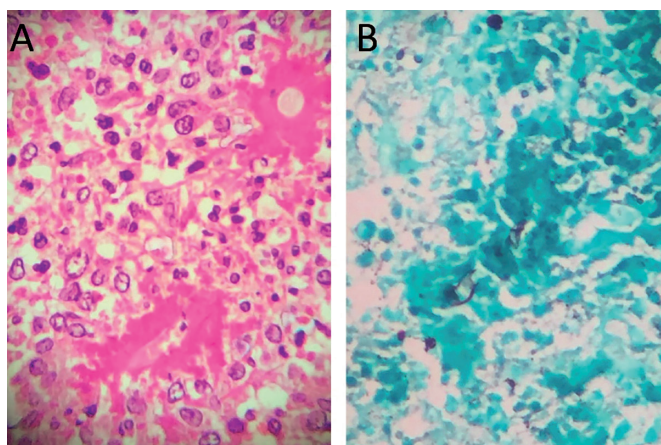
The patient underwent total gastrectomy, with lymphadenectomy and esophagoenteroanastomosis, and treatment containing amphotericin B. Her clinical evolution during 6 weeks of treatment was positive, and she was discharged after being oriented to the outpatient follow-up. The patient received 2.8 grams of amphotericin B throughout the treatment period.

## DISCUSSION

The most frequent forms of mucormycosis presentation are sinus (39%), pulmonary (24%), cutaneous (19%), cerebral (9%), gastrointestinal (7%), disseminated (3%), and kidney (2%)<sup>1,4</sup>. Among the several forms, gastrointestinal mucormycosis is rare, and the manifestations vary from the colonization of peptic ulcers to infiltrative disease with vascular invasion and dissemination<sup>2</sup>.

In gastrointestinal involvement, the most frequently compromised organ is the stomach (58%), followed by the colon (32%), small intestine, and esophagus<sup>1-3,5</sup>. The incidence is increasing, and the diagnosis carries a significant mortality rate of up to 85% due to perforation and massive bleeding<sup>1,2,4</sup>.

The symptomatology of gastrointestinal mucormycosis varies from fever, nausea, non-specific abdominal pain, and vomiting to hematemesis, melena, hematochezia, or gastrointestinal perforation<sup>1</sup>. The diagnosis is frequently confirmed



**FIGURE 3:** **A.** Photomicrograph of hematoxylin-eosin staining demonstrating chronic granulomatous and suppurative gastritis; original magnification x 400. **B.** Photomicrograph of Grocott's staining demonstrating hyphae suggestive of zygomyces; original magnification x 400.

histopathologically based on biopsy of the suspected area during surgery or endoscopy<sup>1</sup>. CT can be instrumental in identifying multi-organ involvement.<sup>6</sup> The diagnosis of gastrointestinal mucormycosis can be established based on endoscopic biopsy of the lesions, which show characteristic hyphae<sup>6</sup>.

Successful management of mucormycosis includes aggressive metabolic support, antifungal therapy with amphotericin B or posaconazole, and surgical debridement of all necrosis-involved tissue<sup>2,3</sup>; the length of treatment is individualized, but is often 4-6 weeks long. There remains a need to achieve resolution of symptoms and confirm radiologic findings and negative cultures of the affected site<sup>6</sup>.

## Conflict of interest

The authors declare that there is no conflict of interest.

## REFERENCES

1. Sánchez Velázquez P, Pera M, Gimeno J, Zapatero A, Nolla J, Pera M. Mucormycosis: an unusual cause of gastric perforation and severe bleeding in immunocompetent patients. *Rev Esp Enferm Dig.* 2017;109(3):223-5.
2. Jung JH, Choi HJ, Yoo J, Kang SJ, Lee KY. Emphysematous gastritis associated with invasive gastric mucormycosis: a case report. *J Korean Med Sci.* 2007;22(5):923-7.
3. Kulkarni RV, Thakur SS. Invasive gastric mucormycosis-a case report. *Indian J Surg.* 2015;77(Suppl 1):87-9.
4. Samet JD, Horton KM, Fishman EK. Invasive gastric mucormycosis: CT findings. *Emerg Radiol.* 2008;15(5):349-51.
5. Roden M, Zaoutis T. Epidemiology and outcome of zygomyces: a review of 929 reported cases. *Clin Infect Dis.* 2005;41(5):634-53.
6. Skiada A, Lanternier F, Groll AH, Pagano L, Zimmerli S, Herbrecht R, et al. European Conference on Infections in Leukemia. Diagnosis and treatment of mucormycosis in patients with hematological malignancies: guidelines from the 3<sup>rd</sup> European Conference on Infections in Leukemia (ECIL 3). *Haematologica.* 2013;98(4):492-504.