

Images in Infectious Diseases

Hepatic hydatid cyst ruptured from the transdiaphragmatic path to the pleural cavity

Ramazan Orkun Önder^[1] and Serdar Aslan^[1]

[1]. Giresun University, Faculty of Medicine, Department of Radiology, Giresun, Turkey.

A 40-year-old man was admitted to our emergency department complaining of weakness, pain in the right hemithorax, and shortness of breath. The patient's medical history was unremarkable. Physical examination revealed tenderness in the upper right quadrant on palpation. Laboratory tests showed elevated white blood cells ($16.5 \times 10^9 /L$), aspartate aminotransferase (145 U/L), alanine aminotransferase (163 U/L), direct bilirubin (1.71 mg/dL), and total bilirubin (1.97 mg/dL). Abdominal ultrasonography (US) revealed a CE-3b type cystic lesion in the dome of the liver. Magnetic resonance cholangiopancreatography (MRCP) showed pleural effusion in the right hemithorax and membranous daughter cysts in addition to the findings noted in US (**Figure 1**). Posteroanterior radiography and thoracic computed tomography (CT) revealed consolidation and pleural effusion in the right inferior segment of the lung (**Figure 2**). Thoracic and general surgeons planned to perform surgery for the patient after antibiotic therapy (ceftriaxone 2 g/day and clarithromycin 500 mg/day) and albendazole (800 mg/day) treatment. Hydatid cyst ruptures can be spontaneous, iatrogenic, or traumatic. Ruptured hydatid cysts may present with asymptomatic or anaphylactic reactions. Coughing, dyspnea, fever, hemoptysis, flank pain, chest pain, and secondary pneumonia with pressure to the neighboring bronchi can develop due to pulmonary rupture of the hydatid cyst on the diaphragmatic surface of the liver¹⁻³. Although rare, primary lesions at the dome of the liver can rupture into the lungs through the diaphragmatic route. Atypical forms of the disease should be considered as differential diagnoses in regions with a high prevalence of echinococcosis.

ACKNOWLEDGMENTS

We offer our deepest thanks to the institutions that provided technical support for the development and implementation of this study.

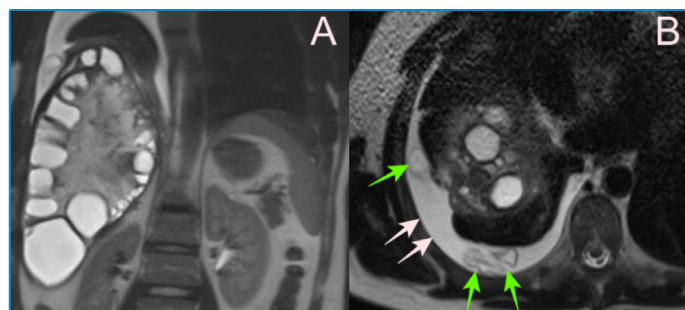


FIGURE 1: CE-3b type (daughter cysts within a solid matrix) cystic lesion in the dome of the liver (A), pleural effusion in the right hemithorax (white arrows) and membranous daughter cysts inside (green arrows) observed on MRCP (B).

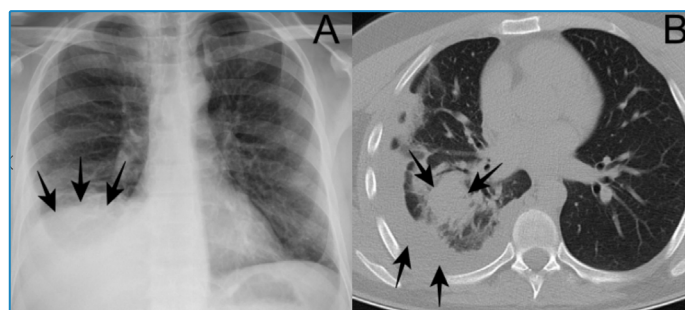


FIGURE 2: Consolidation and pleural effusion in the right inferior segment of the lung as seen on posteroanterior radiograph examination (A) and thorax CT (B).

Corresponding author: Dr. Ramazan Orkun Önder. **e-mail:** orkunonder535@gmail.com

Authors' contribution: ROÖ: Conception and design of the study, Acquisition of data; Conception and design of the study, Analysis and interpretation of data, Final approval of the version to be submitted; SA: Conception and design of the study, Acquisition of data, Drafting the article, Final approval of the version to be submitted, Conception and design of the study, Analysis and interpretation of data.

Conflict of Interest: The author declare that they have no conflict of interest.

Financial Support: No funding was received for this study.

Received 12 December 2022 | **Accepted** 3 January 2023

REFERENCES

1. Hormati A, Alemi F, Eshraghi M, Ghoddoosi M, Mohaddes M, Momeni S. Trans-Diaphragmatic Rupture of Liver Hydatid Cyst in to the Pleural Cavity: A Case Report. Arch Clin Infect Dis. 2020;15(1):e87675. Available from: <https://dx.doi.org/10.5812/archcid.87675>
2. Bulut N, Dagistanlı S. A Case of Ruptured Pulmonary Hydatid Cyst of the Liver and Review of the Literature. Case Reports in Radiology. 2017;2017:7639056. Available from: <https://doi.org/10.1155/2017/7639056>
3. Özdemir A, Bozdemir ŞE, Akbiyik D, Daar G, Korkut S, Korkmaz L, et al. Anaphylaxis due to ruptured pulmonary hydatid cyst in a 13-year-old boy. Asia Pacific Allergy. 2015;5(2):128–31. Available from: <https://doi.org/10.5415/apallergy.2015.5.2.128>