

## Alternative treatment for post-herpetic neuralgia after lung transplantation. Case report\*

*Tratamento alternativo para neuralgia pós-herpética após transplante pulmonar. Relato de caso*

Paulo de Oliveira Vasconcelos Filho, TSA<sup>1</sup>, Fernando Henrique Machado de Carvalho Zylbersztein<sup>1</sup>, Magda Aparecida Santos da Silva<sup>2</sup>, Mara Helena Corso Pereira<sup>3</sup>

\* Received from the Heart Institute (InCor), Clinicas Hospital, School of Medicine, University of São Paulo (HCFMUSP). São Paulo, SP.

### SUMMARY

**BACKGROUND AND OBJECTIVES:** Post-herpetic neuralgia (PHN) is the pain remaining after the resolution of acute herpes zoster episode. This study aimed at reporting a case of PHN pain treatment in lung transplanted patient.

**CASE REPORT:** Male patient, 73 years old, submitted to lung transplantation three years ago and under immunosuppressants. He developed herpes zoster one year ago with vesicles in the eighth intercostal space of the right hemithorax (RHT). Treatment was effective with ganciclovir, however the patient evolved with severe, constant burning pain worsened one month ago with intensity 9 according to the numeric visual scale (NVS), even with 600 mg/day gabapentin. At physical evaluation he presented a hyperesthetic reddish lesion in the RHT. Patient was treated with gabapentin (900 mg), amitriptyline (25 mg), dipirone (8 g) and oxycodone (20 mg) per day. Low intensity laser (LIL) was applied daily for one week, followed by treatment with 4% topic amitriptyline. Pain intensity decreased to 5.

LIL frequency was decreased to once every two days with significant NVS improvement to 1 and 2. He was discharged with 25 mg/day oral amitriptyline and 4% topic amitriptyline.

**CONCLUSION:** LIL and topic amitriptyline were effective for pain remission.

**Keywords:** Amitriptyline, Herpes zoster, Laser beams, Lung transplantation.

### RESUMO

**JUSTIFICATIVA E OBJETIVOS:** A neuralgia pós-herpética (NPH) é a dor que permanece após o desaparecimento do episódio agudo de herpes zoster. O objetivo deste estudo foi relatar o tratamento da dor da NPH em paciente transplantado pulmonar.

**RELATO DO CASO:** Paciente do sexo masculino, 73 anos, transplantado pulmonar há três anos, em uso de imunossuppressores. Desenvolveu quadro de herpes zoster há um ano, com vesículas no oitavo espaço intercostal do hemitórax direito (HTD). O tratamento foi efetivo com ganciclovir; entretanto, o paciente evoluiu com dor em queimação, intensa, constante, com piora no último mês, com intensidade pela escala visual numérica (EVN) de 9, mesmo com uso de 600 mg/dia de gabapentina. Ao exame físico apresentava uma lesão avermelhada no HTD, hiperestésica. Foi instituído tratamento com gabapentina (900 mg), amitriptilina (25 mg), dipirone (8 g) e oxicodona (20 mg) ao dia. Feita a aplicação de laser de baixa intensidade (LBI) diariamente por uma semana, seguido de tratamento com amitriptilina tópica a 4%. A intensidade da dor diminuiu para 5. A frequência de aplicação do LBI diminuiu para uma vez a cada dois dias com melhora significativa com EVN entre 1 e 2. Teve alta hospi-

1. Anesthesiologist of the Pain Group, Heart Institute (InCor), Clinicas Hospital, School of Medicine, University of São Paulo (HCFMUSP). São Paulo, SP, Brazil.

2. Nurse of the Pain Group, Heart Institute (InCor), Clinicas Hospital, School of Medicine, University of São Paulo (HCFMUSP). São Paulo, SP, Brazil.

3. Supervisor of the Pain Group, Heart Institute (InCor), Clinicas Hospital, School of Medicine, University of São Paulo (HCFMUSP). São Paulo, SP, Brazil.

Correspondence to:

Paulo de O. Vasconcelos Filho, M.D.

Rua Estado de Israel, 435/21 Bloco B – Vila Clementino

04022-001 São Paulo, SP.

E-mail: paulo.filho@incor.usp.br

tar, com 25 mg/dia de amitriptilina oral e amitriptilina tópica a 4%.

**CONCLUSÃO:** O uso do LBI e da amitriptilina tópica foi eficaz para remissão do quadro doloroso.

**Descritores:** Amitriptilina, Herpes zoster, Raios laser, Transplante de pulmão.

## INTRODUCTION

The International Association for the Study of Pain (IASP) defines post-herpetic neuralgia (PHN) as pain which remains after the disappearance of vesicles of the acute herpes zoster episode (HZ), after a minimum period of 8 to 12 weeks. There are PHN reports for more than 150 years. During this period, especially in the last 60 years, an extraordinary variety of treatments have appeared to decrease pain during acute HZ phase, to prevent progression to PHN and to decrease pain when the disease is established<sup>1,2</sup>.

HZ is caused by the same virus responsible for varicella, which is the varicella zoster virus (VZV) or human herpes virus type 3 (HHV3). Latent virus reactivation causes the disease. The reactivation cause is unknown and may be related to age group, stress or immunodeficiencies such as tumors, acquired immunodeficiency syndrome (AIDS), autoimmune diseases and the use of immunosuppressive drugs<sup>3,4</sup>.

After the advent of cyclosporin, lung transplantation started to be consolidated as a real therapy for patients with disabling respiratory failure<sup>5</sup>. Cyclosporin leads to immunosuppression and patients are more subject to infections<sup>6</sup>.

This study aimed at reporting the case of a patient who evolved with PHN in the late postoperative period of lung transplantation and had substantial improvement with topical amitriptyline and low intensity laser.

## CASE REPORT

Male patient, 73 years old, diabetic, with clinical, functional, tomographic and pathological diagnosis of idiopathic lung fibrosis (ILF) for six years. Patient progressively evolved with dyspnea at minimum efforts and severe mucoid cough difficult to control. Three years ago he was submitted to left unilateral lung transplantation. He was discharged with immunosuppressive scheme, prednisolone and tacrolimus.

One year ago he developed HZ with the appearance of vesicles in the eight intercostal space of the right hemithorax (RHT). Antiviral treatment with ganciclovir was effective, however patient evolved with PHN.

During the first pain therapy team evaluation patient was clinically well, but with constant burning pain worsened in the last month, with intensity 9 by the visual numerical scale (VNS). Patient was under 600 mg/day gabapentin. He reported sleep changes and high anxiety with regard to the disease. At physical evaluation he presented transplantation scar in left hemithorax and right RHT lesion due to HZ (Figure 1). During lesion evaluation patient complained of hyperesthesia, but not of allodynia.

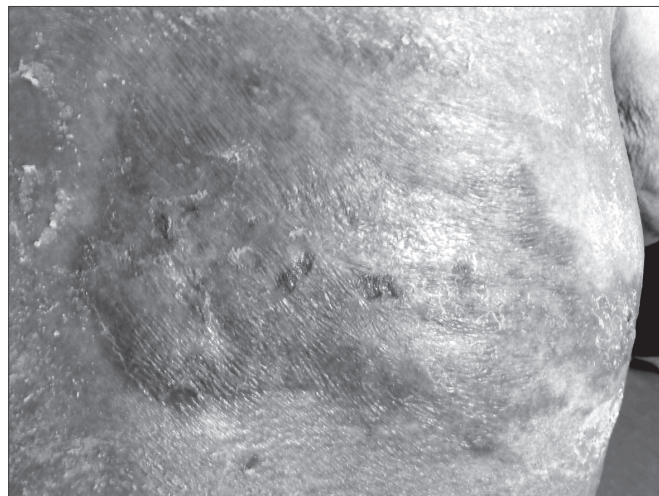


Figure 1 – Chronic herpes zoster lesion

Pain treatment was started with oral gabapentin (900 mg/day), amitriptyline (25 mg/day) and dipirone (8 g/day). Since there was no significant improvement, oxycodone (20 mg/day) was also associated. Patient evolved with postural hypotension, diarrhea and vomiting. Oxycodone was withdrawn and low intensity laser (LIL) application was started with the Twin-Laser<sup>®</sup> (MM-Optics) device, 780 nm/ 40 mW/ 40 Jcm<sup>2</sup>/ 40s per point, in a total of 72 J for 30 minutes, with 10% decrease in pain intensity.

The indication of alcohol injection in the affected nerve was discarded due to technical difficulty and possibility of evolving to deafferentation of the affected nerve<sup>7</sup>.

LIL was applied daily during the first week, in the same intensity. Six days later, 4% topic amitriptyline was started with 30% decrease in pain intensity, with VNS = 5. LIL was then applied every other day with lower potencies varying from 9 to 36 J for 10 to 15 minutes. Oral 600 mg gabapentin, 25 mg amitriptyline and 6 g dipirone per day were maintained.

Patient remained hospitalized for another 15 days having received another 6 LIL applications. There has been significant VNS decrease for 1 to 2 at rest, and 3 to 4 when moving, and gabapentin, amitriptyline and dipi-

rone doses were progressively decreased. At hospital discharge patient had NVS = 1, and was under oral 25 mg/day amitriptyline and 4% topical amitriptyline.

## DISCUSSION

PHN, major HZ complication, has incidence of 10% to 20% and is defined as pain remaining after the disappearance of vesicles of the acute episode, after a minimum period of up to six weeks<sup>8</sup>. In this case, HZ was a consequence of immunosuppression due to lung transplantation due to DLD.

DLF is a chronic disease with progressive evolution to disabling respiratory failure in spite of pharmacological treatment. In this stage, lung transplantation is one treatment option. In the last 15 years, the difference between the number of potential beneficiaries and the number of donors has considerably increased<sup>8</sup>.

After the advent of cyclosporin in the 1980s, lung transplantation started to be consolidated as therapy<sup>9</sup>. Cyclosporin A (CsA) was an immunosuppressive revolutionizing organ transplantations, however, problems associated to dosage came to light. The drug had little and imprecise absorption, narrow therapeutic window and adverse effects. With the availability of other drugs, such as tacrolimus (FK506) and sirolimus, there was a therapeutic control enhancement with serum dosage of immunosuppressives. CsA and FK506, calcineurin inhibitors, are the basis of clinical immunosuppression. They have toxic effects such as dose-related nephrotoxicity<sup>10</sup>.

Studies showing the efficacy of existing treatments for PHN have classified analgesics as first line drugs, together with tricyclic antidepressants, anticonvulsants and lidocaine patch with proven efficacy; and as second line drugs, where opioids were included. Neural blocks may also be considered a potential treatment<sup>11,12</sup>.

In our case, systemic oral or venous administration of analgesics and adjuvants did not change PHN pain profile and was a complicating factor since patient took a large amount of drugs. LIL and topical amitriptyline were decisive for pain remission.

LIL has been used for decades in Europe to treat chronic pains, especially in body regions with soft tissues. Its action mechanism is not totally clear but it seems to be related to microcirculation and inflammatory response improvement and to adenosine triphosphate (ATP) production. In addition, it is believed that laser therapy increases serotonin production. Laboratory essays have shown higher urinary excretion of serotonin byproducts

after treatment. A study has shown that after 4 weeks of LIL, as compared to placebo, there has been significant pain improvement at rest and during activities, as well as pain threshold increase. LIL has the advantage of not being invasive and of being well tolerated by elderly and high-risk patients<sup>13</sup>.

Amitriptyline, a tricyclic antidepressant (TAD), is used as analgesic adjuvant to treat chronic and neuropathic pain in humans. It is orally administered and induces analgesia by acting in spinal cord and supraspinal structures. Recent pre-clinical trials have shown that topical TAD induces analgesia. In formalin models of neuropathic pain and skin reflex in rats, local amitriptyline has induced analgesia. Studies have shown that topical doxepin, as compared to placebo, has induced effective analgesia. Although these drugs may be promising as topical analgesics, peripheral TAD action mechanism is still not well understood<sup>14,15</sup>.

This case presents an alternative treatment for chronic neuropathic pain patients. During the 10 days from admission until pain control, patient was in great distress, which was relatively easily controlled with LIL and topical amitriptyline.

## CONCLUSION

LIL and topical amitriptyline were effective for pain remission.

## REFERENCES

1. Gnann JW Jr, Whitley RJ. Clinical practice. Herpes zoster. *N Engl J Med* 2002;347(5):340-6.
2. Gilden DH, Kleinschmidt-DeMasters BK, LaGuardia JJ, et al. Neurologic complications of the reactivation of varicella-zoster virus. *N Engl J Med* 2000;342(9):635-45.
3. Dworkin RH, Portenoy RK. Pain and its persistence in herpes zoster. *Pain* 1996;67(2-3):241-51.
4. Truini A, Galeotti F, Haanpaa M, et al. Pathophysiology of pain in postherpetic neuralgia: a clinical and neurophysiological study. *Pain* 2008;140(3):405-10.
5. Jatene FB, Pêgo-Fernandes PM. Challenges in lung transplantation. *J Bras Pneumol* 2008;34(5):249-50.
6. Espinosa M, Rodil R, Goikoetxea MJ, et al. Transplante pulmonar. *An Sist Sanit Navar* 2006;29(2):105-12.
7. Fardy MJ, Patton DW. Complications associated with peripheral alcohol injections in the management of trigeminal neuralgia. *Br J Oral Maxillofac Surg* 1994;32(6):387-91.

8. Schmader K. Herpes zoster and postherpetic neuralgia in older adults. *Clin Geriatr Med* 2007;23(3):615-32.
9. Rufino R, Madi K, Mourad O, et al. Accelerated form of interstitial pulmonary fibrosis in the native lung after single lung transplantation. *J Bras Pneumol* 2007;33(6):733-7.
10. Garcia SC, Lopes LS, Schott KL, et al. Ciclosporina A e tacrolimus: uma revisão. *J Bras Patol Med Lab* 2004;40(6):393-401.
11. Tyring SK. Management of herpes zoster and postherpetic neuralgia. *J Am Acad Dermatol* 2007;57(6):S136-42.
12. Dworkin RH, Backonja M, Rowbotham MC, et al. Advances in neuropathic pain. diagnosis, mechanisms, and treatment recommendations. *Arch Neurol* 2003;60(11):1524-34.
13. Bjordal JM, Johnson MI, Iversen V, et al. Photoradiation in acute pain: a systematic review of possible mechanisms of action and clinical effects in randomized placebo-controlled trials. *Photomed Laser Surg* 2006;24(2):158-68.
14. Lynch ME, Clark AJ, Sawynok J, et al. Topical 2% amitriptyline and 1% ketamine in neuropathic pain syndromes: a randomized, double-blind, placebo-controlled trial. *Anesthesiology* 2005;103(1):140-6.
15. Oatway M, Reid A, Sawynok J. Peripheral antihyperalgesic and analgesic actions of ketamine and amitriptyline in a model of mild thermal injury in the rat. *Anesth Analg* 2003;97(1):168-73.

Submitted in December 24, 2010.

Accepted for publication in February 16, 2012.