

# ENDOVASCULAR TREATMENT OF CAROTID ARTERY STENOSIS

## Retrospective study of 79 patients treated with stenting and angioplasty with and without cerebral protection devices

*Eduardo Noda Kihara<sup>1</sup>, Mario Sergio Duarte Andrioli<sup>1</sup>, Eliova Zukerman<sup>2</sup>, Mario Fernando Prieto Peres<sup>2</sup>, Pedro Paulo Porto Júnior<sup>2</sup>, Paulo Hélio Monzillo<sup>2</sup>, Ivan Hideyo Okamoto<sup>2</sup>, Ayrton Roberto Massaro<sup>2</sup>, José Carlos Zirretta<sup>3</sup>.*

**ABSTRACT** - We evaluate the results of stenting and angioplasty on carotid bifurcation stenotic lesions using protection systems, emphasizing the indications and technical aspects. Seventy-nine patients, mean age 64.5 years were treated from February, 1998 to March, 2003. All patients were included in NASCET study criteria. Forty three patients were treated without the protection systems and thirty six were treated with carotid protection filtering system (Angioguard, EPI). Technical success and 6-months carotid Doppler ultrasound follow-up showing stent patency were achieved in all patients. One major stroke and one death due to intracranial reperfusion bleeding occurred in patients treated without cerebral protection devices. Only one patient presenting hyper perfusion syndrome improving after 7 days, was found in the group treated with the cerebral protection filter mechanism, no other neurologic symptom or death occurred in this group. Stenting and angioplasty with protection systems for thromboembolic debris is a safe endovascular method to treat stenotic lesions in the carotid bifurcation with low morbidity and mortality.

**KEY WORDS:** carotid artery stent, carotid artery atherosclerosis, endovascular therapy.

### **Tratamento endovascular das lesões estenóticas em bifurcação carotídea: estudo retrospectivo de 79 pacientes tratados por "stent" e angioplastia com e sem mecanismos de proteção cerebral**

**RESUMO** - Este estudo mostra a experiência e resultados da terapêutica endovascular nas lesões estenóticas em bifurcação carotídea. Entre fevereiro de 1998 e março de 2003 foram tratados 79 pacientes com idades entre 57 e 72 anos (média 64,5 anos) sendo 45 do masculino e 34 do feminino. Todos os pacientes enquadravam-se nos critérios do estudo "NASCET" com comprometimento das artérias carótidas internas. Dos 79 pacientes, 43 foram tratados sem os sistemas de proteção e 36 pacientes foram tratados com sistema de proteção. Dos 36 pacientes tratados com sistema de proteção foram utilizados filtros de proteção (Angioguard e EPI). Observou-se melhora angiográfica em todos os 79 pacientes tratados. Ultrassom Doppler realizado após 6 meses mostrou artérias périas em todos os pacientes. Nos 43 pacientes tratados por "stent"/angioplastia sem a utilização de sistemas de proteção tivemos um paciente com déficit neurológico que perdeu por mais de 30 dias ("stroke major") e um óbito por transformação hemorrágica devido à reperfusão. Ocorreu síndrome de hiperperusão em 1 paciente dos 36 pacientes tratados com o sistema de proteção, regredindo em 7 dias, sendo que nos demais não houve morbi-mortalidade. A angioplastia e "stent" no território carotídeo com a utilização de sistema de proteção é um método seguro com reduzida morbidade e mortalidade estando indicada nas lesões estenóticas das bifurcações carotídeas.

**PALAVRAS-CHAVE:** stent artéria carotídea, aterosclerose carotídea, terapêutica endovascular.

Stroke is one of the leading causes of death worldwide. More than 500 000 new strokes occur annually in the United States, and it has been estimated that

carotid artery disease may be responsible for 20% to 30% of them<sup>1</sup>. The annual stroke event rate for asymptomatic patients with hemodynamically sig-

<sup>1</sup>Médico do Serviço de Neuroradiologia Intervencionista do Hospital Israelita Albert Einstein, São Paulo SP, Brazil (HIAE); <sup>2</sup>Médico Neurologista HIAE; <sup>3</sup>Médico Universidade Estadual do Rio de Janeiro, Rio de Janeiro RJ, Brazil.

Received 31 March 2004. Accepted 16 July 2004.

Dr. Eduardo Noda Kihara - Serviço de Neuroradiologia Intervencionista - Avenida Albert Einstein 627/4º andar - 05651-901 São Paulo SP - Brasil. E-mail: kihara@einstein.br

nificant carotid artery stenosis ranges from 2% to 5%<sup>2</sup>. Carotid artery stenosis usually is identified after transient ischemic attack (TIA), but for many patients, cerebral infarction caused by artery-to-artery embolism or carotid occlusion is the initial event. Progression of asymptomatic carotid artery stenosis to occlusion is unpredictable and can be disastrous; at the time of occlusion, disabling stroke may occur in 20% of patients, and thereafter in 1.5% to 5% annually<sup>3</sup>. The North American Symptomatic Carotid Endarterectomy Trial<sup>4</sup> (NASCET), showed beneficial effect of carotid endarterectomy in symptomatic patients with high-grade carotid stenosis (70 - 99%). The cumulative risk of any ipsilateral stroke at two years were 26 percent in the 331 medical patients and 9 percent in the 328 surgical patients an absolute risk reduction of 17 %. For a major or fatal ipsilateral stroke, the corresponding estimates were 13.1% versus 2.5 %, an absolute risk reduction of 10.6%<sup>4</sup>. No beneficial has been found in less than 50% stenosis<sup>5</sup>. Since then, carotid endarterectomy (CEA) has been one of the most commonly performed peripheral vascular procedures and has been considered the most effective treatment for stroke prevention in patients with high-grade symptomatic or asymptomatic carotid artery disease (CAD)<sup>6,7</sup>.

In the past few years carotid angioplasty and stenting (CAS) has been proposed as an alternative endovascular treatment<sup>8,9</sup>. Despite an increasing enthusiasm for the application of CAS in the treatment of CAD and an abundant literature on case series of CAS, only three studies have been published

to date, which directly compare CEA with CAS<sup>10-12</sup>. In CAVATAS, the first completed, prospective multi-center trial comparing endovascular versus surgical treatment for CAD, a similar major risk and effectiveness for CAS compared with carotid surgery has recently been reported<sup>10</sup>.

Percutaneous carotid stenting is accomplished with an increased incidence of microemboli, as shown by transcranial Doppler monitoring<sup>13</sup>. These emboli are associated with a higher neurological complication rate and are also recognized as a potential cause of periprocedural stroke during endarterectomy<sup>14</sup>.

Cerebral protection with filter devices during carotid artery stenting has been recently shown better results<sup>15-19</sup>.

Multiple cerebral protection systems are available, from occlusion balloon protection techniques to filter devices placed above the lesion. The occlusion balloon system is advanced across the area of stenosis, with a small caliber guidewire, angioplasty is performed with the occlusion balloon inflated. The angioplasty catheter (with its balloon deflated) is advanced just proximal to the occlusion balloon. Angioplasty debris is then flushed into the external carotid circulation, with the occlusion balloon deflated, avoiding the fragments from reaching the distal circulation<sup>15-17</sup>. The filter protection mechanism allows red blood cells flow, blocking only higher than 100 micra particles. Stenotic lesions can be treated even if severe contralateral disease is present<sup>18,19</sup>.

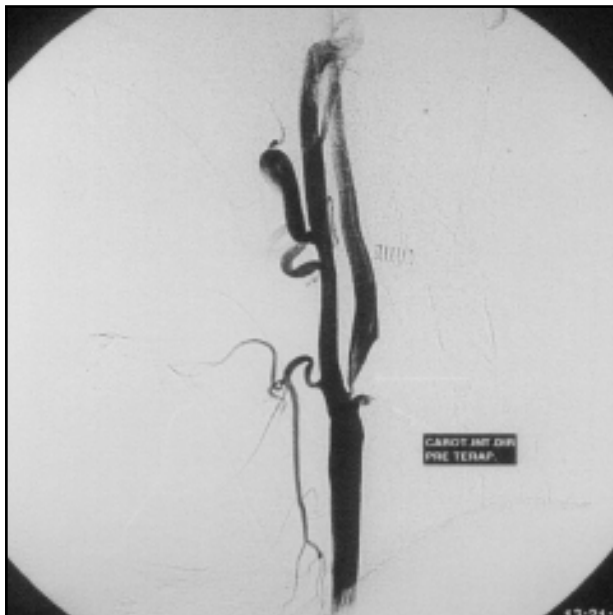

Fig 1. Ulcerated plaque with pre-operative stenosis.

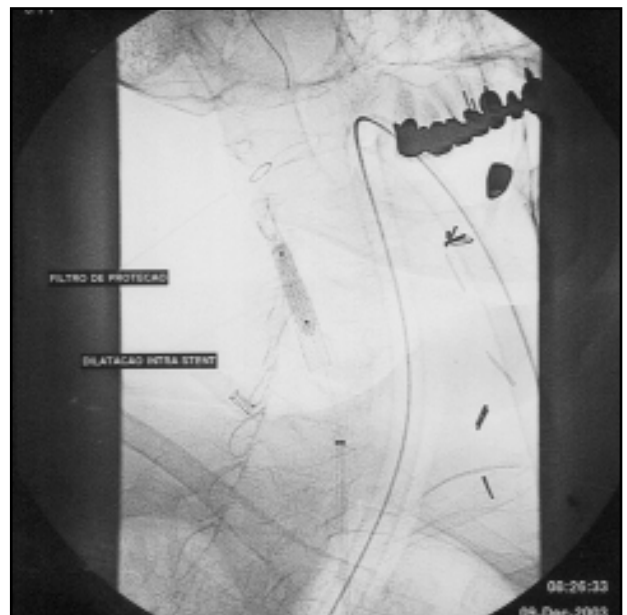


Fig 2. Insuflated baloom intra-stent and protection filter.

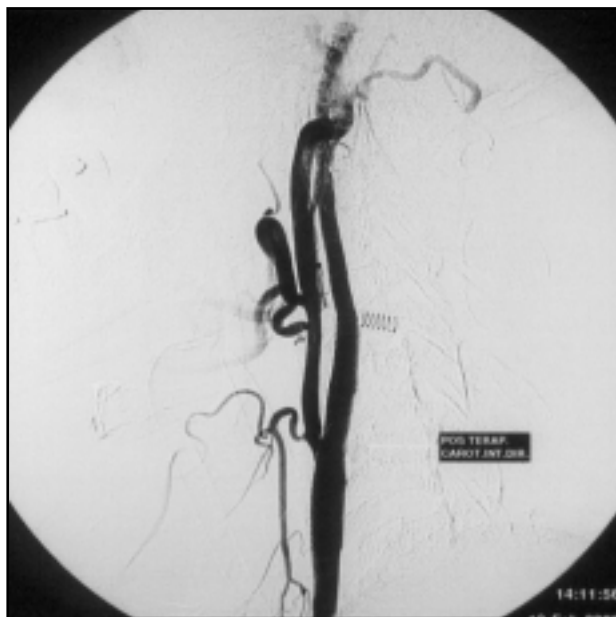

Fig 3. Internal carotid artery after endovascular therapy.

This study objective is to describe our experience in the percutaneous endovascular treatment of internal carotid artery stenosis with angioplasty and stenting with and without cerebral protection devices.

#### METHOD

Seventy nine patients were treated, 49 men, 30 women. Age ranged from 57 to 72 years (mean 64.5). Sixty three patients were symptomatic with higher than 60% stenosis and sixteen asymptomatic patients with higher than 80% stenosis were treated, 43 patients were treated without protection mechanisms, from February, 1998 to July, 2001. After August, 2001, all the procedures were performed with the angioguard or EPI filter<sup>16,17</sup>.

All patients had clinical, neurological, laboratory and neuroimaging evaluation previously to the procedure. Antiplatelet aggregation therapy was started at least 72 hours before it. Local anesthesia at the femoral artery, sedation and anticoagulation with heparin were done during the procedure. Atropine sulfate was administered intravenously in order to avoid any abnormal vagal response after carotid sinus stimulation during the stenting and angioplasty. Angiography was done to assess the intracranial circulation. Under fluoroscopy (roadmap) the protection system was introduced throughout the stenotic lesion, avoiding traumas and false trajectory to the artery wall. In severe stenosis, a pre-dilatation with low profile balloon was done.

After opening the filter device above the lesion, stenting implantation was performed. The balloon was inflated at the stenotic atherome plaque level, decreasing its stenosis after deflation. During the procedure, the protection device was kept open for an eventual emboli

trapping. A completion angiogram was then obtained, for a comparison to previous images. Mechanical reperfusion or thrombolysis were available if necessary. Patients were continuously monitored at the intensive care unit for the first 48 hours. Antiplatelet therapy was prescribed. Tirofiban, a glycoprotein IIa-IIIb blocker was used in severe cases (irregular lesions, smoking patients). In one patient with post-surgical restenosis Abciximab was utilized (19). Carotid Doppler ultrasound follow-up was obtained until 6 months after procedure.

#### RESULTS

Complete stenosis restoration was obtained in all 79 patients treated. In the initial group (43 patients) treated without the protection system, one stroke occurred 24 hours after treatment, and one patient died due to cerebral haemorrhage. In the subsequent 36 patients treated with the filter device, only one patient with severe stenosis presented with hyperfusion syndrome, discharged 9 days after the procedure. No major neurological deficits happened in the patients treated with the filter device.

Carotid sinus vagal reaction occurred in 5 patients after the first 12 hours, the patients were treated with atropine. At the 6-months carotid Doppler follow-up no restenosis were found. Six patients had 12-months angiography follow-up without intraluminal changes (Figs 1, 2, and 3).

#### DISCUSSION

We observed in our case series a trend to less complications in patients treated with the cerebral protection with the filter device, however a definite answer for the true difference in efficacy and complications after percutaneous treatment versus endarterectomy has yet to be determined. Ongoing trials such as the Sapphire and Archer trials will help clarify the issue. The CREST study is following 2500 patients treated with endarterectomy or angioplasty and stenting of moderate to severe carotid stenosis patients<sup>20</sup>.

Other multicenter worldwide study enrolled 6327 patients treated with angioplasty and stenting without cerebral protection devices, showed a technical success in 98.4% of cases. Ischaemic strokes occurred in 2.7%, those with neurological deficits lasting more than 30 days in 1.3%, mortality rate was 0.7%. Restenosis rate in 12-months follow-up was 5.56%.<sup>21</sup> A recent study of 2038 patients treated with angioplasty and stenting with cerebral protection devices showed a significant reduction in strokes and mortality rates<sup>21</sup>.

In conclusion, percutaneous stenting and angioplasty with cerebral protection devices for carotid stenotic lesions, in symptomatic with higher than 60% stenosis and asymptomatic patients with higher than 80% stenosis, is a safe and efficient method of treatment with low morbidity and mortality. Carotid protection devices allowed maintenance of cerebral blood flow during the procedure reducing thrombo embolic complications and morbidity rates.

## REFERENCES

1. Timsit SG, Sacco RL, Mohr JP, et al. Early clinical differentiation of cerebral infarction from severe atherosclerotic stenosis and cardioembolism. *Stroke* 1992;23:486-491.
2. Executive Committee for the Asymptomatic Carotid Atherosclerosis Study. Endarterectomy for Asymptomatic Carotid Artery Stenosis. *JAMA* 1995;273:1421-1428.
3. Moore W. Guidelines for carotid endarterectomy: a multidisciplinary consensus statement from the Ad Hoc Committee, American Heart Association. *Stroke* 1995;26:188-201.
4. North American Symptomatic Carotid Endarterectomy Trial Collaborators. Beneficial effect of carotid endarterectomy in symptomatic patients with high-grade carotid stenosis. *N Engl J Med*, 1991;325:445-447.
5. Kastrup A, Skalej M, Krapf H, Nagele T, Dichgans J, Schulz JB. Early outcome of carotid angioplasty and stenting versus carotid endarterectomy in a single academic center. *Cerebrovascular Dis.* 2003;15:84-89.
6. Clinical advisory. Carotid endarterectomy for patients with asymptomatic internal carotid artery stenosis. *Stroke* 1994;25:2523-2524.
7. Randomised trial of endarterectomy for recently symptomatic carotid stenosis: final results of the MRC European Carotid Surgery Trial (ECST). *Lancet* 1998;351:1379-1387.
8. Theron JG, Payelle GG, Coskun O. Carotid artery stenosis; treatment with protected balloon angioplasty and stent placement. *Radiology* 1996;201:627-636.
9. Albuquerque FC, Teitelbaum GP, Lavine SD. Balloon-protected carotid angioplasty. *Neurosurgery* 2000;46:918-921.
10. Endovascular versus surgical treatment in patients with carotid stenosis in the Carotid and Vertebral Transluminal Angioplasty Study (CAVATAS): a randomised trial. *Lancet* 2001;357:1729-1737.
11. Naylor AR, Bolia A, Abbott RJ, et al. Randomized study of carotid angioplasty and stenting versus carotid endarterectomy: a stopped trial. *J Vasc Surg* 1998;28:326-334.
12. Jordan WD, Schroeder PT, Fisher WS, McDowell HA. A comparison of angioplasty with stenting versus endarterectomy for the treatment of carotid artery stenosis. *Ann Vasc Surg* 1997;11:2-8.
13. Jordan WD, Voellinger DC, Doblar DD, Plyushcheva NP, Fisher WS, McDowell HA. Microemboli detected by transcranial Doppler monitoring in patients during carotid angioplasty versus carotid endarterectomy. *Cardiovasc Surg* 1999;7:33-38.
14. Markus HS, Clifton A, Buckenham T, Brown MM. Carotid angioplasty: detection of embolic signals during and after the procedure. *Stroke* 1994;25:2403-2406.
15. Henry M, Amor M, Henry I. Carotid stenting with cerebral protection: first clinical experience using the Percusurge Guardwire system. *J Endovasc Surg* 1999;6:321-331.
16. Reimers B, Corvaja N, Moshiri S. Cerebral protection with filter devices during carotid artery stenting. *Circulation* 2001;104:12-15.
17. Dietz A, Berkefeld J, Theron JG. Endovascular treatment of symptomatic carotid stenosis using stent placement. *Stroke* 2001;32:1855-1859.
18. Roubin SG, New G, Iyer SS. Immediate and late clinical outcomes of carotid artery stenting in patients with symptomatic and asymptomatic carotid artery stenosis: a 5-year prospective analysis. *Circulation* 2001;103:532-537.
19. Ohki T, Roubin GS, Veith FG. Efficacy of a filter device in the prevention of embolic events during carotid angioplasty and stenting: an ex vivo analysis. *J Vasc Surg* 1999;30:1034-1044.
20. Hobson RW 2nd. CREST (Carotid Revascularization Endarterectomy versus Stent Trial): background, design, and current status. *Semin Vasc Surg* 2000;13:139-143.
21. Wholey MH, Wholey M. Current status in cervical carotid artery stent placement. *J Cardiovasc Surg (Torino)*. 2003;44:331-339.