

# Evaluation of preoperative data and post-operative results of phacotrabeculectomy in minimum five-year follow-up

## *Avaliação dos dados pré e resultados pós operatórios de facotrabeulectomia em seguimento mínimo de cinco anos*

Vitor Luna de Sampaio<sup>1</sup> <https://orcid.org/0000-0003-4593-8206>  
Maria Taianny Gonçalves de Sá<sup>2</sup> <http://orcid.org/0000-0002-1867-1043>  
Carlos Teixeira Brandt<sup>3</sup> <http://orcid.org/0000-0003-0701-386X>

### ABSTRACT

**Objective:** To evaluate the results of phacotrabeculectomy in a follow-up of five years or more. **Methods:** Retrospective, interventional and analytical study that was carried out in the surgical center of clínica de olhos do Juazeiro with patients operated on from 2006 to 2013. 34 eyes of 29 patients with senile cataract and primary open-angle glaucoma, who underwent phacotrabeculectomy were involved in the investigation. A risk score for glaucomatous damage ranging from 0 to 5 when evaluating intraocular pressure, excavation of the optic disc, number of hypotensive drugs used to treat glaucoma and the patient's age in years. The sample was of convenience and paired. The paired Wilcoxon test was used to verify differences between means.  $P < 0.05$  was accepted for the rejection of the null hypothesis. The study was approved by the ethics committee of the Brazil platform and follows the principles of resolution 466 of the National Health Council. **Results:** The mean visual acuity was significantly higher after a five-year follow-up (preoperative average 0.42 +/- 0.23 versus postoperative average 0.62 +/- 0.29 -  $p = 0.0031$ ). The average risk score for glaucomatous damage after five years of follow-up was significantly lower when compared to the preoperative (preoperative mean: 9.47 +/- 1.61 versus postoperative mean 6.55 +/- 2, 21)  $p < 0.0001$ , considered extremely significant. **Conclusion:** Phacotrabeculectomy was significantly effective in improving visual acuity and reducing the risk of glaucomatous damage after a five-year postoperative follow-up.

**Keywords:** Senile cataract; Primary open-angle glaucoma; Phacoemulsification. Trabeculectomy; Results assessment

### RESUMO

**Objetivo:** Avaliar os resultados da facotrabeulectomia em seguimento igual ou superior a 5 anos. **Métodos:** Estudo retrospectivo, de intervenção e analítico realizado no centro cirúrgico da clínica de olhos de Juazeiro do Norte com pacientes operados no período de 2006 a 2013. Foram envolvidos na investigação 34 olhos de 29 pacientes com catarata senil e glaucoma primário de ângulo aberto submetidos à facotrabeulectomia. Foi criado um escore de risco de dano glaucomatoso variando de 0 a 5 ao avaliar pressão intraocular, escavação do disco óptico, número de drogas hipotensoras utilizadas para o tratamento do glaucoma e a idade do paciente em anos. A amostra foi de conveniência e pareada. Foi utilizado o teste de Wilcoxon pareado para a verificação de diferenças entre médias. Foi aceito  $p < 0,05$  para a rejeição da hipótese de nulidade. O estudo foi aprovado pelo comitê de ética da plataforma Brasil e segue a resolução 466 do Conselho Nacional de Saúde. **Resultados:** A média da acuidade visual foi significativamente maior após o seguimento de 5 anos (média pré-operatória 0,42 +/- 0,23 versus média pós-operatória 0,62 +/- 0,29 -  $p = 0,0031$ ). A média dos escores de risco para dano glaucomatoso após 5 anos de seguimento foi significativamente menor quando comparado ao pré-operatório (média pré-operatória: 9,47 +/- 1,61 versus média pós-operatória 6,55 +/- 2,21)  $p < 0,0001$ , considerado extremamente significativo. **Conclusão:** A facotrabeulectomia foi significativamente efetiva na melhora da acuidade visual e na redução do risco de dano glaucomatoso após seguimento pós-operatório igual ou superior a 5 anos.

**Descritores:** Catarata senil; Glaucoma primário de ângulo aberto; Facoemulsificação; Trabeculectomia; Avaliação de resultados

<sup>1</sup>Juazeiro do Norte Estácio Medical School, Juazeiro do Norte City, Ceará State, Brazil.

<sup>2</sup>Doctor of the Family Health Program, Abaré City, Bahia State, Brazil.

<sup>3</sup>Pernambuco Federal University, Recife City, PE, Brazil.

The research was carried out at Cariri Eye Clinic, Juazeiro do Norte City, Ceará State, Brazil

The authors declare no conflict of interest

Received for publication 31/5/2020 - Accepted for publication 29/9/2020

## INTRODUCTION

Cataract is defined as any opacity in the lens; glaucoma, in its turn, is an acquired optic neuropathy that can raise intraocular pressure (IOP) and cause important eye repercussions, such as thinning of the retinal nerve fiber layer, increased optic disc excavation, and loss of visual field. Glaucoma can be a risk factor for cataracts assumingly induced by hypotensive treatments and IOP reduction in glaucoma patients. Thus, these diseases often happen simultaneously in elderly patients.<sup>(1-3)</sup>

According to World Health Organization (WHO), cataract-incidence rate reaches 0.3% in a yearly basis. This number would add up to 500,000 new cataract cases every year, in Brazil.<sup>(4)</sup> Back in 2009, WHO estimated 70 million people with glaucoma by 2013, and this number corresponds to 2% - 3% of the world population. Glaucoma would also be the cause of bilateral blindness in 10% of this population. The number of people with glaucoma was expected to rise to 80 million in 2020.<sup>(5)</sup>

The combination of cataract and glaucoma surgery (FACOTREC) leads to greater IOP control without the use of hypotensive medications than other procedures, given its smaller incision, lesser inflammatory reaction and greater filtering bleb function.<sup>(6)</sup>

Few researches assess phacotrabeculectomy results from the first postoperative week until the last result - more than five years after the procedure. This result is of paramount importance in order to understand morbidities and erroneous behaviors that can influence filtering bleb maintenance.<sup>(7,8)</sup>

The current research aimed at assessing preoperative data and at comparing it to results of combined cataract and glaucoma surgery performed in a private ophthalmology service between 2006 and 2013. It was done to investigate the number of ocular hypotensive drugs, visual acuity, the spherical refractive equivalent and optic nerve excavation.

Therefore, it is necessary to assess what were the ocular results 5 years after surgery, at least, in patients subjected to FACOTREC from 2006 to 2013 in a private clinic in Juazeiro do Norte City, Ceará State/Brazil.

## METHODS

Retrospective, interventional and analytical study, carried out in a single surgical center at Juazeiro do Norte Eye Clinic between 2006 and 2013. The current study was approved by Plataforma Brasil Ethics Committee since it is in compliance with principles of the Declaration of Helsinki. The free consent form was signed by each patient participating in the experiment (CAAE n. 07152818.0.0000.8074).

Patients were followed-up in the Glaucoma Department of Juazeiro do Norte Eye Clinic. Primary open-angle glaucoma (POAG) diagnosis was based on clinical criteria (elevated intraocular pressure and/or suggestive changes in the optic nerve), changes in the visual field, and/or on the retinal nerve fiber layer. All patients underwent gonioscopy, which showed open angle of Shaffer classification greater than, or equals, to 3 (in all quadrants), without synechiae or large pigmentation in the anterior chamber - which is suggestive of secondary or narrow-angle glaucoma.

Patients were using one, two, three, and even four hypotensive eye drugs at the time of surgery. Eye pressure control with medication (target IOP of <21mmHg - value in which changes in

glaucomatous nerve damage progression is assumingly less likely to occur). Patients who had secondary glaucoma, or who had undergone another previous surgical treatment, or laser iridectomy, or, yet, laser trabeculectomy, were excluded from the study.

FACOTREC was recommended for the assessed patients due to low vision caused by cataracts and glaucoma progression risk. All surgeries were performed by the same surgeon and followed the same technique. After peribulbar anesthesia, conjunctival peritomy was performed after subconjunctival injection of 0.1 ml of the solution with 0.04% mitomycin C (MMC) diluted in 2% lidocaine with vasoconstrictor (1:4); cauterization of the scleral bed, with conjunctival flap based on fornix to make rectangular scleral flap; 1mm paracentesis in the clear cornea; 2.75mm incision in a single site, Healon EndoCoat (Jonhson Jonhson Laboratory, USA); manual capsulorhexis anterior performed with phacoemulsification with the aid of stop-and-shop device (Sovering Compact, AMO); intraocular lens implantation in the Sensar ONE AAB00 acrylic lens posterior chamber (ANVISA registration: 80147060143); 0.8mm trabeculectomy, followed by peripheral iridectomy with Vannas scissors; aspiration of the viscoelastic substance; suture of the scleral flap with two stitches with Nylon 10.0 thread; and cornea-conjunctival suture with the same thread (three or four separated stitches).

Patients stopped taking ocular hypotensive drugs in the postoperative period, and started a fixed association of moxifloxacin and dexamethasone (Vigadexa®), one drop every 6 hours, once a day, for seven days; 1% atropine eye drops (Atropina®), one drop every 12 hours for 15 days; and prednisolone 1mg (Predfort®), one drop every hour for 3 days, followed by subsequent weaning (the daily dose was reduced to eight, six, four, three, twice and once a day, every 10 days, until completing 63-day postoperative time - from that day on, the patient no longer used this medication). The next visit was scheduled based on increased frequency, in the first weeks, at each postoperative visit.

Epidemiological data, such as preoperative features (preoperative IOP, gonioscopy, central pachymetry, number of hypotensive drugs, best-corrected visual acuity, visual field analysis, intraocular lens calculation) were assessed before the surgery. Preoperative eye pressure was defined by the average of the last three measurements taken before surgery, which were obtained with the aid of Goldmann applantation tonometer (GAT) (Haig-Streit, Switzerland).

An estimated glaucoma progression risk score (ERPG) was created by using the following variables: age, number of hypotensive drugs used, optic disc excavation size and ocular pressure values, according to the following score: AGE: aged less than 60 years old - 3 points, aged 60 to 69 years old - 2 points, aged 70 years old or more - 1 point; NUMBER OF HYPOTENSIVE DRUGS: no drugs - 0 points, one drug - 1 point, two drugs - 2 points, three drugs - 3 points and four drugs - 4 points; OPTIC NERVE EXCAVATION: less than, or equals, to 0.8 - 2 points, 0.9 - 4 points and excavation 1.0 (total) - 5 points; IOP: less than, or equals to, 14mmHg - 0 point, between 15 and 20 mmHg - 1 point, greater than 20 to 25mmHg - 2 points and above 25mmHg - 3 points. The ERPG score is calculated by summing of the points found for the aforementioned variables, before surgery, and 5 years or more after surgery, in the assessed patient last evaluation (appointment). Wilcoxon paired test for unpaired samples and the GraphPad InStat software were used for result analyses and  $p < 0.05$  was accepted for the rejection of the null hypothesis.

**Table 1**  
**Demographic and preoperative features**

Features	POAG (n=34)
Age (years)	66,3±9.6
Sex	
Men (%)	27.6
Women (%)	72.4
IOP (mmHg)	18.1±8.1
Drugs (quantity)	2.6±0.9
AVL (decimal)	0.4±0.2
Spherical equivalent (diopter)	2.7±2.5
Astigmatism (diopter)	1.3±2.5
Optic disc excavation	0.6±0.3

**Table 2**  
**Postoperative features**

Features	POAG (n=34)
Age (years)	74.0±9.3
IOP (mmHg)	13.2±3
Drugs (quantity)	0.9±1.1
AVL (decimal)	0.6±0.3
Spherical equivalent (diopter)	0.9±0.8
Astigmatism (diopter)	1.2±1
Optic disc excavation	0.7±0.3

**RESULTS**

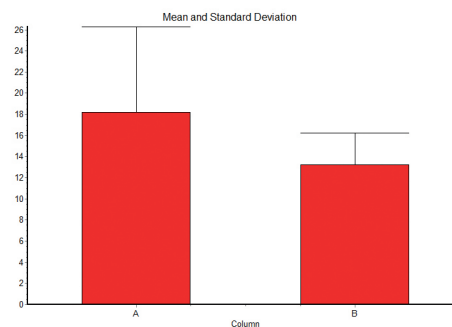
Thirty-four eyes from twenty-nine patients diagnosed with senile cataracts and POAG were included in the study. Men accounted for eight patients (27.6%), and women for 21 patients (72.4%). Mean age was 66.3 ± 9.6 years. Mean preoperative IOP was 18.1±8.1mmHg, and mean use of antiglaucoma drugs was 2.6±0.9. Table 1 shows the epidemiological data.

Mean IOP was 13.2±3mmHg, After a minimum period of 5 years after phacotrabeculectomy surgery, when 0.9±1.1 of drugs was used. (Table 2). Therefore, mean IOP and the administered drugs significantly decreased 5 years after surgery (Figures 1 and 2). The difference between mean best visual acuity and standard deviation (compared before and after phacotrabeculectomy) was significantly better 5 years after the surgical procedure (Figure 3).

Patients were followed up on postoperative outpatient appointments until discharge, after surgery. The end of the late postoperative state was defined at this time, this period-of-time ranged from 38 to 99 days (67 days, on average). The number of postoperative appointments ranged from 4 to 17 (8 postoperative appointments, on average). Patients in the current study were followed up from least 60 months up to 108 months, at most, (80 postoperative months, on average). At this time, their condition before phacotrabeculectomy using MMC was compared to scores before it.

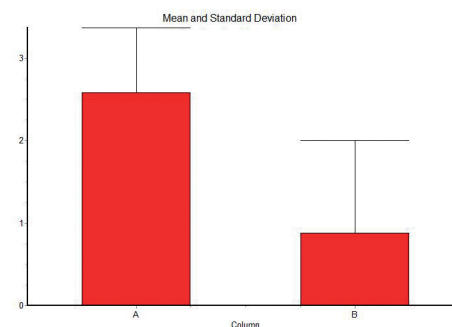
Interventions in the postoperative follow-up were made to maintain aqueous humor flow based on trabeculectomy, such as compressive massage of the eyelid, lysis of conjunctival flap sutures with diode laser using and Blumenthal lens (Volk®), were performed when necessary.

Aqueous humor oozing (positive Seidel sign) was the most frequent complication - reparative suture was immediately con-



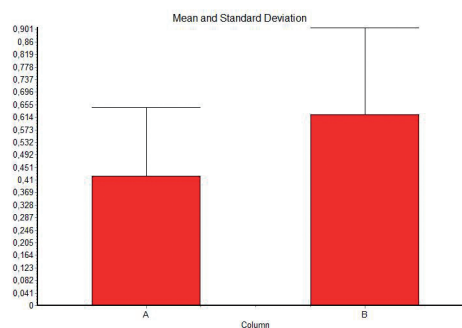
\*p<0.0001 Wilcoxon test

**Figure 1:** Mean and standard deviation of intraocular pressure before phacotrabeculectomy (A) and after five years of phacotrabeculectomy (B)



\* p<0.0001 Wilcoxon test

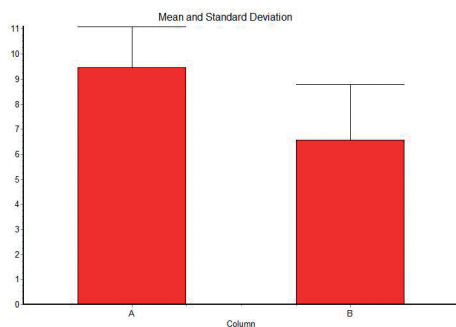
**Figure 2:** Mean and standard deviation of the number of drugs in use before phacotrabeculectomy (A) and five years after phacotrabeculectomy (B)



\* p<0.0022 Wilcoxon test

**Figure 3:** Mean and standard deviation of best-corrected visual acuity before phacotrabeculectomy (A) and five years after phacotrabeculectomy (B)

ducted in the operating room. No severe complications, such as glaucoma due to cyclotorsion of the ciliary body (malignant glaucoma) or endophthalmitis, were observed in the assessed patients.



\*  $p < 0.0001$  Wilcoxon test

**Figure 4:** Mean and standard deviation of the glaucomatous damage progression risk scores based on the following criteria: age, intraocular pressure, number of drugs in use and size of the optic disc excavation before phacotrabeculectomy (A) and the glaucomatous damage progression risk scores five years after phacotrabeculectomy (B)

## DISCUSSION

Although using isolated phacoemulsification is the first treatment of choice in advanced cataracts in comparison to the combined procedure to treat glaucoma, regardless of IOP values or POAG staging, it was not advantageous in significantly reducing IOP or the number of drugs for glaucoma control in patients who suffered with both diseases, at the same time. Therefore, an additional procedure should be evaluated for patients with cataracts and POAG, mainly at moderate and severe glaucoma stages.<sup>(9,10)</sup>

Minimally invasive glaucoma surgery (MIGS) has been an option to treat primary open angle glaucoma as it is often chosen by several anterior segment surgeons. However, MIGS is a new procedure that still shows limitations in all techniques performed so far due to short follow-up and controversial indication in advanced glaucoma - which needs very low IOP.<sup>(11)</sup>

The choice for surgical procedure to treat glaucoma can be influenced by several factors. Surgeon's skill and surgical technique refinement increase procedure efficiency, decrease its risks and, consequently, reduces surgical complications. Trabeculectomy based on MMC using in associated with phacoemulsification was the favorite surgical technique during combined surgeries, based on a recent survey carried out with surgeons who belonging to the American Glaucoma Society (AGS). This procedure was followed by phacoemulsification associated with MIGS, and by phacoemulsification associated with drainage implants.<sup>(10)</sup>

Creating a POAG progression risk score is a complex task that deserves criticism concerning the multiple factors influencing the origin and progression of the disease. Factors such as central corneal thickness were not taken into account in the current study. However, it is known that high IOP is the main risk factor for POAG development, as well as findings of the optic disc, which are expressed by increase in the excavation of the disc, secondary to death of retinal ganglion cells and, consequently, to atrophy of the retinal nerve fiber layer, which causes anatomical changes in the optic nerve head.<sup>(11)</sup> Values recorded for all these variables decreased five years after FACOTREC (Figure 4).

Assessing functional vision loss progression through computerized perimetry is essential to compose the score to assess glaucoma progression<sup>(12)</sup>. It is also necessary analyzing the peri-

papillary nerve fiber layer and the ganglion cell complex in the macula at the time to assess anatomical structure loss in the retina assessed through optical coherence tomography.<sup>(13)</sup>

OAG progression rate varies among patients; however, most it is oftentimes slow, mainly when patients are under treatment - it takes years for important anatomical and functional changes to occur. Therefore, older patients (with shorter life expectancy) are less likely to develop blindness (progression), although severe cases of the disease are more common in the elderly population<sup>(12)</sup>. Assumingly, the disease is more difficult to be controlled when a larger number of drugs is used and when adherence to treatment is not significant. Therefore, the larger number of drugs used to treat POAG can also suggest disease severity and, consequently, progression risk.

The estimated risk of glaucoma progression significantly decreased in patients undergoing MMC phacotrabeculectomy, at least five years after the surgery, when ERPG was assessed. When IOP values decreased, it was necessary taking fewer drugs to control it - at this time, optic disc excavation assessment and patients' older age (lower life expectancy) were taken into account. These findings strengthen the indication for MMC phacotrabeculectomy to treat patients with cataracts and glaucoma, since isolated cataract surgery has no significant influence on POAG treatment. Moreover, some patients may have high IOP peaks and need fast treatment, due to isolated phacoemulsification procedure<sup>(8,10)</sup>.

Mean IOP values significantly dropped five years after the MMC phacotrabeculectomy surgery, as well as the mean need of using ocular hypotensive drugs to control IOP.

There was also significant improvement in visual acuity in comparison to values recorded before the surgery and five years after phacotrabeculectomy with MMC. The surgery did not significantly change the presence of refractive astigmatism. However, the assessment of the spherical refractive equivalent was improved when emmetropia was approached in the postoperative period five years after the procedure.

Although refractive evaluation or biometric calculation applied to the assessed patients was not the focus of the current study, ultrasound biometry with refraction - expected for myopia of a diopter - was performed in the preoperative period. The postoperative refractive spherical equivalent was  $0.9 \pm 0.8D$ . It is known that surprises in the postoperative refractive result are more frequent in glaucoma patients with glaucoma who are subjected to cataract surgery, and vision recovery may not be as expected.<sup>(14)</sup>

The search for alternative surgical procedures to trabeculectomy, both associated with cataract surgery or isolated to treat glaucoma, suggests that trabeculectomy does not yet offer the results and the desired safety for such a treatment. However, it is the best-known procedure among glaucoma surgeons and it is indicated for the combined treatment with phacoemulsification. In the current study, trabeculectomy proved to be more effective five years after its performance.

Lack of computerized perimetry data in this study made it impossible for the authors to comment on the optic neuropathy staging and progression. The size of the vertical excavation of the optic disc was the only variable used to develop the glaucoma progression risk score; however, this variable is very fragile to be analyzed with reproducibility. Variables regarding IOP value, number of intraocular hypotensive drugs and patient's age are easy to measure, as well as show that significant IOP reduction to disease control in most glaucoma patients.

## CONCLUSION

Phacotrabeculectomy decreased IOP, the number of hypotensive medications, the spherical refractive equivalent and the glaucomatous damage progression risk score, as well as improved visual acuity in follow-up 5 years after surgery, at least, in comparison to the preoperative values recorded for these variables.

## REFERENCES

- Picoto M, Galveia J, Almeida A, Patrício S, Spohr H, Vieira P, et al. Pressão intraocular (PIO) após cirurgia de extração de catarata. *Rev Bras Oftalmol.* 2014;73(4):230–6.
- Riordan-eva P, Whitcher JP, organizadores. *Oftalmologia geral de Vaughan e Asbury.* 17ed. Porto Alegre: AMGH; 2011.
- Oliveira FG, Franco CG, Damasceno ML, Ávila MP, Magacho L. Comparison of biometric predictability and final refraction expected in phacoemulsification surgery with and without trabeculectomy. *Rev Bras Oftalmol.* 2018;77(1):25–9.
- Taleb A, Ávila M, Moreira H. *As condições de saúde ocular no Brasil.* São Paulo: Walprint Gráfica e Editora; 2009.
- Gonçalves MR, Guedes MD, Chaves MA, Pereira CC, Otton R. Análise dos fatores de risco e epidemiologia em campanha de prevenção da cegueira pelo glaucoma em João Pessoa, Paraíba. *Rev Bras Oftalmol.* 2013;72(6):396–9.
- Mandia C Jr, Kasahara N, Seixas FS, Paolera MD, Almeida GV, Cohen R. Comparação a longo prazo entre a facectomia extracapsular combinada à trabeculectomia e à facotrabe-culectomia. *Arq Bras Oftalmol.* 2002;65(6):641–4.
- Gutemberg GC, Silva Filho FJ, Rehder JR. Complicações pós-operatórias precoces de tra-beculectomia com mitomicina, em pacientes portadores de glaucoma primário de ângulo aberto. *Rev Bras Oftalmol.* 2010;69(2):100–3.
- Majstruk L, Leray B, Bouillot A, Michée S, Sultan G, Baudouin C, et al. Long term effect of phacoemulsification on intraocular pressure in patients with medically controlled primary open-angle glaucoma. *BMC Ophthalmol.* 2019;19(1):149.
- Hayashi K, Yoshida M, Sato T, Manabe SI. Effect of topical hypotensive medications for preventing iop increase after cataract surgery in eyes with glaucoma. *Am J Ophthalmol.* 2019;205:91–8.
- Ontario Health (Quality). Minimally invasive glaucoma surgery: A budget impact analysis and evaluation of patients' experiences, preferences, and values. *Ont Health Technol Assess Ser.* 2019;19(9):1-57.
- Weinreb RN, Aung T, Medeiros FA. The pathophysiology and treatment of glaucoma: a review. *JAMA.* 2014;311(18):1901–11.
- De Moraes CG, Juthani VJ, Liebmann JM, Teng CC, Tello C, Susanna R Jr, et al. Risk factors for visual field progression in treated glaucoma. *Arch Ophthalmol.* 2011;129(5):562–8.
- Kansal V, Armstrong JJ, Pintwala R, Hutnik C. Optical coherence tomography for glaucoma diagnosis: An evidence based meta-analysis. *PLoS One.* 2018;13(1):e0190621.
- Manoharan N, Patnaik JL, Bonnell LN, SooHoo JR, Pantcheva MB, Kahook MY, et al. Re-fractive outcomes of phacoemulsification cataract surgery in glaucoma patients. *J Cataract Refract Surg.* 2018;44(3):348–54.

---

### Corresponding author:

Vítor Luna de Sampaio

Rua da Conceição, Juazeiro do Norte City, Ceará State, Brazil.

CEP: 63010222.

E-mail: vitorsampaio\_coj@yahoo.com.br