

CASE REPORT

Fonsecaea pedrosoi CEREBRAL PHAEOPHYCOMYCOSIS (“CHROMOBLASTOMYCOSIS”). FIRST HUMAN CULTURE-PROVEN CASE REPORTED IN BRAZIL

José Paulo S. NÓBREGA(1), Sergio ROSEMBERG(2), Ana Maria ADAMI(2), Elizabeth Maria HEINS-VACCARI(3), Carlos da Silva LACAZ(3)† & Thales DE BRITO(2,4)

SUMMARY

Cerebral phaeohyphomycosis (“chromoblastomycosis”) is a rare intracranial lesion. We report the first human culture-proven case of brain abscesses due to *Fonsecaea pedrosoi* in Brazil. The patient, a 28 year-old immunocompetent white male, had ocular manifestations and a hypertensive intracranial syndrome. Magnetic resonance imaging (MRI) of the brain revealed a main tumoral mass involving the right temporo-occipital area and another smaller apparently healed lesion at the left occipital lobe. A cerebral biopsy was performed and the pathological report was cerebral chromoblastomycosis. The main lesion was enucleated surgically and culture of the necrotic and suppurative mass grew a fungus identified as *Fonsecaea pedrosoi*. The patient had received a knife wound sixteen years prior to his hospitalization and, more recently, manifested a pulmonary granulomatous lesion in the right lung with a single non-pigmented form of a fungus present. It was speculated that the fungus might have gained entrance to the host through the skin lesion, although a primary respiratory lesion was not excluded.

The patient was discharged from the hospital still with ocular manifestations and on antimycotic therapy and was followed for eight months without disease recurrence. Few months after he had complications of the previous neuro-surgery and died. A complete autopsy was performed and no residual fungal disease was found.

KEYWORDS: Phaeohyphomycosis; Cerebral “chromoblastomycosis”; *Fonsecae pedrosoi*; Brazil.

CASE REPORT

Case history - Patient: A 28 year-old white male, a rural worker, suffered in 1984 a knife wound in the right inguinal area when working in the woods which progressed to an abscess measuring approximately 2.0 x 0.5 cm in diameter. The patient was hospitalized and cultures of the material from the abscess were positive for *Chromobacterium violaceum*. No biopsy was obtained and no mycological study was done at the time. The patient received antibiotic treatment with healing of the skin lesion. At that time he noticed a visual defect in the left eye, which persisted to the end. He had epidemiological data for schistosomiasis and Chagas disease. The patient also referred an episode of icterus, fever and weakness one year prior to the clinical episode.

Present history: In August 2000 the patient returned complaining of severe bitemporal headache accompanied by fits of dizziness with nausea and vomiting, right ocular pain and loss of the temporal field of the right eye.

Examination showed a conscious young man, oriented, able to communicate well, with right papilledema and left optical disk atrophy. He had a right homonymous inferior quadrantscopy defect and a left homonymous hemianopsy. Isocoric pupils. Direct and consensual papillary reflex slow in the left eye and normal in the right eye. Near reflex normal in both eyes.

Laboratory tests detected macrocytic anemia probably of nutritional origin. Serology for HIV, hepatitis B and C was negative.

Lumbar tap, done few days after hospital admission showed essentially normal spinal fluid except for a moderate increase of gammaglobulins. Direct mycological examination was negative. Magnetic resonance imaging (MRI) of the chest showed a parenchymal lesion at the base of the right inferior lobe of the lung. (Fig. 1B and C). A transbronchial biopsy was done and the pathological report was granulomatous inflammation with absence of acid-fast bacilli.

Financial support for this project was provided by CNPq (300857/94-2-NV), LIM 53 and LIM 06

(1) University of S. Paulo Medical School, São Paulo, SP, Brazil, and “Hospital das Clínicas”, Neurological Clinic, S. Paulo, SP, Brazil.

(2) Division of Pathology, “Hospital das Clínicas”, S. Paulo, SP, Brazil

(3) Institute of Tropical Medicine, Laboratory of Mycology, S. Paulo, SP, Brazil

(4) Institute of Tropical Medicine, Laboratory of Immunopathology, S. Paulo, SP, Brazil

†In Memoriam

Correspondence to: Dr. Thales de Brito, Instituto de Medicina Tropical de S. Paulo, Av. Dr. Enéas de Carvalho Aguiar 470, 05403-907 S. Paulo, SP, Brasil. E. Mail: thalesbr@usp.br

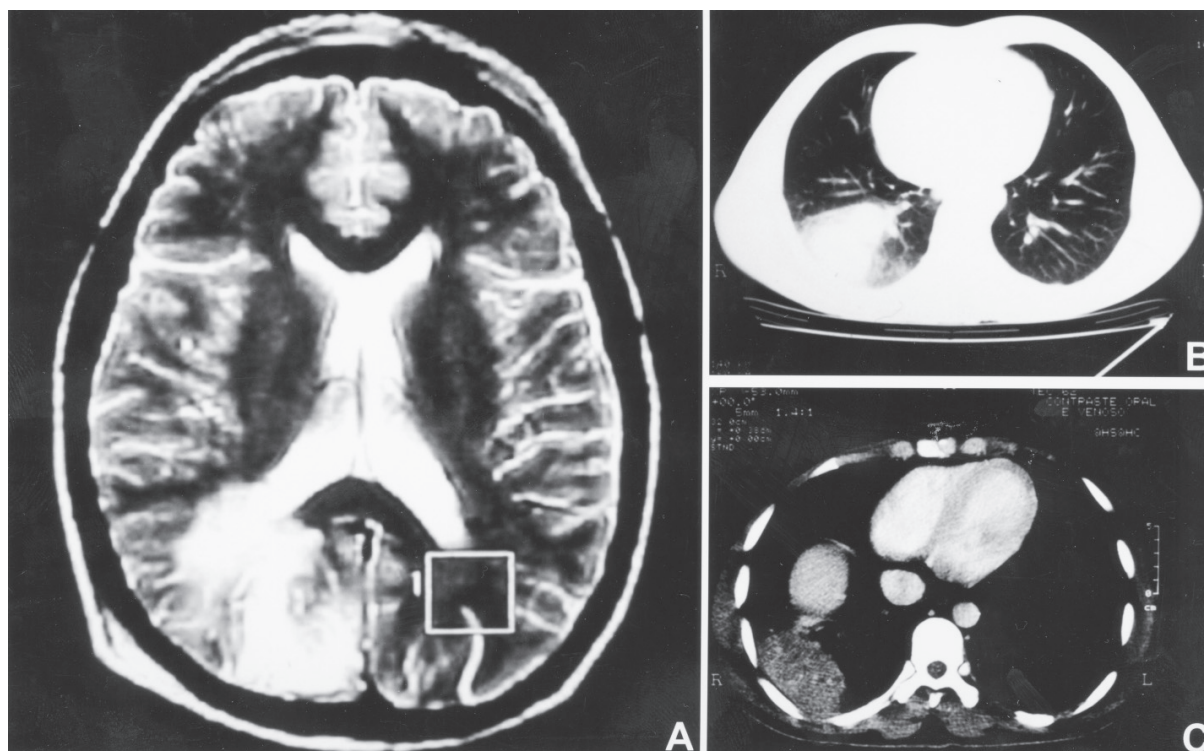


Fig. 1 - A - (MRI) - T2 weighted hypersignal in the right temporo-occipital region extending from the superficial cortex up to the ventricular wall. Note the obstruction of the adjacent sulcus suggesting edema. Attenuated small image involving the left temporo-occipital area (box). Magnetic resonance transversal image (6-mm thick) at the lateral ventricle level. B - Nodular opacity in the basal segment of the right inferior lobe of the lung. C - Soft tissue attenuated mass reveals a heterogeneous enhancement after intravenous contrast (mediastinal window).

MRI of the brain demonstrated a main hypersignal involving the right temporo-occipital area and another small ill-defined image suggestive of a healed small lesion in the left occipital lobe (Fig. 1A). A brain biopsy of the tumoral main lesion revealed granulomatous inflammation around golden brown forms of a fungus ("chromoblastomycosis"). The patient received Amphotericin B, 0.5 mg/day (total dosage: 1350 mg) and, about twenty days later he was submitted to a right temporal craniotomy. On exploratory aspiration purulent and necrotic material was obtained. An abscess wall was encountered 2-3 cm below the cortical surface of the occipital lobe. The abscess measured about 2 cm in diameter and its wall was gently shelled out by finger dissection and apparently the entire lesion was removed.

The immediate postoperative course was uneventful. A lumbar tap revealed normal spinal fluid. No bacteria or fungi were found. The patient was discharged with visual deficiency in both eyes and receiving 200 mg/day of itraconazole. He continued to do well for eight months. Months after he developed complications secondary to the previous neurosurgery and died. Autopsy was performed and no residual fungal disease was found.

Pathologic findings: The brain specimen was an oval mass measuring 2 x 2 x 1.5 cm in diameter and consisted mainly of soft grayish, homogeneous material. Microscopic examination revealed the presence of multiple foci of necrosis with scattered acute and chronic inflammation in surrounding edematous, gliotic tissue. Capillary hyperplasia and perivascular lymphocytic cuffing were also present. Epithelioid

granulomata, frequently with a suppurative center, were seen with giant cells chiefly of the foreign body type. Groups of round or oval forms of a fungus, the walls usually golden brown in color, measuring 10–12 μm in diameter were observed inside giant cells or isolated in necrotic areas (Fig. 2A, B). Septate hyphal forms about 6–7 μm in diameter were seen occasionally within and outside the giant cells.

The pulmonary biopsy was reevaluated and multiple sections were obtained from the paraffin block. A peribronchial chronic inflammation leading to granuloma formation was detected. The granuloma was made up mostly of monocytes with differentiation toward epithelioid cells (Fig. 2C). A foreign body giant cell was present close to the granuloma and an oval thick-walled non-pigmented budding structure about 10 μm in diameter, identified as a fungus after Gridley staining, was detected in its cytoplasm (Fig. 2D, E, F).

Mycologic findings: Direct examination of cerebral tissue with 20% KOH showed the presence of elongated septate pigmented hyphae (Fig. 2G). Also, fragments of the surgical brain specimen were cultured on agar Sabouraud medium at room temperature and after fifteen days flat to dome-shaped colonies were seen to grow. The colonies were velvety, dark olive gray in color, not folded or wrinkled when young but developing radial grooves and a central elevation when old (Fig. 2H).

Slide culture revealed light brown septate hyphae about 3 μm in diameter and straight conidiophores bearing frequently branched one-celled chains of conidia (Fig. 2I). The fungus was identified as *Fonsecaea pedrosoi*.

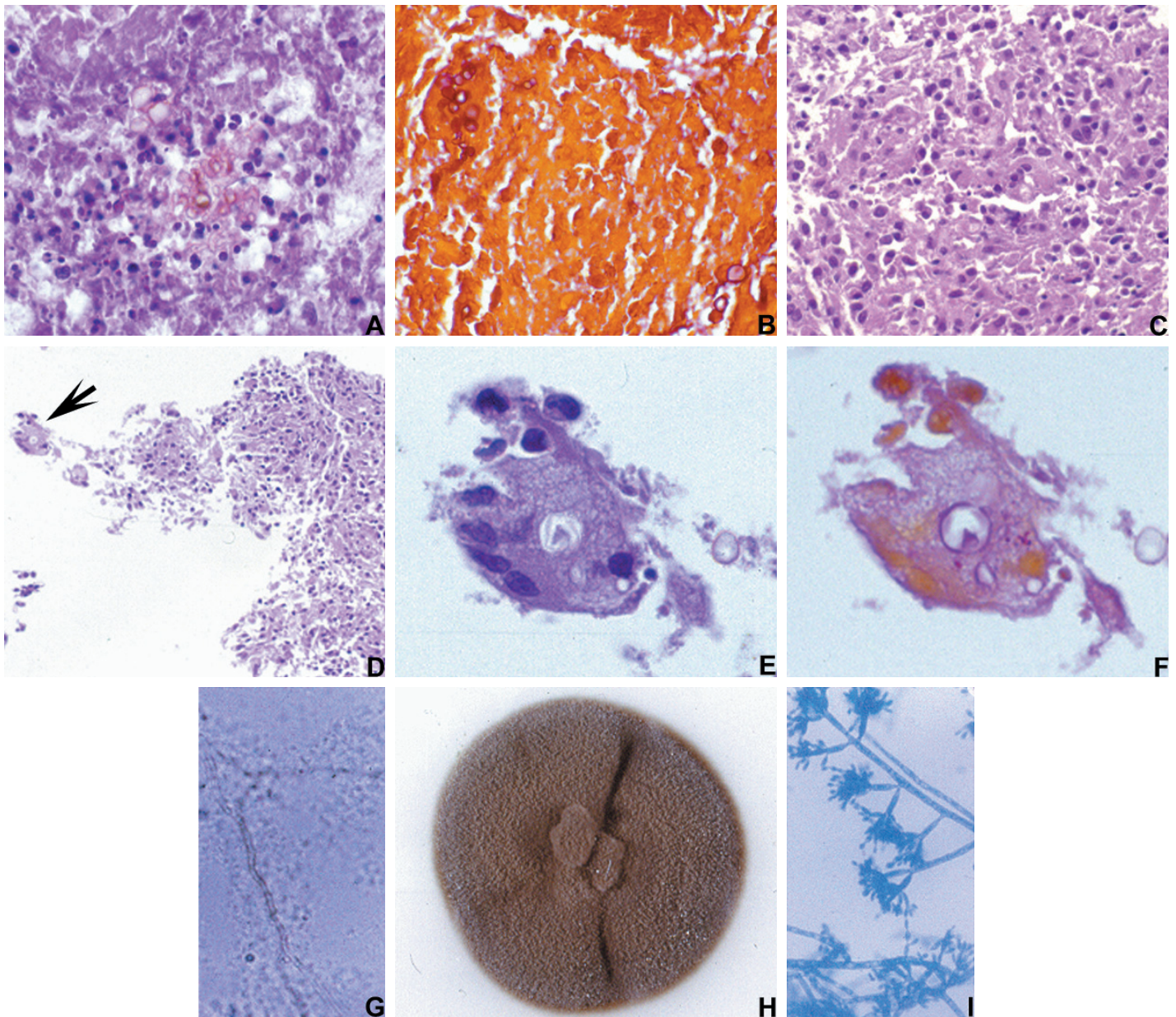


Fig. 2 - A - Necrotic area of the cerebral abscess with groups of round or oval forms of a pigmented fungus. Elongated forms suggestive of small hyphae are also present. Hematoxylin-eosin (HE) stain, original magnification X 600. **B** - Forms of the fungus are better visualized in red by the Gridley stain. Original magnification X 600. **C** - Pulmonary granuloma made up of macrophages and epithelioid cells. HE, original magnification X 400. **D** - At the granuloma periphery a giant cell with a fungal round form in the cytoplasm (arrow). HE, original magnification X 200. **E** - Detail of the giant cell. The fungus in the giant cell cytoplasm apparently has a double membrane and a dark area inside. HE, original magnification X 900. **F** - Gridley stain showing the same giant cell with a red stained budding form of a fungus in the cytoplasm. The original HE slide was destained and stained again by the Gridley stain. Original magnification X 900. **G** - Direct mycological examination of the brain shows elongated golden brown septate hyphae. X 100. **H** - Fungus colony exhibits a flat to dome-shaped aspect, velvety and dark olive gray in color. **I** - Slide culture shows septate hyphae and straight conidiophores bearing branched one-celled chains of conidia. Lactophenol blue stain, X 100.

DISCUSSION

Cerebral phaeohyphomycosis is a general term applicable to all brain infections caused by dematiaceous fungi and should be used instead of chromoblastomycosis. Dematiaceous fungi are usually found as

saprophytes in soil and decaying vegetation. The most common site of infection is the skin of the extremities and usually afflicts legs of barefoot agricultural workers in the tropics.

GARCIN *et al.* in 1949⁶ apparently were the first to report a case of

cerebral infection by an unidentified pigmented fungus. In 1952 BINFORD *et al.*¹ published a case of brain abscess caused by a darkly pigmented fungus which was cultured for the first time and classified by Emmons as *Cladosporium trichoides*, now renamed *Xylohypha bantiana*. Between that time and 1993, 37 cases of central nervous system infection by pigmented fungi have been reported in the United States and Europe⁹, confirmed by either histological methods or fungal culture, or both. Predominant symptoms are either like those produced by any space-occupying intracranial lesion, as observed in our patient, or those of chronic meningitis.

In Brazil there are four case reports of cerebral involvement of the central nervous system by dematiaceous fungi, three of them without culture^{3,7,8,10}. The first report³ was in 1953 and described chromoblastomycosis involving meninges of the basis of the skull and the first cervical segments of the spinal cord. In 1979 QUEIROZ *et al.*¹⁰ reported a case of brain abscess and meningitis caused by a pigmented fungus. The report by LOPES *et al.*⁷ was of cervical cord compression due to chronic granulomatous meningitis with dense fibrosis. The authors found the causative agent to be a pigmented fungus which was assumed to be *Cladosporium trichoides* in view of the frequency of this agent in other reports and of the aspect of the fungus in the histological sections. However, nowadays we know that is impossible to distinguish the different species of dematiaceous fungi on the basis of their appearance in the lesions. The only case of brain abscess in which *Cladosporium trichoides* was cultivated was reported in 1980 by MEIRA *et al.*⁸

Therefore, as far we could ascertain, our case is the first in which *Fonsecaea pedrosoi* was cultivated from a brain abscess in Brazil. Apparently, combined surgical and antimycotic treatment has given good results. It is worth to point out, however, that most cases of cerebral phaeohyphomycosis reported recurred or were fatal and were diagnosed after post-mortem examination.

FUKUSHIRO *et al.* in 1957⁴ were the first to report a culture-proven case of cerebral chromoblastomycosis due to *Fonsecaea pedrosoi* in Japan. Since then reports of this disease have been increasing in Japan and in a series of 249 cases reported by FUKUSHIRO⁵ in 1983 *Fonsecaea pedrosoi* was the causative agent in an overwhelming majority (86.3%). The disease, similarly to our case, was seen predominantly in immunocompetent hosts.

Phaeohyphomycosis usually affects the skin and subcutaneous tissues, *Fonsecaea pedrosoi* is the more common etiologic agent and the major route of entry is through trauma that causes fungus inoculation. Our patient had a previous skin trauma years ago and we might speculate that the fungus gained entry to his organism at that time and probably spread to the central nervous system by hematogenous route. The left occipital image suggestive of a healed lesion might be interpreted as a remnant of this early spread of the fungus and correlates with the first ocular manifestations of the patient. The isolated form of fungus present in the lung was not pigmented and its presence can be interpreted either as the same agent which produced the cerebral abscess or an associated mycosis of unknown etiology. If the former interpretation is correct, either the fungus infected the lung during hematogenous dissemination or a primary respiratory port of entry should also be considered in this case.

RESUMO

Feohifomicose cerebral ("Cromoblastomicose") por *Fonsecaea pedrosoi*: primeiro caso demonstrado por cultura do fungo no Brasil

A Feohifomicose cerebral ("cromoblastomicose") é uma lesão rara. Apresentamos o primeiro caso desta entidade com cultura do abscesso cerebral, devido a *Fonsecaea pedrosoi*. O paciente, um homem de 28 anos de idade, imunocompetente, apresentou manifestações oculares e síndrome de hipertensão intracraniana. Imagens de ressonância magnética (MRI) cerebral mostraram massa tumoral envolvendo a área temporo-occipital direita e outra lesão menor, possivelmente cicatricial, no lobo occipital esquerdo. Biopsia cerebral mostrou cromoblastomicose cerebral. A lesão principal foi enucleada cirurgicamente e *Fonsecaea pedrosoi* foi cultivado da massa necrótica e supurada. O paciente tinha tido um ferimento por faca 16 anos antes de ser visto no nosso hospital e, mais recentemente, uma lesão pulmonar granulomatosa no pulmão direito onde foi identificada uma forma isolada, não pigmentada, de fungo. A possibilidade de que o fungo tenha penetrado no organismo do paciente através da lesão de pele foi considerada, mas não se pode excluir uma eventual lesão primária pulmonar.

O paciente teve alta hospitalar e foi seguido durante oito meses sem recorrência da doença. Meses depois, entretanto, desenvolveu complicações relacionadas à neurocirurgia, vindo a óbito. Uma autopsia completa foi feita, não demonstrando doença fúngica remanescente.

REFERENCES

1. BINFORD, C.H.; THOMPSON, R.K. & GORHAM, M.E. - Mycotic brain abscess due to *Cladosporium trichoides*, a new species. Report of a case. **Amer. J. clin. Path.**, 22: 535-542, 1952.
2. BONIFAZ, A.; CARRASCO-GERARD, E. & SAÚL, A. - Chromoblastomycosis: clinical and mycologic experience of 51 cases. **Mycoses**, 44: 1-7, 2001.
3. FRANÇA NETTO, A.S.; DE BRITO, T. & ALMEIDA, F.P. - Cromomicose do sistema nervoso. Estudo anátomo-clínico de um caso. **Arq. Neuro-psiquiat. (S. Paulo)**, 11: 265-277, 1953.
4. FUKUSHIRO, R.; KAGAWA, S.; NISHIYAMA, S. *et al.* - Un cas de chromoblastomycose cutanée avec métastase cérébrale mortelle. **Presse méd.**, 65: 2142-2143, 1957.
5. FUKUSHIRO, R. - Chromomycosis in Japan. **Int. J. Derm.**, 22: 221-229, 1983.
6. GARCIN, R.; MARTIN, R.; BERTRAND, I.; GRUNER, J. & TOURNEUR, R. - Mycose méningo-épendymaire: étude anatomo-clinique. **Presse méd.**, 57: 1201-1204, 1949.
7. LOPES, M.B.S.; BARBOSA, R.F.; VELLASCO, O. & ROSEMBERG, S. - Compression médullaire due à *Cladosporium trichoides*. Observation anatomo-clinique. **Ann. Path.**, 9: 275-278, 1989.
8. MEIRA, G.M.; NEVES, A.C.A.; DIAS, L.B. *et al.* - Cladospórioze (Demaciomicose) cerebral. Novo caso encontrado no Brasil. **Rev. Inst. Med. trop. S. Paulo**, 22: 310-318, 1980.
9. PALAOGU, S.; SAV, A.; BASAK, T.; YALCINLAR, Y. & SCHEITHAUER, B.W. - Cerebral phaeohyphomycosis. **Neurosurgery**, 33: 894-897, 1993.
10. QUEIROZ, L.S.; NUCCI, A.; LOPES DE FARIA, F.; PEDRO, R.J. & FACURE, N.O. - Cromomicose cerebral. Registro de um caso. **Arq. Neuro-psiquiat. (S. Paulo)**, 37: 303-310, 1979.

Received: 10 June 2003

Accepted: 22 July 2003