

# Quantitative Assessment of Left Ventricular Regional Wall Motion in Endomyocardial Fibrosis

Charles Mady, Vera Maria Cury Salemi, Barbara Maria Ianni, Edmundo Arteaga, Fábio Fernandes, Felix J A Ramires  
São Paulo, SP - Brazil

## Objective

To analyze left ventricular (LV) regional wall motion in patients with endomyocardial fibrosis (EMF).

## Methods

The study comprised 88 patients, 59 of the female sex, with a mean age of  $39 \pm 13$  years (range, 9 to 65) and with echocardiographic and angiographic evidence of left ventricular EMF. The intensity of fibrous tissue buildup on contrast cineventriculography was classified as mild, moderate, or severe. The overall left ventricular ejection fraction (LVEF) was determined by using the area-length method on ventriculography. The motion was measured in 100 equidistant chords perpendicular to the centerline drawn in the middle of the final diastolic and systolic contours and normalized to cardiac size. Five left ventricular segments were analyzed: A - apical; AL - anterolateral; AB - anterobasal; IA - inferoapical; IB - inferobasal. Abnormality was expressed in units of standard deviation of the mean motion in a normal population of reference, comprised of 103 patients with normal LV according to clinical and electrocardiographic data, and angiographic standards.

## Results

Mean LVEF was  $0.47 \pm 0.12$ . Fibrous tissue buildup in the left ventricle was mild in 12 patients, moderate in 40, and severe in 36. The regions with the poorest ventricular wall motion were A ( $-1.4 \pm 1.6$  standard deviation/chords) and IA ( $-1.6 \pm 1.8$  standard deviation/chords) compared with that in AB ( $-0.3 \pm 1.9$  standard deviation/chords), AL ( $-0.5 \pm 1.8$  standard deviation/chords) and IB ( $-0.9 \pm 1.3$  standard deviation/chords). No relation was observed between the intensity of fibrous tissue buildup and regional ventricular wall motion.

## Conclusion

A change in LV regional wall motion exists in EMF, and it is independent of the intensity of fibrous tissue buildup qualitatively assessed. Nonuniform involvement of the LV should be considered when planning surgery for this disease.

## Key words

regional contractility, fibrous involvement, endomyocardial fibrosis

Instituto do Coração (InCor), HC-FMUSP  
Mailing address: Charles Mady - Av. Dr. Néas C. Aguiar, 44  
Cep 05403-000 - São Paulo, SP, Brazil  
E-mail: cmady@cardiol.br, charles.mady@incor.usp.br  
Received for publication: 02/16/2004  
Accepted for publication: 07/29/2004  
English version by Stela Maris Costalonga

The characteristics of the disease that is clinically similar to endomyocardial fibrosis (EMF) were first described in Africans by Bedford and Konstam<sup>1</sup>. Then, Davies<sup>2</sup> detailed its pathological characteristics. The fibrous involvement of the endocardium and myocardium adjacent to the apex and inlet of both ventricles causing a restrictive syndrome characterizes the disease. Usually, the fibrotic tissue involves the papillary muscles, leading to additional atrioventricular valvular dysfunctions, which combined with restriction to ventricular filling cause the clinical manifestations of the disease.

The occurrence of endomyocardial fibrosis is supposedly restricted to tropical zones. Recent studies,<sup>3-5</sup> however, have reported a universal distribution of that disease, which is contrary to the preceding statement.

The ventricular image on echocardiography<sup>6</sup> and cineventriculography<sup>7</sup> is characteristic of the disease. Apical amputation and restriction to diastolic filling occur. The overall systolic function of the left ventricle is usually preserved, except in advanced forms. However, little is known about alterations in segmentary contractility in that disease. The pattern of ventricular involvement varies according to the countries where the studies were performed<sup>8</sup>. It is plausible that the intensity of the distribution of fibrous tissue buildup in the left ventricle may interfere with regional contractility.

This study aimed at assessing left ventricular regional wall motion and analyzing the relation between the alterations in wall motion and intensity of the overall fibrous involvement of the left ventricle in patients with endomyocardial fibrosis.

## Methods

Eighty-eight patients with left ventricular endomyocardial fibrosis were studied, 59 of the female sex, with a mean age of  $39 \pm 13$  years (range, 9 to 65), 85 (96%) of whom had associated right ventricular fibrosis. The distribution of functional class according to the New York Heart Association (NYHA) criterion was as follows: I in 8 (9.1%) patients; II in 11 (12.5%); III in 38 (43.2%); and IV in 31 (35.2%). The normal population of reference comprised 103 individuals, 52 of whom were men, with a mean age of  $52 \pm 10$  years (range, 21 to 72) and normal left ventricle according to clinical and electrocardiographic data, and angiographic pattern.

The diagnosis of endomyocardial fibrosis was established based on the following echocardiographic findings present in all cases: obliteration of the ventricular apex; atrial dilation; an increase in endocardial echo reflectivity; restrictive diastolic filling pattern;

atrioventricular regurgitation<sup>9</sup>. The angiographic images of the left ventricle were performed with a pigtail catheter in the anterior right oblique projection at 30° and confirmed the diagnosis. The intensity of the fibrous tissue buildup on contrast cineventriculography was classified as mild, moderate, or severe<sup>10</sup>. The overall left ventricular ejection fraction (LVEF) was determined by the area-length method<sup>11</sup> and the regional left ventricular wall motion quantified by the centerline method<sup>12,13</sup>, which is a simple model for analyzing ventricular wall motion. The contrast images representing the left ventricle in maximum systole and diastole were chosen, and their contours were transferred to paper for later calculation. The images were analyzed by 2 independent researchers (Fig. 1). By using a specific program developed by Toscano et al<sup>14</sup>, the ventricular images were recorded in a micro-computer with the aid of a digitalizing table (CURTA/model IS/ONE). The centerline was constructed in the computer between the final diastolic and systolic contours (Fig. 1). Motion was measured in 100 equidistant chords perpendicular to the centerline. The length of each chord was the motion of the corresponding point in the left ventricular contour<sup>13</sup>. The chords were normalized to the cardiac size by dividing each length by the final diastolic margin, and a unit without dimension was obtained. Abnormality was expressed as units of standard deviation of the mean motion of the normal population of reference. Positive values indicated hyperkinesia, and negative values indicated hypokinesia.

The measurement of the chords was initiated at the level of the aortic valve, and the chords were successively numerated in a clockwise direction, from the aortic valvular plane to the mitral one. The regions demarcated by the chords from 1 to 10 were excluded, because the analysis showed a great variation in length. The chords 81 to 100 were also excluded because they represented the mitral valve<sup>15</sup>. The left ventricle was divided into 5 regions: anterobasal (AB), chords 10 to 23; anterolateral (AL), chords 24 to 37; apical (A), chords 38 to 52; inferoapical (IA), chords 53 to 66; and inferobasal (IB), chords 67 to 80. The mean length and standard deviation were calculated and compared with the mean curve of 103 healthy individuals.

All patients signed the written consent to participate in the study after being instructed about the objectives and methods to be used. The procedures were performed according to the recom-

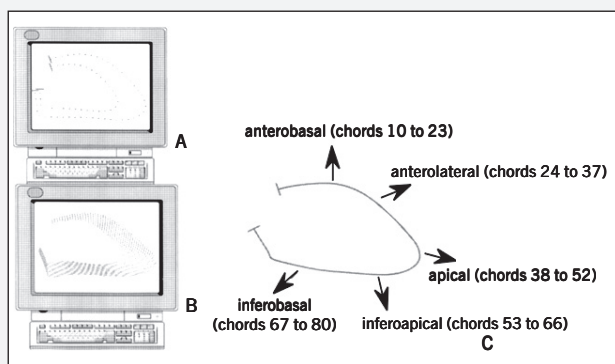


Fig. 1 - Centerline method for analyzing regional left ventricular wall motion. A) final diastolic and systolic endocardial contours on contrast ventriculography; B) 100 chords perpendicular to the centerline delimited between the final diastolic and systolic contours; C) left ventricle divided into 5 regions, the chords 1 to 10 were excluded due to their great variability in length, and chords 81 to 100 were excluded because they represented the mitral valve.

mendations of the institutional review board, which approved the protocol based on the principles defined by the Helsinki Declaration.

The statistical method used for comparing wall motion was the analysis of variance with repeated measures. The significance level adopted was 0.05. The data were analyzed by using the SAS statistical program, version 6.11 (SAS Institute Inc., Cary, NC, USA).

## Results

The mean LVEF was  $0.47 \pm 0.12$ . The left ventricular involvement by fibrous tissue was mild in 12 (14%) patients, moderate in 40 (44%), and severe in 36 (41%). The regions with the worst contractility were A ( $-1.4 \pm 1.6$  standard deviation/chords) and IA ( $-1.6 \pm 1.8$  standard deviation/chords), compared with AB ( $-0.3 \pm 1.9$  standard deviation/chords), AL ( $-0.5 \pm 1.8$  standard deviation/chords), and IB ( $-0.9 \pm 1.3$  standard deviation/chords) (Fig. 2). The left ventricular wall motion did not depend on the intensity of fibrous tissue buildup (Fig. 3). The 2-by-2 comparison of regional ventricular wall motion in endomyocardial fibrosis showed no significant difference between the following regions: AB and AL ( $P=0.29$ ), AL and IB ( $P=0.09$ ), A and IA ( $P=0.18$ ) (Table I).

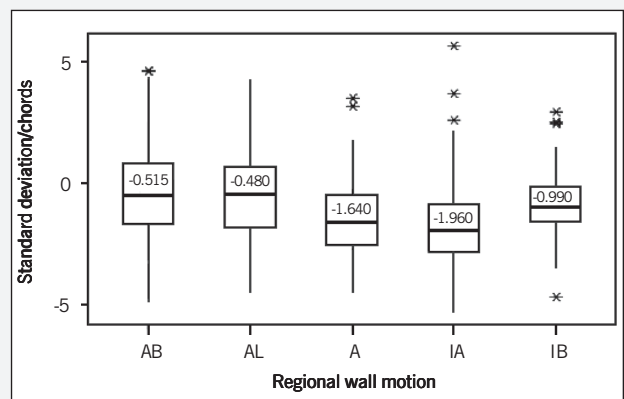


Fig. 2 - Regional wall motion in 5 left ventricular regions showing a reduction in motion in the regions A and IA; AB - anterobasal; AL - anterolateral; A - apical; IA - inferoapical; IB - inferobasal.

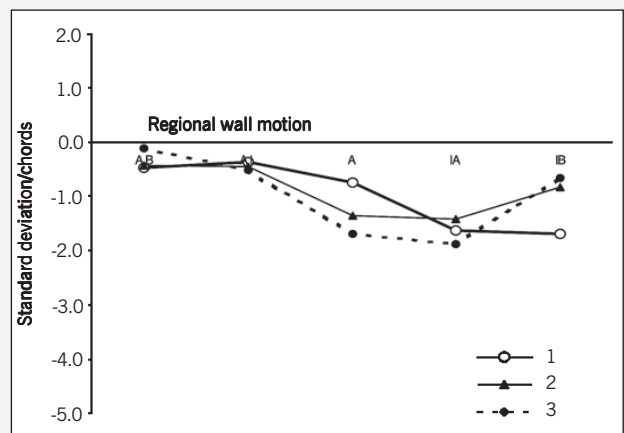


Fig. 3 - The degree of overall fibrosis of the left ventricle was qualitatively analyzed on left ventriculography as mild (12 patients), moderate (40), and severe (36). That fibrosis was related to regional wall motion in each of the 5 left ventricular regions, and it showed no relation to the intensity of the overall buildup of fibrous tissue; A - apical; AL - anterolateral; AB - anterobasal; IA - inferoapical; IB - inferobasal. Overall buildup of fibrous tissue in the LV: 1 - mild; 2 - moderate; 3 - severe.



**Table 1 - Descriptive levels referring to the 2-by-2 comparison of ventricular regional wall motion in endomyocardial fibrosis**

Hypothesis	P
RVWM	0.0001
AB x AL	0.2904
AB x A	0.0001
AB x IA	0.0001
AB x IB	0.0299
AL x A	0.0001
AL x IA	0.0001
AL x IB	0.0916
A x IA	0.1804
A x IB	0.0060
IA x IB	0.0001

RVWM - ventricular regional wall motion; A - apical; AL - anterolateral; AB - anterobasal; IA - inferoapical; IB - inferobasal.

## Discussion

The pathogenic mechanisms of endomyocardial fibrosis are little understood. Some studies have suggested the occurrence of different clinical and histopathological stages in the evolution of the disease, the final stage being characterized by a fibrotic process of the endomyocardium<sup>16</sup>. Some controversial points exist regarding fibrosis as a mere static fibrous tissue, consequent to the thrombotic or previous inflammatory process, or as having an evolutionary character<sup>17,18</sup>.

Some detailed descriptions of the disease exist<sup>4,19</sup>. The lesions reflect the replacement of the endocardium and adjacent ventricular myocardium by fibrous tissue. The lesions are not diffusely located in the endocardium, but usually affect the apex and ventricular inlet. From the left ventricular apex, the fibrotic lesions extend to the posterior wall, involving the posterior leaflet of the atrioventricular valve, which adheres to the fibrosis. This is a continuous or irregular process, with areas of tissue between the apex and the valvular region which are spared from fibrosis. However, the disease may affect only the apex or the valvular region, and may even be found in regions other than the apex and valves<sup>7</sup>. This morphological information is of great relevance, mainly because new surgical techniques have been reported<sup>20</sup>. However, the method of *in vivo* analysis of those ventricles is important.

In clinical practice, ventricular wall motion is assessed through echocardiography by use of the wall motion score<sup>21</sup> or through contrast cineventriculography of the left ventricle. The poor reproducibility of that assessment led to the development of the method used in this study, which was described by Sheehan et al<sup>12</sup> in 1982 and introduced at our institution by Toscano et al in 1992<sup>14</sup>. This method promotes a reliable model for analyzing the left ventricular regional function. Our results showed that the A and IA walls had a significant reduction in motion in comparison with that of the other walls. Because both regions are the predominant site of fibrous tissue buildup in endomyocardial fibrosis, we expected that these regional alterations were greater in the ventricles with more intense fibrosis buildup. In our study, however, we did not find such a relation between them. Quantification of the regional left ventricular wall motion had no relation to the qualitative fibrous tissue buildup assessed on ventriculography, although the latter analysis is useful

predominantly for assessing the endocardial involvement, but not the true myocardial involvement.

In our study, we used 103 left ventricular cineventriculograms of healthy individuals to compare with those of patients with endomyocardial fibrosis. Previous studies have shown that the reliable definition of normal left ventricular cineventriculography requires the analysis of 50 healthy individuals<sup>22</sup>. Therefore, in our study, the number of healthy individuals analyzed exceeded the minimum necessary recommended in the literature.

If one admits that endomyocardial fibrosis is a disease characterized by a scar, an interesting question is to know why, in most cases, the apex and diaphragmatic region are the most affected regions of the left ventricle. As already known, in Chagas' disease, which is characterized by a diffuse myocardial inflammatory process<sup>23</sup>, the apical aneurysm is a very suggestive morphological finding<sup>24</sup>. When the aneurysm is absent, alterations in contractility, which frequently involve the left ventricular posteroinferior wall, may be detected. In nondilated Chagas' disease, a reduction in the segmentary contractility of the inferoapical wall may also be observed<sup>25</sup>. Both heart diseases lead to segmentary alteration in wall motion, which may be analyzed through that method.

Different types of aggressive agents cause different types of morphologic consequences in the left ventricular cavity. Thus, eosinophilic endomyocarditis leads to endomyocardial fibrosis, a restrictive syndrome with small ventricles, while a chronic diffuse inflammatory process, such as Chagas' disease, causes dilated cardiomyopathy. Usually, Chagas' disease causes diffuse active inflammatory cardiomyopathy, while endomyocardial fibrosis is consequent to a previous inflammatory process located mainly in the inner portions of the ventricles. Consequently, in endomyocardial fibrosis, the scar is internal to an almost normal muscular layer, which protects the chamber from dilation. On the other hand, a previous thrombus may become fibrous, reducing the ventricular cavity. However, those 2 different types of cardiomyopathy have one point in common: apical involvement. In the dilated form of Chagas' disease, the apex seems thinner than the other walls, or with aneurysms of different sizes; in the restrictive form, it is thicker, and usually slightly hypokinetic. Probably, the tension in the wall is different in several regions of the left ventricular chamber. This needs to be better elucidated. In endomyocardial fibrosis, fibrosis may sometimes be apparent neither grossly nor on ventriculography. In addition, the histopathological findings of endomyocardial fibrosis show degenerative subendocardial alterations, which certainly justify the described alterations in motion.

Several studies have shown that that method allows the comparison of the effects of the surgical<sup>26,27</sup> and clinical treatment<sup>28</sup> for regional left ventricular wall motion. The next step is to compare wall motion in the pre- and postoperative periods in patients with endomyocardial fibrosis.

Our data may be useful for planning surgery and for analyzing the surgical results according to the type of ventricular involvement.

## Acknowledgments

We thank Nivaldo Bertozzo Jr for the acquisition of data of left ventricular image.

## References

1. Bedford DE, Konstam GLS. Heart failure of unknown aetiology in Africans. *Br Heart J* 1946;8:236-7.
2. Davies JNP. Pathology of Central African natives. *East African Med J* 1948;23:454-62.
3. Ball JD, Williams AW, Davies JNP. Endomyocardial fibrosis. *Lancet* 1954;22:1049-54.
4. Davies J, Spry CJF, Vijayaraghavan G, De Souza JA. A comparison of the clinical and cardiologic features of endomyocardial disease in temperate and tropical regions. *Postgraduate Med J* 1983;59:179-83.
5. Salemi VMC, Mady C. Aspectos clínicos e fatores prognósticos em pacientes com endomiocardiopatia. *Rev Soc Cardiol Estado de São Paulo* 2003;13:509-15.
6. Salemi VMC, Picard MH, Mady C. Assessment of diastolic function in endomyocardial fibrosis: value of flow propagation velocity. *Artif Organs* 2004;28:343-6.
7. Cherian G, Vijayaraghavan G, Krishnaswami S et al. Endomyocardial fibrosis: report on the hemodynamic data in 29 patients and review of the results of surgery. *Am Heart J* 1983;4:659-66.
8. Shaper AG, Hutt MSR, Coles RM. Necropsy study of endomyocardial fibrosis and rheumatic heart disease in Uganda 1950-1965. *Br Heart J* 1968;30:391-401.
9. Brindeiro Filho D, Cavalcanti C. O valor do EcoDopplercardiograma na identificação diagnóstica e no manuseio da endomiocardiopatia. *Arq Bras Cardiol* 1996;67:279-84.
10. Pereira Barretto AC, Mady C, Arteaga E et al. Quadro clínico da endomiocardiopatia. correlação com a intensidade da fibrose. *Arq Bras Cardiol*. 1988;50:401-5.
11. Dodge HT, Sandler H, Ballew BH, Load JD. The use of biplane angiocardiology for the measurement of left ventricular volume in man. *Am Heart J* 1960;60:762-76.
12. Sheehan FH, Dodge HT, Mathey D, Brown BG, Bolson EL, Mitten S. Application of the centerline method: Analysis of change in regional left ventricular wall motion in serial studies. *Comput Cardiol* 1982;3:97-100.
13. Sheehan FH, Bolson EL, Dodge HT, Mathey DG, Schofer J, Woo HW. Advantages and applications of the centerline method for characterizing regional ventricular function. *Circulation* 1986;74:293-305.
14. Toscano M, Calderolli DM, Moura L, Melo CP, Bellotti G, Pileggi F. A microcomputer-based system for the analysis of left ventricle function. *Automédica* 1992;15:163-75.
15. Sheehan FH, Stewart DK, Dodge HT, Mitten S, Bolson EL, Brown BG. Variability in the measurement of regional left ventricular wall motion from contrast angiograms. *Circulation* 1983;68:550-9.
16. Davies JNP. Pathology and pathogenesis of endocardial disease. *Cardiologia* 1963;42:161-75.
17. Mady C, Pereira-Barretto AC, Oliveira SA, Stolf N, Bellotti G, Pileggi F. Evolution of the endocardial fibrotic process in endomyocardial fibrosis. *Am J Cardiol* 1991;68:402-3.
18. Moraes CR, Buffolo E, Moraes-Neto F et al. Recidiva da fibrose após correção cirúrgica da endomiocardiopatia. *Arq Bras Cardiol* 1996;67:297-9.
19. Connor DH, Somers K, Hutt MSR, Maninon WC, D'Arbela PG. Endomyocardial fibrosis in Uganda (Davies' disease). An epidemiologic, clinical, and pathologic study. *Am Heart J* 1967;74:687-707.
20. Oliveira SA, Pereira-Barretto AC, Mady C et al. Surgical treatment of endomyocardial fibrosis: a new approach. *J Am Coll Cardiol* 1990;16:1246-51.
21. Schiller NB, Shah PM, Crawford M et al. Recommendations for quantitation of the left ventricle by two-dimensional echocardiography. American Society of Echocardiography Committee on Standards, Subcommittee on Quantitation of Two-Dimensional Echocardiograms. *J Am Soc Echocardiogr* 1989;2:358-67.
22. Sheehan FH, Bolson EL. Defining normal left ventricular wall motion from contrast ventriculograms. *Physiol Meas* 2003;24:785-92.
23. Laranja FS, Dia E, Nóbrega G, Miranda A. Chagas' disease: a clinical, epidemiologic and pathologic study. *Circulation* 1956;14:1035-60.
24. Carrasco HA, Barboza JS, Inglessis G, Fuenmayor A, Molina C. Left ventricular cineangiography in Chagas' disease: detection of early myocardial damage. *Am Heart J* 1982;104:595-602.
25. Acquatella H, Schiller NB, Puigbó JJ et al. M-mode and two-dimensional echocardiography in chronic Chagas' heart disease. *Circulation* 1980;62:787-99.
26. Bocchi EA, Moreira LF, de Moraes AV et al. Effects of dynamic cardiomyoplasty on regional wall motion, ejection fraction, and geometry of left ventricle. *Circulation* 1992;86 (5 Suppl):II 231-5.
27. Imamaki M, Maeda T, Tanaka S, Sugawara Y, Shimakura T. Prediction of improvement in regional left ventricular function after coronary artery bypass grafting: quantitative stress-redistribution 201Tl imaging in detection of myocardial viability. *J Cardiovasc Surg (Torino)*. 2002;43:603-7.
28. Amos DJ, French JK, Andrews J. Corrected TIMI frame counts correlate with stenosis severity and infarct zone wall motion after thrombolytic therapy. *Am Heart J* 2001;141:586-91.