



Original Article

Evaluation of treatment for camptodactyly: retrospective analysis on 40 fingers^{☆,☆☆}

Saulo Fontes Almeida, Anderson Vieira Monteiro, Rúbia Carla da Silva Lanes*

Instituto Nacional de Traumatologia e Ortopedia, Rio de Janeiro, RJ, Brazil

ARTICLE INFO

Article history:

Received 18 October 2012

Accepted 13 May 2013

Available online 15 March 2014

Keywords:

Hand deformities,
congenital/pathology
Hand deformities,
congenital/therapy
Fingers/abnormalities

ABSTRACT

Objective: to retrospectively assess the results from cases treated in the hand surgery service, starting from a preestablished protocol; and to conduct a critical analysis on the results achieved, with separation of the cases into their respective subgroups.

Methods: twenty-three patients and a total of 40 fingers were evaluated between January 2004 and December 2011. We correlated the altered anatomical structures found in the cases that underwent the surgical procedure and its results, with regard to both conservative and surgical treatment, emphasizing the main indications.

Results: the results were analyzed using the Sierget method of the Mayo Clinic.

Conclusion: we observed that the cases of camptodactyly of the little finger alone in the flexible form ($>60^\circ$) that underwent surgical treatment uniformly presented excellent results. In the rigid forms, our observations indicated that there were benefits comprising gains of extension and correction of the deformity. However, the range of motion with active flexion in the proximal interphalangeal joint was always partial. With evolution over time, some cases presented some loss of the gain previously achieved, which corroborates the need for continual vigilance during the follow-up, with systematic use of braces until the final phase of skeletal growth.

© 2014 Sociedade Brasileira de Ortopedia e Traumatologia. Published by Elsevier Editora Ltda. All rights reserved.

Avaliação do tratamento da camptodactilia: análise retrospectiva de 40 dígitos

R E S U M O

Objetivos: avaliar, retrospectivamente, os resultados dos casos tratados no serviço de Cirurgia da Mão, a partir de um protocolo preestabelecido; e fazer uma análise crítica dos resultados alcançados, com a separação dos casos em seus respectivos subgrupos.

Métodos: foram avaliados 23 pacientes, num total de 40 dígitos, de janeiro de 2004 a dezembro de 2011. Relacionamos as estruturas anatômicas alteradas encontradas nos casos que foram submetidos a procedimento cirúrgico e seus resultados, tanto no tratamento conservador como no cirúrgico, e enfatizamos suas principais indicações.

Palavras-chave:

Deformidade congênita da
mão/patologia
Deformidade congênita da
mão/terapia
Dedos/anormalidades

[☆] Please cite this article as: Almeida SF, Monteiro AV, Lanes RCS. Avaliação do tratamento da camptodactilia: análise retrospectiva de 40 dígitos. Rev Bras Ortop. 2014;49:134-139.

^{☆☆} Work performed at the Hand Surgery Center, Instituto Nacional de Traumatologia e Ortopedia, Rio de Janeiro, RJ, Brazil.

* Corresponding author.

E-mail: rubialanes@gmail.com (R.C.d.S. Lanes).

Resultados: os resultados foram analisados pelo método de Sierget da clínica Mayo.

Conclusão: observamos que os casos de camptodactilia isolada do dedo mínimo na forma flexível, >60°, que foram submetidos a tratamento cirúrgico de maneira uniforme apresentaram resultados excelentes. Nas formas rígidas, nossas observações indicam benefícios com ganho de extensão e correção da deformidade. Entretanto, o arco de movimento com flexão ativa na interfalângica proximal (IFP) é sempre parcial. Com o tempo de evolução, alguns casos apresentaram alguma perda do ganho previamente alcançado, o que corrobora a permanente vigilância necessária no acompanhamento, com uso sistemático de órteses, até a fase final do crescimento esquelético.

© 2014 Sociedade Brasileira de Ortopedia e Traumatologia. Publicado por Elsevier Editora Ltda. Todos os direitos reservados.

Introduction

Camptodactyly is a congenital deformity characterized by a flexed posture in the proximal interphalangeal joint. It is generally found in the little finger and may or may not include the other fingers. It is painless and nontraumatic.¹⁻⁹

It affects approximately 1% of the population.^{8,10} It is bilateral in around two thirds of the patients, although the degree of contracture is usually not symmetrical.^{8,11,12}

The deformity generally increases during growth spurts, especially during the periods of rapid growth from one to four years and from 10 to 14 years of age.^{5,11,13}

The primary cause of this deformity is still a matter for discussion and there is no consensus in the worldwide literature.^{3,4,8,10-13} Although some cases occur sporadically, there is often an autosomal inheritance pattern present.^{4,7,8,14}

The metacarpophalangeal and distal interphalangeal joints are unaffected, although they may develop compensatory deformities.¹²

According to Sierget et al.,⁷ camptodactyly can be divided into simple and complex types from a clinical point of view. The simple type consists of flexed contracture of the proximal interphalangeal joint. In complex camptodactyly, there are other associated deformities such as syndactyly or a combination of clinodactyly and camptodactyly.^{7,10} Glicenstein et al.¹⁵ classified camptodactyly into:

Primitive: when it appears in the first years of life. It affects both sexes in the same proportions and evolves with skeletal growth. It may also appear close to adolescence, with clear predominance in females. It is frequently bilateral. It is restricted to the little finger and progresses rapidly during the growth spurt.

Secondary: associated with syndromes and other malformations and normally involves more than one finger. The most frequent associations are: radial club hand, oculodentodigital syndrome, Marfan syndrome and arthrogryposis.^{15,16}

In 1994, Benson et al.¹⁷ classified camptodactyly as follows:

Type I: This is the commonest form and it becomes evident during childhood. It generally affects the little finger alone. It affects boys and girls equally.

Type II: Camptodactyly of adolescence, which occurs predominantly in females. Clinically, it resembles type I. It develops between the ages of seven and eleven years, starting subtly and evolving gradually and progressively. It affects girls

more than boys. This type of camptodactyly generally does not improve spontaneously and may evolve to severe flexed deformity.

Type III: This is present from the time of birth. It usually affects several fingers. It is constantly bilateral, with accentuated fixed forms. It is associated with a variety of syndromes and other malformations.^{8,12,16,17}

The degree of involvement between the hands is often asymmetrical.

In a general manner, the classifications have the aim of grouping different cases of camptodactyly and from this, to establish a treatment protocol.

Main problems and justifications

Several forms of treatment for camptodactyly have already been proposed. Many published studies have emphasized conservative treatment, while others have described surgical procedures.

The problem with this deformity is that several forms of presentation exist, which means that there is no single model for effective treatment (Fig. 1).

Objectives

The aim of this study was to retrospectively evaluate cases that had been treated at the Hand Surgery Service using a preestablished protocol, and to conduct a critical analysis on the results achieved.

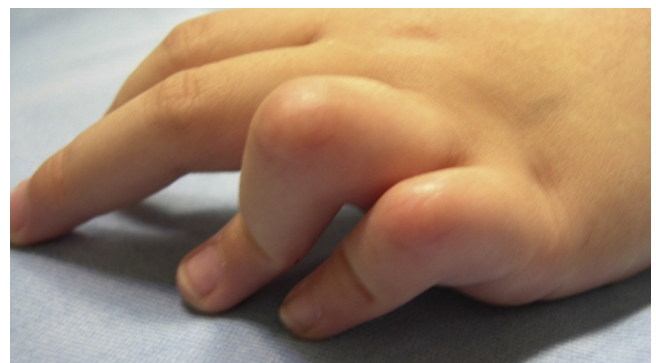

Fig. 1 – Camptodactyly in the ring and little fingers.

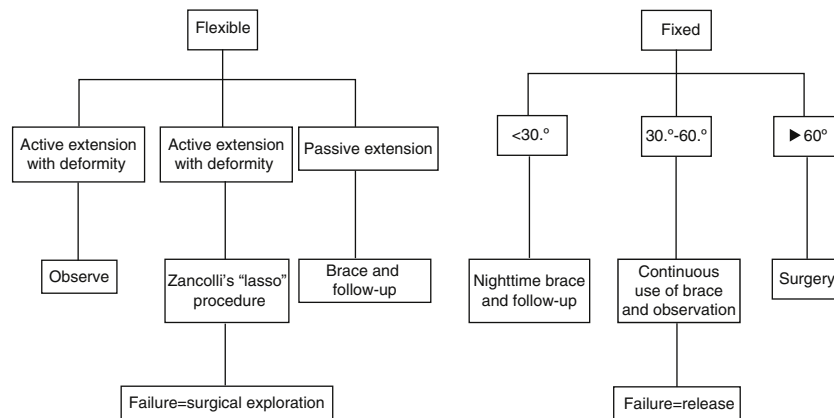


Fig. 2 – Flow diagram of the treatment.

Materials and methods

Twenty-three patients (40 fingers) who were treated at the Hand Surgery Service, Instituto Nacional de Traumatologia e Ortopedia, Rio de Janeiro, were selected.

All the patients had been treated and followed up by the supervisor in charge of this project and by the co-supervisor of the project since 2004, in conformity with the parameters preestablished in the treatment protocol described below.

We made an initial clinical assessment and divided the cases into reducible forms (flexible) and non-reducible forms (fixed), by means of a physical examination. Among the reducible cases, we divided the patients into two subgroups and proposed the following treatment:

If, through stabilization of the metacarpophalangeal joint, active extension of interphalangeal joint would become possible, we indicated conservative treatment for cases of less than 30° of deformity; for deformities greater than 30°, we indicated Zancolli's "lasso" procedure.

If, after correction of the deformity, extension of the interphalangeal joint would only be possible passively with flexion of the metacarpophalangeal joint, we instituted conservative treatment consisting of stretching exercises and use of braces. If conservative treatment failed, we would indicate surgical exploration, in order to search for anomalies in the superficial flexors and/or lumbricals.

Among the non-reducible cases, i.e. fixed forms, we divided the patients into three subgroups and proposed the following treatment:

Deformity less than 30°: the treatment was limited to observation, stretching exercises and use of a nighttime brace.

Deformity between 30° and 60°: conservative treatment, with continuous use of a brace and monitoring of the evolution of the deformity. In cases of failure, surgical treatment was instituted.

Deformity greater than 60°: in these severe cases, in which it was impossible to adequately fit a brace, we indicated surgical treatment, with en-bloc release of the structures of the volar face of the finger (Fig. 2).

We sought to correlate the altered anatomical structures found in the cases that underwent the surgical procedure; and to report the results from both conservative and conservative treatment.

We analyzed the results using the method of Sierget et al.,⁷ from the Mayo clinic:

Excellent: Full correction of extension with <15° loss of flexion of the interphalangeal joint.

Good: Correction with loss of up to 20° of extension and gain of extension of the interphalangeal joint >40°, with loss of flexion <30°.

Fair: Correction with loss of extension of up to 40° and gain of extension of the interphalangeal joint >20°, with loss of flexion <45°.

Poor: Correction with gain of extension of the interphalangeal joint <20°, with range of motion <40°. ^{5,7,8,12}

Results

Twenty-three patients were evaluated: 12 females (52.17%) and 11 males (47.82%) (Fig. 3).

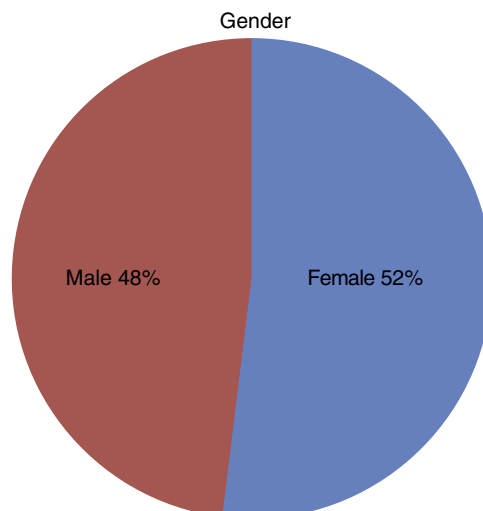


Fig. 3 – Distribution between the sexes.

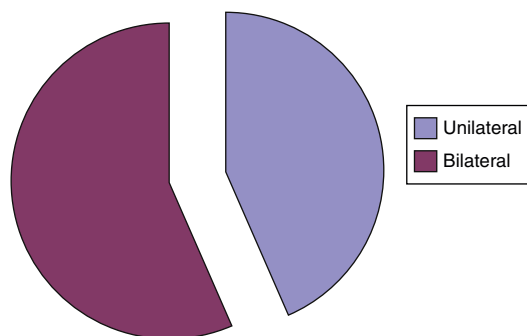


Fig. 4 – Bilateral versus unilateral impairment.

Thirteen patients (56.52%) were affected bilaterally. When patients were affected unilaterally, this occurred more frequently on the right side (56.5%) (Fig. 4).

The finger most affected was the little finger, with a total of 34 cases (85%); and the ring finger was in second place, in five cases (14.6%) (Fig. 5).

Ten patients were classified as Benson type I (42.5%), which was evident during infancy; eight as type II (35%), which developed between the ages of seven and eleven years; and only four patients as type III (10%), which had been present since birth (Fig. 6).

Out of the 40 fingers evaluated, 16 were reducible. With stabilization of the metacarpophalangeal joint, only one finger presented active extension of the interphalangeal joint, with deformity >30°. In this case, we indicated Zancolli's "lasso" procedure. During the operation, we encountered an abnormality in the lumbricals (Fig. 7). The result was excellent, with full correction of extension.

The other 15 fingers that were reducible only presented extension of the interphalangeal joint, with passive flexion of the metacarpophalangeal joint. In these cases, we instituted conservative treatment using braces (Fig. 8A and B) and stretching exercises.

In eight fingers, we obtained an excellent result and in two, a good result with loss of extension of not more than 20° and a gain of extension of the proximal interphalangeal joint of more than 40°, with loss of flexion of less than 30°.

Three patients abandoned the treatment and two fingers had poor results, with correction producing a gain of extension

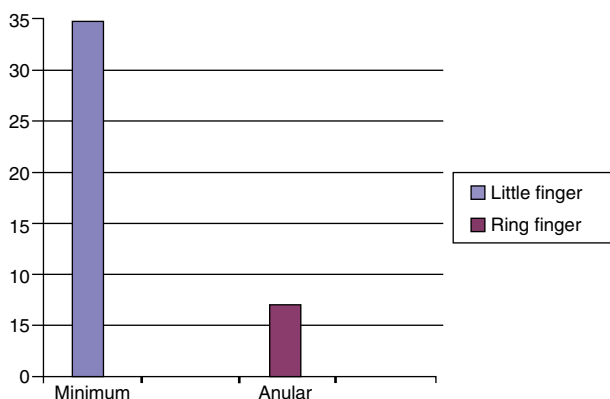


Fig. 5 – Finger most affected.

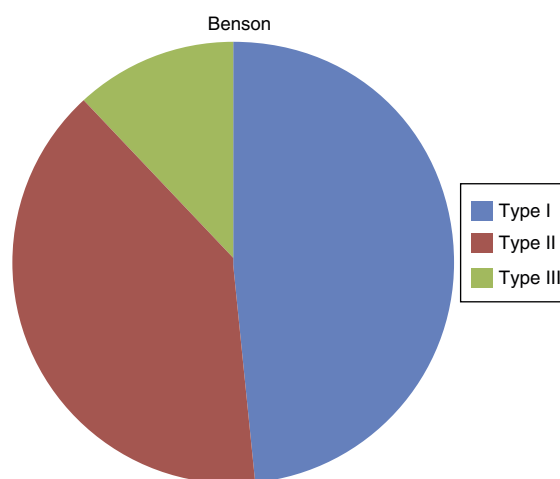


Fig. 6 – Distribution according to Benson classification.

of the proximal interphalangeal joint of less than 20°, with a range of motion of less than 40°. In these cases, we indicated surgical exploration. In both cases, we performed Zancolli's procedure. In one case, abnormal insertion of the lumbricals was found. One finger presented an excellent result, with full correction of extension, and the other evolved with scar retraction during the postoperative period.

The other 23 fingers were irreducible. One presented deformity of less than 30° and an excellent result was obtained through conservative treatment.

Fourteen patients presented deformities of between 30° and 60°. We instituted continuous use of braces and followed up the cases. Eight cases of deformity evolved with excellent results; two patients abandoned the treatment; and four evolved with a poor result and surgical exploration was indicated. Among these, the volar release technique was used in three cases, which produced excellent results in one case, with loss of flexion of the interphalangeal joint of less than 15° and full extension; and good results in two cases, with loss of flexion of the interphalangeal joint of less than 30°.

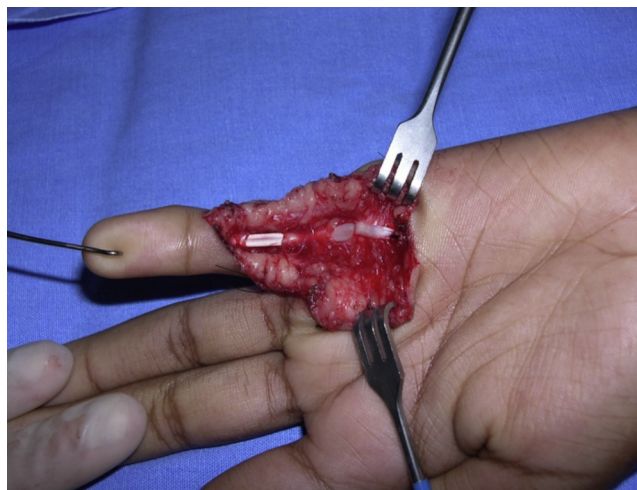


Fig. 7 – "Lasso" procedure.

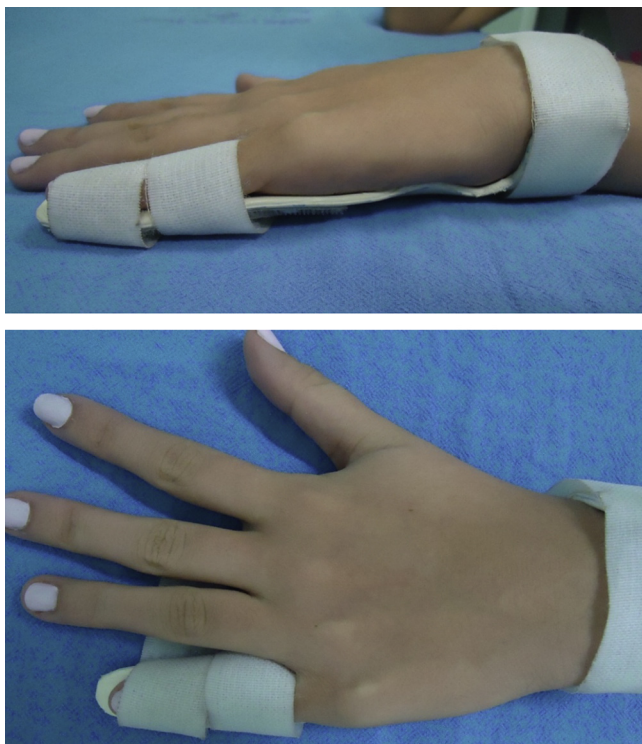

Fig. 8 – Brace.

During the surgical procedure, we found one case of abnormal insertion of the lumbricals and one with a hypoplastic superficial flexor.

Eight fingers presented deformities greater than 60° and en-bloc release of the structures of the volar face of the finger was indicated (Figs. 9 and 10).

In three fingers, abnormal insertion of the lumbricals was encountered. We obtained an excellent result in three cases of deformity and a good result in one finger. Three patients abandoned the treatment, even before the surgery, and one abandoned it after the surgical procedure.

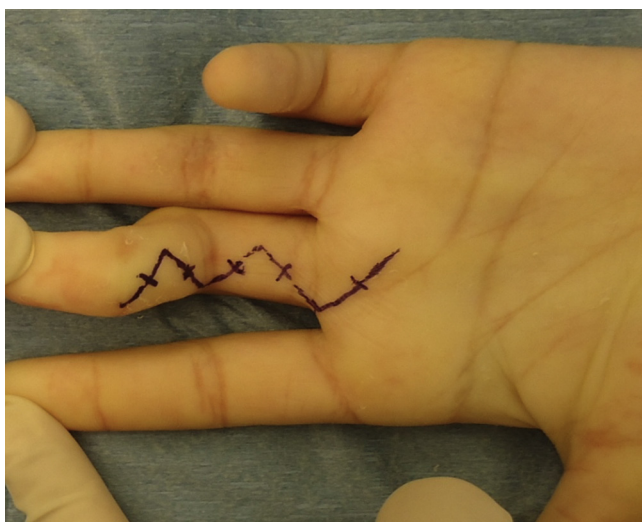


Fig. 9 – Volar access.

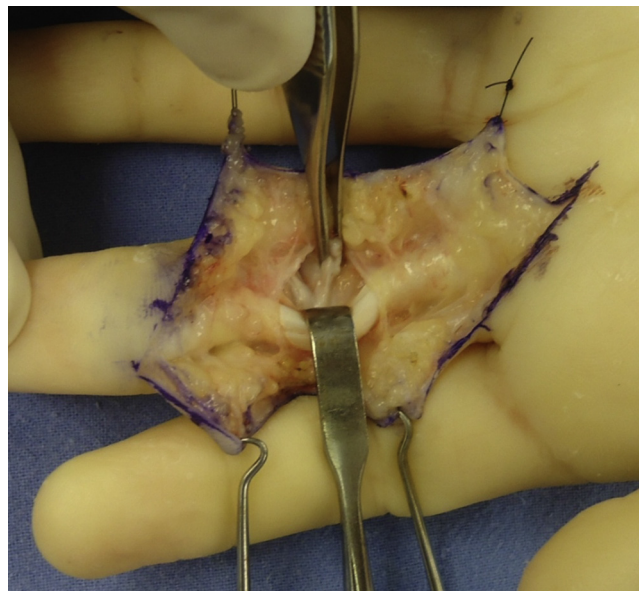


Fig. 10 – Release of volar structures.

Discussion

The degree of flexion of the proximal interphalangeal joint in camptodactyly cases is correctly assessed if the wrist and metacarpophalangeal joints are placed in neutral position. Deformities <30° do not require treatment, while those >60° interfere with function.

The radiographic assessment is done in the AP and lateral views of the finger, in order to examine the configuration of the proximal interphalangeal joint set. The alterations that can be observed and which are generally associated with severe contractures are widening of the base of the middle phalanx with a notch on its joint surface and a chiseled cut on the head of the proximal phalanx with flattening of its surface.^{8,18,19}

The clinical characteristics that should be observed and which guide the treatment are joint reducibility (flexibility) and the degree of deformity. The flexed posture of the proximal interphalangeal joint may be reducible, i.e. passively or actively flexible, or irreducible, i.e. fixed, when extension of the joint affected is not achieved.¹⁶ In most cases, the flexion movement is not affected.

This congenital deformity of relatively simple appearance has several types of presentation and is extremely difficult to treat.^{8,13} The family should be advised that the treatment is long and that follow-up throughout the skeletal growth period is necessary; moreover, after partial or total correction, relapses may occur.⁵

Many studies have demonstrated success through conservative treatment consisting of use of braces and stretching exercises.^{3,5,8,13} For smaller children, the brace should include the hand and the wrist. This brace is initially used during the maximum period of acceptance, with intervals for stretching exercises guided by therapists, until the deformity has been corrected.^{13,18} The importance of the parents with regard to correctly performing the exercises should not be

underestimated, because aggressive stretching could cause pain and tissue damage.⁵

At a later stage, to avoid recurrence, the brace is used for shorter periods during the day. However, nighttime use is maintained until the end of the skeletal growth period.^{8,12,13,16}

Surgical treatment is reserved for specific cases and in cases of failure of conservative treatment.^{3,5,7,8,13,16}

Bone abnormalities are not a contraindication for surgery, but the result expected will be greatly diminished.¹²

The surgical procedures can be described as those that attempt to identify a primary cause; those that attempt to rebalance the interphalangeal joint through transferring flexion force to the extensor surface; those that provide en-bloc release of all of the structures of the volar face in order to achieve correction; and bone procedures with dorsal-angle osteotomy of the neck of the proximal phalanx.^{3,16}

If active extension is possible, with correction of the deformity and placement of the metacarpophalangeal joint in slight flexion, the problem is found in stabilizing the metacarpophalangeal joint, in analogy with an ulnar claw. These cases would gain effective benefit from the "lasso" surgical procedure that was described by Zancolli apud Adams⁸ and McFarlane et al.¹⁹

If the deformity can only be reduced passively, with placement of the wrist or metacarpophalangeal joint in flexion, it can be assumed that the structure responsible for contraction crosses the joints above the flexor surface. The possibilities are that the lumbrical muscle has an abnormal origin or insertion, or that the superficial flexor is abnormally fixed.

Surgery to treat camptodactyly, especially in cases of severe contracture, has several complications, such as lesions of neurovascular structures, scar tension during extension and loss of flexion.

Incomplete extension is better tolerated than deficient flexion. Early mobilization should be instituted in order to promote restoration of flexion.^{8,10}

The return of the set of movements of the deep flexor of the fingers and the proximal interphalangeal joint is slow and may take six to twelve months in patients who are treated surgically.⁸

Conclusion

According to our observations from outpatient review consultations, we concluded that the cases of camptodactyly in the little finger alone, in the flexible form (>60°), which underwent surgical treatment in a uniform manner, presented excellent results.

In the rigid forms, our observations indicated that there were benefits relating to gains of extension and correction of the deformity. However, the range of motion with active flexion of the proximal interphalangeal joint was always partial, i.e. even in the cases with excellent results, there was an average loss of flexion of 15°.

Over time, some cases evolved to present some loss of the gain that had previously been achieved, which emphasizes the need for continual follow-up monitoring, with systematic use of braces, until the final phase of skeletal growth has been reached.

Conflicts of interest

The authors declare no conflicts of interest.

REFERENCES

- Foucher G, Loréa P, Khouri RK, Medina J, Pivato G. Camptodactyly as a spectrum of congenital deficiencies: a treatment algorithm based on clinical examination. *Plast Reconstr Surg*. 2006;117(6):1897-905.
- Eklblom AG, Laurell T, Arner M. Epidemiology of congenital upper limb anomalies in 562 children born in 1997-2007: a total population study from Stockholm, Sweden. *J Hand Surg Am*. 2010;35(11):1742-54.
- Medina J, Pajardi G. An algorithm for treatment of camptodactyly based on a review of 135 fingers treated in 109 patients. *J Hand Surg Br*. 1994;28:36.
- Minami A, Sakai T. Camptodactyly caused by abnormal insertion and origin of lumbrical muscle. *J Hand Surg Br*. 1993;18(3):310-1.
- Rhee SH, Oh WS, Lee HJ, Roh YH, Lee JO, Baek GH. Effect of passive stretching on simple camptodactyly in children younger than three years of age. *J Hand Surg Am*. 2010;35(11):1768-73.
- Goldfarb CA. Congenital hand differences. *J Hand Surg Am*. 2009;34(7):1351-6.
- Siegert JJ, Cooney WP, Dobyns JH. Management of simple camptodactyly. *J Hand Surg Br*. 1990;15(2):181-9.
- Adams BD. Congenital contracture. In: Wolfe SW, Hotchkiss RN, Pederson WC, Kozin SH, editors. *Green's operative hand surgery*. 6th ed. Philadelphia: Churchill Livingstone/Elsevier; 2011. p. 1443-51.
- Reichert B, Brenner P, Berger A. Considerations on etiology, correction and treatment of camptodactyly. *J Hand Surg Br*. 1994;19:9.
- Smith PJ, Grobbelaar AO. Camptodactyly: a unifying theory and approach to surgical treatment. *J Hand Surg Am*. 1998;23(1):14-9.
- Gupta A, Burke FD. Correction of camptodactyly. Preliminary results of extensor indicis transfer. *J Hand Surg Br*. 1990;15(2):168-70.
- Scott BD. Camptodactyly and clinodactyly in hand surgery. In: Berger RA, Weiss AP, editors. *Hand surgery*. Philadelphia: Lippincott Williams & Wilkins; 2004. p. 1478-91.
- Ogino T, Kato H. Operative findings in camptodactyly of the little finger. *J Hand Surg Br*. 1992;17(6):661-4.
- Oberg KC, Feenstra JM, Manske PR, Tonkin MA. Developmental biology and classification of congenital anomalies of the hand and upper extremity. *J Hand Surg Am*. 2010;35(12):2066-76.
- Monteiro AV, Almeida SF. Deformidades congênitas do membro superior. In: Pardini AG, Freitas A, editors. *Cirurgia da mão: lesões não traumáticas*. 2a. ed. Rio de Janeiro: Medbook; 2008. p. 206-8.
- Glicenstein J, Haddad R, Guero S. Surgical treatment of camptodactyly. *Ann Chir Main Memb Super*. 1995;14(6):264-71.
- Benson LS, Waters PM, Kamil NI, Simmons BP, Upton 3rd J. Camptodactyly: classification and results of nonoperative treatment. *J Pediatr Orthop*. 1994;14(6):814-9.
- Miura T, Nakamura R, Tamura Y. Long-standing extended dynamic splintage and release of an abnormal restraining structure in camptodactyly. *J Hand Surg Br*. 1992;17(6):665-72.
- McFarlane RM, Classen DA, Porte AM, Botz JS. The anatomy and treatment of camptodactyly of the small finger. *J Hand Surg Am*. 1992;17(1):35-44.