



## Original Article

# The arcade of Struthers: an anatomical study and clinical implications<sup>☆</sup>



Edie Benedito Caetano<sup>a,\*</sup>, João José Sabongi Neto<sup>b</sup>, Luiz Angelo Vieira<sup>a</sup>,  
Maurício Ferreira Caetano<sup>b</sup>

<sup>a</sup> Pontifícia Universidade Católica de São Paulo, Faculdade de Ciências Médicas e da Saúde, Departamento de Cirurgia, Sorocaba, SP, Brazil

<sup>b</sup> Conjunto Hospitalar de Sorocaba, Serviço de Cirurgia de Mão, Sorocaba, SP, Brazil

## ARTICLE INFO

## Article history:

Received 1 July 2016

Accepted 12 July 2016

Available online 9 May 2017

## Keywords:

Arm/anatomy & histology

Cadaver

Ulnar nerve

## ABSTRACT

**Objective:** To determine the frequency and features of the arcade of Struthers, and to assess its clinical implication in ulnar nerve compression.

**Method:** Forty arms from 26 cadaver specimens were dissected in the Anatomy Laboratory of this institution. The extension of the arcade, distance from the medial epicondyle, and relation with ulnar nerve were recorded.

**Results:** The arcade of Struthers was identified in 40 dissected arms (100%). In 29 (72.5%) the ulnar nerve was covered by a muscular arcade, in nine (22.5%) by an aponeurotic arcade, and in two (5%) the arcade was beneath the ulnar nerve. The extension of the arcade ranged from 3.0 to 7.5 cm, and the distance from the medial epicondyle ranged from 2.5 to 7.0 cm. **Conclusion:** The arcade of Struthers is a musculoaponeurotic canal that represents an important site of entrapment or compression of the ulnar nerve. The arcade, the intermuscular septum, and the internal brachial ligament should be released in patients submitted to ulnar nerve anterior transposition surgery.

© 2017 Published by Elsevier Editora Ltda. on behalf of Sociedade Brasileira de Ortopedia e Traumatologia. This is an open access article under the CC BY-NC-ND license (<http://creativecommons.org/licenses/by-nc-nd/4.0/>).

## Arcada de Struthers: estudo anatômico e implicações clínicas

## RESUMO

**Objetivo:** Determinar a frequência e as características anatômicas da arcada de Struthers e avaliar sua implicação clínica na neuropatia compressiva do nervo ulnar.

**Método:** Para este trabalho foram dissecados 40 membros de 26 cadáveres, pertencentes à disciplina de anatomia da instituição. A extensão da arcada, a distância da margem inferior da arcada ao epicôndilo medial do úmero e sua relação com o nervo ulnar foram registradas.

## Palavras-chave:

Braço/anatomia & histologia

Cadáver

Nervo ulnar

<sup>☆</sup> Study conducted at the Pontifícia Universidade Católica de São Paulo, Faculdade de Ciências Médicas e da Saúde, Departamento de Cirurgia, Sorocaba, SP, Brazil.

\* Corresponding author.

E-mail: [ediecaetano@uol.com.br](mailto:ediecaetano@uol.com.br) (E.B. Caetano).

<http://dx.doi.org/10.1016/j.rboe.2016.07.006>

2255-4971/© 2017 Published by Elsevier Editora Ltda. on behalf of Sociedade Brasileira de Ortopedia e Traumatologia. This is an open access article under the CC BY-NC-ND license (<http://creativecommons.org/licenses/by-nc-nd/4.0/>).

**Resultados:** A arcada de Struthers foi identificada nos 40 membros dissecados (100%), Em dois membros (5%), o nervo ulnar passava anteriormente à arcada. Em 29 (72,5%), uma porção variável do músculo tríceps cobria o nervo ulnar. Em nove membros (22,5%), o nervo estava coberto pela expansão aponeurótica do tríceps. A extensão da arcada variou de 3,0 a 7,5 cm e a distância da margem inferior da arcada ao epicôndilo medial variou de 2,5 a 7,0 cm.

**Conclusão:** A arcada de Struthers é um canal musculoponeurótico que representa importante local (potencial) de compressão do nervo ulnar. A arcada, o septo intermuscular medial e o ligamento braquial interno devem ser seccionados nos procedimentos cirúrgicos de transposição anterior do nervo ulnar no cotovelo.

© 2017 Publicado por Elsevier Editora Ltda. em nome de Sociedade Brasileira de Ortopedia e Traumatologia. Este é um artigo Open Access sob uma licença CC BY-NC-ND (<http://creativecommons.org/licenses/by-nc-nd/4.0/>).

## Introduction

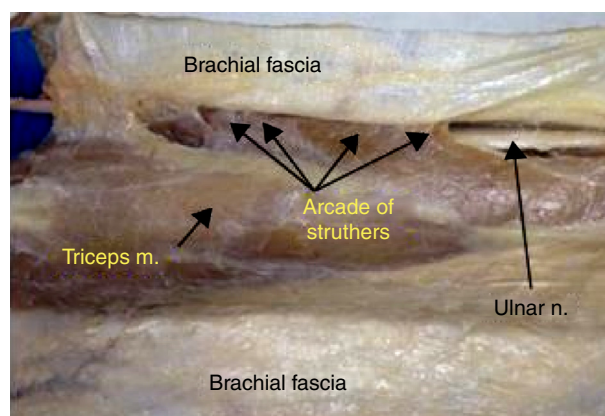
The Struthers' ligament and the arcade of Struthers are two anatomical structures that are often confused. The Struthers' ligament was described by anatomist John Struthers<sup>1</sup> in 1854; it is a fibrous band that extends from a bone spur located on the anteromedial surface of the lower third of the humerus, known as the supracondylar process, and is inserted in the medial humeral epicondyle. The Struthers' ligament passes over the median nerve and the brachial artery, which may cause compression of these structures. It may be observed even in the absence of the supracondylar process; even when present, it may not cause the compression of these structures. The supracondylar process of the humerus has been described by anatomists and anthropologists; it is phylogenetically considered as a vestige of the supracondylar foramen, found in reptiles, marsupials, and some mammals.<sup>2-4</sup> Its occurrence in humans is very rare, being observed in 0.7% to 2.5% of the population.<sup>2,5</sup> However, there is no dispute as to the existence of this ligament. In contrast, the arcade of Struthers was first described in 1973 by Kane et al.<sup>6</sup> It is sometimes defined as a thickening of the brachial fascia, and sometimes as an aponeurotic or musculoponeurotic structure extending from the medial intermuscular septa to the medial head of the triceps brachii muscle at a variable distance above the medial humeral epicondyle.

The arcade of Struthers can cause compression of the ulnar nerve. Controversy exists in the literature regarding the existence of the arcade of Struthers. Some anatomical studies have found an anatomical formation consistent with the arcade of Struthers. Conversely, other studies have reported that the arcade of Struthers does not exist; rather, that there are only anatomical variations of the intermuscular septum and the forearm fascia.<sup>7-9</sup>

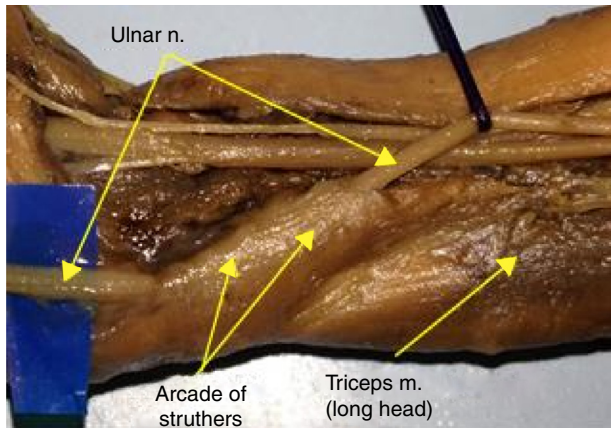
This study aimed to analyze the anatomical structures that relate to the ulnar nerve in the medial aspect of the arm, such as the brachial fascia, the medial intermuscular septum, the internal brachial ligament, and the medial head of the triceps brachii muscle, and to assess the possibility of these structures being responsible for the compressive syndrome of the ulnar nerve or even whether they can interfere after surgical procedures of anterior transposition of the ulnar nerve at the elbow.

## Material and methods

40 arms of 26 adult cadavers of the Anatomy Department of this institution were dissected; 14 bilateral (prepared with formalin solution and glycerin), and 12 only the right upper limb (dissected from fresh cadavers). Of the corpses, 22 were male and four were female, 15 were white and 11 were non-white. Cadavers whose forearms were deformed by traumas, malformations, and scars were excluded. The dissection was performed through an incision in the anteromedial aspect of the arm (from the axilla to the middle third of the forearm). Two flaps that included the skin and the subcutaneous tissue were pulled away, exposing the entire medial surface of the arm. The brachial fascia, basilic hiatus, basilic vein, and the medial cutaneous nerve of the forearm were identified. The brachial fascia was incised longitudinally in the medial margin of the triceps brachii muscle in the same manner that the skin was folded, one anterior flap and one posterior flap (Fig. 1). The ulnar nerve was identified in the axillary region and dissected distally to the medial intermuscular septum, which it crosses, passing from the anterior to the posterior compartment of the arm. In this location, the internal brachial ligament can also be identified. Then, the ulnar nerve was identified distally in the



**Fig. 1 – The brachial fascia was incised longitudinally in the medial margin of the triceps brachii muscle and in the same way in which the skin was folded, with an anterior flap and a posterior flap.**

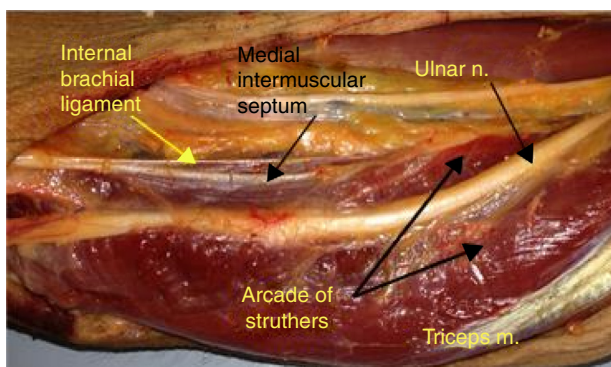


**Fig. 2 – Stillborn arm dissected as a pilot, showing the ulnar nerve surrounded by the medial head of the triceps.**

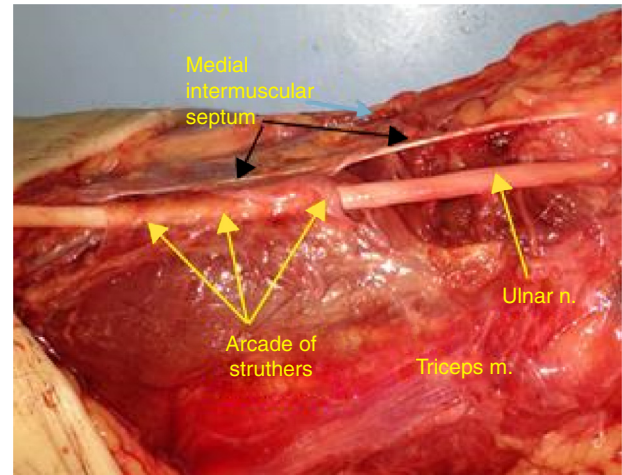
epicondilar-olecranon groove and dissected proximally until it was covered by the medial head of the triceps brachii muscle or by its aponeurosis (which corresponds to the distal edge of the arcade of Struthers). The distance from the arcade to the medial epicondyle and the length of the arcade were measured. Four limbs of two stillborns were dissected as a pilot for familiarization with the structures of the medial aspect of the arm, and were not included in this study (Fig. 2). A Keller brand 2.5X magnifying glass was used for magnification. This study was approved by the Research Ethics Committee of the institution under the number 1.558.501.

## Results

In this study, the arcade of Struthers was defined as a fibrous canal on the medial aspect of the middle- and lower-third of the arm, consisting of the medial head of the triceps brachii muscle and its aponeurotic expansion, which extends into the intermuscular septum and internal brachial ligament and covers part of the ulnar nerve (Fig. 3). The arcade of Struthers was identified in 40 limbs (100%). In two limbs (5%), the ulnar nerve passed anteriorly to the arcade (Fig. 4). In 29 limbs (72.5%), a

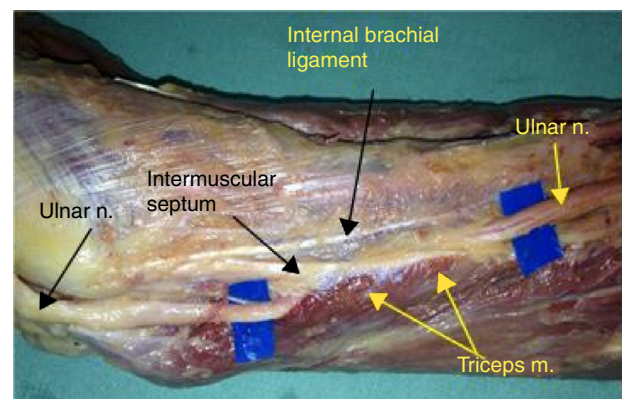


**Fig. 3 – In two limbs (5%), the arcade of Struthers, consisting of the triceps brachii muscle, extended into the intermuscular septum. It passed posteriorly to the ulnar nerve.**



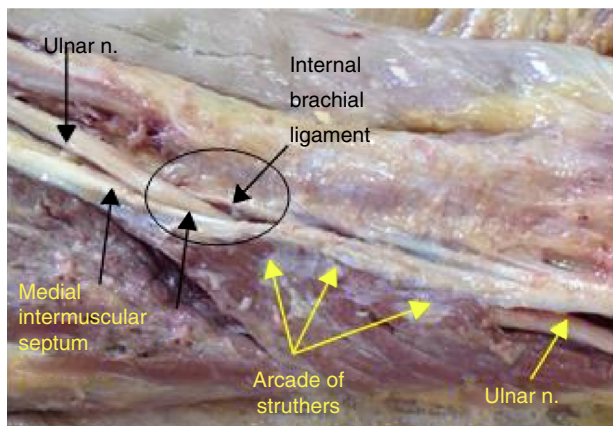
**Fig. 4 – In nine limbs (22.5%), the nerve was covered by a fibrous canal (arcade of Struthers) consisting of the aponeurotic expansion of the triceps, which extended into the intermuscular septum and covered part of the ulnar nerve.**

variable portion of the triceps muscle covered the ulnar nerve (Figs. 1 and 3), and in nine limbs (22.5%) the nerve was covered by the aponeurotic expansion of the triceps brachii (Fig. 5). The length of the arcade ranged from 3.0 to 7.5 cm and the distance from lower limit of the arcade to the medial epicondyle ranged from 2.5 to 7.0 cm. The internal brachial ligament (Fig. 6) was observed in 26 limbs (65%), often originating proximally in the intermuscular septum and attached to it near the medial epicondyle. The authors believe that, in most cases, it represents an unfolding of the intermuscular septum (Fig. 6). The intermuscular septum divides the arm into anterior and posterior compartments. The ulnar nerve passes from the anterior to the posterior compartment at the opening of the Struthers arcade. In four limbs (10%), it was observed that the arcade's entrance (proximally) consisted of a V-shaped channel between the medial intermuscular septum and the internal brachial ligament (Fig. 7). When tractioning the nerve proximally and distally, it was observed that it moved



**Fig. 5 – The internal brachial ligament recorded in 26 limbs (65%), often originating proximally in the intermuscular septum and merging to it near the medial epicondyle.**



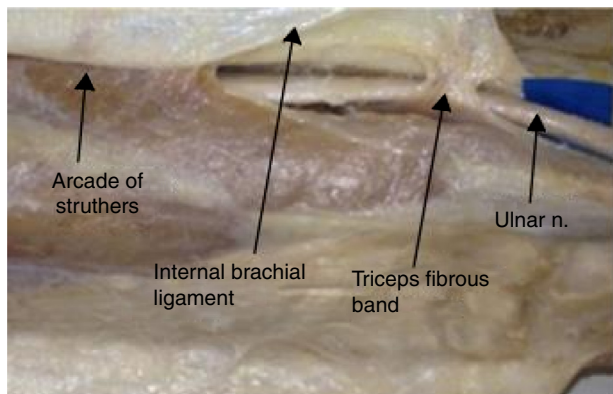


**Fig. 6 – The ulnar nerve passes from the anterior to the posterior compartment at the opening of the arcade of Struthers. In four limbs (10%), it was observed that the entrance (proximal) of the arcade consisted of a V-shaped canal between the medial intermuscular septum and the internal brachial ligament.**

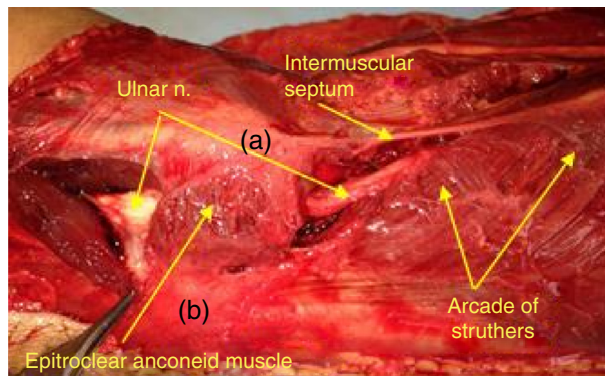
easily within the arch, which was sectioned at the end of the dissection, and it was not possible to identify any points within it that showed any signs of nerve compression. In two limbs, an additional fibrous band was identified near the medial epicondyle (Fig. 8). In one limb, an accessory portion of the medial triceps head that was inserted into the intermuscular septum was identified; another limb presented the anconeus epitrochlearis muscle (Fig. 9).

**Discussion**

The literature review indicates that the arcade of Struthers is still a controversial structure. Some authors confirm its existence,<sup>10-13</sup> while other publications do not consider the arcade to be a compression site, proposing that the term arcade of Struthers should be abandoned.<sup>8,14</sup> De Jesus and Dellon<sup>15</sup> state that Struthers never described this anatomical structure. The main classical treatises of the literature do not consider the arcade of Struthers.<sup>16,17</sup>

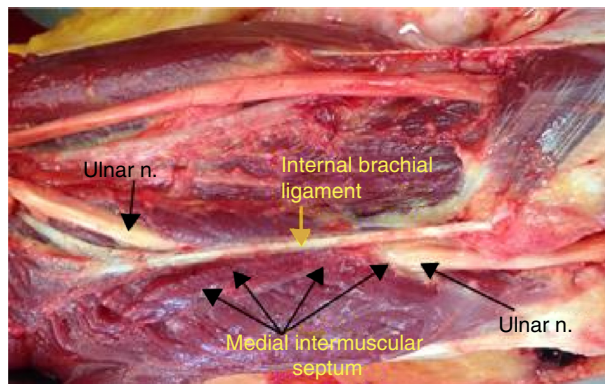


**Fig. 7 – In two limbs, an additional fibrous band was identified near the medial epicondyle.**

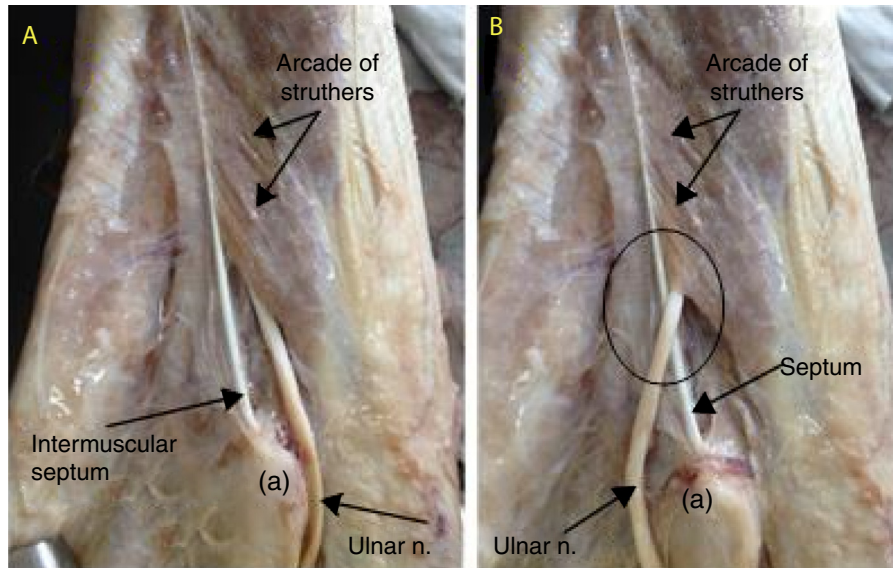


**Fig. 8 – In one limb, the presence of epitrochlear anconeus muscle was observed. Medial epicondyle (a). Olecranon (b).**

The concept of arcade of Struthers was created by Kane et al.<sup>6</sup> in 1973. Those authors identified the arcade in 14 of 20 dissected limbs (70%). Al Qattan and Murray<sup>10</sup> observed similar results, identifying the arcade of Struthers in 17 of 25 fresh cadavers (68%). These authors described the arcade similarly to Kane et al.,<sup>9</sup> but reported that in five limbs the internal brachial ligament was represented by multiple ligaments. Wehrli and Oberlin<sup>9</sup> observed the presence of multiple ligaments, which passed over the ulnar nerve, in six of 30 dissected limbs. Amadio and Bekenbaugh<sup>18</sup> confirmed the findings of Kane et al.<sup>6</sup>; after dissecting 20 limbs from corpses, they found the arcade of Struthers as described by Kane et al.<sup>6</sup> in all of them (100%; 6 to 10 cm proximal to the medial epicondyle, 1.5 to 2 cm wide). Gonzalez et al.<sup>12</sup> reported the arcade of Struthers in 26 out of 39 dissected arms (67%), located on average 8.2 cm proximal to the medial epicondyle. Siqueira and Martins<sup>7</sup> observed the arcade in eight of 60 dissected limbs (13.5%), with a mean 3.75 cm thickness, located on average 6.82 cm proximal to the medial epicondyle. Bartel et al.<sup>8</sup> did not identify brachial fascia thickening when assessing ten limbs. Dellon<sup>14</sup> dissected 104 arms from 64 corpses and observed that the band that could be identified as the arcade of Struthers was not found, and that in more than 300 proce-



**Fig. 9 – Arcade of Struthers: a fibrous canal consisting of the medial head of the triceps brachii muscle and its aponeurotic expansion, which extended into the intermuscular septum. The internal brachial ligament covered part of the ulnar nerve.**



**Fig. 10 – The arcade of Struthers may be responsible for recurrence of compressive neuropathy of the ulnar nerve after anterior transposition of the nerve at the elbow. (A) Nerve in the sulcus between the olecranon and medial epicondyle. (B) Post anterior transposition.**

dures on the ulnar canal never, it was not possible to identify any structure in this region that could cause its compression. However, in 16 limbs (25%), the ulnar nerve was partially or totally covered by the medial triceps head. Von Schroeder and Scheker<sup>19</sup> reported that the arcade of Struthers and the intermuscular septum were identified in 11 (100%) corpses dissected. It consisted of a osteofibrous channel, narrower in its proximal opening, which is a clinically relevant location that can be the cause of compressive neuropathy of the ulnar nerve; this is a fiber channel measuring 5 to 7 cm, comprising the intermuscular septum, the internal brachial ligament, and the triceps muscle and its fascia. Those authors described that the proximal arcade is composed of a canal between the intermuscular septum and the internal brachial ligament, which is considered to be the narrowest site of the arcade.

The discrepancy in the results can be attributed to the definition of arcade of Struthers. The definition adopted in the present study is close to that described by Von Schoeder and Scheker.<sup>19</sup> The arcade of Struthers was defined as a fibrous canal on the medial side of the middle- and lower-third of the arm formed by an expansion of the medial head of the triceps muscle and its aponeurotic expansion, which extends to the intermuscular septum and the internal brachial ligament and covers part of the ulnar nerve. The arcade of Struthers was observed in 40 limbs (100%); in 29 (72.5%), a variable portion of the triceps muscle covered the ulnar nerve (Figs. 1 and 3). In two (5%), the ulnar nerve was positioned anteriorly to the arch (Fig. 4). In nine limbs (22.5%), the ulnar nerve was covered by the aponeurotic expansion of the triceps (Fig. 5). The length of the arcade ranged from 3 to 7.5 cm and the distance from the lower limit of the arcade to the medial epicondyle ranged from 2.5 to 7 cm. The presence of multiple ligaments was not observed in the dissected limbs.

Wehrli and Oberlin<sup>9</sup> report that, in 1854, Struthers described the intermuscular septum and coined the term internal brachial ligament, described as a whitish fibrous band

positioned posteriorly to the intermuscular septum, merging to it near the medial epicondyle; this ligament was considered to be independent of the intermuscular septum. Wehrli and Oberlin<sup>9</sup> recorded the existence of this ligament in 22 of 30 dissected arms (73%), but disagree with Struthers, as they consider this ligament to be an unfolding of the intermuscular septum. In the present study, the internal brachial ligament was observed in 26 limbs (65%); as Wehrli and Oberlin,<sup>9</sup> the authors believe that it represents an unfolding of the intermuscular septum. The intermuscular septum divides the arm into anterior and posterior compartments. The ulnar nerve passes from the anterior to the posterior compartment at the opening of the Struthers arcade. In four limbs (10%), it was observed that the entrance (proximal) of the arcade consisted of a V-shaped canal between the medial intermuscular septum and the internal brachial ligament (Fig. 7), as was observed by Von Schoerer and Scheker.<sup>19</sup>

When pulling the nerve proximally and distally, it was observed that it moved easily within the arcade; the same observation was made by Von Schoerer and Scheker.<sup>19</sup> The arcade was sectioned at the end of the dissection and no points within it that showed any signs of nerve compression were observed. However, the authors believe that this structure may be responsible for nerve compression in limbs where the medial head of the triceps was well developed and covered a large segment of the nerve, as well as in limbs where the entrance (proximal) of the arcade consisted of a V-shaped canal between the medial intermuscular septum and the internal brachial ligament.

The authors agree with Al Qattan and Murray<sup>10</sup> and Spinner and Kaplan<sup>13</sup> that the arcade of Struthers, the medial intermuscular septum, and the internal brachial ligament may be responsible for recurrence of compressive ulnar nerve neuropathy after its anterior transposition in the elbow. Altering the nerve pathway can push it against the intermuscular septum (Fig. 10). The nerve should be dissected

distally and proximally to the medial epicondyle; it must be totally released, until it can be ensured that no structure could cause relapse of the nervous compression.

---

## Conclusion

The arcade of Struthers may be the primary cause of the compressive ulnar nerve syndrome, but it may be mainly responsible for the recurrence of compressive neuropathy of the ulnar nerve after the anterior transposition of the nerve in the elbow; therefore, it is recommended to resect the structures (the arcade, the medial intermuscular septum, and the internal brachial ligament) that may compress the nerve after this procedure.

---

## Conflicts of interest

The authors declare no conflicts of interest.

---

## REFERENCES

1. Struthers J. On some points in the abnormal anatomy of the arm. *Br Foreign Med Chir Rev.* 1854;14:170-9.
2. Terry RJ. On the supracondyloid variations in the negro. *Am J Phys Anthropol.* 1923;6:401-3.
3. Terry RJ. On the racial distribution of the supracondyloid variation. *Am J Phys Anthropol.* 1930;14:459-62.
4. Barnard LB, McCoy SM. The supracondyloid process of the humerus. *J Bone Joint Surg Am.* 1946;28:845-50.
5. Gunther SF, DiPasquale D, Martin R. Internal anatomy of the median nerve in the region of the elbow. *J Hand Surg Am.* 1992;17:648-56.
6. Kane E, Kaplan EB, Spinner M. Observations on the course of the ulnar nerve in the arm. *Ann Chir.* 1973;27:487-96.
7. Siqueira MG, Martins RS. The controversial arcade of Struthers. *Surg Neurol.* 2005;64:17-21.
8. Bartels RHMA, Grotenhuis JA, Kaver JMG. The arcade of Struthers: an anatomical study. *Acta Neurochir (Wien).* 2003;145:295-300.
9. Wehrli L, Oberlin C. Internal brachial ligament of Struthers vs. the so-called arcade of Struthers. *J Reconstr Microsurg.* 2004;20:340-1.
10. Al-Qattan MM, Murray KA. The arcade of Struthers: an anatomical study. *J Hand Surg Br.* 1991;16:311-4.
11. Caputo AE, Watson HK. Subcutaneous transposition of the ulnar nerve for failed decompression of cubital tunnel syndrome. *J Hand Surg Am.* 2000;25:544-51.
12. Gonzales MH, Lofti P, Bendre A, Mandelbroyt Y, Lieska N. The ulnar nerve at the elbow and its local branching: an anatomic study. *J Hand Surg Br.* 2001;26:142-4.
13. Spinner M, Kaplan EB. The relationship of the ulnar nerve to the medial intermuscular septum in the arm and its clinical significance. *Hand.* 1976;8:239-42.
14. Dellon AL. Musculotendinous variations about the medial humeral epicondyle. *J Hand Surg Br.* 1986;11:175-81.
15. De Jesus R, Dellon AL. Historic origin of the arcade of Struthers. *J Hand Surg Am.* 2003;28:528-31.
16. Testut L. Les anomalies musculaires chez l'homme. Paris: Masson; 1884. p. 454-89.
17. Le Double AF. Traité des variations du système musculaire de l'homme et de leur signification au point de vue de l'anthropologie zoologique. Paris: Schleicher Frères; 1897. p. 99-107.
18. Amadio PC, Bekenbaugh RD. Entrapment of ulnar nerve by the deep flexor pronator aponeurosis. *J Hand Surg Am.* 1986;1:83-7.
19. Von Schroeder HP, Scheker LR. Redefining the arcade of Struthers. *J Hand Surg Am.* 2003;28:1018-21.