


Comparison of Wear Rate between Ceramic-on-Ceramic, Metal on Highly Cross-linked Polyethylene, and Metal-on-Metal Bearings*

Comparação da taxa de desgaste entre componentes de cerâmica sobre cerâmica, metal sobre polietileno de alta ligação cruzada e metal sobre metal

Yoshitoshi Higuchi¹  Taisuke Seki¹ Daigo Morita¹ Daigo Komatsu¹ Yasuhiko Takegami¹
Naoki Ishiguro¹

¹ Department of Orthopedic Surgery, Nagoya University Graduate School of Medicine, Tsurumai-cho, Showa-ku Nagoya, Japan

Address for correspondence Yoshitoshi Higuchi, Department of Orthopedic Surgery, Nagoya University Graduate School of Medicine, 65 Tsurumai-cho, Showa-ku Nagoya, Japan 466-8550 (e-mail: rdggd215@yahoo.co.jp).

Rev Bras Ortop 2019;54:295–302.

Abstract

Objective Currently, there is a lack of evidence on the medium-term follow-up of cementless total hip arthroplasty (THA) using metal on highly cross-linked polyethylene (MoP), ceramic-on-ceramic (CoC), and metal-on-metal (MoM) bearings. Our aim was to calculate the 5- to 10-year wear rate and the incidence rate of osteolysis for 3 types of bearings.

Methods A total of 77 patients underwent MoP, 105 underwent ceramic CoC, and 55 underwent MoM THAs. The average patient age at the time of surgery was 64.7, 55.9, and 59.9 years old in the MoP, CoC, and MoM bearings, respectively. Clinical and radiologic measurements at a mean follow-up of 7.6 years were analyzed.


Results The mean postoperative Harris hip scores showed no difference among the groups. The mean annual liner wear rates were 0.0160, 0.0040 and 0.0054 mm/year in MoP, CoC bearings, and MoM bearings, with that of CoC bearings being significantly lower than the others. Osteolysis (14.5%) among MoM bearings was significantly more frequently observed compared with the others. Kaplan-Meier survival at 10 years with implant loosening, or revision THA as the endpoint, was 96.1% (95% confidence interval [CI]: 88.4–98.7) for MoP, 98.6% (95% CI: 90.3–98.6) for CoC bearing, and 98.2% (95% CI: 88.0–99.7) for MoM bearings ($p = 0.360$).

Conclusion Excellent clinical and radiological outcomes were obtained for MoP and CoC bearings.

Keywords

- ▶ arthroplasty
- ▶ ceramics
- ▶ metals
- ▶ polyethylenes
- ▶ prosthesis design

* The present study was conducted at the Department of Orthopedic Surgery of the Nagoya University Graduate School of Medicine, Tsurumai-cho, Showa-ku Nagoya, Japan.

 Yoshitoshi Higuchi's ORCID is <https://orcid.org/0000-0002-1112-2682>.

Resumo

Objetivo Hoje, não há evidências sobre o acompanhamento em médio prazo da artroplastia total do quadril não cimentada com componentes de polietileno de alta ligação cruzada (*highly cross-linked*) sobre metal, cerâmica sobre cerâmica e metal sobre metal. Nosso objetivo foi calcular a taxa de desgaste em 5 a 10 anos e a taxa de incidência de osteólise nos três tipos de componentes.

Métodos Setenta e sete pacientes foram submetidos à artroplastia total de quadril com componentes de polietileno de alta ligação cruzada sobre metal, 105 foram submetidos ao mesmo procedimento com componentes de cerâmica sobre cerâmica e 55 foram submetidos à artroplastia total quadril com componentes de metal sobre metal. A média de idade dos pacientes no momento da cirurgia foi de 64,7, 55,9 e 59,9 anos nos grupos de componentes de polietileno de alta ligação cruzada sobre metal, cerâmica sobre cerâmica e metal sobre metal, respectivamente. As medidas clínicas e radiológicas em um período médio de acompanhamento de 7,6 anos foram analisadas.

Resultados As pontuações médias de Harris no período pós-operatório não mostraram diferença entre os grupos. As taxas médias anuais de desgaste do revestimento foram de 0,0160, 0,0040 e 0,0054 mm/ano em componentes de polietileno de alta ligação cruzada sobre metal, cerâmica sobre cerâmica e metal sobre metal; a taxa de desgaste dos componentes de cerâmica sobre cerâmica foi significativamente menor do que as demais. A osteólise (14,5%) nos componentes de metal sobre metal foi significativamente mais frequente em comparação aos demais. A sobrevida de Kaplan-Meier aos 10 anos com afrouxamento do implante ou revisão da artroplastia total do quadril como desfecho foi de 96,1% (intervalo de confiança de 95% [IC95%]: 88,4–98,7) nos componentes de polietileno de alta ligação cruzada sobre metal, 98,6% (IC95%: 90,3–98,6) nos componentes de cerâmica sobre cerâmica e 98,2% (IC95%: 88,0–99,7) nos componentes de metal sobre metal ($p = 0,360$).

Conclusão Os resultados clínicos e radiológicos de componentes de polietileno de alta ligação cruzada sobre metal e cerâmica sobre cerâmica foram excelentes.

Palavras-chave

- ▶ artroplastia
- ▶ cerâmicas
- ▶ metais
- ▶ polietilenos
- ▶ desenho de próteses

Introduction

Total hip arthroplasty (THA) for patients with end-stage osteoarthritis of the hip aims at ensuring long-lasting pain relief.^{1,2} However, despite improved implant designs and surgical techniques, aseptic loosening and osteolysis due to particulate debris, generated from conventional polyethylene, have become major limitations to long-term survival of prosthetics.^{3–6} Osteolysis has been reported in up to 60% of young, active patients with conventional polyethylene.⁶ In an attempt to avoid problems caused by wear-related debris, various types of bearing surfaces have been designed, such as metal on highly cross-linked polyethylene (MoP), a bearing-surface interaction with reduced linear and volumetric wear in comparison with conventional polyethylene.^{3,4,6,7} Similarly, hard bearing surfaces, which ensure even lower levels of volumetric wear, such as ceramic-on-ceramic (CoC) and metal-on-metal (MoM), have also been developed to address the problem of osteolysis.

However, they have their own inherent limitations, such as ceramic fractures and squeaking, or adverse local tissue reaction (ALTR).^{1,2,6,8} Over the last 2 decades, several systematic reviews and many clinical randomized controlled trials comparing the survivorship of THA implants with different bearing

surfaces have been published. However, the results of these studies are inconsistent and continue to be debated.^{2,6,8–11}

Therefore, the aim of our study was to perform a retrospective evaluation of the clinical and radiographic outcomes between MoP, CoC, and MoM cementless THAs over a 5- to 10-year follow-up period to compare the wear rates and the incidence of osteolysis.

Methods

Patient Selection

Between August 2007 and December 2011, we performed consecutive primary CoC, MoP, or MoM THAs, with the type selected based on the recommendation of the senior surgeon performing the procedure. In total, 220 patients (237 THAs), who completed a minimum follow-up period of 5 years, were eligible for the present study. The exclusion criteria were: death from causes unrelated to surgery (one patient; one joint), patient inaccessibility (five patients moved abroad; five joints) and Crowe group III/IV hips (three patients; three joints). No significant differences were noted between the groups with regard to gender, body mass index (BMI), or diagnosis (▶ **Table 1**). However, the age of the patients at the time of the surgery for the group who received CoC THAs was

Table 1 Patient demographics

| Parameters | MoP (n = 77) | CoC (n = 105) | MoM (n = 55) | p-value |
|--|---------------------------|---------------------------|---------------------------|-----------|
| Age (years old) (range) | 64.7 ± 9.7 (29–76) | 55.9 ± 8.7 (28–76) | 59.9 ± 10.8 (33–74) | < 0.001*† |
| Gender (male/female) | 9/68 | 20/85 | 11/44 | 0.320 |
| Body mass index (kg/m ²) (range) | 23.1 ± 3.2 (15.6–31.2) | 23.0 ± 3.5 (16.7–31.9) | 23.3 ± 3.4 (18.3–35.1) | 0.849 |
| Follow up (years) (range) | 7.0 ± 1.0 (5–10) | 7.0 ± 1.1 (5–10) | 7.6 ± 1.1 (5–10) | 0.466 |
| Diagnosis (n, %) | | | | 0.769 |
| Osteoarthritis | 73 (94.8%) | 93 (88.6%) | 50 (90.9%) | |
| Avascular necrosis | 4 (5.2%) | 11 (10.5%) | 5 (5.1%) | |
| Post-traumatic osteoarthritis | 0 | 1 (0.9%) | 0 | |
| Implants | | | | |
| Cementless Cup | | | | |
| Trident PSL | 24 (31.2%) | 22 (21.0%) | NA | |
| TriAD HA | 53 (68.8%) | 74 (70.5%) | NA | |
| Secur Fit AD | NA | 9 (8.5%) | NA | |
| Pinnacle-A | NA | NA | 55 (100%) | |
| Cementless Stem | | | | |
| Super Securfit HA | 77 (100%) | 105 (100%) | NA | |
| G2 stem | NA | NA | 55 (100%) | |
| Fomoral head diameter | | | | |
| 22 mm | 7 (9.1%) | NA | 0 | |
| 26 mm | 70 (91.9%) | NA | 0 | |
| 28 mm | 0 | 67 (63.8) | 28 (50.9%) | |
| 32 mm | 0 | 38 (36.2) | NA | |
| 36 mm | 0 | 0 | 27 (49.1%) | |

Abbreviations: BMI, Body mass index; CoC: ceramic-on-ceramic; MoM: metal-on-metal; MoP: metal on highly cross-linked polyethylene; NA, Not available. All of the values are given as the mean and standard deviation.

*CoC THAs vs MoM THAs $p < 0.001$.

†CoC THAs vs MoP THAs $p < 0.001$.

significantly lower than that of the other groups. Informed consent was obtained from all of the patients, and the present study was approved by the ethics committee of our hospital.

A posterolateral approach was used for all procedures, with patients in the lateral decubitus position. The socket was fixed in the acetabulum using an acetabular alignment guide, with a target acetabular position of 20° of anteversion and 45° of inclination.¹²

Acetabular and Femoral Components

Acetabular and femoral components used for MoP and CoC THAs were manufactured by Stryker Orthopaedics (Mahwah, NJ, USA), while those for MoM were from Depuy Orthopaedics (Warsaw, IN, USA) (►Fig. 1 and ►Table 1). The Crossfire Polyethylene Insert (Stryker Orthopaedics) was used for all cases in which a highly cross-linked polyethylene liner was implanted, with the BIOLOX forte (Ceramtec, Plochingen, Germany) used as a ceramic liner and head. The diameter of

the cobalt chrome head and of the ceramic head used is provided in ►Table 1.

Data Collection

The clinical data of the patients, including the Harris hip score (HHS), were prospectively recorded by a senior surgeon 1 month prior to the THA, at 6 months and 1 year post-THA, and then annually, up to the endpoint of the follow-up. These data were then retrospectively extracted from the medical records of the patients for analysis.

Radiographs of the hips were obtained in the standard anteroposterior (AP) view, with both hips in neutral rotation and 0° abduction, and in the Lauenstein (frog position) view, with the patient in the supine position and the hips in 45° abduction.^{7,13} Radiographs were obtained at 3 months post-operatively and then annually until the last follow-up.

Definite loosening of the femoral component was defined as a progressive axial subsidence of > 3 mm or a varus or valgus shift.¹⁴ Definite loosening of the acetabular component was

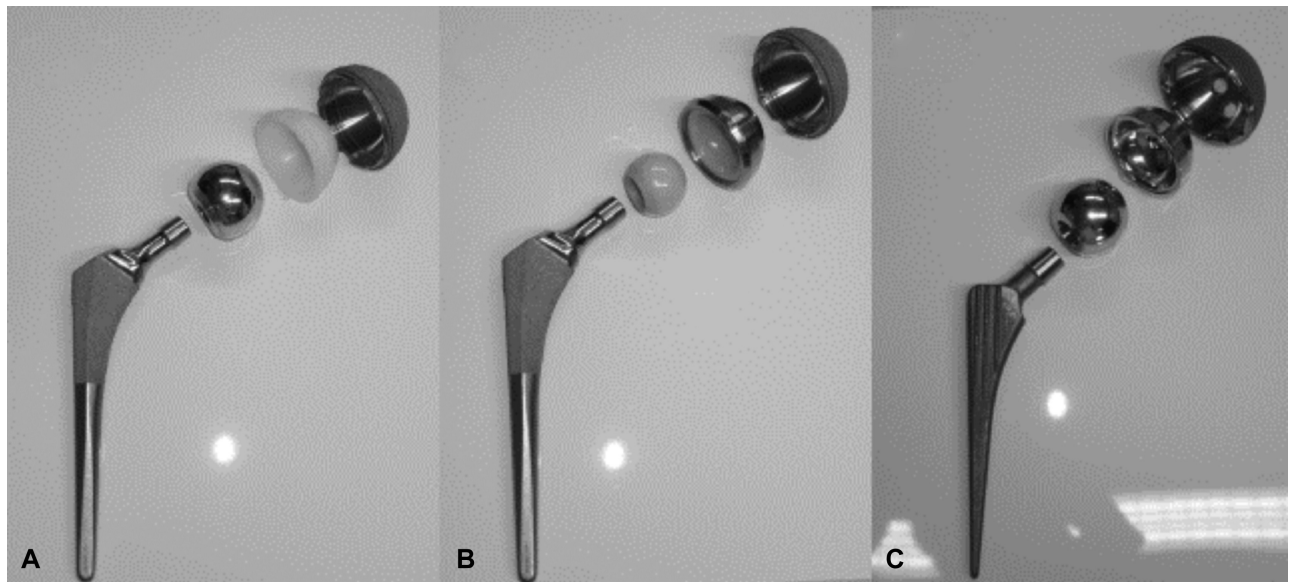


Fig. 1 Cementless components used in the present study. (A) Metal on highly cross-linked polyethylene bearing. (B) Ceramic-on-ceramic bearing. (C) Metal-on-metal bearing.

defined as a change in the vertical and/or medial position of > 2 mm or as the presence of a continuous radiolucent line > 2 mm in width on both AP- and Lauenstein-view radiographs.¹⁵ Osteolysis was defined as areas of endosteal, intracortical or cancellous bone destruction of > 2 mm, which were non-linear and progressive.¹⁶ The acetabular inclination was measured using the transischial line as a reference, and anteversion was measured from digitized AP radiographs, using the method of Lewinnek et al.¹⁷ Using the methods of Dorr et al apud Barrack et al,¹⁸ the penetration of the femoral head into the liner was measured from digitized AP- and Lauenstein-view radiographs (**Fig. 2**) by two surgeons using the Roman software, Version 1.70 (Institute of Orthopaedics, Oswestry, UK).

The femoral head penetration was measured at annual intervals to calculate the rate of wear, true wear and creep. The true wear represented the steady-state linear wear rate, while creep represented a measure of early head penetration, a feature attributable to the so-called “running-in” wear, in cases involving hard-on-hard bearings, or polyethylene creep and deformation in cases involving MoP.⁵ The wear rate was calculated by dividing total femoral head penetration at the end-point of observation by the number of years of follow-up. Linear regression models of femoral head penetration over time were constructed, with the y-intercept representing the creep rate or “running-in,” and the slope of the line representing the true wear rate.^{11,19} Intraclass correlation coefficients (ICCs) were calculated and used to determine interobserver reliability regarding the measurement of femoral head penetration. In the MoM group, patients underwent magnetic resonance imaging (MRI) when indicated, based on clinical symptoms, including hip pain or discomfort of the hip and concern for ALTR.

Statistical Analysis

Statistical analyses were performed using SPSS Statistics for Windows, Version 21 (IBM Corp., Armonk, NY, USA) and EZR (Saitama Medical Center, Jichi Medical University, Tochigi,

Japan). The differences between the groups were evaluated using analysis of variance (ANOVA), the Tukey test, the Pearson chi-squared test, the Holm-Bonferroni methods, and the log-rank test, as appropriate. A p -value < 0.05 was considered statistically significant.

Results

Clinical Results

The mean postoperative HHS was 85.3, 89.9, and 90.3 among cases involving MoP, CoC, and MoM THAs, respectively ($p = 0.063$) (**Table 2**). Neither the incidence of dislocation nor the heterotopic bone formation differed among the three groups (**Table 3**). All of the five dislocations were successfully treated conservatively via single closed reduction, without recurrence. All of the joints were classified as Brooker class 1²⁰ with the patients showing no symptoms. There was no ceramic fracture among cases involving CoC THAs (**Table 3**).

One joint among those having undergone MoP THAs (1.3%) required a revision THA owing to aseptic loosening of the cup. One joint (0.9%) among those having undergone CoC THAs required a revision THA owing to progressive femoral osteolysis caused by femoral neck impingement on the elevated acetabular metal liner. No cases of revision THA was observed among those involving MoM THAs.

One joint (0.9%) among those involving CoC THAs exhibited audible squeaking; however, a revision THA was not required because the condition was painless. No incidence of deep infection or of pulmonary embolism was identified in either group. One incidence of deep vein thrombosis (DVT) was identified among the cases involving MoP THAs; however, no DVT was observed in the CoC and MoM THA groups.

Based on the Kaplan-Meier survival curve analysis, considering implant loosening or revision THA as the endpoint, at 10 years, prosthetic survival was 96.1% (95% confidence interval [CI]: 90.0–99.3) for the MoP group, 98.6% (95% CI:

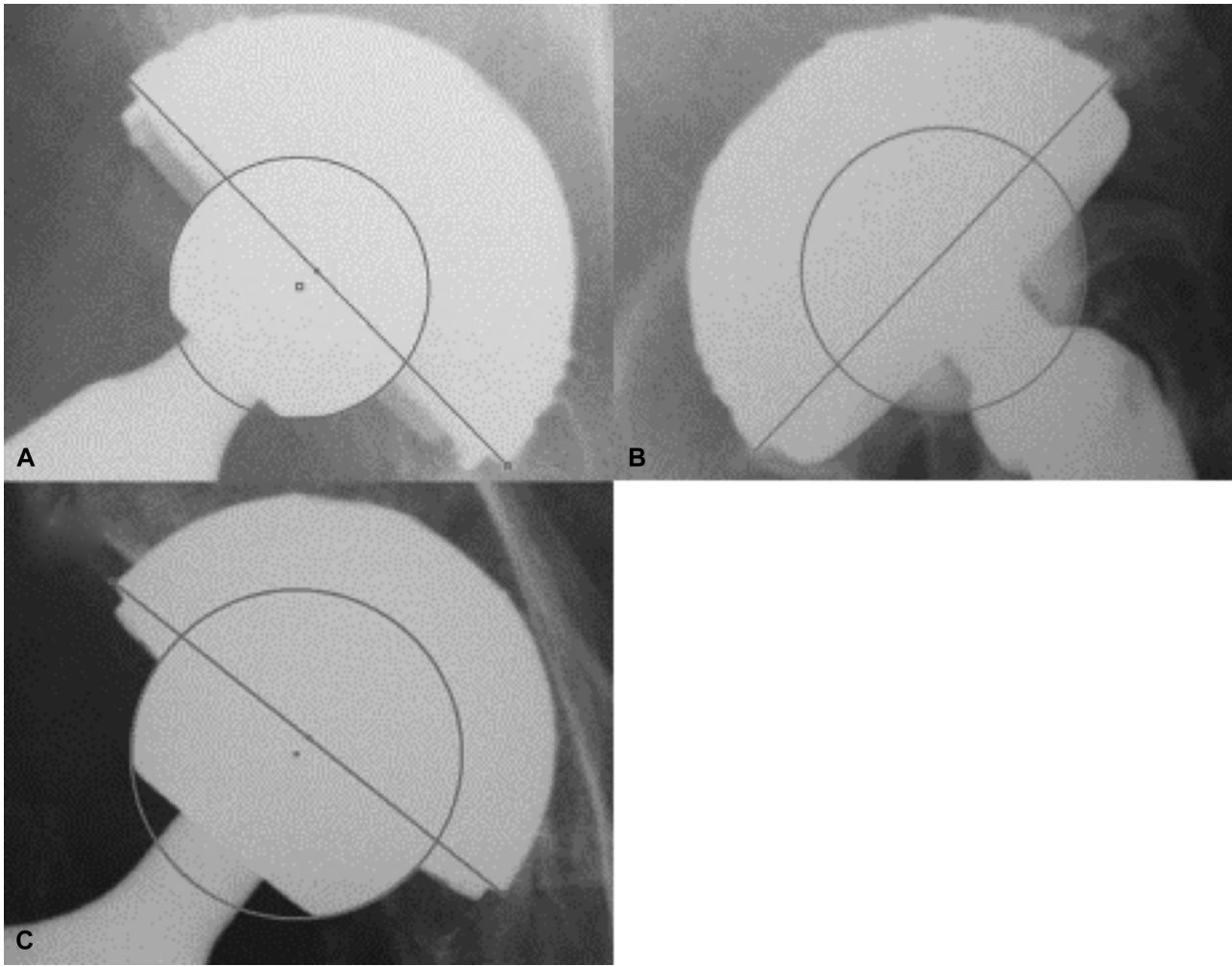


Fig. 2 Digitized anteroposterior view radiographs using the computer-digitizer facilities of the Roman software, Version 1.70 (Institute of Orthopaedics, Oswestry, UK) were obtained to determine femoral head penetration into the liners. (A) Metal on highly cross-linked polyethylene bearing. (B) Ceramic-on-ceramic bearing. (C) Metal-on-metal bearing.

90.3–98.6) for the CoC group, and 98.2% (95% CI: 88.0–99.7) for the MoM THA group. These values were not significantly different among the groups ($p = 0.360$)

Radiographic Results

Neither the anteversion nor the inclination of the implanted acetabular component differed between the three THA groups (► **Table 2**). The incidence rate of osteolysis was greater for MoM THAs than either MoP ($p < 0.05$) or CoC ($p < 0.001$) THAs (► **Table 3**). Although no joints among CoC THAs showed aseptic loosening, 2 joints (2.6%) among MoP THAs showed loosening, with 1 of these cases (1.3%) requiring revision because of progression of loosening. In contrast, 1 joint (1.8%) among MoM THAs showed aseptic cup loosening (► **Table 3**). Magnetic resonance imaging was performed on a total of 10 hips (18.2%). A pseudocystic tumor was identified in four hips; as the symptoms were minimal, a revision THA was not required.

The Wear Rate

Femoral head penetration could not be measured in eight joints among patients with CoC THAs, and in two joints among

patients with MoM THAs because the margin of the femoral head could not be identified clearly in these joints. Thus, measures of femoral head penetration were obtained for 97 and 53 joints among patients with CoC and MoM THAs, respectively. The ICC of measurement was 0.737 (95% CI: 0.16–0.982; $p = 0.0043$) for CoC, 0.876 (95% CI: 0.490–0.977; $p = 0.002$) for MoP, and 0.761 (95% CI: 0.203–0.958; $p = 0.001$) for MoM THAs.

The wear rates of CoC and MoM THAs were significantly lower than that of MoP THAs, irrespective of the radiographic view (AP and Lauenstein, $p < 0.0001$). In addition, the wear rate was significantly lower for CoC than for MoM THAs on AP-view radiographs, while the wear rate in the Lauenstein-view showed no difference between CoC and MoM THAs (► **Table 4**).

The running-in rate for CoC THAs was of 0.0036 mm/year based on AP radiographs, and of 0.0028 mm/year based on Lauenstein-view radiographs. The running-in rate for MoM THAs was of 0.0013 mm/year based on AP radiographs and of 0.0018 mm/year based on Lauenstein-view radiographs. Conversely, the creep rate for MoP THAs was of 0.0426 mm on AP-view radiographs and of 0.0440 mm on Lauenstein-view radiographs (► **Fig. 3**). The true wear rate for MoP THAs was

Table 2 Clinical and radiographic findings

| Parameters | MoP (n = 77) | CoC (n = 105) | MoM (n = 55) | p-value |
|-------------------------------|-----------------|------------------|-----------------|-----------|
| HHS | | | | |
| Preoperative | 57.0 ± 9.7 | 59.9 ± 9.2 | 61.2 ± 10.5 | 0.067 |
| Last follow-up | 87.0 ± 8.0 | 89.9 ± 7.3 | 90.3 ± 7.1 | 0.054 |
| Acetabular component position | | | | |
| Anteversión (°) | 20.7 ± 5.5 | 17.4 ± 6.9 | 19.6 ± 3.1 | 0.059 |
| Inclination (°) | 46.9 ± 5.5 | 45.9 ± 5.5 | 45.1 ± 3.1 | 0.158 |
| Osteolysis | | | | |
| Overall | 2 (2.6%) | 2 (1.9%) | 8 (14.5%) | < 0.001*† |
| Acetabular | 2 (2.6%) | 1 (0.9%) | 5 (9.1%) | 0.016‡ |
| Femoral | 1 (1.3%) | 2 (1.9%) | 4 (7.3%) | 0.143 |
| Aseptic loosening | | | | |
| Overall | 2 (2.6%) | 0 | 1 (1.8%) | 1 |
| Cup | 1 (1.3%) | 0 | 1 (1.8%) | 1 |
| Stem | 1 (1.3%) | 0 | 0 | 1 |

Abbreviation: CoC: ceramic-on-ceramic; HHS, Harris hip score; MoM: metal-on-metal; MoP: metal on highly cross-linked polyethylene. All of the values are given as the mean and standard deviation.

*CoC THAs vs MoM THAs: $p < 0.001$.

†MoM THAs vs MoP THAs: $p < 0.05$.

‡CoC THAs vs MoM THAs: $p < 0.05$.

Table 3 Complications

| Parameters | MoP (n = 77) | CoC (n = 105) | MoM (n = 55) | p-value |
|----------------------|-----------------|------------------|-----------------|---------|
| Revision THA | 1 (1.3%) | 1 (0.9%) | 0 | 0.598 |
| Deep joint infection | 0 | 0 | 0 | 1 |
| Dislocation | 2 (2.6%) | 2 (1.9%) | 1 (1.8%) | 0.797 |
| DVT, PE | 1 (1.3%)/0 | 0/0 | 0/0 | 0.556 |
| Heterotopic bone | 4 (5.2%) | 2 (1.9%) | 2 (3.6%) | 0.138 |
| Ceramic fracture | NA | 0 | NA | |
| Audible Squeaking | | 1 (0.9%) | | |

Abbreviation: CoC: ceramic-on-ceramic; DVT, Deep vein thrombosis; MoM: metal-on-metal; MoP: metal on highly cross-linked polyethylene; PE, Pulmonary embolism; THA, Total hip arthroplasty.

of 0.0096 mm/year on AP-view radiographs and of 0.0093 mm/year on Lauenstein-view radiographs, while the rate for CoC was of 0.0037 mm/year on AP-view radiographs and of 0.0038 mm/year on Lauenstein-view radiographs. Conversely, the true wear rate for MoM THAs was of 0.0051 mm/year on AP-view radiographs and of 0.0050 mm/year on Lauenstein-view radiographs.

Discussion

The main reason for failure of THA with conventional polyethylene is wear of the bearing surface and the resultant

wear-induced osteolysis, which can result in implant loosening and failure.^{8,9,21} Therefore, modern materials with improved wear characteristics, such as metal, ceramics, and highly cross-linked polyethylene, have been implanted worldwide for use in THA.^{9,21–23}

Previous studies have shown that survival with aseptic loosening at the midterm follow-up does not differ significantly between CoC and MoP THAs.^{6,10} However, few studies have compared midterm outcomes between MoP, CoC, and MoM THA, without a meta-analysis being available.²⁴ In our study, we have found that the survival rates at the 10-year follow-up with regard to implant loosening or revision THA did not differ significantly between the three types of THAs. However, the risk of osteolysis was significantly higher with MoM than with CoC and MoP THAs. Therefore, the revision rate of MoM THA in long-term follow-up may be higher than that of the other THAs, because of gradually increasing osteolysis with the passage of time.²⁵

Previous studies reported a mean liner wear rate of between 0.01 and 0.059 mm/year for MoP THAs, measured using AP radiographs.^{5,6,26,27} In contrast, the mean liner wear rate for CoC THAs was of between 0.00183 and 0.0067 mm/year based on AP radiographs.^{6,28} The in vitro wear rate of CoC and MoM components were of < 0.1 mm³/million cycles and of < 1.0 mm³/million cycles, respectively.²⁹ Thus, our results are fairly consistent with those of previous reports in that the wear rate for CoC THAs was roughly 25% of the rate for MoP THAs. The wear rate for MoM THAs was ~ one-third of that for MoP THAs.

The true wear rate for MoP THAs was previously reported to be of 0.006 mm/year.¹⁹ However, to the best of our

Table 4 Wear rate

| Parameters | MoP (n = 77) | CoC (n = 105) | MoM (n = 55) | p-value |
|----------------------------|-----------------|------------------|-----------------|---------------------------|
| <i>Wear rate (mm/year)</i> | | | | |
| AP view | 0.0161 ± 0.0051 | 0.0041 ± 0.0022 | 0.0054 ± 0.0019 | < 0.001 ^{‡,§,¶} |
| Lauenstein view | 0.0158 ± 0.0061 | 0.0043 ± 0.0026 | 0.0053 ± 0.0020 | < 0.001 ^{**} ,†† |

Abbreviation: AP, anteroposterior; CoC: ceramic-on-ceramic; MoM: metal-on-metal; MoP: metal on highly cross-linked polyethylene
 Femoral head penetration could not be measured for 8 joints in the CoC group and for 2 joints in the MoM group, because the margin of the femoral head could not be identified clearly in these joints. The wear rates were measured for 97 joints in the CoC group and for 53 joints in the MoM group. All of the values are given as mean and standard deviation (SD).

[‡]CoC THAs vs MoM THAs: $p < 0.05$ (95% confidence interval [CI]: 0.00071–0.00292).

[§]CoC THAs vs MoP THAs: $p < 0.001$ (95% CI: 0.01115–0.00137).

[¶]MoM THAs vs MoP THAs: $p < 0.001$ (95% CI: 0.00934–0.01253).

^{**}CoC THAs vs MoP THAs: $p < 0.001$ (95% CI: 0.00997–0.01268).

^{††}MoM THAs vs MoP THAs: $p < 0.001$ (95% CI: 0.00900–0.01221).

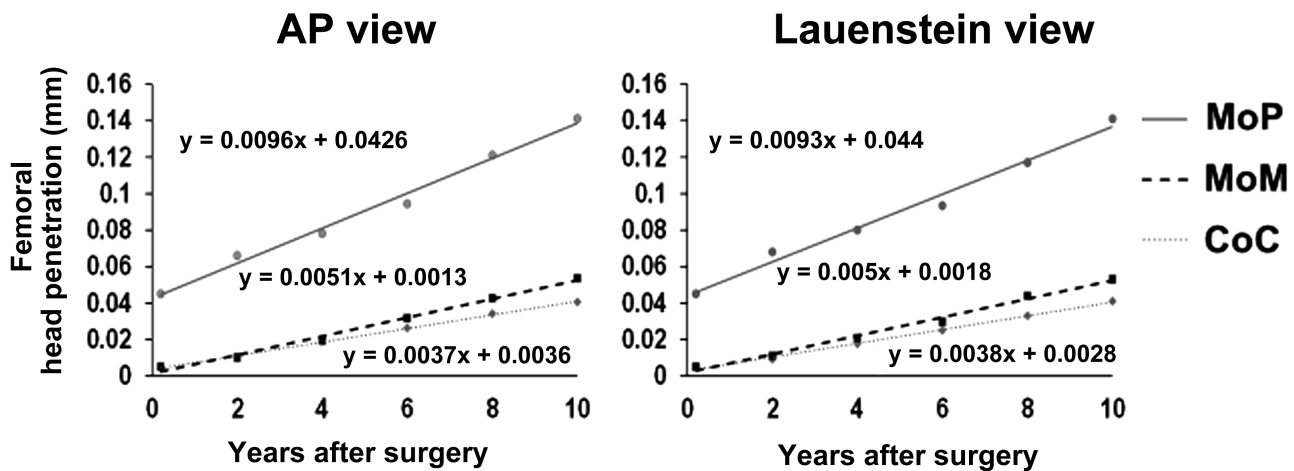


Fig. 3 Linear regression for mean femoral head penetration over time in the CoC THA and on the MoM and MoP THA groups. The slope and intercept are considered to represent true wear and creep, respectively. Abbreviations: AP: anteroposterior; CoC: ceramic-on-ceramic; MoM: metal-on-metal; MoP: metal on highly cross-linked polyethylene.

knowledge, the true wear rate for MoM THAs has not been reported thus far. The true wear rate of CoC THAs, as per our previous study, was ~ 50% of that of MoP THAs.

The overall THA survivorship was high for all of the groups, with no significant differences between the groups. The wear rates of MoM and CoC THAs were significantly lower than that of MoP THAs. However, MoM THAs exhibited more frequent osteolysis and demonstrated a significantly higher risk of revision compared with CoC and MoP THAs.²⁴ Thus, excellent clinical and radiological outcomes were obtained for CoC and MoP THAs. Longer-term studies are needed to determine the effect of the wear rate and true wear rate on implant longevity.

The present study has some limitations. First, our study is retrospective in nature, with a relatively small number of patients. Also, the analysis was based on consecutive cases, with no randomization and no power analysis performed to determine if sufficient patients were included to detect clinically meaningful differences between groups. The patients who received CoC THAs were significantly younger than the patients in the other groups. This might have been caused by selection bias and might have affected the clinical

and radiographic results. Second, we have measured femoral head penetration using the technique described by Dorr et al along with the computer-digitizer facilities of the Roman software, Version 1.70. The validity of this method for measuring femoral head penetration following CoC THAs has been previously reported.^{6,11,19} However, validation of MoM THA has never been reported. This method, which is typically used to examine femoral head penetration following MoP THA, is not easily applicable for CoC and MoM THAs. Third, we could not analyze the metal artifact reduction sequence MRI and serum metal ion levels for all of the patients with MoM THAs and could not identify an objective causative factor of osteolysis. Further studies are needed to clarify the association between bearing type and osteolysis. Finally, there were major differences in relation to the diameter of the prosthetic heads used in the three groups. In a hip simulator study, the wear rate of 36-mm ceramic bearings was significantly higher than that of 28-mm bearings, owing to their larger contact area, and paucity of lubrication when subjected to edge loading conditions.²⁹ This suggests the possibility of increased wear with the use of large heads in certain circumstances.

Conclusions

Although CoC and MoM THAs had a lower wear rate than MoP THAs, the three types of THAs provided good implant survivorship. However, osteolysis among MoM THAs was more frequently observed compared with MoP and CoC THAs. Studies that span a longer follow-up period are needed to better understand the effects of wear rate and material bioactivity on implant longevity.

Conflicts of Interests

The authors have no conflicts of interests to declare.

References

- D'Antonio JA, Capello WN, Naughton M. Ceramic bearings for total hip arthroplasty have high survivorship at 10 years. *Clin Orthop Relat Res* 2012;470(02):373–381
- Shetty V, Shitole B, Shetty G, Thakur H, Bhandari M. Optimal bearing surfaces for total hip replacement in the young patient: a meta-analysis. *Int Orthop* 2011;35(09):1281–1287
- Callary SA, Solomon LB, Holubowycz OT, Campbell DG, Munn Z, Howie DW. Wear of highly crosslinked polyethylene acetabular components. *Acta Orthop* 2015;86(02):159–168
- D'Antonio J, Capello W, Manley M, Bierbaum B. New experience with alumina-on-alumina ceramic bearings for total hip arthroplasty. *J Arthroplasty* 2002;17(04):390–397
- Engh CA Jr, Stepienwski AS, Ginn SD, Beykirch SE, Sychterz-Terefenko CJ, Hopper RH, et al. A randomized prospective evaluation of outcomes after total hip arthroplasty using cross-linked marathon and non-cross-linked Enduron polyethylene liners. *J Arthroplasty* 2006;21(06, Suppl 2):17–25
- Nikolaou VS, Edwards MR, Bogoch E, Schemitsch EH, Waddell JP. A prospective randomised controlled trial comparing three alternative bearing surfaces in primary total hip replacement. *J Bone Joint Surg Br* 2012;94(04):459–465
- Takao M, Ohzono K, Nishii T, Miki H, Nakamura N, Sugano N. Cementless modular total hip arthroplasty with subtrocantalic shortening osteotomy for hips with developmental dysplasia. *J Bone Joint Surg Am* 2011;93(06):548–555
- Milošev I, Kovač S, Trebše R, Levašič V, Pišot V. Comparison of ten-year survivorship of hip prostheses with use of conventional polyethylene, metal-on-metal, or ceramic-on-ceramic bearings. *J Bone Joint Surg Am* 2012;94(19):1756–1763
- Wyles CC, Jimenez-Almonte JH, Murad MH, Norambuena-Morales GA, Cabanela ME, Sierra RJ, et al. There Are No Differences in Short- to Mid-term Survivorship Among Total Hip-bearing Surface Options: A Network Meta-analysis. *Clin Orthop Relat Res* 2015;473(06):2031–2041
- Bascarevic Z, Vukasinovic Z, Slavkovic N, Dulic B, Trajkovic G, Bascarevic V, et al. Alumina-on-alumina ceramic versus metal-on-highly cross-linked polyethylene bearings in total hip arthroplasty: a comparative study. *Int Orthop* 2010;34(08):1129–1135
- Higuchi Y, Hasegawa Y, Seki T, Komatsu D, Ishiguro N. Significantly Lower Wear of Ceramic-on-Ceramic Bearings Than Metal-on-Highly Cross-Linked Polyethylene Bearings: A 10- to 14-Year Follow-Up Study. *J Arthroplasty* 2016;31(06):1246–1250
- Kanoh T, Hasegawa Y, Masui T, Yamaguchi J, Kawabe K, Ishiguro N. Accurate acetabular component orientation after total hip arthroplasty using an acetabular alignment guide. *J Arthroplasty* 2010;25(01):81–86
- Mestriner MB, Verquietini CM, Waisberg G, Akkari M, Fukunaga ET, Santili C. Radiographic evaluation in epiphysiolysis: possible predictors of bilaterality? *Acta Ortop Bras* 2012;20(04):203–206
- Kim YH, Kim JS, Oh SH, Kim JM. Comparison of porous-coated titanium femoral stems with and without hydroxyapatite coating. *J Bone Joint Surg Am* 2003;85-A(09):1682–1688
- Sutherland CJ, Wilde AH, Borden LS, Marks KE. A ten-year follow-up of one hundred consecutive Müller curved-stem total hip-replacement arthroplasties. *J Bone Joint Surg Am* 1982;64(07):970–982
- Lee JH, Lee BW, Lee BJ, Kim SY. Midterm results of primary total hip arthroplasty using highly cross-linked polyethylene: minimum 7-year follow-up study. *J Arthroplasty* 2011;26(07):1014–1019
- Lewinnek GE, Lewis JL, Tarr R, Compere CL, Zimmerman JR. Dislocations after total hip-replacement arthroplasties. *J Bone Joint Surg Am* 1978;60(02):217–220
- Barrack RL, Lavernia C, Szuszczewicz ES, Sawhney J. Radiographic wear measurements in a cementless metal-backed modular cobalt-chromium acetabular component. *J Arthroplasty* 2001;16(07):820–828
- García-Rey E, García-Cimbreno E, Cruz-Pardos A, Ortega-Chamorro J. New polyethylenes in total hip replacement: a prospective, comparative clinical study of two types of liner. *J Bone Joint Surg Br* 2008;90(02):149–153
- Brooker AF, Bowerman JW, Robinson RA, Riley LH Jr. Ectopic ossification following total hip replacement. Incidence and a method of classification. *J Bone Joint Surg Am* 1973;55(08):1629–1632
- Cai P, Hu Y, Xie J. Large-diameter Delta ceramic-on-ceramic versus common-sized ceramic-on-polyethylene bearings in THA. *Orthopedics* 2012;35(09):e1307–e1313
- Gallo J, Goodman SB, Lostak J, Janout M. Advantages and disadvantages of ceramic on ceramic total hip arthroplasty: a review. *Biomed Pap Med Fac Univ Palacky Olomouc Czech Repub* 2012;156(03):204–212
- Lombardi AV Jr, Mallory TH, Cuckler JM, Williams J, Berend KR, Smith TM. Mid-term results of a polyethylene-free metal-on-metal articulation. *J Arthroplasty* 2004;19(07, Suppl 2):42–47
- Yin S, Zhang D, Du H, Du H, Yin Z, Qiu Y. Is there any difference in survivorship of total hip arthroplasty with different bearing surfaces? A systematic review and network meta-analysis. *Int J Clin Exp Med* 2015;8(11):21871–21885
- Greiner JJ, Callaghan JJ, Bedard NA, Liu SS, Goetz DD, Mahoney CR. Metal-on-Metal Total Hip Arthroplasty at Five to Twelve Years Follow-Up: A Concise Follow-Up of a Previous Report. *J Arthroplasty* 2016;31(08):1773–1778
- Capello WN, D'Antonio JA, Ramakrishnan R, Naughton M. Continued improved wear with an annealed highly cross-linked polyethylene. *Clin Orthop Relat Res* 2011;469(03):825–830
- Reynolds SE, Malkani AL, Ramakrishnan R, Yakkanti MR. Wear analysis of first-generation highly cross-linked polyethylene in primary total hip arthroplasty: an average 9-year follow-up. *J Arthroplasty* 2012;27(06):1064–1068
- Epinette J-A, Manley MT. No differences found in bearing related hip survivorship at 10-12 years follow-up between patients with ceramic on highly cross-linked polyethylene bearings compared to patients with ceramic on ceramic bearings. *J Arthroplasty* 2014;29(07):1369–1372
- Al-Hajjar M, Fisher J, Tipper JL, Williams S, Jennings LM. Wear of 36-mm BIOLOX(R) delta ceramic-on-ceramic bearing in total hip replacements under edge loading conditions. *Proc Inst Mech Eng H* 2013;227(05):535–542