

Reconstruction of the Lower Limb with Fasciocutaneous Flap of the Distal Pedicle - Modified Technique of Monteiro, Series of 15 Cases*

Reconstrução do membro inferior com retalho fasciocutâneo de pedículo distal – Técnica de Monteiro modificada, série de 15 casos

Saulo Souto Montenegro¹ Antônio Carlos Costa² Robert Meves²

¹Plastic Surgery Service, Hospital Universitário Lauro Wanderley, Universidade Federal da Paraíba (UFPB), João Pessoa, PB, Brazil

²Orthopedics and Traumatology Department, Faculdade de Ciências Médicas da Santa Casa de São Paulo, São Paulo, SP, Brazil

Address for correspondence Saulo Souto Montenegro, MD, Serviço de Cirurgia Plástica, Universidade Federal da Paraíba Centro de Ciências da Saúde, Medicina, João Pessoa, PB, 58033-455, Brazil (e-mail: saulosoutomontenegro@gmail.com).

Rev Bras Ortop 2020;55(6):736–741.

Abstract

Objective To describe and demonstrate the outcomes of the modified Monteiro (1991) technique for lower limb reconstruction with a fasciocutaneous flap of the distal pedicle in a series of 15 cases.

Method We present the technique and outcomes from a series of 15 cases of the modified technique using a fasciocutaneous flap of the distal pedicle to repair the lower third of the leg and the foot.

Results Outcomes were satisfactory since these flaps provided good cutaneous and subcutaneous tissue coverage in cases with bone exposure and skin loss. The donor area was closed 3 days after surgery with a partial skin graft to provide better graft viability.

Conclusion The fasciocutaneous flap of the distal pedicle proved to be a good option for reconstruction of the middle and lower thirds of the leg, offering good bone coverage.

Keywords

- ▶ surgical flaps
- ▶ reconstruction
- ▶ lower limb
- ▶ fascia

Resumo

Objetivo Descrever e demonstrar o desfecho da técnica modificada de Monteiro (1991) para a reconstrução do membro inferior com retalho fasciocutâneo de pedículo distal numa série de 15 casos.

Método Com uma série de 15 casos, apresentamos a técnica e o desfecho da técnica modificada do retalho fasciocutâneo de pedículo distal com para a reparação do terço inferior da perna e do pé.

Resultados Os resultados foram satisfatórios porque os retalhos proporcionaram boa cobertura de pele e tecido celular subcutâneo nos casos de exposição óssea e perda cutânea. A área doadora foi fechada 3 dias após a cirurgia, com enxerto de pele de espessura parcial, proporcionando uma melhor viabilidade do enxerto.

Conclusão O retalho fasciocutâneo de pedículo distal mostrou-se como uma boa opção para a reconstrução do terço médio e inferior da perna, oferecendo boa cobertura óssea.

Palavras-chave

- ▶ retalhos cirúrgicos
- ▶ reconstrução
- ▶ extremidade inferior
- ▶ fásia

* Study performed at Hospital Universitário Lauro Wanderley (HULW-PB), Universidade Federal da Paraíba (UFPB), João Pessoa, PB, Brazil.

Introduction

The reconstruction of complex lesions in the lower limbs, usually associated with great tissue loss and bone structure exposure and fracture, is a frequent procedure due to the increased incidence of trauma in society.¹ The coverage of such lesions challenges the surgeon, who must be able to carry out a comprehensive treatment of the injury, in its multiple aspects, including, in addition to its repair, the often difficult management of complications arising during and after therapy.²

Complications, including deep venous thrombosis, venous stasis, chronic edema, atherosclerosis (which is frequent), difficulty in nerve regeneration and local skin and muscle necrosis, can occur when severe injuries are repaired.³

According to Ger,⁴ the treatment of complex tibial fractures shows that the muscle incorporation into skin increases its blood supply. Pontén⁵ reports that fascia preservation can increase the safety of skin flaps.

Microsurgical flaps are the most suitable for repairing lesions at the distal third of the leg and the foot; however, this more complex technique is difficult to perform in centers with fewer institutional resources.⁶

Fasciocutaneous flaps indications and limits were described in 1982.⁷ Some flaps with a proximal pedicle are more suitable for repair at the proximal two thirds of the leg. Basically, the techniques for soft-tissue reconstruction in the lower limbs include skin grafts, muscle flaps, fasciocutaneous flaps, cross-leg, and microsurgical flaps. Several authors have described a fasciocutaneous flap with a distal pedicle to repair lesions in the distal third of the leg and the foot.^{1,8-10}

Currently, fasciocutaneous flaps including skin, subcutaneous tissue and fascia are described; these flaps are based on the septocutaneous blood vessels system, which emerge through intercommunication with the fascial septa, branching out to form plexuses supplying the regional fat and cutaneous tissue.^{11,12}

Fasciocutaneous flaps must be the first option for soft-parts reconstruction in the lower limbs because, as regional flaps, they provide a resistant skin cover with a relatively normal appearance. They are relatively easy to perform, with great versatility, and a well-defined vascular anatomy pattern. These flaps are used even in patients with associated vascular insufficiency, such as diabetes mellitus and venous insufficiency.¹³ For Terziu and Djordjević,¹⁴ these flaps stand out in comparison to other types especially due to their well-defined vascular pattern.

The distal thirds of the leg and the foot, however, are difficult to repair because of limitations related to myocutaneous and fasciocutaneous flap pedicles.¹⁵

As such, we present a series of 15 cases using the modified technique of fasciocutaneous flap from the distal pedicle, altering flap angulation to reach a greater axis of rotation to reconstruct the middle and distal thirds of the lower limb; this modification facilitates flap management in comparison with the Monteiro technique described in 1991.⁹

We aim to describe and demonstrate outcomes from the modified Monteiro Júnior et al.⁹ technique for lower limb reconstruction with a fasciocutaneous flap of the distal pedicle in a series of 15 cases.

Method

This study was submitted to the Human Research Ethics Committee, under number CAAE 74112317.4.0000.5183

Before the experiment, each volunteer was informed about the purpose of the study and signed the Informed Consent Form (ICF) in accordance with Resolution 466/12 from the Brazilian Research Ethics Commission (*Comissão Nacional de Ética em Pesquisa*, CONEP).

The study participants were patients referred to the surgical service of Hospital Universitário Lauro Wanderlei (HULW) to repair complex lower limb lesions that met the following inclusion criteria:

- A lower limb injury
- Open or closed bone fracture
- Older than 18 years old
- Absence of any other comorbidity preventing the use of the technique proposed in the present study.
- Patients with a clinical condition favorable to the procedure.
- Minimum follow-up of 6 months

Initially, a study of the anatomical bases for flap preparation was performed by dissecting corpses in prone position. A transverse incision was made at the posterior aspect of the leg, about 6 cm from the popliteal fold, including skin, subcutaneous tissue, and muscular fascia. Two other parallel incisions were made to include the fascia, generating a flap with a distal pedicle. The perforating vessels identified at the original study were observed during dissection.

The present study was performed on patients with lower limb trauma submitted to coverage with a fasciocutaneous flap with a distal pedicle. All orthopedic procedures were performed previously or concomitantly with the flap.

All patients were submitted to an epidural anesthesia in L3-L4 with a Touhy needle # 17 using levobupivacaine hydrochloride Novabipi (Itapira, São Paulo, Brazil) 0.5%, 20 mL, and Fentanyl (Itapira, São Paulo, Brazil), 100 mcg. Dissection and flap elevation technique were performed in supine or lateral position, depending on the patient's injury.

The flap was prepared at the distal region of the leg, following a line 6 cm proximal to the popliteal fossa and 2 other distal lines perpendicular to the 1st, stopping 12 cm from the lateral malleolus and 10 cm from the medial malleolus. These points were joined, giving the flap the shape of a 'racket', with a distal base narrower than its proximal end. As such, the flap had a good amount of tissue to cover lesions at the lower third of the leg.

Dissection was performed in a craniocaudal direction, including all planes, except muscles. Perforating vessels that emerge from the muscular septum were carefully dissected with minimal trauma. The larger lateral perforating vessels were spared. Next, the flap was rotated and sutured in position at the previously prepared recipient area. The flap angulation was modified according to the position of the defect area, allowing a greater rotation arc and, consequently, a better coverage of the most distal

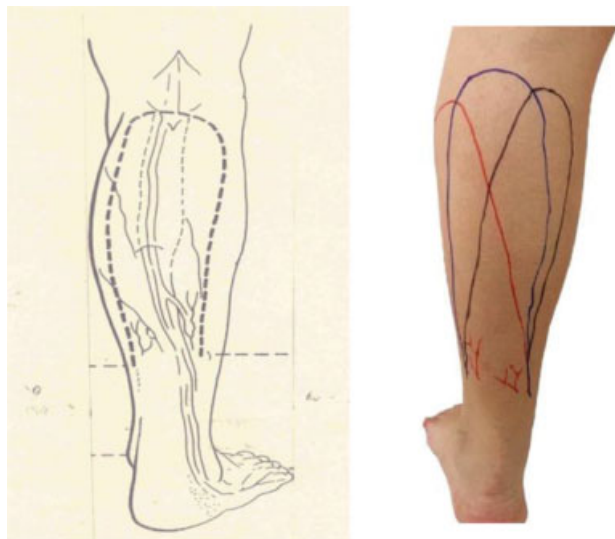


Fig. 1 The illustration shows the original dissection technique, and the photograph shows the modified flap angulation. The original flap is in blue, whereas the flap angle variation is in black and red. Source: Monteiro Jr. et al., 1991, and research data, 2019.

lesions during lower limb reconstruction (►Figure 1). The smaller muscle perforating vessels were connected, as well as the sural nerve and external saphenous vein. The largest lateral and medial perforating vessels were isolated.

The donor area was closed with a partial skin graft after 3 days, when the granulation tissue was formed, increasing graft viability. After 3 weeks, the vascular pedicle was ligated.

Results

In the present case series, 15 patients with traumatic, complex wounds in the lower limbs were treated and followed-up for a minimum period of 6 months (the approximate time for flap integration) and a maximum period of 24 months, totaling a mean time of 8 months (standard deviation, 4.89). The average age was 39.38 years, ranging from 18 to 62 years old. Most patients were in the age group from 25 to 29 years old. Fourteen patients were male, and only one was female.

Thirteen cases presented excellent results, with 100% coverage of skin and subcutaneous tissue, flap perfusion with no necrosis, and absence of infection. One case had good results, with partial skin and subcutaneous tissue coverage over the trauma area and seroma draining with no flap damage. Lastly, one case presented an intermediate result due to partial flap loss or necrosis of less than 5% of the flap with no exposure of any structure below the subcutaneous tissue. These outcomes were classified according to the Odom criteria modified by the author.¹⁶

Patients presented open fractures types III A and III B according to the Gustilo and Anderson classification¹⁷ of soft-tissue injuries in the middle and lower thirds of the leg (►Table 1 and ►Table 2). The flap provided good skin and subcutaneous tissue coverage for exposed bones in a fifteen cases series (►Figures 2–10).

Table 1 Gustilo and Anderson classification of open fractures

Type	Description
I	Wound < 1 cm with minimal soft-tissue injury
II	Wound > 1 cm with moderate soft-tissue injury
III A	Extensive soft-tissues laceration or flaps with intact skin coverage over the fractured bone, or high-energy trauma regardless of lesion size
III B	Extensive soft-tissue injury with periosteal stripping and bone exposure, usually associated with extensive contamination
III C	Open fracture with arterial injury requiring repair

Source: Gustilo RB; Anderson JT, 1976.

Sequelae were inherent to fasciocutaneous flaps, including an esthetically unpleasing scar at the donor region and hypoesthesia at the lateral the leg and foot. No complaints were reported, a fact that can be attributed to the patients' prior clarification regarding flap-related "sequelae". After 6 months, the donor area appearance was similar to ►Figure 6, with no leg function compromise.

Discussion

This case series showed that wide fasciocutaneous flaps can be elevated and rotated with few complications. The disadvantages of fasciocutaneous flaps from the distal pedicle are related to the large donor area at the leg and the performance of the procedure in two stages.

Reconstruction with free flaps requires a long and costly hospitalization, and very specialized surgical training and experience; in addition, these procedures have high material cost and long surgical time, which are the main disadvantages of this method.^{13,15}

The medial and distal thirds of the leg are difficult to repair in case of bone exposure and skin loss. Microsurgical flaps require properly equipped centers and specialized staff, with high institutional costs.

Donski and Fogdestam,⁸ in 1983, transferred their flaps based only on lateral perforating vessels, while flaps from Amarante et al.,¹⁸ in 1986, were based on medial perforating vessels. These flaps were less safe and could be compromised by the restricted blood supply.

In 1991, Monteiro Junior et al.⁹ added the 2 pedicles mentioned in ►Figure 1, greatly increasing the safety of these flaps. In our modification, by varying the angle during flap design, we increased the arc of rotation of the flap without impairing its blood supply, reaching more distal areas of the leg and the foot.

Disadvantages include the need for two surgical times to obtain the final result, and the apparent sequelae in donor areas.

This surgical procedure brought benefits to the patient, with limb recovery and movement return, depending on the type of injury; in addition, body image was restored, increasing self-esteem. The procedure also brought benefits to the institution, since outcomes from these surgeries will be useful to teach other professionals.

Table 2 Case description including age, lesion etiology, defect location, bone fracture and complications

Case	Age (years old)	Etiology	Defect location	Open fracture	Complication
1	20	Car accident	Medium third (leg)	III A	Seroma
2	16	Car accident	Medium third (leg)	III A	No
3	28	Motorcycle accident	Medium third (leg)	III A	No
4	32	Motorcycle accident	Medium third (leg)	III A	Partial necrosis
5	42	Car accident	Medium third (leg)	III B	No
6	58	Motorcycle accident	Medium third (leg)	III B	No
7	62	Motorcycle accident	Distal third (leg)	III B	No
8	25	Motorcycle accident	Distal third (leg)	III B	No
9	28	Motorcycle accident	Distal third (leg)	III B	No
10	31	Motorcycle accident	Distal third (leg)	III B	No
11	34	Motorcycle accident	Distal third (leg)	III B	No
12	45	Motorcycle accident	Distal third (leg)	III B	No
13	51	Motorcycle accident	Distal third (leg)	III B	No
14	56	Motorcycle accident	Distal third (leg)	III B	No
15	15	Motorcycle accident	Distal third (leg)	III B	No

Source: Research data, 2019.

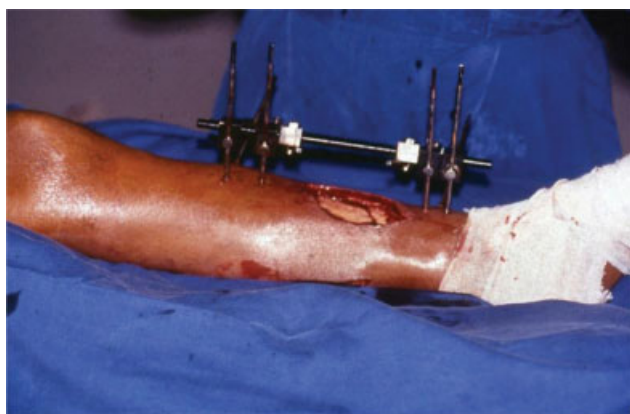

Fig. 2 Preoperative image. Source: Research data, 2019.

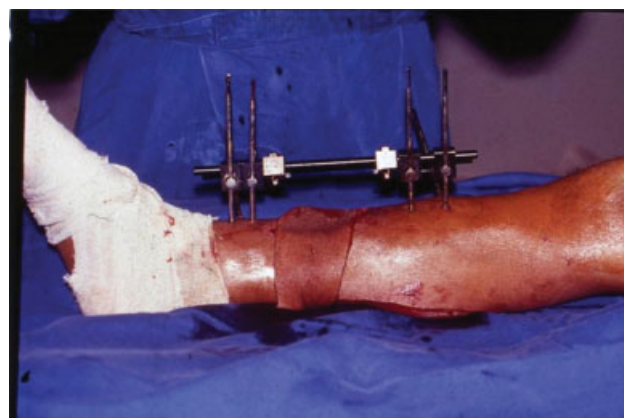


Fig. 4 Surgical image. Source: Research data, 2019.

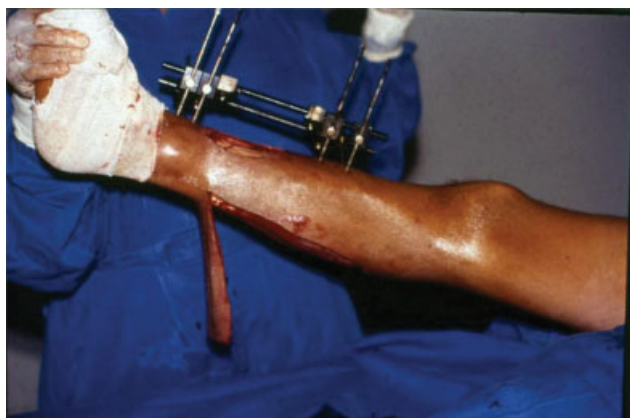

Fig. 3 Surgical image. Source: Research data, 2019.

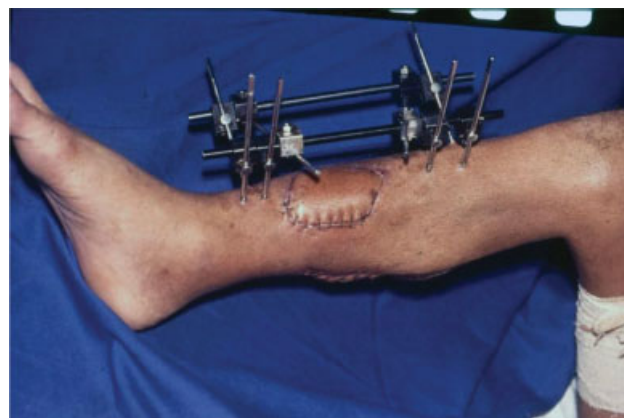

Fig. 5 Postoperative image. Source: Research data, 2019.

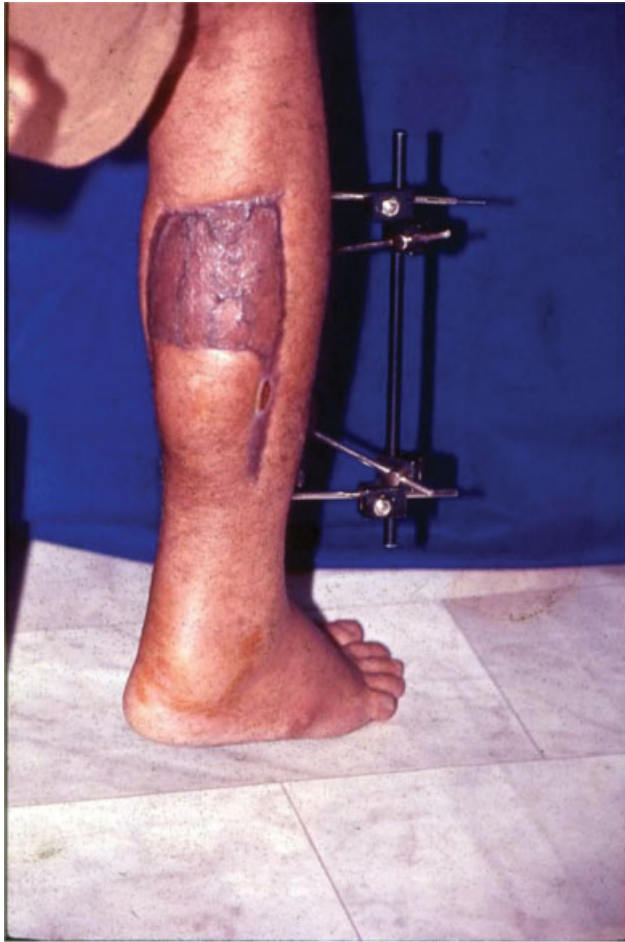

Fig. 6 Postoperative image. Source: Research data, 2019.

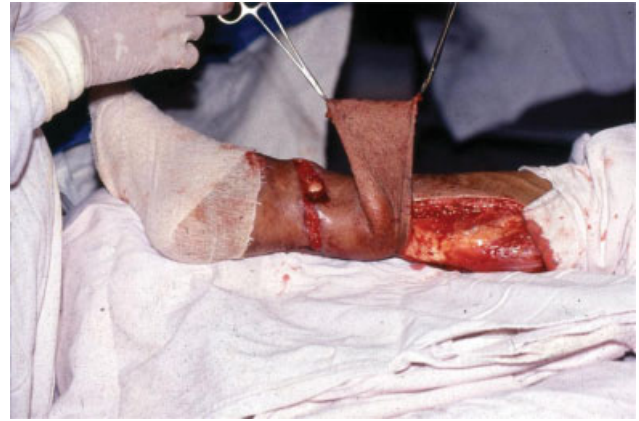

Fig. 8 Surgical image. Source: Research data, 2019.

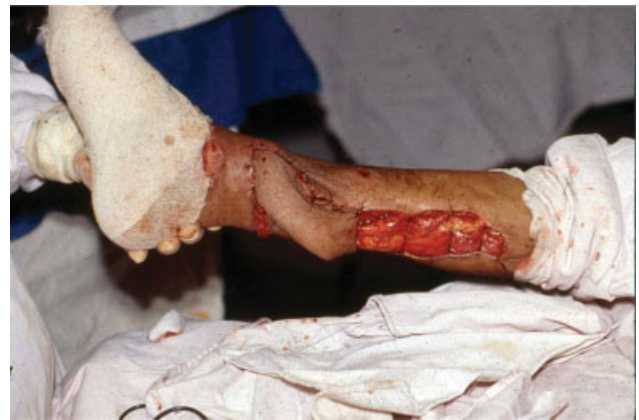

Fig. 9 Surgical image. Source: Research data, 2019.

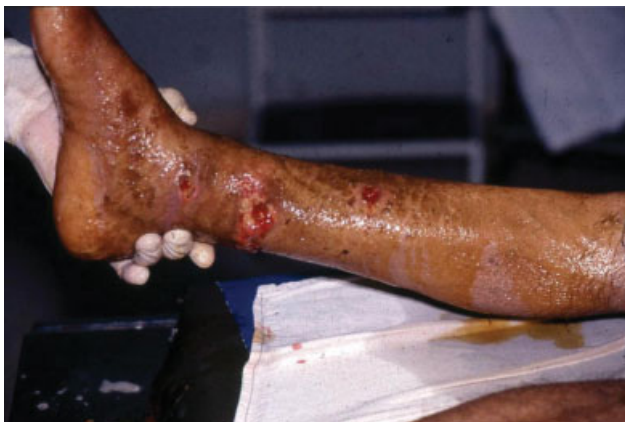

Fig. 7 Preoperative image. Source: Research data, 2019.

offering good skin coverage and subcutaneous tissue for

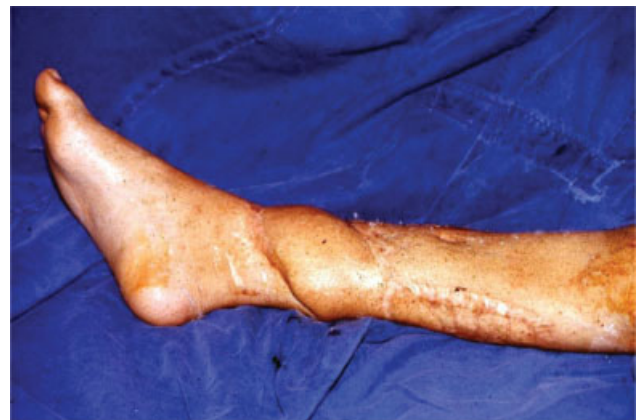

Fig. 10 Postoperative image. Source: Research data, 2019.

Conclusion

Fasciocutaneous flaps of the distal pedicle, made according to our modification in design angulation, proved to be a good option to reconstruct the medial and lower thirds of the leg,

exposed bone. In addition, this procedure can be performed in medium complexity hospitals.

Conflicts of Interest

The authors declare that there are no conflicts of interest.

References

- 1 Ríos-Luna A, Villanueva-Martínez M, Fahandezh-Saddi H, Villanueva-Lopez F, del Cerro-Gutiérrez M. Versatility of the sural fasciocutaneous flap in coverage defects of the lower limb. *Injury* 2007;38(07):824-831
- 2 Baumeister SP, Spierer R, Erdmann D, Sweis R, Levin LS, Germann GK. A realistic complication analysis of 70 sural artery flaps in a multimorbid patient group. *Plast Reconstr Surg* 2003;112(01):129-140, discussion 141-142
- 3 Rezende RBM, Macedo JLS, Rosa SC, Galli FS. Epidemiological profile and treatment of substance losses by trauma to the lower limbs. *Rev Col Bras Cir* 2017;44(05):444-451
- 4 Ger R. The management of open fracture of the tibia with skin loss. *J Trauma* 1970;10(02):112-121
- 5 Pontén B. The fasciocutaneous flap: its use in soft tissue defects of the lower leg. *Br J Plast Surg* 1981;34(02):215-220
- 6 Ferreira MC, Besteiro JM, Monteiro Júnior AA, Zumioti A. Reconstruction of the foot with microvascular free flaps. *Microsurgery* 1994;15(01):33-36
- 7 Barclay TL, Cardoso E, Sharpe DT, Crockett DJ. Repair of lower leg injuries with fascio-cutaneous flaps. *Br J Plast Surg* 1982;35(02):127-132
- 8 Donski PK, Fogdestam I. Distally based fasciocutaneous flap from the sural region. A preliminary report. *Scand J Plast Reconstr Surg* 1983;17(03):191-196
- 9 Monteiro Júnior AA, Alonso N. Repair of cutaneous losses on the leg and foot with the distally based fasciocutaneous flap. *Rev Soc Bras Cir Plast* 1991;6(1/2):33-40
- 10 Hallock GG. Utility of both muscle and fascia flaps in severe lower extremity trauma. *J Trauma* 2000;48(05):913-917
- 11 Coehn M. *Mastery of Plastic and Reconstructive Surgery*. Boston: Little & Brown Co; 1994
- 12 Taylor GI, Corlett RJ, Dhar SC, Ashton MW. The anatomical (angiosome) and clinical territories of cutaneous perforating arteries: development of the concept and designing safe flaps. *Plast Reconstr Surg* 2011;127(04):1447-1459
- 13 Benito-Ruiz J, Yoon T, Guisantes-Pintos E, Monner J, Serra-Renom JM. Reconstruction of soft-tissue defects of the heel with local fasciocutaneous flaps. *Ann Plast Surg* 2004;52(04):380-384
- 14 Terzić Z, Djordjević B. Clinical aspects of reconstruction of the lower third of the leg with fasciocutaneous flap based on peroneal artery perforators. *Vojnosanit Pregl* 2014;71(01):39-45
- 15 Costa-Ferreira A, Reis J, Amarante J. Reconstruction of soft-tissue defects of the heel with local fasciocutaneous flaps. *Ann Plast Surg* 2005;54(05):580-581
- 16 Odom GL, Finney W, Woodhall B. Cervical disk lesions. *J Am Med Assoc* 1958;166(01):23-28
- 17 Gustilo RB, Anderson JT. Prevention of infection in the treatment of one thousand and twenty-five open fractures of long bones: retrospective and prospective analyses. *J Bone Joint Surg Am* 1976;58(04):453-458
- 18 Amarante J, Costa H, Reis J, Soares R. A new distally based fasciocutaneous flap of the leg. *Br J Plast Surg* 1986;39(03):338-340