

# Combined use of low level laser therapy and cyclooxygenase-2 selective inhibition on skin incisional wound reepithelialization in mice: a preclinical study<sup>\*</sup>

Uso combinado da laserterapia de baixa potência e da inibição da ciclooxygenase-2 na reepitelização de ferida incisional em pele de camundongos: um estudo pré-clínico

Cíntia Helena Santuzzi<sup>1</sup>

Diego França Pedrosa<sup>3</sup>

Breno Valentim Nogueira<sup>5</sup>

Hygor Franca Buss<sup>2</sup>

Martha Oliveira Vieira Moniz Freire<sup>4</sup>

Washington Luiz Silva Gonçalves<sup>6</sup>

**Abstract:** BACKGROUND: Low level laser therapy and cyclooxygenase-2 (COX2) selective inhibitors have been widely used to modulate inflammatory response; however, their effect on wound reepithelialization are not well understood.

OBJECTIVE: To evaluate the isolated and combined effects of low level laser therapy and COX2 in the reepithelialization of skin incisional wounds in mice.

METHODS: We induced a 1-cm wound on the back of each mouse, which were divided into four groups (N = 20): control, laser therapy, treated with celecoxib and combined therapy. The animals in the celecoxib and combined therapy groups were treated with celecoxib for 10 days before skin incision. The experimental wounds were irradiated with He-Ne low power laser (632nm, dose: 4J/cm<sup>2</sup>) in scanning for 12 seconds during three consecutive days in the laser therapy and combined therapy groups. The animals were sacrificed 3 days after surgery. Samples of the wounds were collected and stained (Masson's Trichrome) for histomorphometric analysis.

RESULTS: Both the laser therapy group and the celecoxib group showed an increase in skin reepithelialization compared to the control group; however, the combined therapy group showed no differences. As for keratinization, the laser therapy and combined therapy groups showed a reduction in keratinocytes compared with the control group.

CONCLUSION: The results show that the use of low level laser therapy and COX2 in isolation increases epithelial cells, but only low level laser therapy reduced skin keratinocytes. The combined treatment restores innate epithelialization and decreases keratinization in spite of accelerating wound contraction with improvement in the organization of the wound in the skin of mice.

Keywords: Cyclooxygenase 2 inhibitors; Epithelial cells; Keratinocytes; Laser therapy; Wound healing

**Resumo:** FUNDAMENTOS: A laserterapia de baixa potência e os inibidores seletivos da ciclooxygenase-2 (COX2) vem sendo muito utilizados para modular a resposta inflamatória, entretanto, os seus efeitos na reepitelização de feridas não são bem compreendidos.

OBJETIVO: Avaliar os efeitos isolados e combinados da laserterapia de baixa potência e da COX2 na reepitelização de ferida incisional na pele de camundongos.

MÉTODO: Foi induzida uma ferida de 1 cm no dorso de cada camundongo, que foram divididos em quatro grupos (N=20): Controle, Laserterapia, Tratados com celecoxib e Terapia conjugada. Os animais dos grupos celecoxib e Terapia conjugada foram tratados com celecoxib por 10 dias antes da incisão cutânea. As feridas experimentais foram irradiadas com laserterapia de baixa potência He-Ne (632nm, dose: 4J/cm<sup>2</sup>) em varredura, por 12 segundos durante três dias consecutivos nos grupos Laserterapia e Terapia conjugada. Os animais foram sacrificados no 3º dia de pós-operatório. Amostras das feridas foram coletadas e coradas (Tricromio de Masson) para análise histomorfométrica.

RESULTADOS: Tanto o grupo Laserterapia, quanto o grupo celecoxib, mostrou aumento da reepitelização cutânea em relação ao grupo Controle, entretanto, o grupo Terapia conjugada não apresentou diferenças. Quanto à queratinização o grupo Laserterapia e Terapia conjugada apresentaram redução dos queratinócitos, comparados com o grupo Controle.

CONCLUSÕES: Os resultados mostram que o uso da laserterapia de baixa potência e da COX2 isoladamente aumentam as células epiteliais, mas somente a laserterapia de baixa potência reduziu os queratinócitos cutâneos. O tratamento conjugado restabelece a reepitelização inata e diminui a queratinização, embora ocorra uma acelerada contração da ferida com melhora na organização da ferida na pele de camundongos.

Palavras-chave: Cicatrização; Células epiteliais; Inibidores de ciclooxygenase 2; Queratinócitos; Terapia a Laser

Received on 20.01.2010.

Approved by the Advisory Board and accepted for publication on 24.06.10.

<sup>\*</sup> Study conducted at the Federal University of Espírito Santo (UFES), Vitória, Espírito Santo, Brazil.

Conflict of interest: None / *Conflito de interesse: Nenhum*

Financial funding: None / *Suporte financeiro: Nenhum*

<sup>1</sup> PhD student in Physiological Sciences, Federal University of Espírito Santo (UFES). – Professor at the Faculdade Salesiana of Vitoria (UNISALES) – Vitoria (ES), Brazil.

<sup>2</sup> Medicine student, Federal University of Espírito Santo (UFES) – Student in Scientific Initiation - Vitoria (ES), Brazil.

<sup>3</sup> PhD student in Biotechnology, Federal University of Espírito Santo (UFES) – Assistant Professor at the Department of Pharmaceutical Sciences, UFES – Vitoria (ES), Brazil.

<sup>4</sup> MSc in Physiological Sciences, Federal University of Espírito Santo (UFES) – Assistant Professor of Physiology, Faculdade Vitoriana (FAVI) - Vitoria (ES), Brazil.

<sup>5</sup> PhD in Physiological Sciences, Federal University of Espírito Santo (UFES) – Professor at the Department of Morphology, UFES - Vitoria (ES), Brazil.

<sup>6</sup> PhD in Physiological Sciences, Federal University of Espírito Santo (UFES). – Collaborating Professor at the Department of Physiological Sciences, University of Espírito Santo - Vitoria (ES), Brazil.

©2011 by Anais Brasileiros de Dermatologia

## INTRODUCTION

Cutaneous wound healing is a dynamic process that involves blood cells, cell mediators, extracellular matrix (ECM) and parenchymal cells. The classic model of skin repair presents three consecutive phases: *inflammation*, *proliferation* (formation of granulation tissue) and *regeneration* (tissue remodeling). Understanding these phases allows us to identify normal skin healing, recognize when intervention is necessary, and be consistent as to implementing an adjuvant therapy.<sup>1,2</sup> In the inflammatory and proliferative phases, that is, first and second phases of the skin repair process, the keratinocytes at the edge of an epidermal wound migrate, proliferate, and differentiate in order to cover the exposed surface of the wound. Then, neutrophils, macrophages and capillaries produce a new granulation tissue. Each step of this intricate process can be regulated by numerous bioactive substances released at the site of the injury and / or derived from the system, which include inflammatory cytokines, growth factors, ECM components, prostanoids, and reactive oxygen species (ROS).<sup>1-4</sup>

Classic studies show that prostaglandins (PGs), prostanoids formed by the actions of phospholipases (tissue-specific isomerases) on arachidonic acid (AA) in cell membrane phospholipids, are directly involved in tissue repair. Among the many functions of PGs are the local control of tissue metabolism and, consequently, the dynamics of cutaneous-wound healing. Lipooxygenase (LOX) and cyclooxygenase (COX) enzymes are two of these classic tissue isomerases that convert AA into PGs.<sup>4,5</sup> Currently, there are two identified isoforms of COX, a constitutive form (COX-1) and a homologous inducible form (COX-2).

Non-steroidal anti-inflammatory drugs (NSAIDs) are among the most commonly used therapeutic agents to modulate acute inflammatory response (AIR) in the tissue repair process. It has long been known that these drugs exert their effects on AIR by inhibiting the synthesis of PGs. Thus, the NSAIDs currently available are used to inhibit the synthesis of PGs and enzymes such as COXs, modulating AIR.<sup>5-8</sup> In addition, it is established that the use of cyclooxygenase (COX) selective inhibitors does not only inhibit the synthesis of PGs but also reduces the synthesis and bioavailability of nitric oxide (NO), which interferes with the structure and function of damaged skin by slowing the innate healing process.<sup>5-10</sup>

A laser is a form of "Light Amplification by Stimulated Emission of Radiation," which originated the term 'laser' as its acronym. Lasers are basically classified into two types: "high-power lasers" and "low-level lasers". Low level laser therapy (LLLT) has been mainly and widely used in many biomedical areas in order to modulate inflammatory response

and accelerate the tissue repair process.<sup>1,2,11-14</sup> Recent investigations show the influence of LLLT in the dynamics of healing of the skin and other tissues; however, there are still some controversies about it because of the wide variability and divergence in irradiation parameters, in addition to discrepancies in the biological findings.<sup>14-16</sup> Previous studies in our laboratory as well as others have suggested that photo-stimulation by laser seems to occur during the inflammatory and proliferative phases of wound healing, exactly because of their influence on biomodulation of eicosanoids, especially PGs, and on the oxidative enzyme system of the skin.<sup>1,2,5,11-19</sup>

Consequently, studies that show the effects of combined treatments in wound healing are opportune, since both laser therapy and the use of COX inhibitors act during the same time period in the repair process, that is, both separate treatments affect the inflammatory and proliferative phases of skin healing in animals and humans. Considering this scenario, the purpose of this pre-clinical study was to evaluate the isolated and combined effects of low level laser therapy (LLLT) with helium-neon (He-Ne, 632nm) and selective inhibition of cyclooxygenase-2 (COX-2) in the reepithelialization of skin-incisional wounds in mice.

## MATERIALS AND METHODS

We used 20 male Swiss mice (*Webster*) at 12 weeks of age and body weight ranging from 30-35 grams from a vivarium (CCS/UFES). The animals were kept in individual cages in a large environment with temperature controlled at 22° C and artificial light, with a photoperiod of 12h light/12 h dark; food (Purina®) and water were provided *ad libitum*. The mice were randomly divided into four groups (N = 5 in each group): 1 - Control (CT); 2 - Low-level laser therapy (LS); 3 - Treated with COX-2 inhibitors (CE); and 4 - Combined therapies (CE + LS).

The investigation was conducted in accordance with the norms established by the *Guide for the Care and Use of Laboratory Animals*, approved by the Animal Research Ethics Committee at the Federal University of Espirito Santo (UFES), under opinion report No. 004/2007.

Ten days before the surgical procedure (incision of the wound), 10 mice were previously treated with Celebra® (celecoxib, Pfizer Ind., Guarulhos, SP, Brazil) at a dose of 50 mg/Kg<sup>-1</sup>, which was daily corrected according to body weight and administered by gavage (PO), thus ensuring the effects of the drug. On the 10th day of treatment with inhibitor (COX-2), the animals were anesthetized with an anesthetic solution containing Ketamine + Xylazine (100 ml + 10 mg. Kg<sup>-1</sup>

<sup>1</sup>, respectively, intraperitoneally), the dorso-thoracic region (T<sub>1</sub> – T<sub>7</sub>) of the bodies of the mice was shaved and cleaned. Then, with a scalpel, we performed an incisional wound 1cm in length in all of the experimental animals. After that, skin sutures were performed using Steri Strip (3M<sup>®</sup>, Sao Paulo, Brazil). After suturing, LLLT was irradiated by a laser device commercially available (KLD Biosystems, Sao Paulo, SP, Brazil) with the following characteristics: helium and neon (He-Ne) semiconductors, continuous waves, wavelength of 632 nm, peak power of 5 mW, average output power of 0.5 to 3.5 mW, and application through optical fiber (spot size, 1.5 cm). The experimental wounds were irradiated in the following parameters: dose of 4 J / cm<sup>2</sup> for 12s in each of the applications in the laser (LS) and combined therapy (CE + LS) groups. Laser irradiation was performed by using the scanning method in the total length of each wound (suture), thus allowing its uniform treatment. The first laser application occurred immediately after the surgery and the other applications in the subsequent days, totalizing three days of treatment. No form of treatment was used in the control group. On the third day after surgery, the animals were sacrificed in CO<sub>2</sub> chamber, as recommended by COBEA. Samples of all skin lesions were collected in a way that included part of the skin adjacent to the sutured edges of the incisional wound and all the scar tissue in depth.<sup>2,12,20</sup>

The samples of the skin lesions obtained were fixed in paraformaldehyde-10% (pH 7.0) for at least 24 hours. After fixation, the samples were gradually dehydrated in increasing concentrations of ethanol (70% to 100%), cleared in xylene, and embedded in paraffin in accordance with routine histological methods. The fragments embedded in paraffin were cut using 820 Spencer microtome, yielding pairs of sections of 6µm thick. The histological slides were incubated for drying and, subsequently, tissue sections were stained with Masson's Trichrome (TM) for subsequent histological analysis. We captured images of four microscopic fields of each histological slide with a digital camera (100x total zoom) of optical microscope model AX70 Plus (Olympus<sup>®</sup>, Tokyo, Japan). Histomorphometric analyses were performed and evaluated using images captured by computerized imaging system *Sigma-pro*<sup>®</sup> (Sigma, St Louis, MO, USA) and stored on PC. At the end of the study, ten pairs of images were filed, totaling 50 histological sections, which were subjected to counting the volume fraction (mm<sup>2</sup>) of keratinocytes (keratinization) and epithelium (epithelialization) using digital marking by color contrast.<sup>2,20</sup>

Initially, we performed an ideal estimate for sampling using Statemat<sup>®</sup> 2.0 software, with test

power of 90% and alpha error of 0.05, which indicated five animals per group, totaling 20 experimental animals. In the evaluation of data, we performed a normality test (Shapiro-Wilk) and one-way analysis of variance (ANOVA), followed by the nonparametric test of Mann-Whitney U, using Prism<sup>®</sup> 5.0 software (GraphPad, San Diego, CA, USA). Values were expressed as mean ± standard error (SE) and the significance level for all analyses was  $p \leq 0.05$ .

## RESULTS

Histological observations of samples of skin wounds of all of the animals showed a small amount of fibronectin material (clot) on the surface with clear presence of blood vessels in the hypodermis; little or no exudate in the suture area. The skin wounds of the control group (CT) showed tissue-repair pattern of the inflammatory phase (day 3 after surgery), with raised borders and crust formation and with reddish center due to presence of blood irrigation in the area, which seemed to present an aspect of granulation tissue, consistent with the normal pattern of healing (Figure 1A). The wounds of the group treated with He-Ne LLLT (LS) presented accelerated repair, showing an early morphological and functional recovery of tissue, delineated scars with clear edges and an uneven central portion, besides a significant increase in reepithelialization (Figure 1B). Wounds in the group treated with COX-2 inhibitors (CE) presented initial repair pattern (inflammatory phase) and some clots, without demarcation of the wound edges, although they presented high presence of granulation tissue and a significant increase in reepithelialization (Figure 1C). On the other hand, the combination therapy (CE + LS) presented less fibronectin material with reepithelialization similar to that found in the control group; however, it showed early incisional wound contraction, better organization of the scar with apparent acceleration of the repair process, consistent with 7 to 9 days after surgery (Figure 1D).

In the epithelial histomorphometry presented in Graph 1A, the results showed a significant increase ( $p < 0.01$ ) of the degree of reepithelialization in the LS ( $16.9 \pm 0.8 \text{ mm}^2$ ) and CE ( $19.1 \pm 0.8 \text{ mm}^2$ ) groups compared to the CT group ( $12.6 \pm 0.8 \text{ mm}^2$ ); however, the CE + LS group ( $11.8 \pm 0.6 \text{ mm}^2$ ) showed restoration of the basal patterns of reepithelialization, indicating that the combination of techniques eliminated their separate effects. As for keratinocyte volume fraction, Graph 1B, the results showed a significant ( $p < 0.05$ ) reduction in the LS ( $6.4 \pm 0.2 \text{ mm}^2$ ) and CE + LS ( $5.3 \pm 0.5 \text{ mm}^2$ ) groups compared to the CT group ( $8.1 \pm 0.4 \text{ mm}^2$ ); however, the CE group ( $8.1 \pm 0.8 \text{ mm}^2$ ) did not present statistically significant effects. This suggests that LLLT, but not COX-2

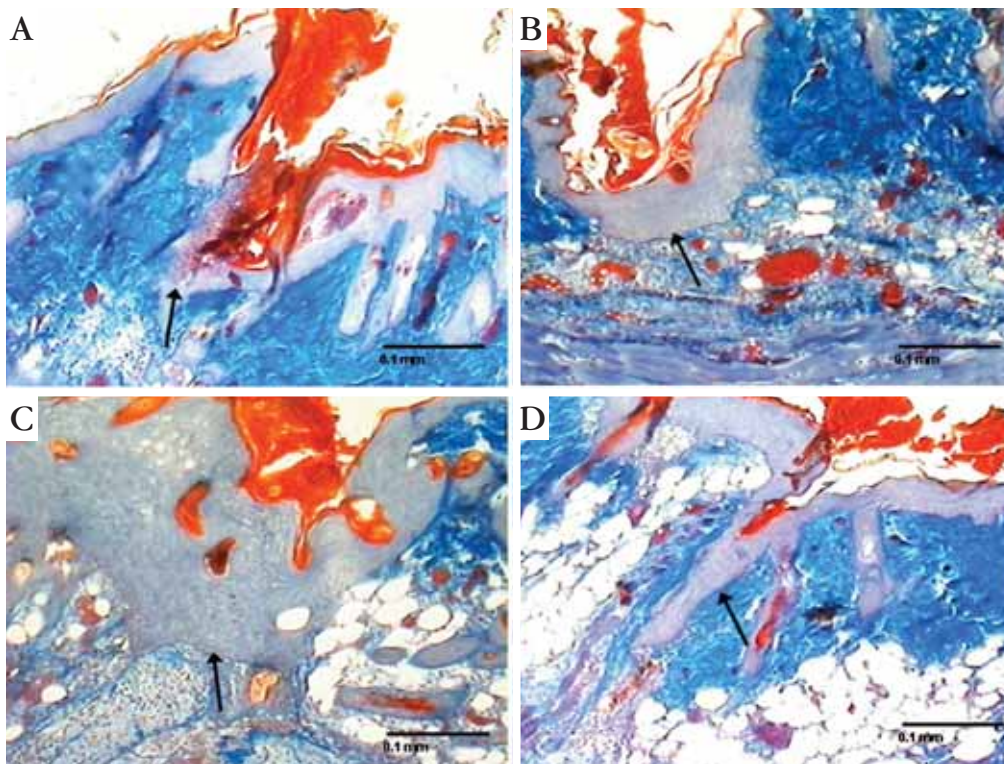
inhibitors, modulates the migration and differentiation of keratinocytes in skin wounds of mice.

**DISCUSSION**

The present study demonstrates the effects of LLLT (He-Ne) and inhibition of COX-2 (Celebra®) on the reepithelialization of surgical wounds when used alone and combined. The data obtained indicated that both LLLT (He-Ne) and COX-2 inhibitors alone increase the degree of reepithelialization in the skin of mice. However, the results also showed that the combination of the treatments eliminated the separate effects on reepithelialization and reduced the degree of keratinization in the experimental animals. They also demonstrated that this treatment combination promoted an early incisional wound contraction with improvement in the organization of scars in the skin of healthy mice.

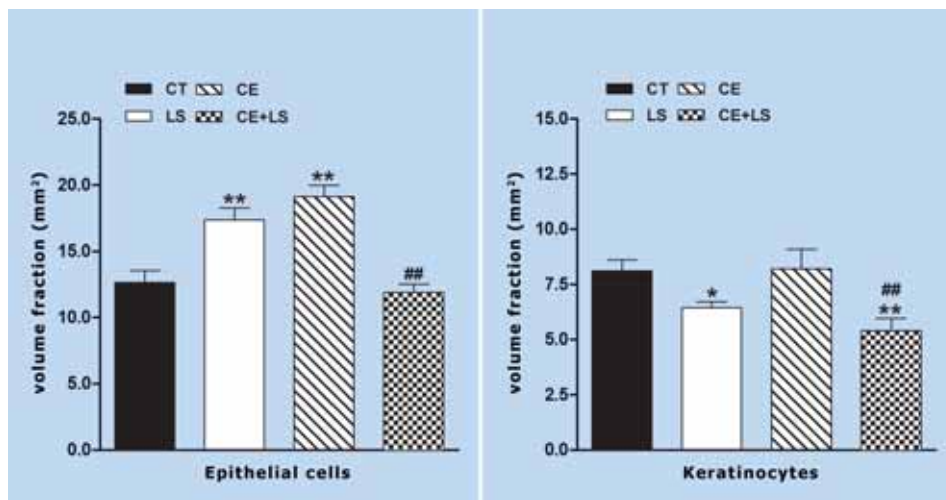
Inflammatory response induced by an epidermal injury causes migration of monocytes, particularly keratinocytes and neutrophils, which perform a rapid local consumption of oxygen (O<sub>2</sub>).<sup>3,4</sup> This mechanism activates the epidermal NADPH oxidase, catalyzing the transfer of electrons from NADPH to O<sub>2</sub>, forming superoxide anion (O<sub>2</sub><sup>-</sup>), which in larger quantities activate antioxidant enzymes and nitric oxide synthase (NOS). It is believed that laser therapy reduces local consumption of O<sub>2</sub> by neutrophils and

macrophages, stimulates the phagocytic activity of leukocytes and the differentiation of keratinocytes, leading to a decrease in the formation of O<sub>2</sub><sup>-</sup> and consequently reducing the duration of the inflammatory phase of the repair process.<sup>18, 21,22</sup> This reduction in ROS by LLLT described in the literature can also be associated with a mitochondrial reabsorption mechanism, suggesting that O<sub>2</sub><sup>-</sup> can be a source of electrons for oxidative phosphorylation of adenosine diphosphate (ADP) to adenosine triphosphate (ATP).<sup>23,24</sup> In addition, other studies have reported that LLLT directly influences levels of oxidative stress in the skin by modifying antioxidant enzymes and NOS, altering the production of ROS such as peroxynitrite (•OONO), which is a strong oxidant with the potential to destroy critical cellular components.<sup>17,17,21,22</sup> Some studies also emphasize that there may be a dose and time-dependent relation between LLLT and the production of ROS and free radicals in the skin tissue.<sup>21-23</sup> According to Karu et al.<sup>17,24</sup> and other authors<sup>20-23</sup>, exposure to LLLT stimulates an extra mitochondrial electrochemical activity and a simultaneous increase in the synthesis of adenosine triphosphate (ATP), in addition to an increase in the intracellular concentration of calcium (Ca<sup>+2</sup>), exerting effects on cellular signaling and increasing the activity of NOS in endothelial cells, which would offer cytoprotection to damage caused by lipid peroxidation induced by LLLT.<sup>14-16</sup>



**FIGURA 1:** Photomicrograph montage of skin wounds in mice in the following groups: control (CT, A), He-Ne laser therapy (LS, B), treated with celecoxib (CE, C), and treated with combined therapy (CE + LS, D). The arrows show the degree of reepithelialization in skin wounds in all groups (Masson's Trichrome, scale bar: 0.1 mm)

*Photomicrograph montage of skin wounds in mice*



Determination of the volume fraction (mm<sup>2</sup>) of epithelial cells (A) and keratinocytes (B) in the skin of mice on the 3rd postoperative day

**GRAPH 1:** Determination of the volume fraction (mm<sup>2</sup>) of epithelial cells (A) and keratinocytes (B) in the skin of mice on the 3rd postoperative day in the following groups: control (CT), He-Ne laser therapy (LS), treated with celecoxib (CE), and treated with combined therapy (CE + LS). Data expressed as mean  $\pm$  standard error of the mean (SEM). We used the Mann-Whitney U for the non-parametric variables. Being p<0.05 \*\* p<0.01 vs. CT and ## p<0.01 vs. LS and CE

Additionally, recent research has shown that the inducible isoform of nitric oxide (iNOS), a small free radical formed from the amino acid L-arginine, participates in the first phase of wound healing through inflammatory cells, especially monocytes: neutrophils and leukocytes present in the process of skin healing.<sup>3-5,17,20-24</sup> It has also been reported that nitric oxide (NO) produced by activation of the iNOS enzyme in monocytes participates in signaling for deposition of granulation tissue and collagen and for wound contraction (scar formation) via distinct pathways in animal models of wound healing.<sup>3,14,15,17,21,24</sup> Some authors also show biostimulation effects of LLLT on inflammatory cytokines through gene expression modulation of various growth factors such as platelet-derived growth factor (PDGF), transforming growth factor beta (TGF- $\beta$ ), tumor necrosis factor alpha (TNF- $\alpha$ ), and interferon gamma (IFN- $\gamma$ ), which are also potentially involved in the healing of skin wounds.<sup>24,25</sup> These regulatory effects of oxidative stress in skin, biomodulation of inflammatory cytokines and growth factors could be related to the histological findings observed in this study, in relation to the isolated treatment with LLLT (He-Ne).

The results obtained in the group treated only with COX-2 inhibitor showed a sharp increase of epithelial cells in skin wounds without changes in the keratinocytes (Graph 1A and 1B). These effects may be due to a reduction in local formation of PGs produced by classic NSAIDs, besides the important role of NSAIDs in altering the bioavailability of NO, especially selective COX-2 inhibitors,<sup>2,4-10</sup> which could have promoted the accelerated increase in reepithelialization, but with a consequent deficit in scar organization observed in the histological sections and presented in

Fig. 1C. However, it is believed that both COX-1 and COX-2 are key mediators in skin-wound healing, although COX-1 becomes important only when COX-2 is impaired. Other studies<sup>5,6,9,10</sup> also show that inhibition of COX-1 and COX-2 simultaneously can cause a compensatory increase in NOS and COX mRNA in the repair tissue, suggesting distinct and important roles for the different isoforms of COX and NOS during healing of regular skin wounds and those with deficit.<sup>6,8,14</sup>

The combination of the COX-inhibitor and LLLT (He-Ne) treatments promoted a reduction in the volume fraction of keratinocytes, which could be associated with the effect of LLLT (He-Ne) in regulating the expression and synthesis of inflammatory cytokines involved in the repair process, since the basic fibroblast growth factor (bFGF) and keratinocyte growth factor (KGF) accelerate cell differentiation of the granulation tissue.<sup>14,21,23,25</sup> However, this combination of treatments did not alter the wound reepithelialization of skin wounds in mice, but it is speculated that COX inhibitor favors biostimulation of the inflammatory phase promoted by LLLT (He-Ne), which is characterized in this study by early incisional wound contraction with improvement in scar organization, as shown in Figure 1D and in Graph 1.

## CONCLUSION

The combination of He-Ne laser therapy with COX-2 inhibitor was able to regulate the separate biostimulation effects of both treatments, presenting a more accelerated skin histomorphofunctional aspect compared with the innate process, with better arrangement of the epithelial and hypodermic structures, conjugated with accelerated and organized

repair process. However, further studies are needed to better elucidate the mechanisms involved in the

effects of LLLT and COX-2 inhibitor in terms of skin repair and regeneration. □

## REFERENCES

- Rocha Jr AM, Vieira BJ, de Andrade LCF, Aarestrup FM. Effects of low-level laser therapy on the progress of wound healing in humans: the contributions of in vitro and in vitro experimental studies. *J Vasc Bras*. 2007;6:258-66.
- Gonçalves WL, Souza FM, Conti CL, Cirqueira JP, Rocha WA, Pires JG, et al. Influence of He-Ne laser therapy on the dynamics of wound healing in mice treated with anti-inflammatory drugs. *Braz J Med Biol Res*. 2007;40:877-84.
- Witte MB, Barbul A. Role of nitric oxide in wound repair. *Am J Surg*. 2002;183:406-12.
- Clark RAF. Mechanisms of cutaneous wound repair. In: Fitzpatrick TB, Eisen AZ, Wolff K, Freedberg IM, Austen MD, editors. *Dermatology in general medicine*. New York: McGraw-Hill; 1993. p. 473-86.
- Futagami A, Ishizaki M, Fukuda Y, Kawana S, Yamanaka N. Wound healing involves induction of cyclooxygenase-2 expression in rat skin. *Lab Invest*. 2002;82:1503-13.
- Willoughby DA, Moore AR, Colville-Nash PR. COX1, COX2, and COX3 and the future of chronic inflammatory disease. *Lancet*. 2000;355:646-8.
- Amadeu TP, Costa AMA. Nitric oxide synthesis inhibition alters rat cutaneous wound healing. *J Cutan Patol*. 2006;33:465-73.
- Kampfer H, Brautigam L, Geisslinger G, Pfeilschifter J, Frank F. Cyclooxygenase-1-coupled prostaglandin biosynthesis constitutes an essential prerequisite for skin repair. *J Invest Dermatol*. 2003;120:880-90.
- Muscará MN, McKnight W, Asfaha S, Wallace JL. Wound collagen deposition in rats: effects of an NO-NSAID and a selective COX-2 inhibitor. *Br J Pharmacol*. 2000;129:681-6.
- Cahill RA, Sheehan KM, Scanlon RW, Murray FE, Kay EW, Redmond HP. Effects of a selective cyclo-oxygenase-2 inhibitor on colonic anastomotic and skin wound integrity. *Br J Surg*. 2004;91:1613-8.
- Rocha Jr AM, Oliveira RG, Farias RE, de Andrade LCF, Aarestrup FM. Modulação da proliferação fibroblástica e da resposta inflamatória pela terapia a laser de baixa intensidade no processo de reparo tecidual. *An Bras Dermatol*. 2006;81:150-6.
- Pessoa ES, Melhado RM, Theodoro LH, Garcia VG. A histologic assessment of the influence of low-intensity laser therapy on wound healing in steroid-treated animals. *Photomed Laser Surg*. 2004;22:199-204.
- Pourzarandian A, Watanabe H, Ruwanpura SM, Aoki A, Noguchi K, Ishikawa I. Er: YAG laser irradiation increases prostaglandin E production via the induction of cyclooxygenase-2 mRNA in human gingival fibroblasts. *J Periodontol Res*. 2005;40:182-6.
- Reddy GK. Photobiological basis and clinical role of low-intensity lasers in biology and medicine. *J Clin Laser Med Surg*. 2004;22:141-50.
- Posten W, Wrone DA, Dover JS, Arndt KA, Silapunt S, Alam M. Low-level laser therapy for wound healing: mechanism and efficacy. *Dermatol Surg*. 2005;31:334-40.
- Maiya GA, Kumar P, Rao L. effects of low intensity helium-neon (He-Ne) laser irradiation on diabetic wound healing dynamics. *Photomed Laser Surg*. 2005;23:187-90.
- Karu TI, Pyatibrat LV, Afanasyeva NI. Cellular effects of low power laser therapy can be mediated by nitric oxide. *Lasers Surg Med*. 2005;36:307-14.
- Silveira PCL, Silva LA, Tuon T, Freitas TP, Streck EL, Pinho RA. Effects of low-level laser therapy on epidermal oxidative response induced by wound healing. *Rev Bras Fisioter*. 2009;13:281-7.
- de Araújo CE, Ribeiro MS, Favaro R, Zzell DM, Zorn TM. Ultrastructural and autoradiographical analysis show a faster skin repair in He-Ne laser-treated wounds. *J Photochem Photobiol B*. 2007;86:87-96.
- Carvalho PTC, Mazzer N, Reis FA, Belchior ACG, Silva IS. Analysis of the influence of low-power He-Ne laser on the healing of skin wounds in diabetic and non-diabetic rats. *Acta Cir Bras*. 2006;21:177-83.
- Fujimaki Y, Shimoyama T, Liu Q, Umeda T, Nakaji S, Sugawara K. Low-level laser irradiation attenuates production of reactive oxygen species by human neutrophils. *J Clin Laser Med Surg*. 2003;21:165-70.
- Mileva M, Bakalova R, Zlateva G. Low-intensity laser irradiation does not affect the oxidative stress in experimental cataract. *Medical Laser Application*. 2004;19:150-4.
- Fillipin LI, Mauriz JL, Vedovelli K, Moreira AJ, Zettler CG, Lech O, et al. Low-level laser therapy (LLLT) prevents oxidative stress and reduces fibrosis in rat traumatized achilles tendon. *Lasers Surg Med*. 2005;37:293-300.
- Karu TI, Afanas'eva NI. Cytochrome c oxidase as the primary photoacceptor upon laser exposure of cultured cells to visible and near IR-range light. *Dokl Akad Nauk*. 1995;342:693-5.
- Safavi SM, Kazemi B, Esmaili M, Fallah A, Modarresi A, Mir M. Effects of low-level He-Ne laser irradiation of IL-1 $\beta$ , TNF- $\alpha$ , IFN- $\gamma$ , TGF- $\beta$ , bFGF, and PDGF in rat's gingival. *Lasers Med Sci*. 2008;23:331-5.

### MAILING ADDRESS / ENDEREÇO PARA CORRESPONDÊNCIA:

**Cíntia Helena Santuzzi**

**R. Miltbor de Oliveira Fernandes - 50**

**Ap. 404 Bloco A Bairro: Jardim Camburi**

**29090760 Vitória - SP, Brazil**

**Celular: 27 9944 1177 Fone (Alt.)**

**Email: csantuzzi@terra.com.br**

How to cite this article/*Como citar este artigo*: Santuzzi CH, Buss HF, Pedrosa DF, Freire MOV, Nogueira BV, Gonçalves WLS. Combined use of low level laser therapy and cyclooxygenase-2 selective inhibition on skin incisional wound reepithelialization in mice: A preclinical study. *An Bras Dermatol*. 2011;86(2):278-83.