

Right Colon Volvulus associated to Acquired Megacolon

Work carried out at the "Hospital Municipal Prof. Waldomiro de Paula, Hospital Umberto Primo I".

Key Words: Volvulus, Megacolo, Colo, Colectomy, Chagas' Diseases.

INTRODUCTION

Colon volvulus is one of the leading causes of intestinal obstruction. It is cited in two different literature reviews, one from England and the other one from the US, as the etiologic agent of abdominal obstruction in 4 to 5% (1,2). In two other literature reviews from the Hospital das Clínicas da Universidade de São Paulo in São Paulo city, Brazil, colon volvulus was the cause of intestinal obstruction in 11 to 20% of the cases (3,4). Habr-Gam et al reported a 20% of incidence of volvulus in cases of intestinal obstruction (3). That is possibly related to the high prevalence of Chagasí disease in Brazil that affects the rectal and sigmoid segments of the colon leading to sigmoid volvulus. The authors reported that out of 709 consecutive cases of volvulus, only cases of sigmoid volvulus were seen with no right colon volvulus recorded in that sample (4).

Right colon volvulus is an uncommon cause of intestinal obstruction. According to American and European literature reviews, right colon volvulus is responsible for only 1 to 2% of the cases of volvulus and out of the overall cases of colon volvulus, right colon volvulus is responsible for 25 to 40% of the cases displaying a mortality rate ranging from 6 to 35% (5,6,7,8,9,10,11,12,13).

The authors report herein two subjects with right colon volvulus associated with an acquired megacolon. The subjects responded successfully to surgery and had an uncomplicated follow-up.

CASE REPORT

Case number 1

A 61-year-old male was initially admitted to the emergency ward of the Hospital Municipal Prof. Waldomiro de Paula in São Paulo city because of a 7-day-long history of constipation associated with abdominal pain in the last three days. Usual bowel habits averaged twice a week with the help of laxative medication. The physical exam demonstrated abdominal distention with no palpable abdominal masses. Rectal examination was unremarkable. Blood leukocyte count showed a shift to the left. Abdominal roentgenograms disclosed a voluminous distension of the abdominal loops with several air-fluid levels, both highly suggestive of obstruction. An image suggestive of the cecum was identified in the upper left abdominal quadrant just above the gastric bubble (fig 1).

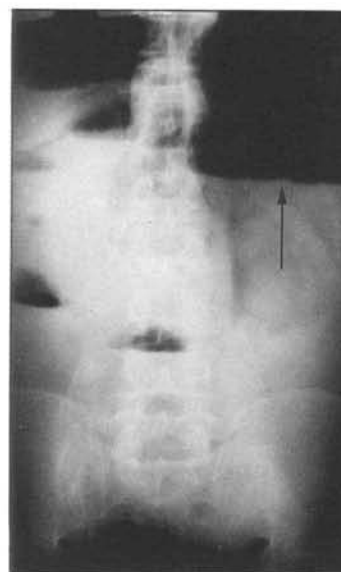


Figure 1 – Abdominal roentgenogram obtained in orthostasis. Upper left abdominal quadrant cecum is suspected

Address for correspondence: Dr. Francisco de Salles

Collet e Silva
 Rua Pamplona, 444, Apt. 52 – CEP 01405-000
 São Paulo – São Paulo – Brazil

The subject was operated upon and a cecal volvulus was found intra-operatively in the upper left abdominal quadrant. The cecum was enlarged and displayed several ischemic patches on its wall. The right colon disclosed a common mesoileocolon but no adherence to the posterior peritoneal cavity was found. A megasigmoid was also found (fig 2). Total colectomy was performed and a one-time ileorectostomy was undertaken.

Follow-up was unremarkable and the subject presented a mild surgical wound infection. Bowel habits resumed at three times/day at the time the patient was discharged.

Anatomopathological analysis revealed a cecum and descendent colon diameter of 18 centimeters in size. Sigmoid diameter was 16 centimeter in size and the other segments had 2,3 centimeters of diameters. Microscopic exam revealed an acute colitis with patchy areas of necrosis on its wall.

Case number 2

A 42 year-old woman was admitted to the emergency ward of the Hospital Humberto Primo in São Paulo city because of a 15-day-long history of colicky abdominal pain. Three days before admission she had developed nausea, vomiting, abdominal distension and arrest in the elimination of gases and feces.

She reported Chagasí disease and eight previous surgeries for the correction of a megacolon and megaesophagus in the past years.

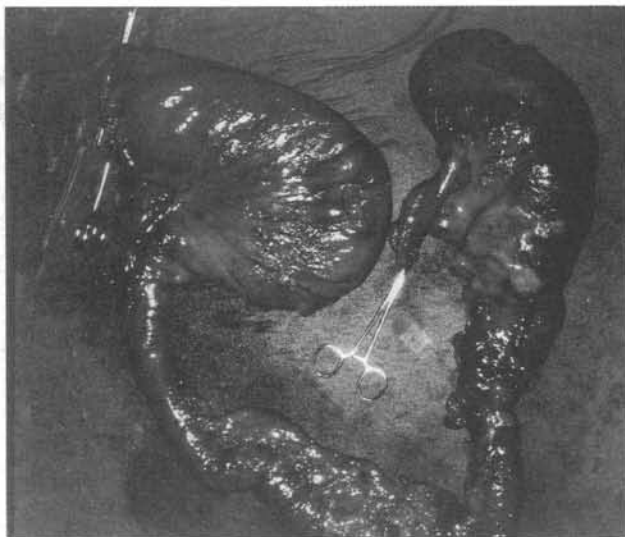


Figure 2 – Surgical piece showing diameter enlargement of both right and sigmoid colon.

Physical examination revealed signs of dehydration and sepsis. Abdominal distension was also present as well as suggestive signals of peritonitis.

Laboratory findings were: Hb = 13.3g/dl; Ht = 44% ; Leukocyte count = 7,300 cells with 10% of band neutrophils.

An abdominal roentgenogram disclosed signals of pneumoperitoneum and distension.

The patient was operated and the intra-operative findings were: generalized peritonitis; a distended right colon with a volvulus; the absence of the sigmoid because of the previous surgeries. Total colectomy and ileostomy with closure of the rectal stump were performed. She developed a post-operative lung infection which was promptly treated with antibiotics. Reconstruction of her intestine was performed 6 months later. At 18-month follow-up she did not present any signs of restrictive diarrhea.

Anatomopathological analysis demonstrated a colon with 15 centimeters of diameter and several smaller diverticula of 0.5 to 2.0 centimeter of diameter.

DISCUSSION

Literature reviews about right colon volvulus acknowledge the determining factor of its emergence the mobility of the colon segment that is usually attached to the posterior abdominal wall (6, 7, 8, 9, 10, 11). Predisposing factors to volvulus are: constipation, pregnancy, laxative medication, previous abdominal surgery (6).

In the first case reported herein, there are two factors, colon mobility and laxative medication because of chronic obstipation. In the second case, three factors were found, colon mobility, laxative medication and previous abdominal surgery.

The incidence of sigmoid volvulus in Brazil is high due to the presence of Chagasí disease. The latter is caused by the *Trypanosoma cruzi* which is transmitted by a hematophagous insect of the *triatominae* family (3). The *Trypanosoma cruzi* promotes the destruction of the intestinal intramural nerve plexus, producing a motor dysfunction that leads to stasis and enlargement in length and diameter of the colon (3,14,15). These are the predisposing factors for the development of megacolon and one of its complications, the volvulus.

The authors have found a megasigmoid in the first case and serologic reaction for Chagasí disease in both cases. These morphological changes determined by the *Trypanosoma cruzi* in the colon could play a definite role in the determination of a right colon volvulus provided that mobility of this segment is present.

The incidence of other complications such as necro-

sis or perforation in subjects with right colon volvulus is high (about 23%) with a high death rate (5, 6, 7, 8, 9, 10, 11, 12, 13). Toxic dilatation of the colon in Chagas's disease may also lead to a similar clinical picture and when associated with colon volvulus produces a dramatic clinical picture with a high mortality (16). Uncomplicated right colon volvulus can be treated with the fixation of the right colon to the wall and drainage by means of a cecostomy through the base of the cecal appendix is also possible (5, 6, 7, 8, 9, 10, 11, 12, 13). The current literature is concordant about complicated volvulus. Resection is mandatory with intestinal reconstruction performed at the time of the surgery or later. This reconstruction should be performed as long as the situation is favorable during the initial surgery.

In the case of toxic megacolon, total colectomy is necessary as performed in the first case reported herein (16). Anatomopathologically determined colitis was identified in case number one.

REFERÊNCIAS

1. BALLANTYNE, D. G.; BRANDNER, M. D.; BEART R. W. & ILSTRUP, D. M. – Volvulus of the colon: incidence and mortality. *Ann Surg*, **202**: 83-92, 1985.
2. BUECHTER, K. J.; BOUSTANY, C. & CAILLOUETTE, R. – Surgical management of acutely obstructed colon – a review of 127 cases. *Am J Surg*, **156**: 153-158, 1988.
3. HABR-GAMA, A.; HADDAD, J.; SIMONSEN, O.; WARDE, P.; MANZIONE, A.; SILVA, J. H.; IOSHIMOTO, M.; CUTAIT, D. & RAI, A. – Volvulus of sigmoid colon in Brazil – report of 230 cases. *Dis Col Rect*, **19**: 314-320, 1976.
4. HALVORSEN, J. F. & SEMB, B. H. K. – Volvulus of the right colon. Review of 30 cases with special references to late results of various surgical procedures. *Acta Chir Scand*, **141**: 804-809, 1975.
5. HINSHAW, D. B.; CARTER, R. & JOERGENSON, E. J. – Volvulus of the cecum or right colon – a study of fourteen cases. *Am J Surg*, **98**: 175-183, 1959.
6. HJORTTRUP, A.; FREIS, J.; MERSER, S. & BREDESEN, J. – Volvulus of cecum. *Dan Med Bull*, **34**: 331-333, 1987.
7. KOBAYASI, S.; MENDES, E. F.; RODRIGUES, M. A. M. & FRANCO, M. F. – Toxic dilatation of the colon in Chagas' disease. *Br J Surg*, **79**: 1202-1203, 1992.
8. KOBERLE, F. – Patogênese dos megas. *Rev Goiana Med*, **2**: 101-110, 1954.
9. KOBERLE, F. & ALCANTARA, F. C. – Mecanismo de destruição neuronal do sistema nervoso periférico na moléstia de Chagas. *Hospital*, **57**: 1057, 1960.
10. McENTEE, G.; PENDER, D.; MULVIN, D.; McCULLOUGH, M.; NAEEDER, S.; FARAH, S.; BADURDEEM, M. S.; FERRARO, V.; CHAM, C.; GILHAM, N. & MATTEWS, P. – Current spectrum of intestinal obstruction. *Brit J Surg*, **74**: 946-980, 1987.
11. NEIL, D. A. H.; REASBECK, P. K.; REASBECK, J. C.; & EFFENEY, D. J. – Cecal volvulus: ten year experience in an Australian teaching hospital. *Ann R Col Surg Eng*, **69**: 283-285, 1985.
12. NEMER, F. D.; HAGIHARA, P. F.; MAY, E. T. & GRIFFEN, W. O. – Volvulus of the colon – a continuing surgical problem. *Dis Col Rect*, **19**: 321-329, 1976.
13. O'MARA, C. S.; WILSON, T. H.; STONESIFER, G. L. & CAMERON, J. L. – Cecal volvulus – analysis of 50 patients with long-term follow up. *Am J Surg*, **198**: 724-731, 1979.
14. RAI, A. A.; MELLO, J. B.; NETTO, A. C. & ZERBINI, E. J. – Obstrução intestinal. In: *Clínica cirúrgica. São Paulo, Sarvier*, **4**: 389-404, 1988.
15. TJLER, G. & JEBORN, H. – Volvulus of the cecum – report of 26 cases and review the literature. *Dis Col Rect*, **51**: 445-449, 1988.
16. VILLET, D. G. – Volvulus of the proximal colon. *Ann Surg*, **159**: 1075, 1959.

RESUMO

O volvo de colo direito é uma rara causa de obstrução intestinal em nosso meio e apresenta uma mortalidade elevada. Apresentam-se dois casos de volvo de colo direito associado ao megacolo adquirido, que apresentaram boa evolução. Discute-se a etiologia, o tratamento e as complicações.