



Fracture of corpora cavernosa with massive cavernosal-venous shunts

Erich K. Lang, Harry Zinn, Geraldine Abbey-Mensah, Andrew Kesselman, Michael Bergen

Radiology Department of SUNY Downstate Medical Center, Brooklyn, NY, USA

CASE DESCRIPTION

A 43 year old white male with no significant past medical history presented to our emergency department (ED) with worsening penile pain and difficulty urinating. Several hours prior to admission, the patient was involved in a motor vehicle accident in which he was an unrestrained driver. His pelvis struck the steering wheel, while he was sexually aroused. Over the next 16 hours, his penis became increasingly swollen and painful. He presented to our ED when he was unable to void.

On physical exam, the patient's vitals were unremarkable. His chest was clear and abdomen was soft. The patient's right thigh was discolored and swollen. His penis was enlarged and swollen with a very prominent and distended dorsal penile vein. Auscultation over the penis revealed a loud bruit.

Urinalysis was positive for 20-30 red blood cells and isolated small blood clots.

A retrograde urethrogram was attempted, revealing a concentrically compressed, pendulous urethra with incomplete filling of the bulbous urethra. There was no evidence of extravasation. However, the procedure was aborted secondary to intolerable pain.

A T2-weighted MRI revealed a transverse fracture across the corpora cavernosa (Figure-1, black arrows). Minimal extravasation of blood was noted on the right juxta-corporal area exten-

ding through the tunica albuginea, but contained within Buck's fascia (Figure-1, white arrow). A massively dilated draining vein was identified, indicative of arteriovenous shunt (Figure-2, arrow).

Surgical exploration revealed two small arteriovenous fistulas, which were ligated without difficulty. The enveloping tunica was repaired and the patient recovered. He sustained no loss of erectile function.

DISCUSSION

Penile fracture is a rare urologic emergency that constitutes rupture of the corpus cavernosum and tunica albuginea secondary to trauma or a sudden increased intracorporal pressure within an erect penis. Past imaging options included cavernosography and ultrasonography. However, newer options are an MRI, which offers the most accurate assessment when penile fracture is suspected and urethrogram if urethral injury is suspected (1). Contrast enhanced imaging offers no additional information.

The tunica albuginea shows low intensity on both T1 and T2-weighted sequences allowing for optimal evaluation of its integrity even in patients with severe pain and swelling of the penis (2). Tears of the tunica albuginea can appear as discontinuity of the low signal intensity structure (2). Other findings include intracavernosal and extratunical hematomas, as well as arteriovenous fistulas, as demonstrated

Figure 1 - T2 weighted MRI revealed a transverse fracture across the corpora cavernosa (black arrows). Minimal extravasation of blood is noted on the right juxta-corporal extending through the tunica albuginea, but contained within Buck's fascia (white arrow).

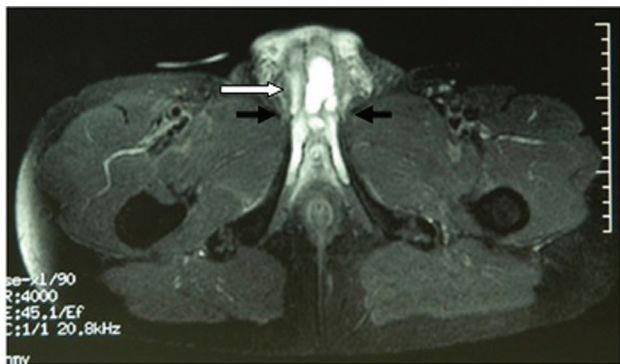
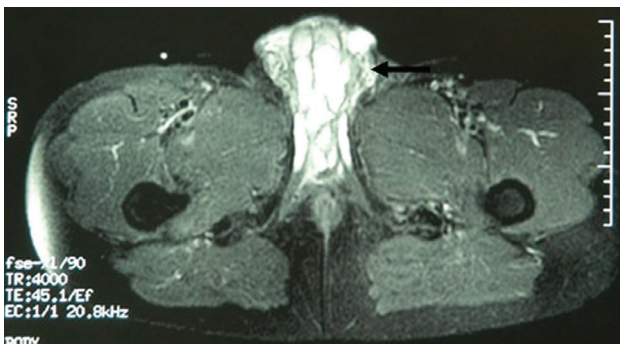


Figure 2 - Massively dilated draining vein indicative of the presence of an arteriovenous shunt (arrow).



in our case. Additionally, the presence of urethral or spongiosal involvement is associated with higher complication rates and necessitates immediate surgical intervention (3).

REFERENCES

1. Fedel M, Venz S, Andreessen R, Sudhoff F, Loening SA: The value of magnetic resonance imaging in the diagnosis of suspected penile fracture with atypical clinical findings. *J Urol.* 1996; 155: 1924-7.
2. Choi MH, Kim B, Ryu JA, Lee SW, Lee KS: MR imaging of acute penile fracture. *Radiographics.* 2000; 20: 1397-405. Erratum in: *Radiographics* 2000; 20: 1818.
3. Hoag NA, Hennessey K, So A: Penile fracture with bilateral corporeal rupture and complete urethral disruption: case report and literature review. *Can Urol Assoc J.* 2011; 5: E23-6.

Correspondence address:

Geraldine Abbey-Mensah, MD
SUNY Downstate Medical Center/
Kings County Hospital
Department of Radiology
451 Clarkson Ave #1198
Brooklyn, 11203, NY, USA
Fax: +1 516 385-9279

E-mail: geraldine.abbey-mensah@downstate.edu

ARTICLE INFO

Int Braz J Urol. 2014; 40: 277-8

Submitted for publication:
August 11, 2013

Accepted after revision:
October 09, 2013