

ASSOCIATION OF CALCIUM HYDROXIDE AND METRONIDAZOLE IN THE TREATMENT OF DOG'S TEETH WITH CHRONIC PERIAPICAL LESION

ASSOCIAÇÃO DO HIDRÓXIDO DE CÁLCIO E METRONIDAZOL NO TRATAMENTO DE DENTES DE CÃES COM LESÃO PERIAPICAL CRÔNICA

Sônia Regina PANZARINI¹, Valdir SOUZA², Roberto HOLLAND², Eloi DEZAN JÚNIOR²

1- DDS, MSc, PhD Full Professor, Department of Surgery and Integrated Clinics, Dental School of Araçatuba – UNESP – São Paulo State University, Araçatuba, São Paulo, Brazil.

2- DDS, MSc, PhD Full Professor, Department of Dentistry, Dental School of Araçatuba – UNESP – São Paulo State University - Araçatuba, São Paulo, Brazil.

Corresponding address: Professora Sônia Regina Panzarini - Departamento de Cirurgia e Clínica Integrada, Disciplina de Clínica Integrada UNESP - Universidade de São Paulo - Faculdade de Odontologia do Câmpus de Araçatuba - Rua José Bonifácio 1193 - Cep.: 1601-050 Araçatuba - São Paulo - Brasil. - Tel: (18) 3636 3249 - Fax - (18) 3636 3332 - e-mail: panzarini@foa.unesp.br

Received: November 11, 2005 - Modification: April 18, 2006 - Accepted: September 1, 2006

ABSTRACT

One of the primary objectives of endodontic treatment of teeth with pulp necrosis is the elimination of microorganisms from the root canal system, as effectively as possible, especially in cases with chronic periapical lesions. AIM: The purpose of this study was to analyze the response of the periapical tissue of dogs' teeth with chronic periapical lesions to endodontic treatment performed with utilization of metronidazole, calcium hydroxide, and an association of both as root canal dressings. METHODOLOGY: Forty root canals were submitted to pulpectomy and the root canals were kept exposed to the oral environment for 6 months. Then, they were submitted to biomechanical preparation and divided into 4 study groups with 10 specimens: group I – no root canal dressing; group II – calcium hydroxide; group III – metronidazole; group IV – calcium hydroxide associated to metronidazole. After 15 days, the root canals were filled with Fill Canal sealer. After 90 days, the animals were killed and the specimens processed for histological analysis. RESULTS: Calcium hydroxide dressing provided a significantly better outcome compared to other experimental groups ($\alpha = 0.01$). Also, the results of the association of metronidazole and calcium hydroxide were similar to those observed for the metronidazole group. The worst results were obtained by the no root canal dressing group. CONCLUSION: The use of metronidazole alone or associated with Calcium hydroxide, did not improve periapical healing when compared to Calcium hydroxide dressing.

Uniterms: Calcium hydroxide; Endodontic treatment; Metronidazole; Root canal dressing.

RESUMO

Um dos principais objetivos do tratamento endodôntico de dentes com polpa necrosada é a eliminação máxima possível dos microrganismos presentes no sistema de canal radicular, principalmente nos casos que apresentam lesões periapicais crônicas. OBJETIVO: O presente trabalho teve como objetivo analisar a resposta dos tecidos periapicais de dentes de cães com lesão periapical crônica ao tratamento endodôntico utilizando como curativo de demora o metronidazol, o hidróxido de cálcio e a associação das duas substâncias. METODOLOGIA: Foram empregados 44 canais radiculares de 2 cães adultos, portadores de lesão periapical crônica induzida experimentalmente. Após o preparo biomecânico os dentes foram divididos em quatro grupos experimentais de acordo com o curativo de demora empregado: Grupo I – controle – sem curativo de demora; Grupo II – hidróxido de cálcio; Grupo III – associação de hidróxido de cálcio e metronidazol e Grupo IV – metronidazol. Após 15 dias todos os canais foram obturados com cimento Fill Canal e passados 90 dias os animais foram sacrificados. RESULTADOS: Os dados obtidos evidenciaram que o hidróxido de cálcio apresentou resultado superior aos demais tratamentos, com diferença estatisticamente significante ($\alpha = 0.01$) e o metronidazol resultado semelhante à associação do hidróxido de cálcio com o metronidazol. Os piores resultados foram obtidos pelo grupo sem curativo de demora. CONCLUSÃO: O uso de metronidazol ou da sua associação com hidróxido de cálcio, não proporcionou melhoras no reparo quando comparado ao curativo de hidróxido de cálcio.

Unitermos: Hidróxido de cálcio; Tratamento endodôntico; Metronidazol; Curativo de demora.

INTRODUCTION

One of the primary objectives of endodontic treatment of teeth with pulp necrosis is the elimination of microorganisms from the root canal system, as effectively as possible, especially in cases with chronic periapical lesions. Instrumentation and irrigation of the root canal are the most effective procedures for such purpose, however, maintenance and enhancement of root canal cleaning is fundamental for the success of treatment. One of the procedures employed for such enhancement is the utilization of dressings between sessions⁶.

The effectiveness of intracanal medication can only be helpful if the drug employed is a germicide, since chronic periapical lesions are related to the presence of bacteria, especially anaerobes^{18,27,29}.

Calcium hydroxide has been widely employed and investigated as a root canal dressing, because of its biological and bacteriological properties^{6,8,9,14,18,25}.

Metronidazole is a synthetic antimicrobial agent, which is bactericidal and exceptionally effective against anaerobes. Even though it is not the drug of choice for dental infections, it has been largely employed as a coadjuvant in the treatment of periodontal diseases and anaerobic infections in general, when other antibiotics are not effective or are contraindicated. In Endodontics procedures, this drug has been empirically used but a scientific base is required despite the *in vitro* effectiveness against bacterias^{22,30}.

In an attempt to increase the antimicrobial activity of root canal dressing, with possible improvement of the final outcome of treatment, the aim of the present study was to analyze the response of the periapical tissue of dogs' teeth with experimentally induced chronic periapical lesions to the endodontic treatment performed with utilization of metronidazole, calcium hydroxide, and an association of both as root canal dressings.

MATERIALS AND METHODS

The sample comprised maxillary and mandibular incisors and premolars of two young male beagle dogs, adding up to 40 root canals. All the procedures of the treatment were developed in agreement with the Ethical Principles for Animal Research established by the Brazilian College for Animal Experimental (COBEA) and approved by the Institutional Committee for Ethics in Animal Research (São Paulo State University – UNESP). After anesthesia, crown opening and pulpctomy were performed on the selected teeth, and the root canals were kept exposed to the oral environment for nearly 6 months, until a radiolucent area could be observed on the tooth apices.

Afterwards, endodontic treatment was conducted in two sessions. The first session was performed with rubber dam isolation and the root canals were submitted to crown-down preparation with utilization of orifice opener, Gates Glidden burs and Kerr files until ≈ 40 , up to the cementodentinal junction, with frequent and thorough irrigation with 1%

sodium hypochlorite. After this procedure, the cement apical barrier was perforated with a Kerr file $\neq 15$ and the apical root canal was widened up to file $\neq 25$. After preparation, the root canals were once again irrigated and dried, and the teeth were divided into four study groups with 10 specimens each, according to the treatment employed: group I – no root canal dressing; group II – dressing with calcium hydroxide (Reagen Quimibras); group III – dressing with metronidazole (400mg - Rhodia Farma Ltda); group IV – dressing of calcium hydroxide associated with metronidazole (equal parts of powder). The vehicle employed was propylene glycol – 0,10ml (Apothicário Pharmacy – Araçatuba, Brazil). Canals were filled with the pastes using a lentulo and coronal sealing performed with zinc oxide eugenol cement. After 15 days, the root canal dressings of groups II, III, IV were removed, and the root canals of all study groups were filled with Fill Canal sealer, a Grossman cement (Dermo – Catumbi, Brazil) and gutta-percha by the lateral condensation technique. Finally, the cavities were restored with hybrid composite resin Z 250 (3M).

After 90 days, the animals were killed, the specimens were retrieved and processed (demineralized by EDTA 18%), and the sections obtained were stained with hematoxylin and eosin and by the Brown and Brenn staining.

For histological evaluation of the results achieved, 15 histomorphological events, according to the criteria used by Panzarini, et al.¹⁶ showed in Table 1 were considered. They were quantified by scores 1 to 4, on which 1 corresponds to the best outcome and 4 indicates the worst outcome, with intermediate outcomes for scores 2 and 3 Table 2. This way, the results achieved allowed for application of statistical analysis by the Kruskal-Wallis method and Dunn.

RESULTS

Group I – no root canal dressing

This group displayed newly formed, eosinophilic cement, usually only partially repairing the areas of resorption. This newly formed cement had variable thickness, with a mean of 21.7 micrometers. The new cement formation did not provide complete biological closure of the main foramina in any case. There were rare instances of complete biological sealing of the branches of the main root canal. Thus, most of these small canals kept their communication with the periodontal ligament. The apical cement displayed many areas of resorption without repair, besides areas of active resorption (Figure 1).

In half of the specimens, the filling material reached the cementodentinal junction, the apical root canal had been penetrated in 4 instances, and overfilling toward the periodontal ligament was observed in one case. When in contact with the periodontal connective tissue in the apical root canal or ligament, the filling material led to chronic inflammatory infiltration and appearance of foreign body giant cells. A small amount of debris was observed in most specimens, which were composed of particles of dentin or

TABLE 1- Histomorphologic parameters and scores

<i>Limit of the filling material</i>
1 - CDC limit
2 - Foramen level
3 - Little overfilling
4 - Great overfilling
<i>Intensity of inflammatory reaction*</i>
1 - Absent or very few cells
2 - Mild: less than 10 cells on average
3 - Moderate: between 10 and 25 cells
4 - Severe: more than 25 cells on average
<i>Extension of the inflammatory reaction*</i>
1 - Absent
2 - Mild: inflammatory cells only close to the foramen
3 - Moderate: inflammatory cells in part of PDL thickness
4 - Severe: Inflammatory cells in all PDL thickness
<i>Apical PDL thickness (average of measurements taken in five different areas)</i>
1 - ≤ 200 µm
2 - From 201 to 300 µm
3 - From 301 to 400 µm
4 - ≥ 401 µm
<i>Apical PDL organization**</i>
1 - Well-organized PDL in all 4 parts of apical third
2 - Well-organized PDL in 3 parts
3 - Well-organized PDL in 1 or 2 parts
4 - Absent PDL in the apical third
<i>Thickness of the neoformed cementum</i>
1 - ≥ 60 µm
2 - From 20 to 59 µm
3 - From 1 to 19 µm
4 - Absent neoformed cementum
<i>Extension of the neoformed cementum</i>
1 - Neoformed cementum deposited in resorption areas or over preexisting cementum
2 - Neoformed cementum repair in more than 1/3 of the resorption areas
3 - Neoformed cementum repair in up to 1/3 of the resorption areas
4 - No neoformed cementum repair in the resorption areas
<i>Biological closure of the apical accessory canals</i>
1 - Complete closure of all apical accessory canals
2 - Complete closure of most apical accessory canals
3 - Complete closure of few apical accessory canals
4 - No closure of the apical accessory canals
<i>Biological closure of the main root canal</i>
1 - Complete apical closure
2 - Partial closure: little communication between the PDL and root canal interior
3 - Neoformed cementum deposited in the apical lateral walls of the main root canal
4 - No deposition of neoformed cementum
<i>Apical cementum resorption</i>
1 - No resorption or repaired resorption areas
2 - Partially repaired resorption areas
3 - Non-repaired resorption areas
4 - Active resorption areas
<i>Bone tissue resorption</i>
1 - Absent or repaired resorption areas
2 - Inactive resorption areas
3 - Few active resorption areas
4 - Many active resorption areas
<i>Microorganisms</i>
1 - Absent
2 - Present
<i>Debris (between filling material and periapical tissues)</i>
1 - Absent
2 - Little debris
3 - Moderate amount of debris
4 - Great amount of debris
<i>Giant Cells</i>
1 - Absent
2 - Few (1 to 3)
3 - Moderate number (4 to 6)
4 - Great number (more than 7)
<i>-Ankylosis**</i>
1 - Absent
2 - Present in 1/4 of apical third
3 - Present in 2/4 of the apical third
4 - Present in more than 2/4 of the apical third

* Acute and chronic processes were evaluated in different areas (X400 magnification). ** The apical third of the root was divided into 4 parts of similar dimensions. PDL=periodontal ligament

connective tissue and did not hinder proper sealing of the root canal. The thickness of the periodontal ligament ranged from 179 to 700 micrometers, with a mean of 436µm. In all cases, it was disorganized and displayed moderate to severe chronic inflammatory infiltrate, usually accompanied by neutrophilic infiltrate of variable intensity and extension (Figure 1). Some instances presented microabscesses.

Except for one case, the Brown and Brenn staining revealed the presence of Gram-positive and Gram-negative bacteria close to the dentinal tubules, branches of the root canal and cement lacunae.

Group II – Calcium hydroxide

Newly formed, eosinophilic cement was observed in all cases, with complete repair of the areas of resorption in most cases (Figure 2). This cement provided partial biological closure of the apical root canal in half of the specimens (Figure 3), yet covered only the lateral root canals in 2 cases. The newly formed cement provided complete biological closure of the apical branches in 6 specimens, with no or only partial closure in the other specimens. The thickness of this cement ranged from 5 to 150 micrometers, with a mean of 56µm.

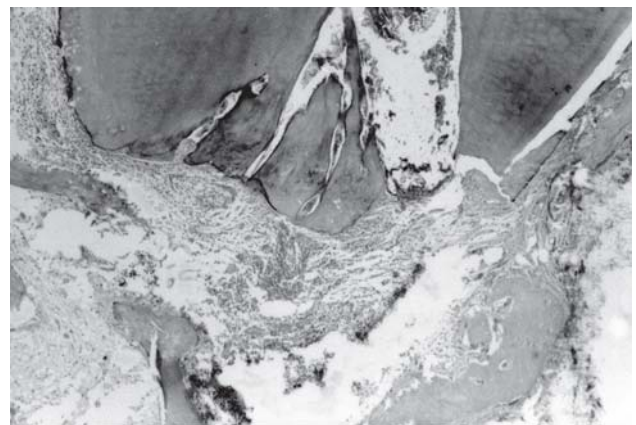


FIGURE 1- Group I – no root canal dressing – No biological closure and cement displaying areas of resorption. H.E., 100X

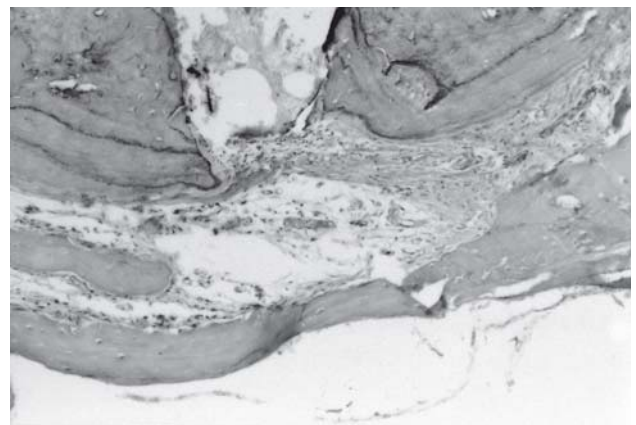


FIGURE 2- Group II – Calcium hydroxide – Presence of newly formed cement with repair of the areas of resorption and a discrete chronic inflammatory infiltrate. H.E., 100X

The filling material only reached the cementodentinal junction, except for one case. Small amounts of debris were observed in some sections; however, they did not impair the apical sealing. The thickness of the periodontal ligament ranged from 80 to 500 micrometers, with a mean thickness of 233µm, being completely or partially organized in most cases, and disorganized in only 2 specimens. No inflammatory infiltrate was observed in 3 cases; the remaining cases displayed chronic inflammatory infiltrate of variable extension and intensity.

The Brown and Brenn staining revealed the presence of Gram-positive and Gram-negative microorganisms inside the

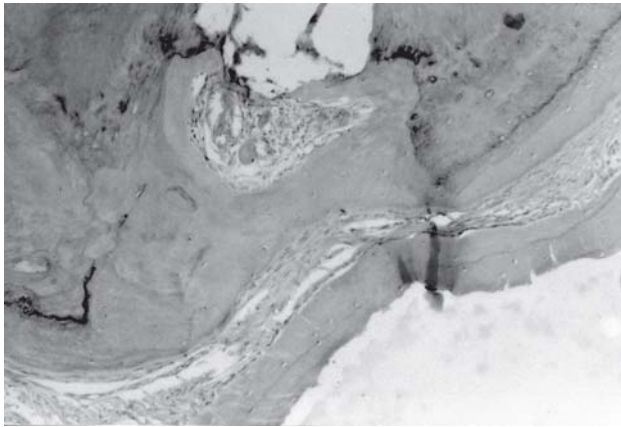


FIGURE 3- Group II – Calcium hydroxide – Newly formed cement providing a partial biological closure and a completely organized periodontal ligament. H.E., 100X

apical delta and cement lacunae in 4 specimens.

Group III – Metronidazole

Newly formed cement was found in all specimens, with thickness ranging from 10 to 154 micrometers and a mean thickness of 48µm. There were no cases of biological closure, and only 2 specimens exhibited cement formation on the lateral walls of the apical root canal. Biological closure was observed in only few apical branches. In half of the specimens, the areas of resorption were completely repaired by newly formed cement, with partial repair in the other cases (Figures 4 and 5).

Overfilling occurred in 2 instances, whereas for the other specimens the filling material was contained in the root canals; in spite of that, giant cells were found in 6 cases. The periodontal ligament usually exhibited partial organization, and chronic inflammatory infiltrate of variable intensity and extension was observed in 9 cases (Figures 4 and 5).

The Brown and Brenn staining revealed the presence of Gram-positive and Gram-negative microorganisms in 5 cases. These were found inside the apical branches and in cement lacunae.

Group IV – Calcium hydroxide + Metronidazole

Newly formed, eosinophilic cement was observed, the thickness of which ranged from 8 to 40 micrometers, with a mean of 17µm. This cement provided complete or nearly complete repair of the areas of resorption, with complete

TABLE 2- Means of the scores achieved for the different histomorphological events considered for the 4 study groups

Histomorphological events	Group I	Group II	Group III	Group IV
Thickness of newly formed cement	2.7	1.6	1.9	2.4
Extension of newly formed cement	2.1	1.7	1.6	1.4
Biological closure of the accessory foramen	3.6	2.6	3.1	2.5
Biological closure of the main foramen	3.4	2.8	3.8	3.6
Resorption of cement	2.0	1.4	1.6	1.4
Resorption of osseous tissue	2.6	1.6	1.9	1.3
Intensity of acute inflammatory infiltrate	2.6	1.3	1.0	1.1
Extension of acute inflammatory infiltrate	2.6	1.3	1.0	1.2
Intensity of chronic inflammatory infiltrate	3.6	2.5	3.0	3.6
Extension of chronic inflammatory infiltrate	3.6	2.4	2.6	3.4
Thickness of periodontal ligament	3.2	1.8	2.2	2.5
Organization of periodontal ligament	2.9	1.9	2.0	2.1
Limit of filling	1.7	1.2	1.8	2.1
Presence of debris	1.8	1.5	1.4	1.6
Presence of giant cells	2.3	1.4	1.8	2.6
Presence of bacteria	3.7	2.2	2.5	3.1
Total Score – Mean	2.71	1.82 *	2.07	2.24

* Statistical significant level (α=0.01)

biological closure of many apical branches and partial sealing of the main root canal in 2 cases, with no sealing in the other instances (Figure 6).

The apical limit of the filling material was restricted to the cementodentinal junction in 3 cases, whereas overfilling was found in 4 specimens. Debris was not observed in most cases and foreign body giant cells were found in 8 specimens. The thickness of the periodontal ligament ranged from 190 to 450 micrometers, with a mean thickness of 308µm, being partially organized in most cases. Chronic inflammatory infiltrate of moderate or severe intensity was observed in all specimens, and neutrophilic infiltrate was found in only 1 case (Figures 6 and 7).

The Brown and Brenn staining revealed Gram-positive and Gram-negative microorganisms in 6 specimens, located in the apical branches and cement lacunae.

The means of the scores achieved for the different histomorphological events considered for the four study groups are displayed in Table 1.

The scores achieved were submitted to statistical analysis by the Kruskal-Wallis method and Dunn, which

demonstrated that the calcium hydroxide dressing provided a significantly better outcome compared to metronidazole used in isolation or in combination with calcium hydroxide ($\alpha=0.01$, Table 1). On the other hand, the two latter treatment options displayed similar outcomes, yet better than those observed for the group with no dressing.

DISCUSSION

The approaches to endodontic treatment have currently emphasized the need of good biomechanical preparation and sealing of the root canal. Even though these aspects of treatment are fundamental, they should not be considered as exclusive in post-treatment repair. Thus, the steps of disinfection and cleaning should not be overlooked, since they are part of the basic principles of Endodontics for the achievement of better outcomes.

This importance was demonstrated in the present study,

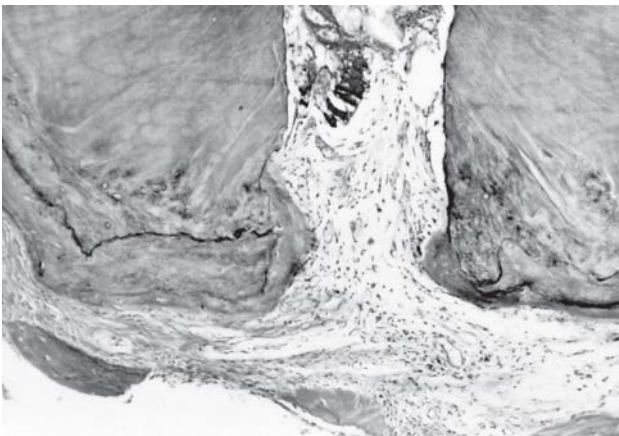


FIGURE 4- Group III – Metronidazole – No biological closure, repair of areas of cemental resorption and periodontal ligament showing few chronic inflammatory cells. H.E., 100X

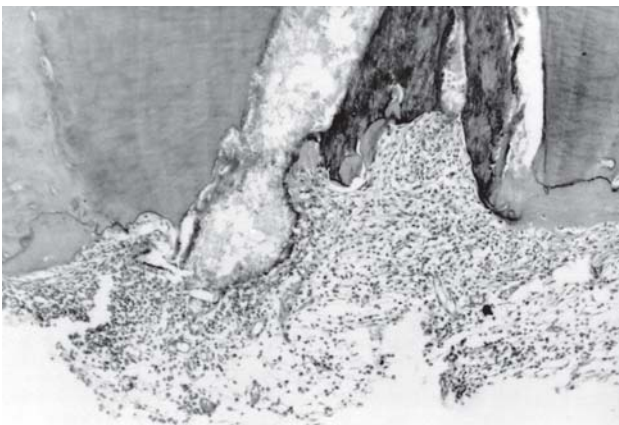


FIGURE 5- Group III – Metronidazole – No biological closure, partial repair of areas of cemental resorption and an intense chronic inflammatory infiltrate in the periodontal ligament. H.E., 100X

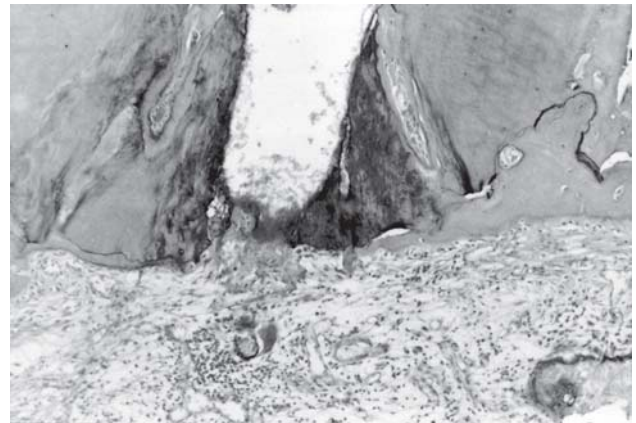


FIGURE 6- Group IV – Calcium hydroxide + Metronidazole – Partial biological closure of the main foramina and complete biological closure of some apical branches. Repair of areas of cemental resorption and presence of a moderate chronic inflammatory infiltrate in the periodontal ligament. H. E., 100X

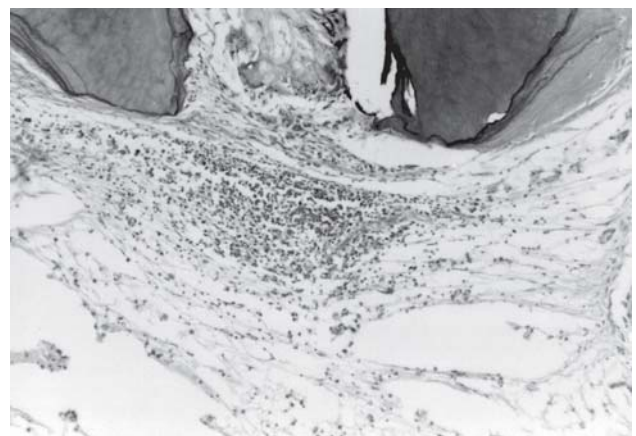


FIGURE 7- Group IV - Calcium hydroxide + Metronidazole – No biological closure and periodontal ligament showing an intense chronic inflammatory infiltrate. H. E., 100X

as indicated by the higher number of cases presenting bacteria in the group with no dressing, which influences the repair, in agreement with previous investigations^{12,16,26}.

Biomechanical preparation is known to lead to a remarkable reduction in the number of microorganisms inside the root canals^{3,4,5}. However, this reduction is only temporary, since the remaining microorganisms proliferate quickly between sessions^{7,20,24}.

Most microorganisms are located inside the main root canal, yet they can also be observed in the dentinal tubules, root canal branches, cement lacunae^{1,21}, and at the periapical region of teeth with chronic periapical lesion^{13,15,28,29}.

Calcium hydroxide has a high pH and two important properties: the inactivation of bacterial enzymes, with antibacterial effect, and the activation of tissue enzymes, with mineralizing effect⁸. Moreover, this material further affects the bacterial endotoxins, which are directly related to the synthesis and release of cytokines, which in turn are the main activators of osteoclasts¹⁷. Even though the antibacterial action of calcium hydroxide may not be complete, as demonstrated by the sections stained by the Brown and Brenn staining, the present data demonstrate that this material employed in isolation provided better outcomes when compared to the other study groups.

Considering that the bacteria found in the root canals are predominantly anaerobes²⁷, and that metronidazole is active against practically all Gram-negative anaerobes bacillus², better results were expected for the groups in which this material was used. However, they revealed that, when employed in isolation, metronidazole did not lead to biological closure of the main root canal, with closure of few apical branches and presence of bacteria in five specimens.

Despite of root canals microflora be predominantly anaerobic a mixed infection should be considered²⁷. The elimination of part of suspected pathogen could not be enough to achieve the healing. In some cases, species not eliminated by endodontic therapy can lead to treatment failure. However, although several cases of endodontic failure have been associated with a restricted group of species²³.

When compared to the calcium hydroxide group, the superiority of the latter was evidenced by the complete biological closure of the apical branches and repair of the areas of resorption observed in most specimens. These favorable results are probably related to the aforementioned properties of calcium hydroxide, i.e. potentially antibacterial and mineralizing^{8,10,19}.

Even though the difference observed in the present study was not significant, Siqueira and Uzeda²² conducted an *in vitro* investigation of the antibacterial capacity of metronidazole and calcium hydroxide associated, or not, with camphorated paramonochlorophenol and observed that metronidazole was not more effective.

The vehicle employed may interfere with the action of the drug, since it is directly related to the ionic dissociation and ability of penetration into the dentinal tubules and branches. The vehicle used in this study was propylene glycol, which is hydrosoluble, which may enhance its

diffusion in the dentin and root canal branches¹¹.

The association of calcium hydroxide and metronidazole aimed at combining the beneficial properties of both materials is an attempt to obtain a better outcome. However, this was not achieved, since the results were similar to those observed for the metronidazole group and worse than those for the calcium hydroxide group. This result may probably be related to the reduction in the volume of calcium hydroxide in the mixture and to the highly alkaline pH, which may have interfered with the action of metronidazole, therefore impairing the synergistic effect of both drugs.

Considering the results of the present study, in addition to the findings of Siqueira and Uzeda²², who did not observe an antimicrobial action superior to that of conventional drugs, the utilization of metronidazole as a routine root canal dressing is not justified.

CONCLUSIONS

The use of metronidazole alone or associated with Calcium hydroxide, did not improve periapical healing when compared to Calcium hydroxide dressing.

REFERENCES

- 1- Akpata ES, Blechman H. Bacterial invasion of pulpal dentin wall in vitro. *J Dent Res.* 1982;61:435-8.
- 2- Andrade, ED. Terapêutica Medicamentosa em Odontologia. In: Andrade ED, editor. *Uso clínico dos antimicrobianos.* São Paulo: Artes Médicas; 1999. p. 65-92.
- 3- Byström A, Sundqvist G. Bacteriologic evaluation of the efficacy of mechanical root canal instrumentation in endodontic therapy. *Scand J Dent Res.* 1981;89:321-8.
- 4- Byström A, Sundqvist G. Bacteriologic evaluation of the effect of 0.5% sodium hypochlorite in endodontic therapy. *Oral Surg Oral Med Oral Pathol.* 1983;55:307-12.
- 5- Byström A, Claesson R, Sundqvist G. The antibacterial effect of camphorated paramonochlorophenol, camphorated phenol and calcium hydroxide in the treatment of infected root canals. *Endod Dent Traumatol.* 1985;1:170-5.
- 6- Bystrom A, Happonen RP, Sjogren U, Sundqvist G. Healing of periapical lesions of pulpless teeth after endodontic treatment with controlled asepsis. *Endod Dent Traumatol.* 1987;3:58-63.
- 7- Chong BS, Pitt Ford TR. The role of intracanal medication in root canal treatment. *Int Endod J.* 1992;25:97-106.
- 8- Estrela C, Sidney GB, Bammann LL, Felipe O Jr. Estudo do efeito biológico do pH na atividade enzimática de bactérias anaeróbias. *Rev Fac Odontol Bauru.* 1994;2:29-36.
- 9- Holland R, Souza V, Nery MJ, Mello W, Bernabé PFE, Otoboni JA Filho. A histological study of the effect of calcium hydroxide in the treatment of pulpless teeth of dogs. *J Br Endod Soc.* 1979;12:15-23.
- 10- Holland R, Pinheiro CE, Mello M, Nery MJ, Souza V. Histochemical analysis of the dog's dental pulp after pulp capping with calcium, barium, and strontium hydroxides. *J Endod.* 1982;8:444-7.

- 11- Holland R, Otoboni JA Filho, Bernabe PF, Souza V, Nery MJ. Healing process of dog's pulpless teeth after apicoectomy and root canal filling at different levels. *Endod Dent Traumatol.* 1993;9:8-12.
- 12- Holland R, Otoboni JA Filho, Souza V, Nery MJ, Bernabé PFE, Dezan E Jr. Tratamiento endodóntico en una o en dos visitas. Estudio histológico em dentes de perros com lesión periapical. *Endodoncia.* 2003;21:20-7.
- 13- Kiryu T, Hoshino E, Iwaku M. Bacteria invading periapical cementum. *J Endod.* 1994;20:169-72.
- 14- Leonardo MR, Silveira FF, Silva LA, Tanomaru Filho M, Utrilla LS. Calcium hydroxide root canal dressing. Histopathological evaluation of periapical repair at different time periods. *Br Dent J.* 2002;13:17-22.
- 15- Nair PN, Sjogren U, Krey G, Kahnberg KE, Sundqvist G. Intraradicular bacteria and fungi in root-filled, asymptomatic human teeth with therapy resistant periapical lesions: a long-term light and electron microscopic follow-up study. *J Endod.* 1990;16:580-8.
- 16- Panzarini SR, Souza V, Holland R, Dezan E Jr. Tratamento de dentes com lesão periapical crônica. Influência de diferentes tipos de curativo de demora e do material obturador de canal radicular. *Rev Odontol UNESP.* 1998;27:509-26.
- 17- Safavi KE, Nichols FC. Effect of calcium hydroxide on bacterial lipopolysaccharide. *J Endod.* 1993;19:76-8.
- 18- Schein B, Schilder H. Endotoxin content in endodontically involved teeth. *J Endod.* 1975;1:19-21.
- 19- Seux D, Couble ML, Hartman DJ, Gauthier JP, Magloise H. Odontoblastic-like cytodifferentiation of human dental pulp cells "in vitro" in the presence of calcium hydroxide-containing cement. *Arch Oral Biol.* 1991;36:117-28.
- 20- Shih M, Marshall FJ, Rosen S. The bactericidal efficiency of sodium hypochlorite as an endodontic irrigant. *Oral Surg Oral Med Oral Pathol.* 1970;29:613-9.
- 21- Shovelton DS. The presence and distribution of microorganisms within non vital teeth. *Br Dent J.* 1964;117:101-7.
- 22- Siqueira JF, Uzeda M. Intracanal medicaments: evaluation of the antibacterial effects of chlorhexidine, metronidazole, and calcium hydroxide associated with three vehicles. *J Endod.* 1997;23:167-9.
- 23- Siqueira JF. Endodontic infections: concepts, paradigms, and perspectives. *Oral Surg Oral Med Oral Pathol.* 2002;94:281-93.
- 24- Sjögren U, Sundqvist G. Bacteriologic evaluation of ultrasonic root canal instrumentation. *Oral Surg Oral Med Oral Pathol.* 1987;63:366-70.
- 25- Souza V, Bernabé PFE, Holland R, Nery MJ, Mello W, Otoboni JA Filho. Tratamento não cirúrgico de dentes com lesão periapical. *Rev Bras Odontol.* 1989;46:39-46.
- 26- Souza V, Holland R. Tratamento de dentes com lesões periapicais. Influência do curativo de tricresol formalina ou de paramonoclorofenol canforado no processo de reparo após a obturação dos canais radiculares. *Rev Odontol UNESP.* 1992;21:255-66.
- 27- Sundqvist G. Taxonomy, ecology, and pathogenicity of the root canal flora. *Oral Surg Oral Med Oral Pathol.* 1994;78:522-30.
- 28- Trönstad L, Barnett F, Riso K, Slots J. Extraradicular endodontic infections. *Endod Dent Traumatol.* 1987;3:86-90.
- 29- Trönstad L, Kreshtool D, Barnett F. Microbiological monitoring and results of treatment of extraradicular endodontic infection. *Endod Dent Traumatol.* 1990;6:129-36.
- 30- Windley W, Teixeira F, Levin L, Sigurdsson A, Trope M. Disinfection of immature teeth with a triple antibiotic paste. *J Endod.* 2005;31:439-43.